


Mediwheel

भारत सरकार
Government of India

आधार

Issue Date: 06/07/2011



ప్రశాంత్ నన్నపనేని
Prasanth Nannapaneni
పుట్టిన తేదీ / DOB: 20/02/1987
పురుషుడు / MALE

2853 5244 8207

मेरा आधार, मेरी पहचान

Handwritten signature

DR. HARI CHHABLANI

M.B.B.S F.C.C.P.(RESP.MEDICINE) F.GOVAN, F.CDMLS
FELLOW INTENSIVE CARE
MMC REG. NO. - 91702

(BS/M)

DR. PLUS HEALTHCARE CENTRE
NATHANI HEIGHTS
42, MUMBAI CENTRAL


भारतीय विशिष्ट पहचान प्राधिकरण
Unique Identification Authority of India

आधार

Print Date: 27/02/2021

చిరునామా: ఎస్/ఓ నాగార్జున బాబు నన్నపనేని,
ప్లాట్ నెం 7 ఫ్లాట్ నెం 201 రాష్మిత ఎన్క్లేవ్,
భాగ్యనగర్ కాలనీ, కెపి హెచ్ బి మెట్రో స్టేషన్ దగ్గర,
కూకట్ పల్లి, కూకట్ పల్లి, మెదచల్-మల్కాజ్గిరి,
తెలంగాణ, 500072

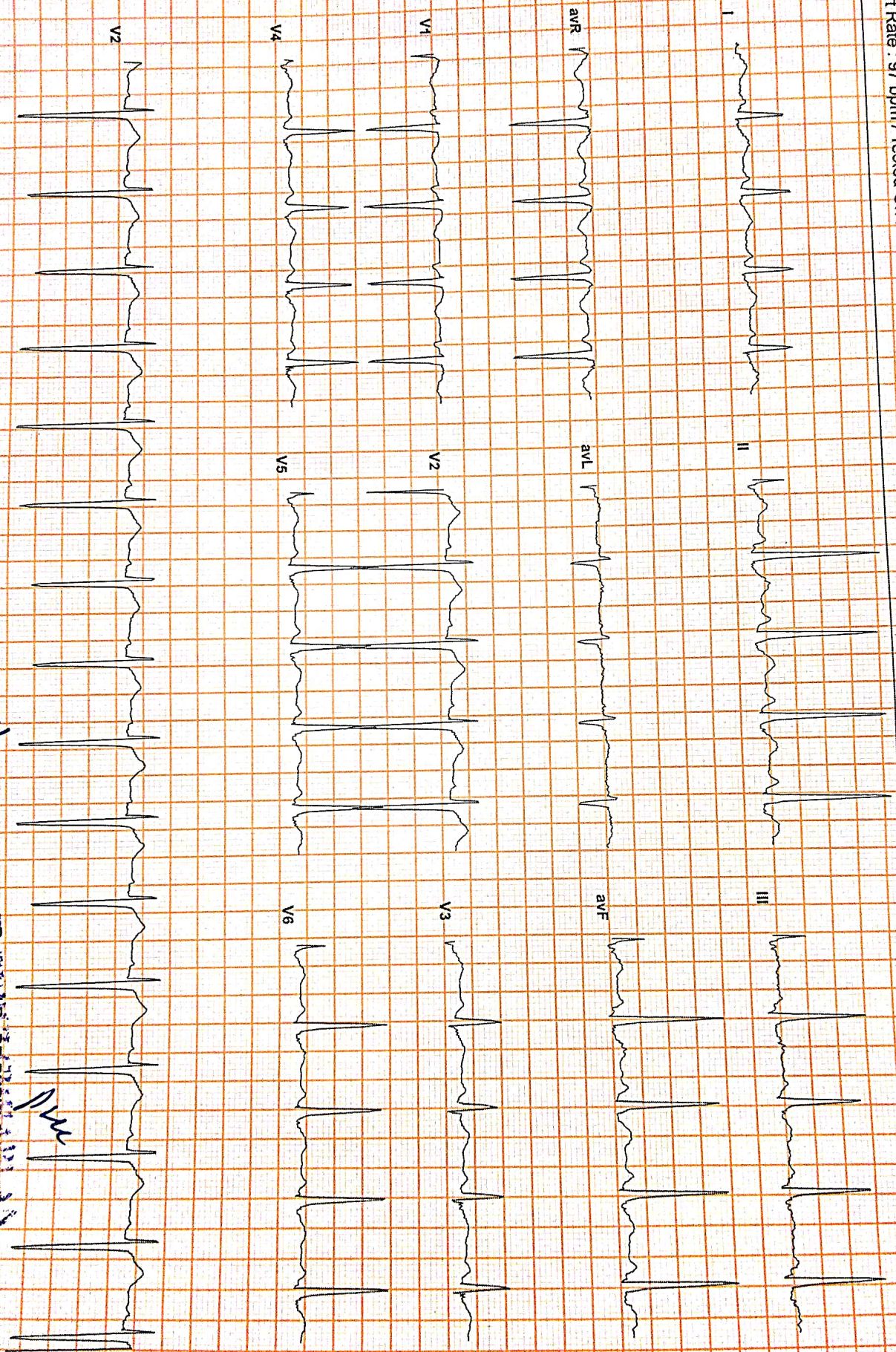
Address: C/O S/O Nagarjuna Babu
Nannapaneni, Plot No 7 Flat No 201
Rashmitha Enclave, Bhagyanagar Colony,
Near KPHB Metro Station, Kukatpally,
Kukatpally, Medchalmalkajgiri, Telangana,
500072



2853 5244 8207

1947 help@uidai.gov.in www.uidai.gov.in

DR PLUS HEALTHCARE CENTRE - MUMBAI CENTRAL
1550 / PRASANTH NANNAPANENI / 35 Yrs / M
Heart Rate : 97 bpm / Tested On : 13-Mar-22 11:17:59 / HF 0.05 Hz - LF 100 Hz / Notch 50 Hz / Sn 1.00 Cm/mV / Sw 25 mm/s



Allengers ECG (Piscos)(P/IS2.16200529)

TRM

M

DR. P. R. VICHABANI
MRCS (D), D. I. D. (D)
Consultant Physician And Interventional Cardiologist
REG No. 7799F



Dr-Plus Healthcare Centre

NATHANI HEIGHTS, B-Wing, Shop No. 42, Ground Floor, Opp. Mumbai Central Station (East), Mumbai - 400 008.

Patient's Name : PRASANTH NANNAPANENI

Referred By Dr. : SELF

Report Date : 13/03/2022

Age : 35 Years

Sex : MALE

Chest X-ray PA

- No active pulmonary lesion seen.
- Trachea and mediastinum are in midline .
- Cardiac size and configuration are within normal limits .
- Pleural cavities are clear .
- Domes of diaphragm are smooth in outline.
- Bony thorax is normal .


Radiologist

DR. A. J. MAZUMDAR

MD. DMRE, MDRD

"DR. PLUS HEALTHCARE CENTRE"
NATHANI HEIGHTS', B-WING,
42, MUMBAI CENTRAL (EAST)

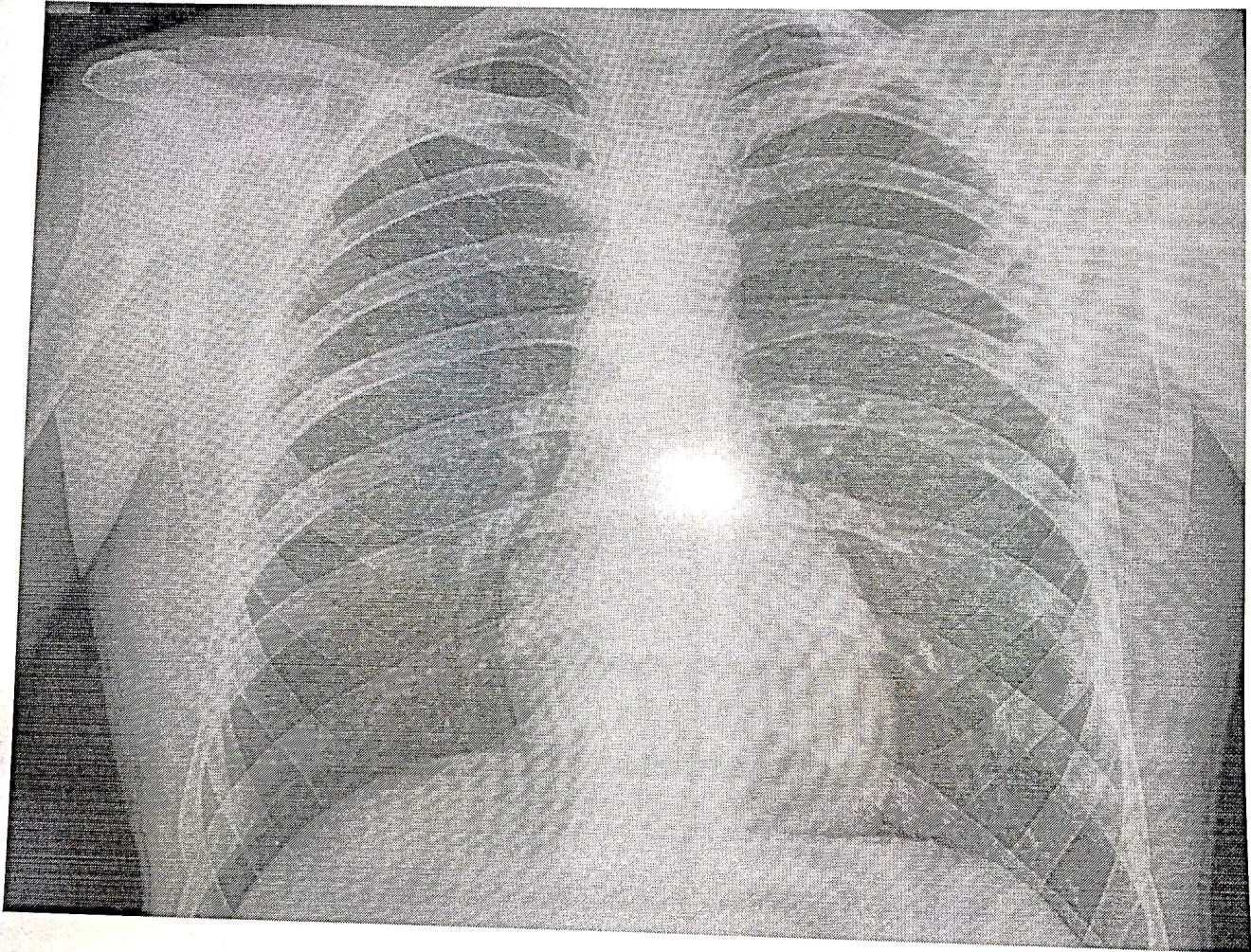
Patient's Name : PRASANTH NANNAPANENI

Report Date : 13/03/2022

Referred By Dr. : SELF

Age : 35 Years

Sex : MALE

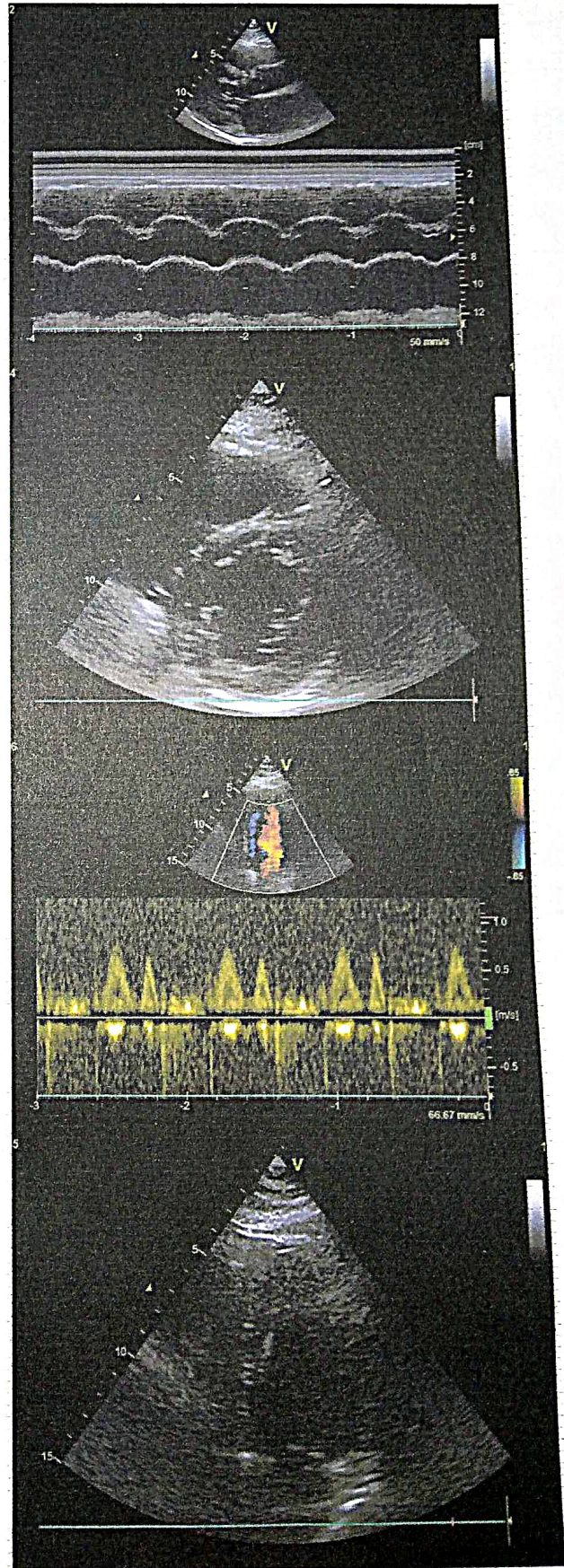
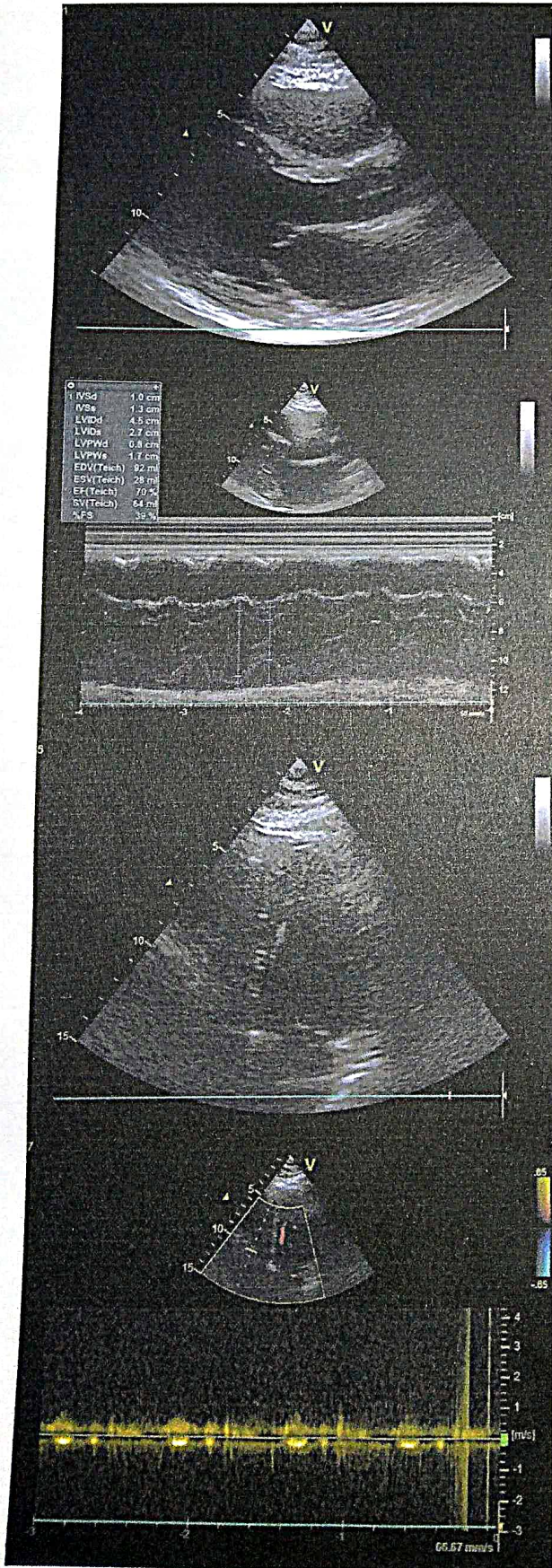


Name **PRASANTH NANNAPANENI**

Sex **Male**

Age **35**

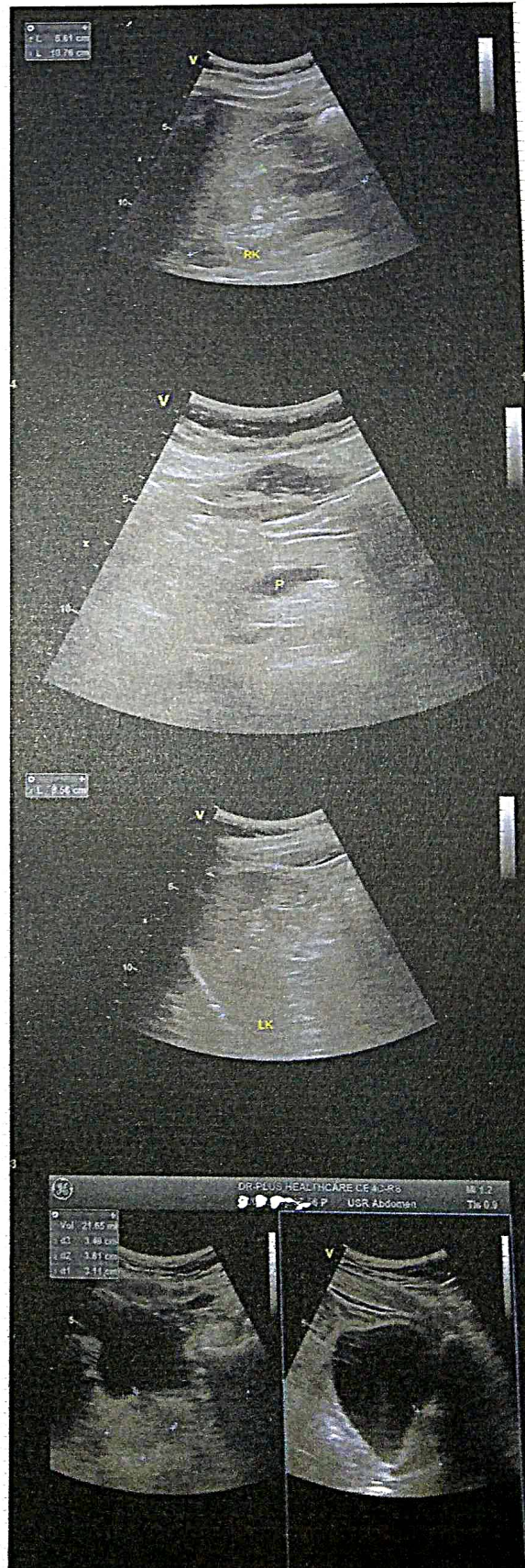
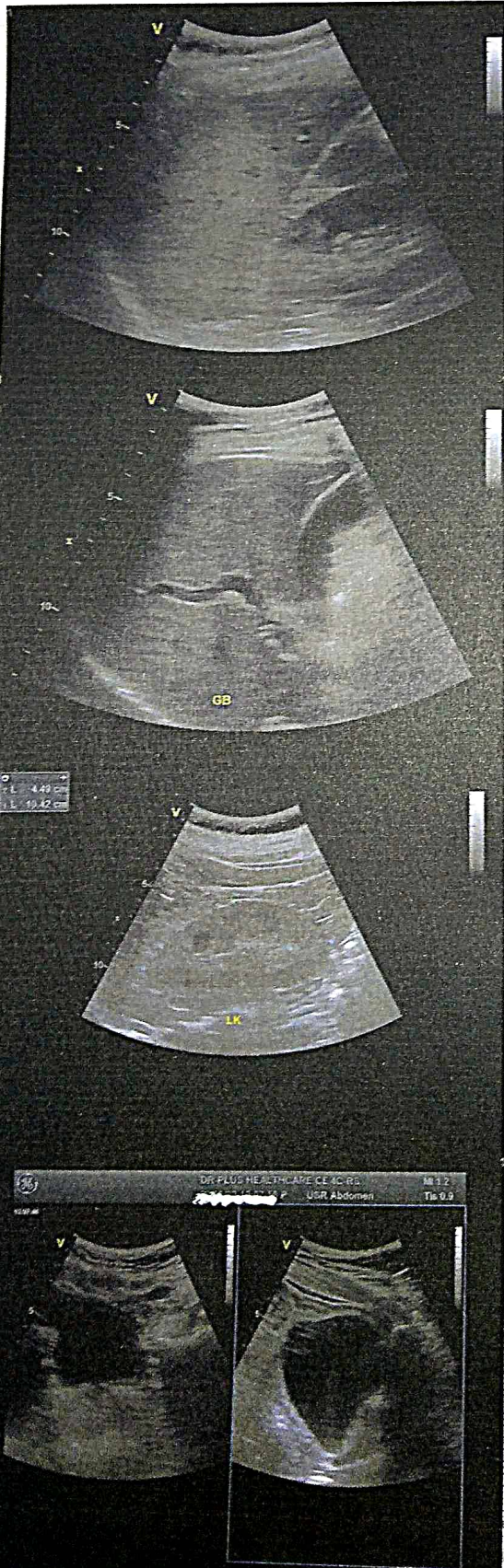Date **13/03/2022**



Name **PRASANTH NANNAPANENI**

Sex **Male**

Age **35**





NAME : PRASANTH NANNAPANENI

35/M

DATE:13/03/2022

REF BY : DR. HARI CHHABLANI

2D-ECHO. AND COLOR DOPPLER REPORT

- NORMAL CARDIAC VALVES WITH TRIVIAL TR.
- NORMAL CARDIAC CHAMBERS
- NO E/O REGIONAL WALL MOTION ABNORMALITY. WITH NORMAL LVEF OF 58 %.
- NO E/O PULMONARY HYPERTENSION .PASP 29 mmHg by TR jet.
- NO E/O LEFT VENTRICULAR HYPERTROPHY.
- NO E/O DIASTOLIC DYSFUNCTION.
- NO E/O PERICARDIAL EFFUSION.
- NO E/O INTRACARDIAC CLOT OR VEGETATION
- INTACT IAS / IVS

- CONVENTIONL DOPPLER :

E TO A RATIO IS MORE THAN ONE IN LV INFLOW.


THERE IS NO GRADIENT ACROSS AV, LVOT OR RVOT

PASP FROM TR JET IS 29 mm OF Hg.

- COLOUR DOPPLER:

TRIVIAL TR

EF Slope	116	mm/sec		
Opening Amplitude	21			
Posterior leaflet				
E.P.S.S	02	mm		
Mitral valve prolapse				
Vegetations				
TRICUSPID VALVE	OBSERVED	NORMAL VALUES		
PULMONARY VALVE	OBSERVED	NORMAL VALUES		
EF Slope				
'A' Wave				
Midsystolic notch				
Flutter				
Other Findings				
AORTIC VALVE	OBSERVED	NORMAL VALUES		
Cuspal opening	16	mm		
Closure line	Central			
Eccentricity index	1			
Other Findings				
DIMENSIONS	OBSERVED	NORMAL VALUES		
1. Lvd (Diastolic)	41	26-52		
2. Lvd (Systolic)	31	24-42mm		
3. RVD (Diastolic)	18	7-23mm		
4. IVST (Diastolic)	08	6-11mm		
5. IVST (Systolic)	15			
6. LVPWT (Diastolic)	09	6-11mm		
7. LVPWT (Systolic)	15			
8. Aortic root	31	22-37mm		
9. left Atrium	33	19-40mm		
	STRUCTURE	REGURG GRADING	VELOCITY m/sec	STENOSIS GRADIENT mm/Hg
			Max mean	Peak mean
MITRAL VALVE	NORMAL	0/3	/	/
TRICUSPID VELVE	NORMAL	TRIVIAL	/	/
PULMONARY VELVE	NORMAL	0/4	/	/
AORTIV VALVE	NORMAL	0/4	/	/


DR.P.H.CHHABLANI
 M.B.B.S, DNB.(MEDICINE)
 CONSULTANT PHYSICIAN AND CARDIOLOGIST.

DR. PURVI CHHABLANI
 M.B.B.S, DNB-(Medicine)
 Consultant Physician And Intensivist
 Reg No. 77696



Dr-Plus Healthcare Centre

NATHANI HEIGHTS, B-Wing, Shop No. 42, Ground Floor, Opp. Mumbai Central Station (East), Mumbai - 400 008.

Patient Name	:	PRASANTH NANNAPANENI	Sex:	MALE
Doctor's Name	:	DR. H. CHHABLANI	Age:	35 YEARS
Date	:	13/03/2022		

ULTRASONOGRAPHY OF THE ABDOMEN AND THE PELVIS:

The relevant sonographic findings include the following:

HEPATOBIILIARY APPARATUS

The liver is normal in size and echogenicity. No obvious focal parenchymal lesion is seen.

Extrahepatic biliary radicals are not dilated.

The portal vein and the common bile duct are normal.

GALL BLADDER

The gall bladder is adequately distended. The wall thickness is normal.

No echogenic contents are noted in its lumen. There is no pericholecystic collection noted.

PANCREAS

The pancreas shows normal echogenicity and size. No focal or diffuse lesions are noted.

No evidence of calcification is noted.

SPLEEN

The spleen appears normal in size and echogenicity. No focal or diffuse lesions are noted.

No evidence of calcification is noted.

KIDNEYS

Right Kidney measure: 11.4 x 4.4 cm, Left kidney measure: 10.8 x 4.5 cm

Both the kidneys appear normal in size, shape and echogenicity. Both the pelvicalyceal system is normal and both corticomedullary differentiations are well maintained. There is no obvious focal or diffuse lesion noted. No evidence of any calculus seen in either kidney.

PROSTATE

The Prostate appears normal and shows a normal echogenicity.


URINARY BLADDER

The urinary bladder shows anechoic contents. Its wall thickness appears normal.

No evidence of calcification is seen.

There is no obvious evidence of abdominal or pelvic lymphadenopathy or ascites noted.

IMPRESSION: No significant abnormality is detected.


DR. VICTOR X. COUTINNO
(MBBS, DMRE)
MMC REGD NO 847325

DR. PLUS HEALTHCARE CENTRE
NATHANI HEIGHTS', B-WING,
42, MUMBAI CENTRAL (EAST)



Dr-Plus Healthcare Centre

NATHANI HEIGHTS, B-Wing, Shop No. 42, Ground Floor, Opp. Mumbai Central Station (East), Mumbai - 400 008.

Full Name of life to be assured: **PRASANTH NANNAPANENI** 35/M DATE:13/03/2022

HAEMOGRAM

		Normal Range			
1.	Red Blood Cell Count	4.8	[M : 4.5 - 5.6 / F : 3.5 - 5.5/cu.mm]		
2.	Hb%	14.6	[M: 14-18 / F : 11-16%]		
3.	Hematocrit	45.8	[M : 40-53 / F : 30-47 %]		
4.	Indices:				
(a)	MCV(Mean Corpuscular Volume)	84.6	[79-101 cu.mi.]		
(b)	MCH(Mean Corpuscular Hb)	30.1	[27-32 pg]		
(c)	MCHC(Mean Corpuscular Hb Concentration)	34.5	[32-38%]		
5.	Morphology				
	Macrocytes :	--	Microcytes:	--	Hypochromia: --
	Piokilocytosis:	--	Anisocytosis:	--	
6.	Target cells:	--			
	Spherocytes:	--	Elliptocytes:	--	
7.	TOTALW.B.C.Count	6,500	{4000-11000/cu.mm}		
Differential Count					
a)	Neutrophils :	65	[45 -70%]	c)	Eosinophils: 05 [01 - 06%]
b)	Lymphocytes :	25	[20 - 45%]	d)	Monocytes: 04 [00 - 08%]
e)	Basophils :	01	[00 - 01%]		
8.	Platelets :2.68	1.5-4.5 Lacks/cu.mm			
9.	Erythrocyte Sedimentation Rate:15	20 mm at end of 1 hour		Method : Westergrens	

ROUTINE URINE EXAMINATION (RUA)

1. Physical Examination:

(i)	Colour:	PALE YELLOW	(ii)	Sediment:	CLEAR
(iii)	Transparency:	ABSENT	(iv)	Reaction:	ACIDIC
(v)	Specific gravity	1.020			

2. Chemical Examination:

(i)	Protein :	ABSENT	(ii)	Sugar:	ABSENT
(iii)	Bile salt:	ABSENT	(iv)	Bile pigment:	ABSENT

3. Microscopic Examination:

(i)	Red Blood Cells:	ABSENT	(ii)	Epithelial Cells:	ABSENT
(iii)	Crystals:	ABSENT	(iv)	Pus Cells:	01 TO 02/HPF
(v)	Casts:	ABSENT	(vi)	Deposits:	ABSENT
(vii)	Bacteria's :	ABSENT			

DR. RAKESH PATKAR
M.D. (P.M.B. (Pathology))
Reg. No. 2013/05/1660



Dr-Plus Healthcare Centre

NATHANI HEIGHTS, B-Wing, Shop No. 42, Ground Floor, Opp. Mumbai Central Station (East), Mumbai - 400 008.

Full Name

PRASANTH NANNAPANENI

35/M

13/03/2022

Life to be assured:

	Type of Test	Actual Reading	Normal Range
1	Fasting Blood Sugar	85.0	70-100 mg%
2	PPBS	115	110 TO 140 mg%
3	Total Cholesterol	166.0	120-200 mg%
4	VERY LOW DENSINTY LEVEL(VLDL)	14.0	10-30 mg/dl
5	High Density Lipid (HDL)	51.	40-60 mg%
6	Low Density Lipid (LDL)	101	Upto 150
7	S. Triglycerides	115.9	50-150 mg%
8	CHOL/HDL	3.2	Upto 5
9	HDL/LDL	0.4	
10	S. Creatinine	0.95	0.5-1.2 mg%
11	Blood Urea Nitrogen (BUN)	17.8	7-21 mg%
12	BUN/CREAT RATIO	19.7	
13	S. Proteins	6.6	6.0-7.9 mg%
14	(a) Albumin	3.6	3.5-5.5 mg%
15	(b) Globulin	3.0	2.0-3.5 mg%
16	A/G RATIO	1.2	
17	S. Bilirubin	0.9	0.3-1.3mg%
18	(a) Direct	0.6	0.0-0.8 mg%
19	(b) Indirect	0.3	0.0-0.5 mg%
20	SGOT (AST)	26.5	05-34 IU
21	SGPT (ALT)	30.5	05-40 IU
22	GGTP (GGT)	35.9	05-50 IU
23	SGOT/SGPT	0.8	
24	HBA1C	5.4	UPTO 6.5
25	S. Alkaline Phosphatase	95.6	30-115 IU
26	T3	150.1	80-180ng/dl
27	T4	5.65	4.6-12 ug/dl
28	TSH	3.5	0.4-4.0 mIU/L
29	SERUM URIC ACID	5.6	2.5-7.2mg/dl
30	URINE SUGAR PP	ABSENT	
31	URINE SUGAR FASTING	ABSENT	
32	BLOOD GROUP	"A POSITIVE "	

DR. RAKESH PATKAR
M.D., D.M.B. (Pathology)
Reg. No. 2013/95/1660



Dr. Hari Chhablani

Cardiometabolic Physician & Intensivist
M.B.B.S., F.C.C.P. (RESP. MED.), PGDHMM,
PGDMLS, FELLOW INTENSIVE CARE MED.

ATTACHED TO : Wockhardt Hospital • Saifee Hospital • Apollo Spectra Hospital

NATHANI HEIGHTS, B-Wing, Shop No. 42, Ground Floor, Opp. Mumbai Central Station (East),
Mumbai - 400 008. • Cell : 98206 46163 • E : drharichhablani@gmail.com

PHYSICIAN REPORT

DATE : 13/03/2022

NAME : PRASANTH NANNAPANENI 35/M

PRESENTING COMPLAINS: LOW BACK PAIN RADIATING TO RIGHT LEG SINCE 2 YEARS ON ACCUPUNCTURE .

MRI SHOWS L4-L5 DISC BULGE.

PAST HISTORY: H/O COVID JAN- 2022 .

FAMILY HISTORY: NOT SIGNIFICANT

TREATMENT : ACCUPUNCTURE FOR LOW BACK PAIN

HABITS: NIL

HT.- 183 CM. WT.- 118 Kg. BMI.-35

P: 96/MIN ., REGULAR BP: 120/84

EYE EXAMINATION : NEAR VISION -B/E - N18 , DISTANT VISION -B/E 6/12

COLOR VISION : NORMAL

RS: CLEAR

CVS: S1,S2 REGULAR

PA: SOFT

CNS: CLINICALLY NAD

LABS: ATTACHED

USG - WNL

2D-ECHO : WNL

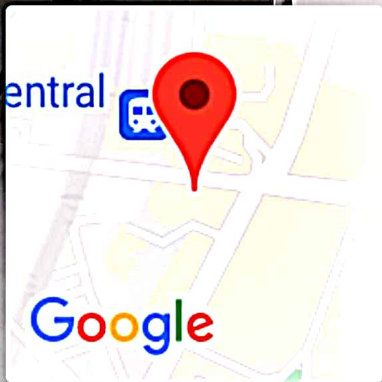
ECG: WNL

X-RAY - WNL

IMPRESSION : : FIT ON CLINICAL MEDICAL EXAMINATION .

DR.HARI CHHABLANI

DR. HARI CHHABLANI
M.B.B.S.F.C.C.P.(RESP.MEDICINE) PGDHMM, PGDMLS
FELLOW INTENSIVE CARE
MMC REG. NO. - 91702



Mumbai, Maharashtra, India
D/1, Belasis Rd, Marzban Parsi Colony, Dalal Estate,
Kamathipura, Mumbai, Maharashtra 400008, India
Lat 18.968696°
Long 72.819945°
13/03/22 09:21 AM

