

3548 7061 9716


श्रीधर -सामान्य माणसाचा अधिकार

श्री

श्रीमती शशी

CONSTITUTION OF INDIA

श्रीमती शशी पाटील  
Kavita Ashok Patil  
जन्म तारीख / DOB 23/10/1979  
लिंग / GENDER FEMALE



श्री कविता अशोक पाटील



NAME : MRS. KAVITA PATIL

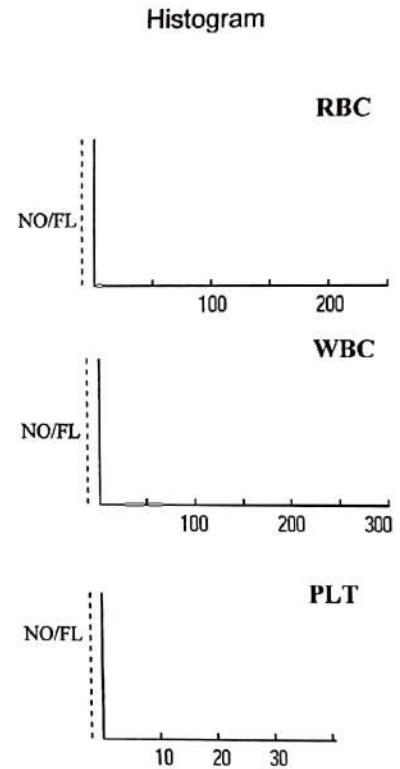
DATE : 14/09/2024 PT.NO. : 203 14092

REF BY : Dr. MEDIWHEEL LIFE INS

AGE : 45. Yrs. SEX : F

### HAEMOGRAM WITH INDICES

Test	Result	Units	Normal Range
<b>Haemoglobin</b>	- 8.5	g/dl	12-16
RBC Count	- 4.14	millions / cu-mm	4.5 - 6.5
PCV	- 32.0	%	40 - 54
MCV	- 77.3	fL	80 - 96
MCH	- 20.5	Pg	27 - 33
MCHC	- 26.6	gm/dl	33 - 36
RDW CV	- 17.7	%	11.0 - 14.5
<b>WBC Count</b>	- 4200	/cumm	4000 - 11000
Neutrophils	- 62	%	55 - 75
Lymphocytes	- 33	%	20 - 50
Eosinophils	- 03	%	1 - 6
Monocytes	- 02	%	2-10
Basophils	- 00	%	0 - 1
<b>Platelet Count</b>	- 241000	/ul	150000 - 450000
MPV	- 9.3	fL	7.4 - 10.4
PDW	- 11.3	%	8-12
P-LCR	- 21.0	%	15-35
<b>E.S.R.</b>	- 16	mm at 1hr	0-15



(By Wintrobe Method)

RBC Morphology - Hypochromic +, Microcytic +, Anisocytosis +.

WBC Morphology - Within Normal Limits

Platelets - Adequate

\* Blood group - 'A' Rh Positive

Vandana G. Powar  
M.B.B.S., D.C.P.  
Reg. No. 68137  
PATHOLOGIST  
DR. VANDANA POWAR  
M.B.B.S., D.C.P.

All Biochemistry Tests Done By Computerised Auto Analyser

HAEMATOLOGY | CLINICAL PATHOLOGY | BIOCHEMISTRY | SEROLOGY | MICROBIOLOGY | HISTOPATHOLOGY

24 Hours Emergency Service

Home Service Available







PT.NAME : MRS. KAVITA PATIL  
REF. BY : DR. MEDIWHEEL LIFE INS

DATE : 14/09/2024  
AGE : 45 Yrs. SEX : F  
PT.NO. : 203 140924

BIOCHEMISTRY TEST REPORT

			<u>Normal Range</u>
Fasting Plasma Glucose	: 86.1	mg/dl	60-110 mg/dl
Fasting Urine Glucose	: Absent		Absent
2 Hrs. Plasma Glucose	: 106.5	mg/dl	90-140 mg/dl
2 Hrs. Urine Glucose	: Absent		Absent
S. Creatinine	: 1.01	mg/dl	0.6 - 1.4 mg/dl
Blood Urea	: 25.9	mg/dl	12-42 mg/dl
Blood Urea Nitrogen	: 12.1	mg/dl	5 - 21 mg/dl
S. Uric acid	: 4.1	mg/dl	2.6 -6.0 mg/dl
CHOLESTEROL	: 122.5	mg/dl	0-250 mg/dl
HDL Cholesterol	: 26.3	mg/dl	30 - 70 mg/dl
S. Triglycerides	: 107.2	mg/dl	0 - 190 mg/dl
LDL Cholesterol	: 74.8	mg/dl	60 - 150 mg/dl
TC/HDLC Ratio	: 4.7		
LDLC/HDLC Ratio	: 2.8		

Dr. Vandana G. Powar<sup>0-5</sup>  
M.B.B.S., D.C.P.  
2.Reg.No. 68137



**PATHOLOGIST**

*[Signature]*  
DR. VANDANA POWAR  
M.B.B.S., D.C.P.

All Biochemistry Tests Done By Computerised Auto Analyser

HAEMATOLOGY | CLINICAL PATHOLOGY | BIOCHEMISTRY | SEROLOGY | MICROBIOLOGY | HISTOPATHOLOGY

24 Hours Emergency Service

Home Service Available



Dr. Vandana G. Powar M.B.B.S., D.C.P.  
Consultant Pathologist



**PARTH**  
PATHOLOGY LABORATORY  
(Computerised)

AB - Shop No. 7, "Diwan Towers" Mangalwar Peth, Near Mirajkar Tikti, Opp. Nutan Marathi  
High School, Kolhapur. Mob. 9158529408, 9422047480, 9921285167

PT.NAME : MRS. KAVITA PATIL  
REF. BY : DR. MEDIWHEEL LIFE INS

DATE : 14/09/2024  
AGE : 45 Yrs. SEX : F  
PT.NO. : 203 140924

### BIOCHEMISTRY TEST REPORT

			<u>Normal Range</u>
S. Bilirubin (Total)	: 0.32	mg/dl	0 - 1.0 mg/dl
S. Bilirubin (Direct)	: 0.21	mg/dl	0 - 0.25 mg/dl
S. Bilirubin (Indirect)	: 0.11	mg/dl	0 - 0.75 mg/dl
S.G.O.T	: 27.6	IU/L	0 - 42 IU/L
S.G.P.T	: 17.5	IU/L	0 - 42 IU/L
S. Alkaline Phosphatase	: 79.6	IU/L	64-306 IU/L
Total Proteins	: 6.8	g/dl	6.6 - 8.3 g/dl
S. Albumin	: 4.1	g/dl	3.5 - 5.0 g/dl
S. Globulin	: 2.7	g/dl	1.5 - 3 g/dl
A/G Ratio	: 1.5 : 1		0.90 - 2.00

Dr. Vandana G. Powar  
M.B.B.S., D.C.P.  
Reg. No. 68137



**PATHOLOGIST**

*[Signature]*  
DR. VANDANA POWAR  
M.B.B.S., D.C.P.

All Biochemistry Tests Done By Computerised Auto Analyser

HAEMATOLOGY • CLINICAL PATHOLOGY • BIOCHEMISTRY • SEROLOGY • MICROBIOLOGY • HISTOPATHOLOGY

24 Hours Emergency Service

Home Service Available



Scanned with OKEN Scanner

Dr. Vandana G. Powar M.B.B.S., D.C.P.  
Consultant Pathologist



**PARTH**  
PATHOLOGY LABORATORY  
(Computerised)

AB - Shop No. 7, "Diwan Towers" Mangalwar Peth, Near Mirajkar Tikti, Opp. Nutan Marathi  
High School, Kolhapur. Mob. 9158529408, 9422047480, 9921285167

PT.NAME : MRS. KAVITA PATIL  
REF. BY : DR. MEDIWHEEL LIFE INS

DATE : 14/09/2024  
AGE : 45 Yrs. SEX : F  
PT.NO. : 203 140924

**REPORT ON % GLYCOHAEMOGLOBIN OF BLOOD**

% Glycohaemoglobin of blood : 4.6 %

Estimated mean blood glucose : 85.0 mg/dl

(Reference For Guideline)

- < 6.0 - Normal
- 6.0 - 7.0 % - Good Control
- 7.0 - 8.0 % - Fair Control
- 8.0-10.0% - Unsatisfactory control
- >10.0% - Poor control

Dr. Vandana G. Powar  
M.B.B.S., D.C.P.  
Reg. No. 68137



**PATHOLOGIST**

DR. VANDANA POWAR  
M.B.B.S., D.C.P.

All Biochemistry Tests Done By Computerised Auto Analyser

HAEMATOLOGY • CLINICAL PATHOLOGY • BIOCHEMISTRY • SEROLOGY • MICROBIOLOGY • HISTOPATHOLOGY

**24 Hours Emergency Service**

**Home Service Available**



Scanned with OKEN Scanner



Dr. Vandana G. Powar M.B.B.S., D.C.P.  
Consultant Pathologist



**PARTH**  
PATHOLOGY LABORATORY  
(Computerised)

AB - Shop No. 7, "Diwan Towers" Mangalwar Peth, Near Mirajkar Tikti, Opp. Nutan Marathi High School, Kolhapur. Mob. 9158529408, 9422047480, 9921285167

PT.NAME : MRS. KAVITA PATIL  
REF. BY : DR. MEDIWHEEL LIFE INS

DATE : 14/09/2024  
AGE : 45 Yrs. SEX : F  
PT.NO. : 203 140924

**EXAMINATION OF URINE**

Normal Range

**PHYSICAL EXAMINATION**

Quantity : 05 ml  
Colour : Pale Yellow  
Appearance : Clear  
Deposit : Absent  
Reaction (pH) : Acidic  
Specific Gravity : 1.024

**CHEMICAL EXAMINATION**

Proteins : Absent  
Glucose : Absent  
Ketone Bodies : --  
Bile Salts : -- Absent  
Bile Pigments : -- Absent  
Urobilinogen : --  
Occult Blood : Absent

**MICROSCOPIC EXAMINATION**

Epithelial Cells : 1 - 2 /hpf  
Pus Cells : 2 - 3 /hpf  
Red Blood Cells : Absent /hpf  
Casts : Absent  
Crystals : Absent  
Amorphous Deposits : Absent

**OTHER FINDINGS**

Yeast Cells : Absent  
Trichomonas vaginalis : Absent  
Bacteria : Absent  
Mucus Threads : Absent  
Spermatozoa : Absent



Dr. Vandana G. Powar  
M.B.B.S., D.C.P.  
Reg. No. 68137

**PATHOLOGIST**

*[Signature]*  
DR. VANDANA POWAR  
M.B.B.S., D.C.P.

All Biochemistry Tests Done By Computerised Auto Analyser

HAEMATOLOGY | CLINICAL PATHOLOGY | BIOCHEMISTRY | SEROLOGY | MICROBIOLOGY | HISTOPATHOLOGY

**24 Hours Emergency Service**

**Home Service Available**



Scanned with OKEN Scanner

Dr. Vandana G. Powar M.B.B.S., D.C.P.  
Consultant Pathologist



**PARTH**  
PATHOLOGY LABORATORY  
(Computerised)

LAB - Shop No. 7, "Diwan Towers" Mangalwar Peth, Near Mirajkar Tikti, Opp. Nutan Marathi High School, Kolhapur. Mob. 9158529408, 9422047480, 9921285167

PATIENT NAME :- KAVITA PATIL

AGE - 45 /SEX-FEMALE

REFERANCE :- MEDIWHEEL LIFE INS.

DATE - 14/09/2024

BIOCHEMISTRY

NORMAL VALUE

SRUM VLDL - 27.0mmol/L

10-50 mmol / L

Dr. Vandana G. Powar  
M.B.B.S., D.C.P.  
Reg. No. 68137



**PATHOLOGIST**

*Vandana*  
DR. VANDANA POWAR  
M.B.B.S., D.C.P.

All Biochemistry Tests Done By Computerised Auto Analyser

HAEMATOLOGY | CLINICAL PATHOLOGY | BIOCHEMISTRY | SEROLOGY | MICROBIOLOGY | HISTOPATHOLOGY

24 Hours Emergency Service

Home Service Available



Scanned with OKEN Scanner

Dr. Vandana G. Powar M.B.B.S., D.C.P.  
Consultant Pathologist



**PARTH**  
PATHOLOGY LABORATORY  
(Computerised)

Shop No. 7, "Diwan Towers" Mangalwar Peth, Near Mirajkar Tikti, Opp. Nutan Marathi  
High School, Kolhapur. Mob. 9158529408, 9422047480, 9921285167

PATIENT NAME:- KAVITA PATIL

AGE - 45 /SEX -FEMALE

REFERANCE :- MEDIWHEEL LIFE INS.

DATE - 14/09/2024

**BIOCHEMISTRY**

S. GAMMA G.T : 21.5 mmol/L

NORMAL RENG

10 -50 mmol/L



Dr. Vandana G. Powar  
M.B.B.S., D.C.P.  
Reg. No. 68137

**PATHOLOGIST**

*[Signature]*  
DR. VANDANA POWAR  
M.B.B.S., D.C.P.

All Biochemistry Tests Done By Computerised Auto Analyser

HAEMATOLOGY | CLINICAL PATHOLOGY | BIOCHEMISTRY | SEROLOGY | MICROBIOLOGY | HISTOPATHOLOGY

**24 Hours Emergency Service**

**Home Service Available**



Scanned with OKEN Scanner



Patient Name : MRS. KAVITA PATIL  
Referred By : Dr. VANDANA POWAR  
Clinically - FOR HEALTH CHECK UP.

Date : 14 Sep 2024  
Age : 45 YEARS Sex : F

### Abdomen Sonography

**GASSY ABDOMEN PREVENTS OPTIMAL VISUALISATION OF ABDOMINAL ORGANS.**

**LIVER** : is normal in size, shape, position and shows normal echogenicity. The contours are smooth. The parenchyma shows homogeneous echotexture. The intra – hepatic portal and venous system appears normal. The portal vein is normal and show hepatopetal flow. The intra-hepatic biliary radicals are not dilated. There is no focal mass lesion.

**GALL BLADDER**: is physiologically distended, normal in size and echotexture. There is no evidence of echoreflexive calculus in gall bladder. There is no abnormal biliary tree dilation noted. The portal vein & C.B.D appear normal. Wall thickness is normal. No e/o cholecystitis/calculus seen. PV measures -11 mm, CBD measures – 3 mm.

**PANCREAS**: is normal size, position & echotexture. The contours are smooth. There is no focal mass lesion seen. No pancreatitis or calcification.

**SPLEEN**: is normal in size, shape and echopattern. The contours are smooth. The splenic vein and portal vein are normal in calibre.

**KIDNEYS**: Both the kidneys are normal in size, shape and position and contours. There is no echoreflexive obstructing calculus seen on either sides nor hydronephrosis. Both visualized ureters appear to be normal. Parenchymal/cortical thickness is normal. Cortico -medullary differentiation is well maintained. Overlying bowel gases does not show further course of ureter. **Right kidney** measures- 96 x 45 mm, **Left kidney** measures -96 x 61 mm.

**Urinary bladder** is partially distended, appears normal. No intraluminal abnormality.

**Uterus** – is retro-verted, measures 66 x 40 x 50 mm, appears normal. The endometrium measures 6.5 mm. Ovaries are not visualized.

Aorta and IVC are normal. No e/o free fluid in peritoneal cavity. No ascites. No significant lymphadenopathy. **Bowel loops appear normal in size with good peristalsis.**

**Appendix** is not appreciated in today's study. Terminal ileum is well seen. No probe tenderness in right iliac fossa or anywhere in abdomen.

**IMPRESSION** : < NO SIGNIFICANT ABNORMALITY SEEN.

ADVICE - Clinical correlation and follow up with preparation & full bladder if needed.  
THANKS FOR REFERRAL. FEEDBACK IS WELCOME



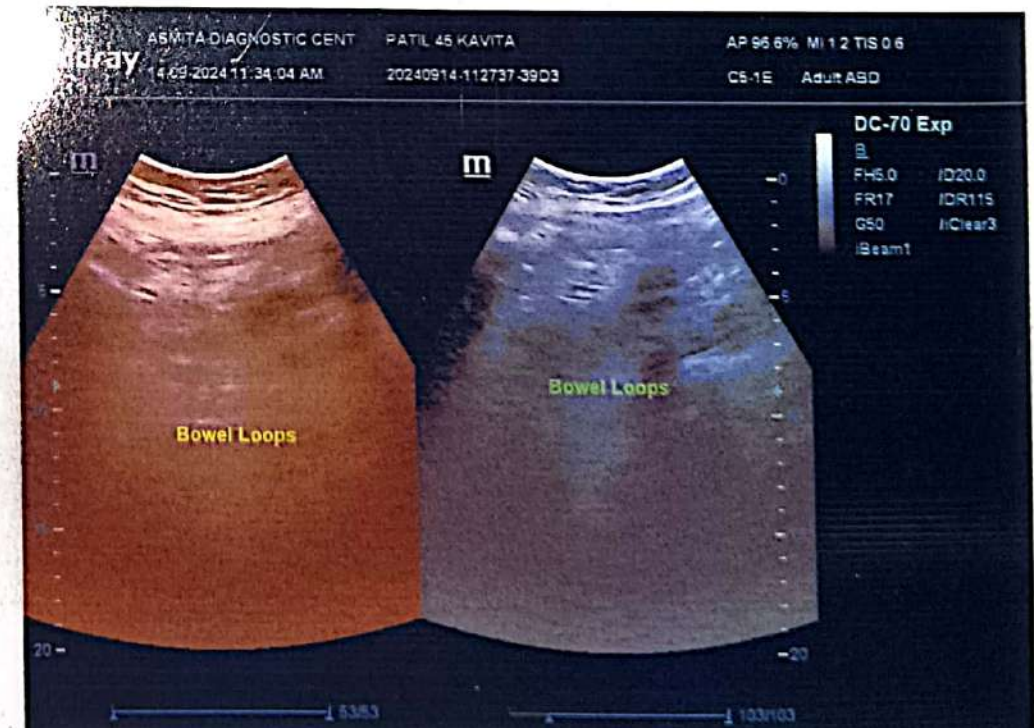
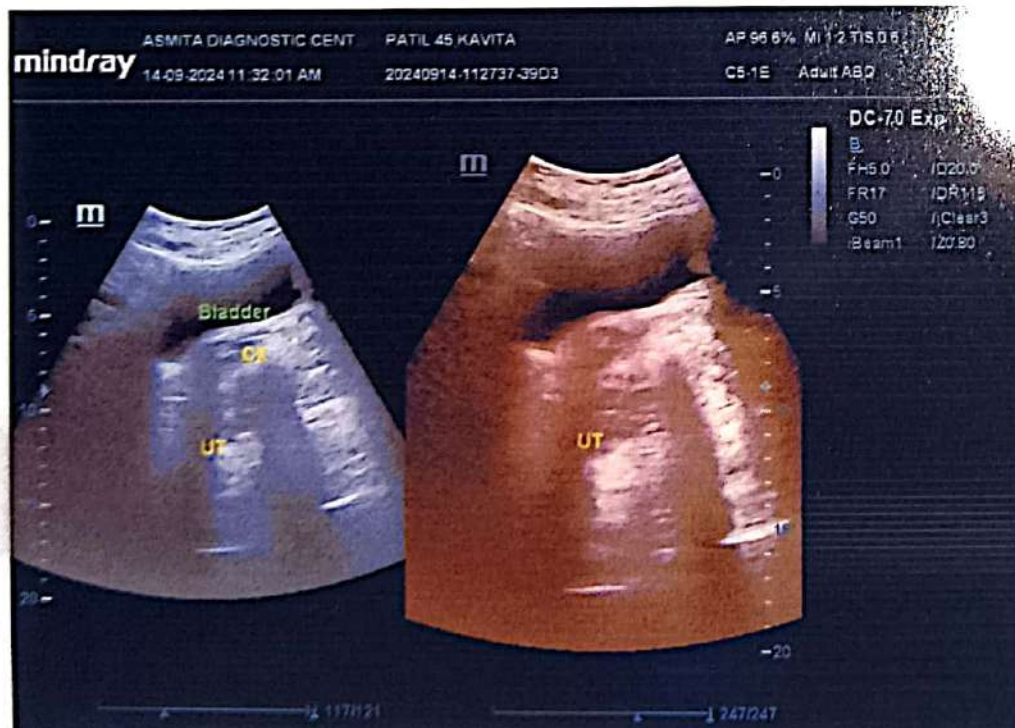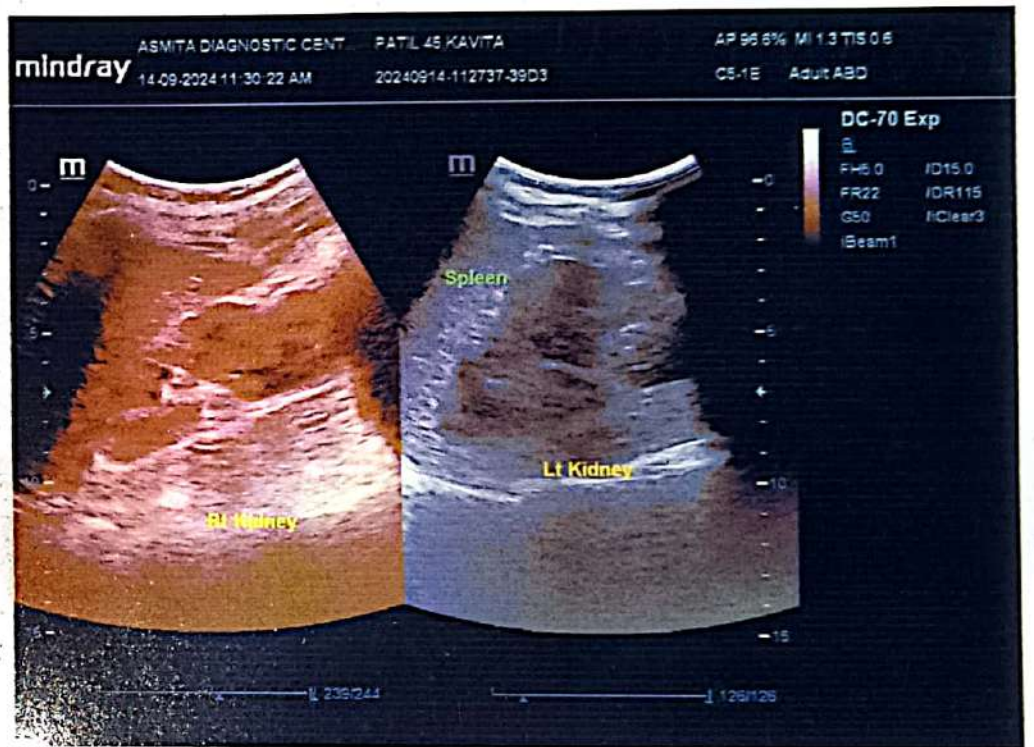
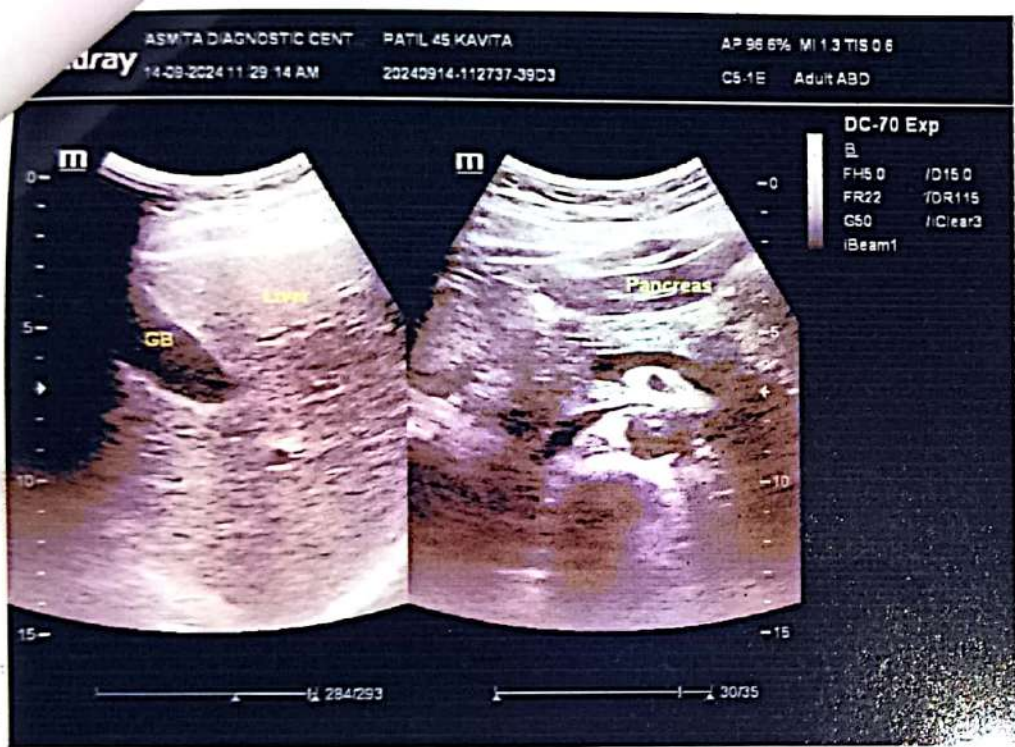**DR. NEHA S. GHORPADE**  
MBBS DMRE Reg. No. 79916  
Consulting Radiologist

**डॉ. नेहा घोरपडे**

एम. बी. बी. एस., डी.एम.आर.ई (रेडीओलॉजिस्ट)  
रजि.नं.79916

परत येताना सर्व जुने रिपोर्ट्स, सोनोग्राफी रिपोर्ट्स अथवा एक्स-रे असल्यास बरोबर घेऊन येणे.









Kolhapur, Maharashtra, India

1095/1B/1, Mangalwar Peth, C Ward, Kolhapur, Maharashtra 416012, India

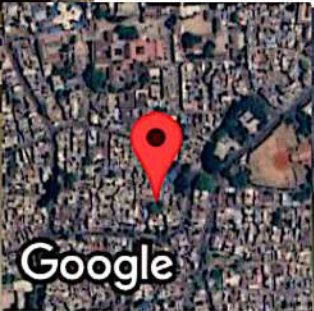
Lat 16.692816°

Long 74.22428°

14/09/24 09:15 AM GMT +05:30



GPS Map Camera



Google



Scanned with OKEN Scanner





# SWARA DIGITAL

## X- RAY

All Types Of Digital, Portable X-rays And Procedural X-rays

---

PATEINT NAME : MRS KAVITA PATIL      AGE/SEX : 45Y/FEMALE  
REF BY : PARTH LAB      DATE : 14/09/2024

---

### CHEST X-RAY PA

Both lungs fields are normal

Both costophrenic angles appear normal

The tracheal lucency is centrally placed

The mediastinal & diaphragmatic outlines appear normal.

The heart shadow is normal

IMPRESSION :      **NORMAL CHEST X-RAY**

ADV: Clinical correlated

**DR SAKSHAM GUPTA**  
MBBS,MD Radio diagnosis FMF UK  
Consultant Radiologist

**Mob. 9890185675**

Address : Bramhanand, Near Tawanappa Patne High School, Rajarampuri 10 Galli, Kolhapur.

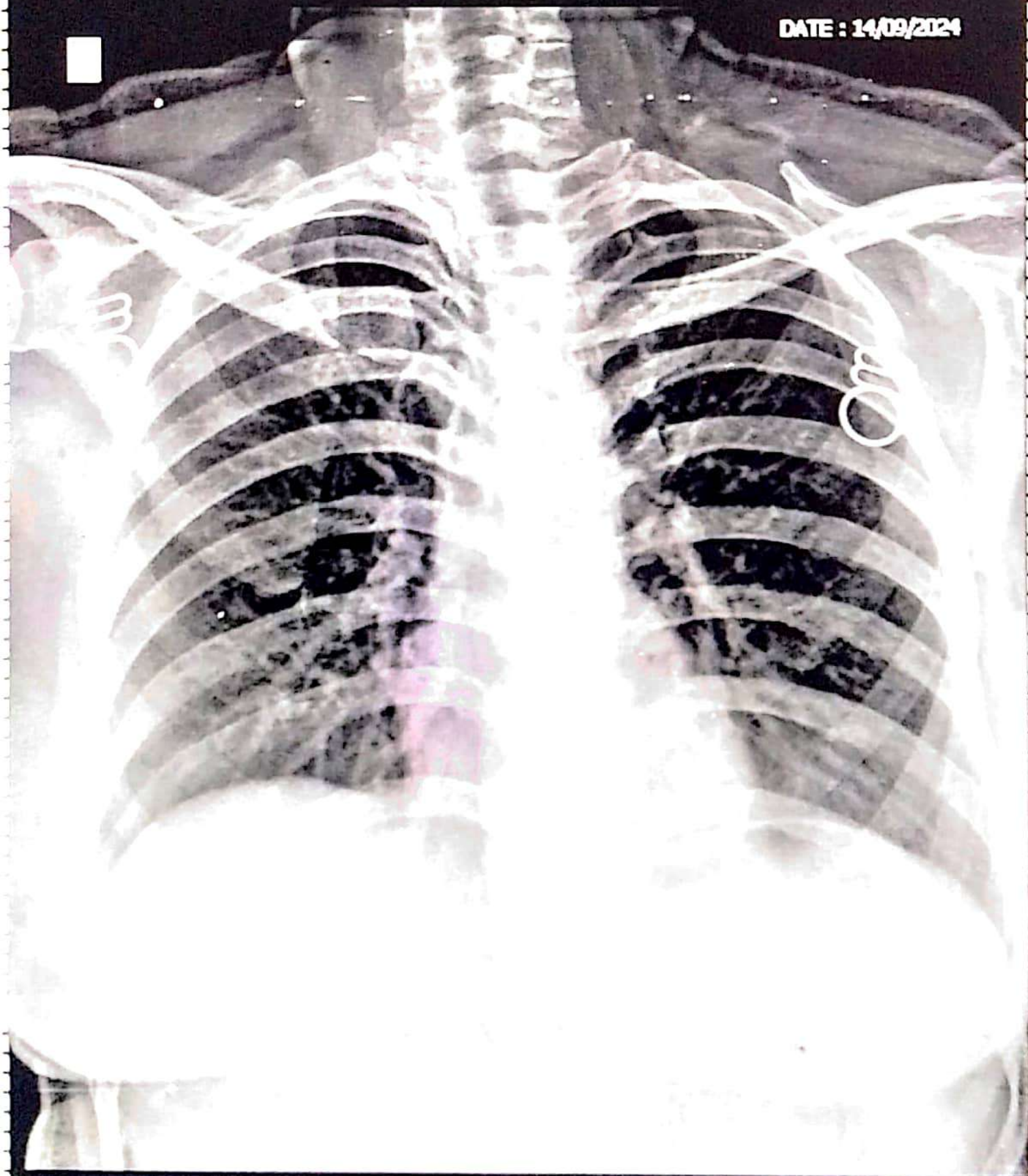
Scanned with ACE Scanner



Scanned with OKEN Scanner



DATE : 14/09/2024



Name: MRS KAMTAPATIL

Age/Sex: 45 / Female

Ref. Dr. PARTH LAB

Chest PA

SWARA DIGITAL X-RAY RAJARAMPURI 12TH LANE KOLHAPUR



Scanned with OKEN Scanner