

ECHO REPORT

Name of the patient: MRS. NISHA Age: 34 Sex: Male FemaleUHID No: 30290 ^{Bilino} IPD No: 24093570 Date: 8/3/24Refer By Doctor: DR. RAKESH ADORALVEF% 60.1

2D ECHO

> Mitral Value Normal Pulmonary Value N Pulm
 > Artery N
 > Aortic avive N Tricuspid valve N

2D RWMA

> N RWMA (Regional wall motion abnormality) at rest

COLD DOPPLER

> N Significant Vavular stenosis / Regurgiation

COMMENTS AND SUMMARY

> All cardiac chambers of N size and shape NO dilatation or hypertrophy.

> NO RWMA (Regional wall motion abnormality) at rest

> NO Cloth / Vegetation/ pericardial effusion

> LV 60.1 Systolic function

> NO Significant Vavular stenosis / Regurgiation

Final Impression

> EF at Rest 60.1

COMMENTS 2DECHO & Color Doppler study WNL

Consultant Cardiology

Doctor Name : Dr.

Date :

Rakesh
 Dr. Rakesh Kumar Adora
 MBBS, MD (Cardiology)
 Signature :
 Time :
 Park Hospital, Faridabad



DEPARTMENT OF PATHOLOGY

Patient Name : Mrs. NISHA

MR No : 30290

Age/Sex : 34 Years 6 Months 1 Days / Female

Type : OPD

TPA/Corporate : MEDIWHEEL

Bill Date : 08/03/2024

Reporting Date : 08/03/2024

Sample ID : 71047

Bill/Req. No. : 24093570

Ref Doctor : Dr. CONSULTANT

Test	Result	Bio. Ref. Interval	Units
HB A1C GLYCOSYLATED HAEMOGLOBIN			
HBA1C	5.3		%

• Note : Non-Diabetics 4.0 - 6.0 %

In Diabetics

Good Control 6.1 - 6.8 %

Fair Control 6.9 - 7.6 %

Poor Control > 7.6 %

***** END OF THE REPORT *****

OUT SOURCE
PARK HOSPITAL
GGN



Sample no.

Dr. VAISHALI YADAV
CONS. PATHOLOGIST

Dr. REETU JADHAV
CONS. PATHOLOGIST

Dr. PARDIP KUMAR
MICROBIOLOGIST & ICO

S.C. GAUR

LAB INCHARGE USER NM SEHDEV

(This is only professional opinion and not the diagnosis, Please correlate clinically)

J-Block, Sector-10, Near Court, Faridabad - 121004, Haryana

Tel.: 0129-4200000 E-mail : parkfaridabad@gmail.com



DEPARTMENT OF PATHOLOGY

Patient Name : Mrs. NISHA	Bill Date : 08/03/2024
MR No : 30290	Reporting Date : 08/03/2024
Age/Sex : 34 Years 6 Months 1 Days / Female	Sample ID : 71047
Type : OPD	Bill/Req. No. : 24093570
TPA/Corporate : MEDIWHEEL	Ref Doctor : Dr.CONSULTANT

Test	Result	Bio. Ref. Interval	Units
BLOOD SUGAR 2 HR. PP			
BLOOD SUGAR P.P.	85.09	80 - 150	mg/dl

***** END OF THE REPORT *****



Sample no.

Dr. VAISHALI YADAV Dr. REETU JADHAV Dr. PARDIP KUMAR S.C. GAUR
CONS. PATHOLOGIST CONS. PATHOLOGIST MICROBIOLOGIST & ICO LAB INCHARGE USER NM PRIYANKA

(This is only professional opinion and not the diagnosis, Please correlate clinically)

J-Block, Sector-10, Near Court, Faridabad - 121004, Haryana

Tel.: 0129-4200000 E-mail: parkfaridabad@gmail.com



DEPARTMENT OF PATHOLOGY

Patient Name : Mrs. NISHA
MR No : 30290
Age/Sex : 34 Years 6 Months 1 Days / Female
Type : OPD
TPA/Corporate : MEDIWHEEL
Bill Date : 08/03/2024
Reporting Date : 08/03/2024
Sample ID : 71047
Bill/Req. No. : 24093570
Ref Doctor : Dr.CONULTANT

Test	Result	Bio. Ref. Interval	Units
LFT (LIVER FUNCTION TEST)			
LFT			
TOTAL BILIRUBIN	0.7	0 - 1.2	mg/dL
DIRECT BILIRUBIN	0.3	0 - 0.4	mg/dL
INDIRECT BILIRUBIN	0.4	0.10 - 0.6	mg/dL
SGOT (AST)	23	0 - 45	U/L
SGPT (ALT)	12	0 - 45	U/L
ALKALINE PHOSPHATASE	89.2	30 - 170	IU/L
TOTAL PROTEIN	7.1	6.4 - 8.0	g/dL
ALBUMIN	4.0	3.3 - 5.5	g/dL
GLOBULIN	3.1	2.3 - 4.5	g/dL
A/G RATIO	1.29	1.1 - 2.2	

***** END OF THE REPORT *****



Sample no.

Dr. VAISHALI YADAV Dr. REETU JADHAV Dr. PARDIP KUMAR S.C. GAUR
CONS.PATHOLOGIST CONS.PATHOLOGIST MICROBIOLOGIST & ICO LAB INCHARGE USER NM PRIYANKA

(This is only professional opinion and not the diagnosis, Please correlate clinically)

J-Block, Sector-10, Near Court, Faridabad - 121004, Haryana

Tel.: 0129-4200000 E-mail : parkfaridabad@gmail.com



DEPARTMENT OF PATHOLOGY

Patient Name : Mrs. NISHA
 MR No : 30290
 Age/Sex : 34 Years 6 Months 1 Days / Female
 Type : OPD
 TPA/Corporate : MEDIWHEEL

Bill Date : 08/03/2024
 Reporting Date : 08/03/2024
 Sample ID : 71047
 Bill/Req. No. : 24093570
 Ref Doctor : Dr. CONSULTANT

Test	Result	Bio. Ref. Interval	Units
KFT (RENAL PROFILE)			
KFT			
SERUM UREA	20	10 - 45	mg/dL
SERUM CREATININE	0.6	0.4 - 1.4	mg/dL
SERUM URIC ACID	2.99	2.5 - 7.0	mg/dL
SERUM SODIUM	135 L L	136 - 148	mmol/L
SERUM POTASSIUM	3.5	3.5 - 5.5	mmol/L
CHLORIDE	92.0 L L	96 - 106	mmol/L

***** END OF THE REPORT *****



Sample no.

Dr. VAISHALI YADAV Dr. REETU JADHAV Dr. PARDIP KUMAR S.C. GAUR *Low*
 CONS. PATHOLOGIST CONS. PATHOLOGIST MICROBIOLOGIST & ICO LAB INCHARGE USER NM PRIYANKA

(This is only professional opinion and not the diagnosis, Please correlate clinically)

J-Block, Sector-10, Near Court, Faridabad - 121004, Haryana

Tel.: 0129-4200000 E-mail : parkfaridabad@gmail.com



DEPARTMENT OF PATHOLOGY

Patient Name :	Mrs. NISHA	Bill Date :	08/03/2024
MR No :	30290	Reporting Date :	08/03/2024
Age/Sex :	34 Years 6 Months 1 Days / Female	Sample ID :	71047
Type :	OPD	Bill/Req. No. :	24093570
TPA/Corporate :	MEDIWHEEL	Ref Doctor :	Dr.CONSULTANT

Test	Result	Bio. Ref. Interval	Units
BLOOD SUGAR FASTING			
PLASMA GLUCOSE FASTING	74.00	60 - 110	mg/dl

***** END OF THE REPORT *****



Sample no.

Dr. VAISHALI YADAV Dr. REETU JADHAV Dr. PARDIP KUMAR S.C. GAUR
 CONS. PATHOLOGIST CONS. PATHOLOGIST MICROBIOLOGIST & ICO LAB INCHARGE USER NM PRIYANKA

(This is only professional opinion and not the diagnosis, Please correlate clinically)

J-Block, Sector-10, Near Court, Faridabad - 121004, Haryana

Tel.: 0129-4200000 E-mail : parkfaridabad@gmail.com



DEPARTMENT OF PATHOLOGY

Patient Name : Mrs. NISHA
 MR No : 30290
 Age/Sex : 34 Years 6 Months 1 Days / Female
 Type : OPD
 TPA/Corporate : MEDIWHEEL

Bill Date : 08/03/2024
 Reporting Date : 08/03/2024
 Sample ID : 71047
 Bill/Req. No. : 24093570
 Ref Doctor : Dr. CONSULTANT

Test	Result	Bio. Ref. Interval	Units
LIPID PROFILE			
LIPID PROFILE			
TOTAL CHOLESTEROL	142.06	120.0 - 200.0	mg/dL
SERUM TRIGLYCERIDES	93.47	40.0 - 160.0	mg/dl
HDL-CHOLESTEROL	65.25	30 - 70	mg/dl
VLDL CHOLESTEROL	18.69	6 - 32	mg/dL
LDL	58.12	50 - 135	mg/dl
LDL CHOLESTEROL/HDL RATIO	0.89 L L	1.0 - 3.0	mg/dL
TOTAL CHOLESTEROL/HDL RATIO	2.18	2.0 - 5.0	mg/dl

***** END OF THE REPORT *****



Sample no.

Dr. VAISHALI YADAV Dr. REETU JADHAV Dr. PARDIP KUMAR S.C. GAUR
 CONS. PATHOLOGIST CONS. PATHOLOGIST MICROBIOLOGIST & ICO LAB INCHARGE USER NM PRIYANKA

(This is only professional opinion and not the diagnosis, Please correlate clinically)

J-Block, Sector-10, Near Court, Faridabad - 121004, Haryana
 Tel.: 0129-4200000 E-mail : parkfaridabad@gmail.com



DEPARTMENT OF PATHOLOGY

Patient Name : Mrs. NISHA
 MR No : 30290
 Age/Sex : 34 Years 6 Months 1 Days / Female
 Type : OPD
 TPA/Corporate : MEDIWHEEL

Bill Date : 08/03/2024
 Reporting Date : 09/03/2024
 Sample ID : 71047
 Bill/Req. No. : 24093570
 Ref Doctor : Dr. CONSULTANT

Test	Result	Bio. Ref. Interval	Units
THYROID PROFILE			
TRI-iodothyronine (T3)	1.43	0.60 - 1.81	ng/ml
THYROXINE (T4)	10.2	5.01 - 12.45	µg/dL
THYROID STIMULATING HORMONE	5.54 H	0.5-5.50	µIU/ml

***** END OF THE REPORT *****

OUT SOURCE
 PARK HOSPITAL
 GGN



Sample no.

Dr. VAISHALI YADAV
 CONS.PATHOLOGIST

Dr. REETU JADHAV
 CONS.PATHOLOGIST

Dr. PARDIP KUMAR
 MICROBIOLOGIST & ICO

S.C. GAUR
 LAB INCHARGE USER NM SUNIL

(This is only professional opinion and not the diagnosis, Please correlate clinically)

J-Block, Sector-10, Near Court, Faridabad - 121004, Haryana

Tel.: 0129-4200000 E-mail : parkfaridabad@gmail.com



DEPARTMENT OF PATHOLOGY

Patient Name : Mrs. NISHA
MR No : 30290
Age/Sex : 34 Years 6 Months 1 Days / Female
Type : OPD
TPA/Corporate : MEDIWHEEL

Bill Date : 08/03/2024
Reporting Date : 08/03/2024
Sample ID : 71047
Bill/Req. No. : 24093570
Ref Doctor : Dr.CONULTANT

Test	Result	Bio. Ref. Interval	Units
CBC			
HAEMOGLOBIN	14.0	12 - 15	gm/dL
PACKED CELL VOLUME	44.6	35.0 - 50.0	%
RED BLOOD CELL COUNT	4.70	3.5 - 5.5	millions/ μ L
MEAN CORPUSCULAR VOLUME	94.9	83 - 101	fL
MEAN CORPUSCULAR HAEMOGLOBIN	29.8	27 - 31	pg
MEAN CORPUSCULAR HB CONC	31.4 L	33 - 37	g/dl
RDW	12.3	11.6 - 14.5	%
TOTAL LEUCOCYTE COUNT	4090	4000-11000	/ μ L
DIFFERENTIAL COUNT			
NEUTROPHILS	50	40.0 - 80.0	%
LYMPHOCYTES	40	20 - 40	%
MONOCYTES	06	2.0 - 10.0	%
EOSINOPHILS	04	0.0 - 5.0	%
BASOPHILS	00	0.0 - 2.0	%
PLATELET COUNT	1.44 L	1.50 - 4.50	lac/cumm

***** END OF THE REPORT *****



Sample no.

Dr. VAISHALI YADAV Dr. REETU JADHAV Dr. PARDIP KUMAR S.C. GAUR
CONS. PATHOLOGIST CONS. PATHOLOGIST MICROBIOLOGIST & ICO LAB INCHARGE USER NM PRIYANKA

(This is only professional opinion and not the diagnosis, Please correlate clinically)



DEPARTMENT OF PATHOLOGY

Patient Name	: Mrs. NISHA	Bill Date	: 08/03/2024
MR No	: 30290	Reporting Date	: 08/03/2024
Age/Sex	: 34 Years 6 Months 1 Days / Female	Sample ID	: 71047
Type	: OPD	Bill/Req. No.	: 24093570
TPA/Corporate	: MEDIWHEEL	Ref Doctor	: Dr.CONULTANT

Test	Result	Bio. Ref. Interval	Units
------	--------	--------------------	-------

BLOOD GROUPING AND rh FACTOR

BLOOD GROUP	" B " Rh NEGATIVE
-------------	-------------------

***** END OF THE REPORT *****



Sample no.

Dr. VAISHALI YADAV Dr.REETU JADHAV Dr. PARDIP KUMAR S.C.GAUR
CONS.PATHOLOGIST CONS.PATHOLOGIST MICROBIOLOGIST & ICO LAB INCHARGE USER NM PRIYANKA

(This is only professional opinion and not the diagnosis, Please correlate clinically)

J-Block, Sector-10, Near Court, Faridabad - 121004, Haryana
Tel.: 0129-4200000 E-mail : parkfaridabad@gmail.com



DEPARTMENT OF RADIOLOGY

Patient Name	Mrs. NISHA	Billed Date	: 08/03/2024	9.23 AM
Reg No	30290	Reported Date	: 08/03/2024	
Age/Sex	34 Years 6 Months 1Days / Female	Req. No.	: 24093570	
Type	OPD	Consultant Doctor	: Dr. CONSULTANT	

USG WHOLE ABDOMEN

LIVER : The liver is normal in size, shape and echotexture. No evidence of any focal lesion. IHBR is not dilated.

GALL BLADDER : The gall bladder is well distended. No evidence any calculus or mass seen. GB wall thickness with in normal limits. No evidence of pericholecystic fluid is seen. The common bile duct is normal.

SPLEEN :The spleen is normal in size and shape. Its echotexture is homogeneous. No evidence of focal lesion is noted.

PANCREAS :The pancreas is normal in size, shape, contours and echotexture.

BILATERAL KIDNEYS : The bilateral kidneys are normal in size and echotexture. Cortico-medullary differentiation is maintained. There is no evidence of obvious calculus or hydronephrosis seen.

URINARY BLADDER :The urinary bladder is well distended. Wall thickness within normal limits. No evidence of calculus is seen. No evidence of mass or diverticulum is noted.


UTERUS: The uterus is normal in size, shape and echopattern. Endometrium echo is normal in thickness. No adnexal mass lesion seen.

No free fluid is seen in peritoneal cavity.

No evidence of obvious retroperitoneal or mesenteric lymphadenopathy is seen.

IMPRESSION: USG WHOLE ABDOMEN REVEALS NO OBVIOUS ABNORMALITY.

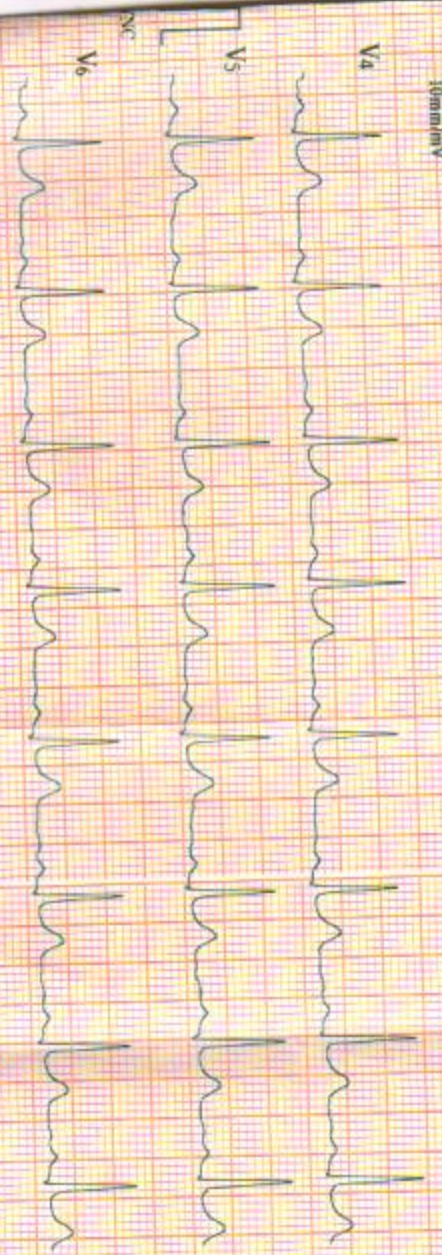
TO BE CORRELATED CLINICALLY.


DR. BINOD KR CHAUDHARY
MBBS, MD
CONSULTANT RADIOLOGIST

(This is only professional opinion and not the diagnosis, Please correlate clinically)

J-Block, Sector-10, Near Court, Faridabad - 121004, Haryana

Tel : 0129-4200000 E-mail : parkfaridabad@gmail.com



ID : 4271

Name: *Maha Shetty*

Sex: *Female*

Age :

HR : 78
 RR : 764
 PR : 177
 QT/QTc : 336/384
 P/QRS/T : 74/76/55
 HV5/SVL : 1-110/0-530 mV
 RV5-SVL : 1-640 mV

----- Sinus Rhythm
 ----- F Abnormal ECG (Flat T)
 ----- Marked Counter-clockwise Rotation

Interfirmed report Verified by:

ECG-1200 42,000x6100xV2,000x AMP



DEPARTMENT OF RADIOLOGY

Patient Name	Mrs. NISHA	Billed Date	: 08/03/2024	9.23 AM
Reg No	30290	Reported Date	: 08/03/2024	
Age/Sex	34 Years 6 Months 1Days / Female	Req. No.	: 24093570	
Type	OPD	Consultant Doctor	: Dr. CONSULTANT	

X-RAY CHEST AP/PA

Bilateral lungs appears normal.

Both hila are normal in size, have equal density and bear normal relationship.

The heart and trachea are central in position and no mediastinal abnormality is visible.

The cardiac size is normal for patient age and view.

The domes of the diaphragms are normal in position and show smooth outline.

To be correlated clinically

DR BINOD KR CHAUDHARY
MBBS, MD
CONSULTANT RADIOLOGIST

(This is only professional opinion and not the diagnosis, Please correlate clinically)

J-Block, Sector-10, Near Court, Faridabad - 121004, Haryana

Tel.: 0129-4200000 E-mail : parkfaridabad@gmail.com