



भारतीय विशिष्ट पहचान प्राधिकरण

Unique Identification Authority of India

Address:

D/O: Kaushal Kumar Kailash,
Jain Mandir Road, Infront Of Budhia
Hospital, Pasi Tola, Nath Nagar, Bhagalpur
Bhagalpur,
Bihar- 812006

पता

आत्मजा: कौशल कुमार कैलाश
जैन मंदिर रोड, बुधिया अस्पताल के
सामने, पासी टोला, नाथ नगर,
भागलपुर,
बिहार - 812006

4372 4823 4584



19-17



help@uidai.gov.in

www

www.uidai.gov.in



GPS Map Camera

Varanasi, Uttar Pradesh, India

44-B3, Durgakund, Bhelupur, Varanasi, Uttar Pradesh 221001,
India

Lat 25.289295°

Long 82.993281°

08/07/23 10:14 AM GMT +05:30



Google



भारत सरकार
Government of India



राखी सरोज
Rakhi Saroj
जन्म तिथि/DOB: 03/04/2000
महिला/Female



4372 4823 4584

मेरा आधार, मेरी पहचान



GPS Map Camera

Varanasi, Uttar Pradesh, India

44-B3, Durgakund, Bhelupur, Varanasi, Uttar Pradesh 221001,
India

Lat 25.289295°

Long 82.993281°

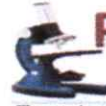08/07/23 10:14 AM GMT +05:30



Google

Facilities:
 All clinical Biomedical & Hematology Investigations
 including Bone Marrow Examination
 VPT, Podiascan & Complete Foot Care (First Time in Purvanchal)
 All Hormonal Investigation by Chemiluminescent Method
 Visceral Fat by (AB-140) Ambulatory BP Monitoring
 CGMS & Insulin Pump Available
 PFT, 2D-ECHO (Color Doppler), Holter, TMT, Cardiac-3 available
 VIA, VILI, Colposcopy available
 Special Endocrinological Investigation Protocols.

ISO 9001:2008 Certified
 Mobile: 9389994334, 9554572190, 9453837595



Panacea Pathology

Clinical Reference Lab

Persistence, Preparedness and Precision
 EQAS (CMC Vellore Attached) & IQAS System
 पूर्वांचल की सर्वोत्तम गुणवत्ता वाली पैथोलॉजी

PATIENT NAME : RAKHI SAROJ	AGE/GENDER : 33 YRS/FEMALE
REFD BY DR. : ARCO FEMI HEALTHCARE LTD.	RECEIVED DATE : 08-07-2023 (09:00AM)
SAMPLE : BLOOD & URINE	REPORT DATE : 08-07-2023 (07:00PM)

PATHOLOGY REPORT

COMPLETE BLOOD COUNT (CBC)

TEST	LAB TEST VALUES	NORMAL RANGE
HEMOGRAM		
HEMOGLOBIN (FLOW CYTOMETRY)	11.1	13 – 16 gm/dl
TOTAL LEUCOCYTE COUNT (TLC)	5,300	4000 – 11000
RBC COUNT	3.78	3.5 – 5.5
PCV (HCT)	35.1	37 – 47
MCV	92.2	80 – 95
MCH	29.4	28 – 34
MCHC	31.6	30 – 36
PLATELET COUNT	1,82,000	1,50,000 – 4,00,000
E.S.R. (WINTROBE FIRST HOURS)	12.0	20 mm/1 st hr
DIFFERENTIAL LEUCOCYTE		
NEUTROPHILS	62	40 – 75%
LYMPHOCYTES	34	20 – 45%
EOSINOPHILS	02	1 – 6%
MONOCYTES	02	2 – 8%
BASOPHILS	00	< 2%

RANDOM/FASTING BLOOD SUGAR

TEST	LAB TEST VALUES	NORMAL RANGE
RBS/FBS		
FASTING BLOOD SUGAR	91.8	70-125 mg/dl
RANDOM BLOOD SUGAR	110.0	125-140 mg/dl

GLYCOSYLATED HEMOGLOBIN (HBA1C)

TEST	LAB TEST VALUES	NORMAL RANGE
HBA1C	5.2	Normal : <5.97 % Good Control : 5.97 – 6.81% Fair Control : 6.81 – 7.65% Poor Control : >7.65%

PAGE 1

Lab Technician

PANACEA HOSPITAL
 (A UNIT OF AAROHA HEALTHCARE PVT. LTD.)
 M.D. Pathology
 REG NO. AL-7500

Timing : 8.00 a.m. to 9.00 p.m. (Sunday 8.00 a.m. to 3.00 p.m.)

This Report is not valid for medico legal purpose

Note: These tests have technical limitations. Clinico-pathological interpretation is necessary. In case of any disparity test

Facilities:
 All clinical Biomedical & Hematology Investigations including Bone Marrow Examination
 VPT, Podiascan & Complete Foot Care (First Time in Purvanchal)
 All Hormonal Investigation by Chemiluminescent Method
 Visceral Fat by (AB-140) Ambulatory BP Monitoring
 CGMS & Insulin Pump Available
 PFT, 2D-ECHO (Color Doppler), Holter, TMT, Cardiac-3 available
 VIA, VILI, Colposcopy available
 Special Endocrinological Investigation Protocols.

Mobile: 9389994334, 9554572190, 9453837595



Panacea Pathology

Clinical Reference Lab

Persistence, Preparedness and Precision
 EQAS (CMC Vellore Attached) & IQAS System
 पूर्वांचल की सर्वोत्तम गुणवत्ता वाली पैथोलॉजी

PATIENT NAME : RAKHI SAROJ
 REFD BY DR. : ARCO FEMI HEALTHCARE LTD.
 SAMPLE : BLOOD & URINE
 AGE/GENDER : 33 YRS/FEMALE
 RECEIVED DATE : 08-07-2023 (09:00AM)
 REPORT DATE : 08-07-2023 (07:00PM)

PATHOLOGY REPORT

LIPID PROFILE, SERUM

TEST	LAB TEST VALUES	NORMAL RANGE
BLOOD CHEMISTRY		
TOTAL CHOLESTEROL (SERUM)	165.0	Desirable:- < 200 mg/dl Borderline:- 200 – 239 mg/dl High:- > 240 mg/dl
TRIGLYCERIDES (SERUM)	163.0	35 – 170 mg/dl
HDL CHOLESTEROL (SERUM)	43.0	35.30 – 79.50 mg/dl
LDL CHOLESTEROL (SERUM)	89.4	< 130 mg/dl
VLDL	32.6	< 40 mg/dl
CHOLESTROL/HDL RATIO	3.83	< 3.0 Low Risk Ratio 3.0 – 5.0 Avg Risk > 5.0 High Risk
LDL/HDL RATIO	2.07	< 3 Ratio

BLOOD GROUP

TEST	LAB TEST VALUES
BLOOD GROUP ABO & RH FACTOR	
BLOOD GROUP	"O"
RH FACTOR	POSITIVE

LIVER PROFILE TEST, SERUM

TEST	LAB TEST VALUES	NORMAL RANGE
BIO CHEMISTRY		
TOTAL BILIRUBIN	0.64	0.0 – 1.1 mg/dl
DIRECT BILIRUBIN	0.20	0.0 – 0.2 mg/dl
INDIRECT BILIRUBIN	0.44	< 0.90 mg/dl
SGOT (AST)	18.0	0 – 52 mg/dl
SGPT (ALT)	24.0	0 – 39 mg/dl
GGT (GYT)	21.0	< 55 U/L

THYROID PROFILE (T3, T4, TSH)

TEST	LAB TEST VALUES	NORMAL RANGE
THYROID FUNCTION TEST		
T3	0.02	0.60 – 1.81 ng/ml
T4	7.92	4.50 – 10.90 ug/dl
TSH	4.69	0.39 – 6.10 uIU/mL

PAGE 2

Lab Technician

Timing : 8.00 a.m. to 9.00 p.m. (Sunday 8.00 a.m. to 3.00 p.m.)

This Report is not valid for medico legal purpose

Note: These tests have technical limitations. Clinico-pathological interpretation is necessary in case of any disparity test

PANACEA HOSPITAL & HEALTHCARE PVT. LTD.
 (A UNIT OF ARCO FEMI HEALTHCARE PVT. LTD.)
 REG NO. AL-1500
 B-36/44, B-4, KASIR NAGAR,
 DURGAKUNDI, VARANASI-221005

Facilities:

All clinical Biomedical & Hematology Investigations including Bone Marrow Examination VPT, Podiascan & Complete Foot Care (First Time in Purvanchal) All Hormonal Investigation by Chemiluminescent Method Visceral Fat by (AB-140) Ambulatory BP Monitoring CGMS & Insulin Pump Available PFT, 2D-ECHO (Color Doppler), Holter, TMT, Cardiac-3 available VIA, VILI, Colposcopy available Special Endocrinological Investigation Protocols.

ISO 9001:2008 Certified
Mobile: 9389994334, 9554572190, 9453837595



Panacea Pathology

Clinical Reference Lab

Persistence, Preparedness and Precision
EQAS (CMC Vellore Attached) & IQAS System
पूर्वांचल की सर्वोत्तम गुणवत्ता वाली पैथोलॉजी

PATIENT NAME : RAKHI SAROJ

AGE/GENDER : 33 YRS/FEMALE

REFD BY DR. : ARCO FEMI HEALTHCARE LTD.

RECEIVED DATE : 08-07-2023 (09:00AM)

SAMPLE : BLOOD & URINE

REPORT DATE : 08-07-2023 (07:00PM)

PATHOLOGY REPORT

RENAL & KIDNEY PROFILE, SERUM

TEST	LAB TEST VALUES	NORMAL RANGE
RENAL FUNCTION TESTS		
BLOOD UREA NITROGEN (BUN)	9.2	10 – 50 mg/dl
SERUM CREATININE	0.68	0.60 – 1.60 mg/dl
URIC ACID	4.10	3.60 – 7.70 mg/dl
ALKALINE PHOSPHATASE (ALP)	68.0	142 – 353 mg/dl
TOTAL PROTIENS	7.30	0 – 39 mg/dl
ALBUMIN	4.10	3.8 – 5.4 mg/dl
SERUM GLOBULIN	3.20	2.1 – 3.5 mg/dl
AG RATIO	1.28	-

URINE ROUTINE EXAMINATION

TEST	LAB TEST VALUES	NORMAL RANGE
PHYSICAL EXAMINATION		
QUANTITY	30	ML
COLOUR	STRAW	PALE YELLOW
APPEARANCE	CLEAR	CLEAR
SPECIFIC GRAVITY	1.010	1.01 – 1.03
PH	6.0	4.7 – 7.5
CHEMICAL EXAMINATION		
GLUCOSE	Not Detected	Not Detected
PROTEIN	NIL	Not Detected
MICROSCOPIC EXAMINATION		
PUS CELLS	01-02	0-5
RBC	Not Detected	Not Detected
EPITHELIAL CELLS	01-02	0-5
CASTS	Not Detected	Not Detected
CRYSTALS	Not Detected	Not Detected
BACTERIA	Not Detected	Not Detected

----- End of Report -----

Lab Technician

PANACEA HOSPITAL
M.D., Pathology
(A UNIT OF AAROHA HEALTHCARE PVT. LTD.)

Timing : 8.00 a.m. to 9.00 p.m. (Sunday 8.00 a.m. to 3.00 p.m.)

This Report is not valid for medico legal purpose

Note: These tests have technical limitations. Clinico-pathological interpretation is necessary. In case of any disparity test

REG NO. 11-1500
B-36/44, B-4, KABIR NAGAR,
DURGAKUND, VARANASI - 221005



PANACEA HOSPITAL

B 36/44 F.K KABIR NAGAR, DURGAKUND
TOLLFREE NO-18001233070.
Whatsapp No - 8795832852
www.piire.org



Oxve

OP Slip

Print Date : 08-Jul-2023 10:24AM



UHID No :- UD-23240001415	OP No :- OP-23240004938	OP Date :- 08 Jul 2023 10:21AM
Patient Name :- Mrs Rakhi saroj	Age/Sex :- 23 Y/Female	Mobile No :- 9534281732
Husband :- Kumr saurav	Department :- OBST. & GYNAECOLOGY	
Pay Type :- Cash	Consultant :- Dr VANDANA SINGH (MBBS,MS)	
Token No :- NOR. - 2	Paid/Bal :- 0.00 /30.00	
Patient Type :- Normal		
Address :- khoja bazar,munger,BIHAR		

BP :- 90/60
height :-
Weight (kg) :- 59.1
BMI :-

Rx

elo → ml.

SpO2 - 100
PR - 94

LMP - 22/6/23.
Poto.
married - 2 yrs.

Ins Pap smear.

No gynae. complaints

Vandana Singh

Printed By : Ms. ANJALI

Created By : Ms. ANJALI

BPL - 02

AUTO 10mm/mV

10mm/mV

aVR

10mm/mV

V1

10mm/mV

V4

V5

V6

aVL

V2

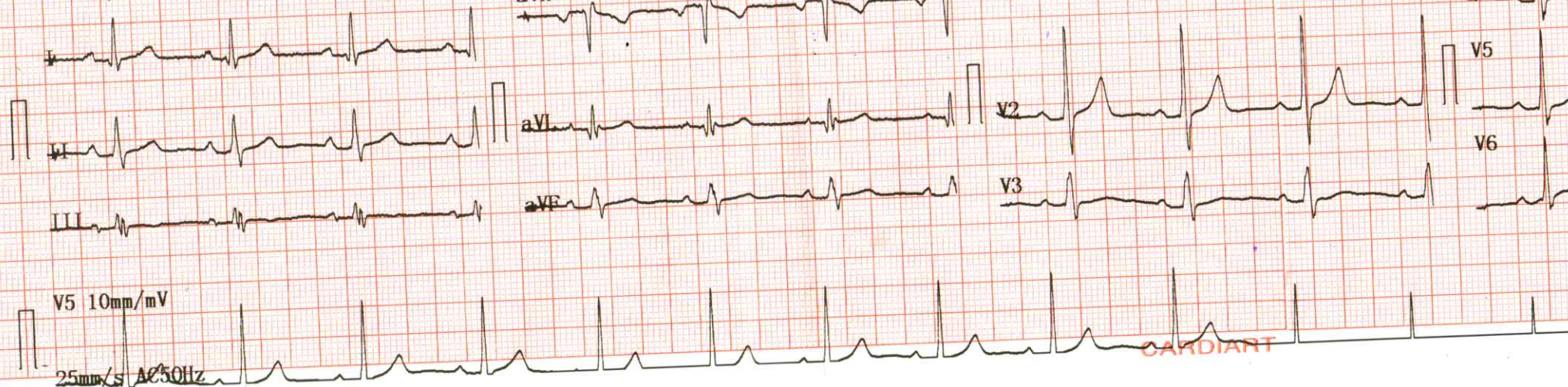aVF

V3

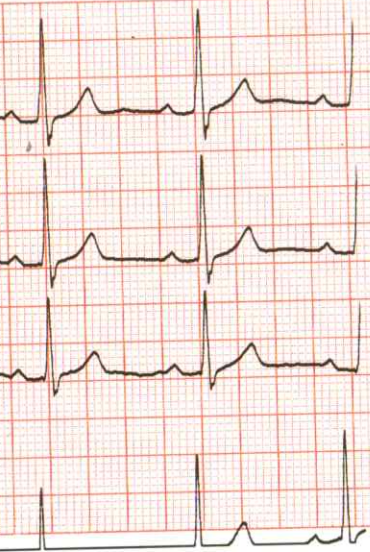V5 10mm/mV

25mm/s AC 50HZ

CARDIANT



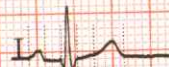BPL - 02



10mm/mV

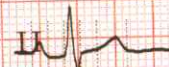10mm/mV

10mm/mV



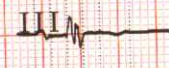
aVL

V3



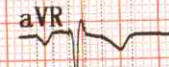
aVF

V4



V1

V5



V2

V6

25mm/s

2023-07-08 10:51

<< Conclusions >>

ID :
 Name : RAKHI SARDI
 Sex : FEMALE Age : 23 Yrs
 Height : _____ Weight : _____ kg
 SYS : _____
 DIA : _____

Normal Sinus Rhythm;
 Cardiac electric axis normal;
 Report need physician confirm

HR [bpm] : 73
 PR Interval [ms] : 181
 P Duration [ms] : 93
 QRS Duration [ms] : 88
 T Duration [ms] : 164
 QT/QTc [ms] : 344/380
 P/QRS/T Axis [deg] : 42.2/42.3/35.1
 R(V5)/S(V1) [mV] : 1.35/0.23
 R(V5)+S(V1) [mV] : 1.58

DR. PALLAVI MISHRA
 MBBS, MD GENERAL MEDICINE
 MCI No. 52033

Physician
CARDIANT



Call Now - 1800-123-3070

PANACEA HOSPITAL

A shelter for many hearts A Home for many lives

(An ISO 9001:2008 Certified Organisation)

Lab Attached with CMC Vellore Under EQAS Scheme

PATIENT'S NAME : MRS RAKHI SAROJ

AGE/SEX: 23 Y/F

REF. BY : Dr. ASHUTOSH MISHRA (MD)

Saturday, July 08, 2023

Echo - Cardiography


MITRAL VALVE Doppler	AML - normal morphology MV Flow - E - 0.6 A-0.4 E/A=1.56	PML - normal morphology MVA - 3.0 cm ² Mitral Regurgitation - No
TRICUSPID VALVE Doppler	Normal TV Flow -No	Tricuspid Regurgitation -No
PULMONARY VALVE Doppler	Normal PV Flow -No	Pulmonary Regurgitation - No
AORTIC VALVE Doppler	Trileaflet-No AV Flow - no	Aortic Regurgitation - no
MEASUREMENT	Aorta - 21.7 (20-38) mm IVS ed - 6.3 (6-12) mm LVID ed - 53.1 (35-55) mm LVPW ed - 8.0 (6-12) mm OA - 7 (> 5) mm	LA - 31.4 (24-32) mm IVS es -13.1 (6-12) mm LVID es - 38.8 (24-40) mm LVPW es - 10.9 (6-12) mm EPSS - 6 (< 9) mm

CONCLUSION

All cardiac chamber dimensions are WNL
No valvular abnormalities
Good LV systolic function present Modified Simpson's method (4C, 2C) (LVEF-52%)
No diastolic dysfunction present (E/A = 1.56)
No RWMA
No pericardial effusion
Intact IAS / IV
No PAH
No intra cardiac mass /thrombus /vegetation

IMPRESSION Normal Echocardiogram

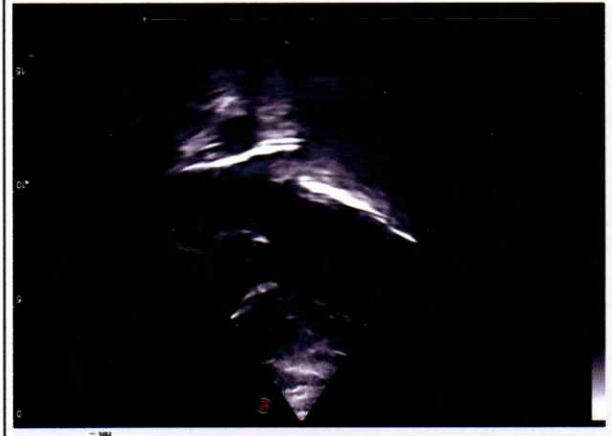

Niraj Mishra
Physician Assistant
(PIRE)


Dr. Pallavi Mishra
MBBS, MD (MED) Lucknow
Echocardiography Specialist, MIAE
Non-invasive cardiologist
Women Cardiologist
Diabetocardiologist

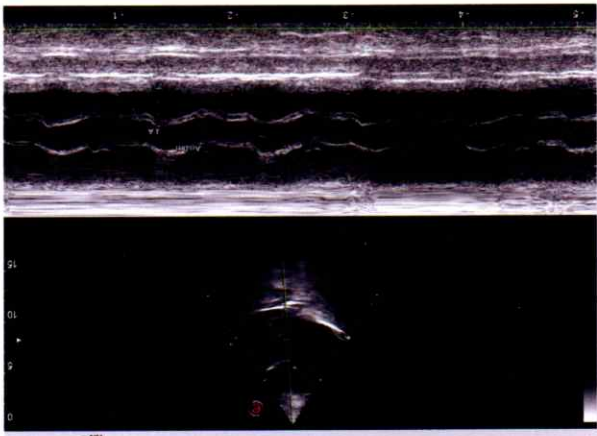
Address : Kabir Nagar (Near Sanjay Shiksha Niketan), Durgakund, Varanasi

Mobile : 9554572190 / 9453837595 / Recpn. 9389994334

E-mail : dramishra@gmail.com, drpallaviojha@gmail.com, Website: www.paire.org

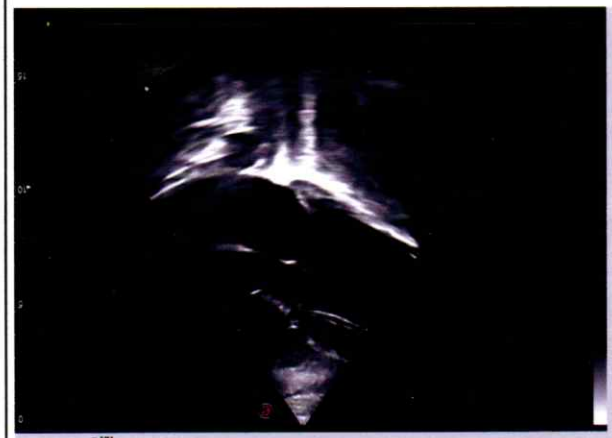


RAKHI SAROU 23Y/F
 08 07 2023 12:02:00 PM
 P 80% M 0.9 TIS 0.5
 PENL G
 PRC 6/2/4 PRS 1
 X/M C/L-
 150 mm

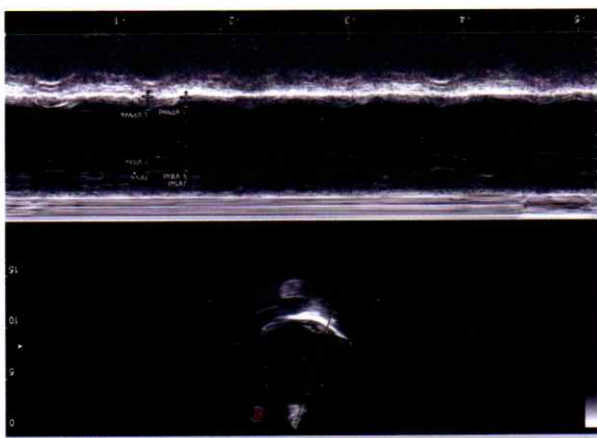


RAKHI SAROU 23Y/F
 08 07 2023 12:02:00 PM
 P 80% M 0.7 TIS 0.5
 PENL G
 PRC 6/2/4 PRS 1
 X/M C/L-
 150 mm

AV EI --
 LA/Ao 1.45
 AVCoap -- mm
 R-R -- ms
 PEP/ET --
 Ao PEP -- ms
 LVET -- ms
 AV OD -- mm
 LA 31.4 mm
 Ao Dm 21.7 mm

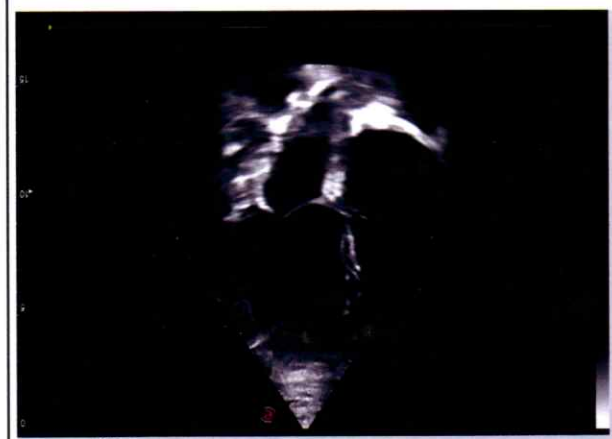

RAKHI SAROU 23Y/F
 08 07 2023 12:02:00 PM
 P 80% M 0.9 TIS 0.5
 PENL G
 PRC 6/2/4 PRS 1
 X/M C/L-
 150 mm

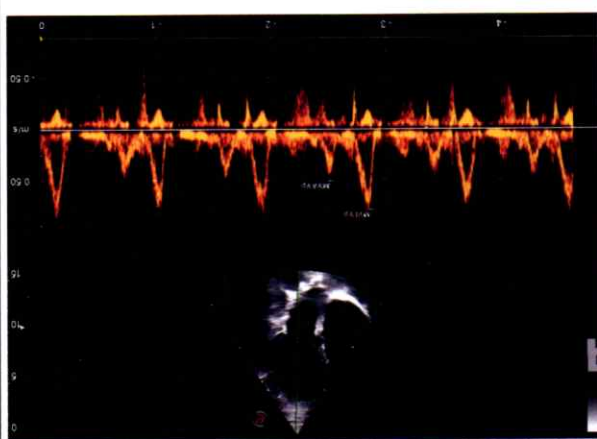


RAKHI SAROU 23Y/F
 08 07 2023 12:02:00 PM
 P 80% M 0.7 TIS 0.5
 PENL G
 PRC 6/2/4 PRS 1
 X/M C/L-
 150 mm

RV/D -- mm
 IVSD 8.3 mm
 LVIDd 53.1 mm
 LVPWd 8.0 mm
 IVSs 13.1 mm
 LVIDs 38.8 mm
 LVPWs 10.9 mm
 EF 52 %
 %LV FS 27 %
 HR eca -- bpm
 %IVS 109 %
 %PW 36 %
 LVMass 149 g
 LVMI --
 S-PWD -- ms
 FioPv -- m/s
 E/Vp --




RAKHI SAROU 23Y/F
 08 07 2023 12:02:00 PM
 P 80% M 0.9 TIS 0.5
 PENL G
 PRC 6/2/4 PRS 1
 X/M C/L-
 150 mm



RAKHI SAROU 23Y/F
 08 07 2023 12:02:00 PM
 P 80% M 0.8 TIS 0.5
 PW F 2.5 MHz G
 PRC 4/1
 X/M C/L-
 150 mm

MV VTI -- m
 MVEVd 0.79 m/s
 MVAVd 0.51 m/s
 MVEGd 2.5 mmHg
 MVAEd 1.0 mmHg
 MVVmn -- m/s
 Mgm -- mmHg
 MV Pht -- ms
 MVAdht -- cm²
 MV E/A 1.56
 MV AT -- ms
 MV DT -- ms
 IVRT -- ms
 IVCT -- ms
 AVDT -- ms
 LVET -- ms
 LIMP --



 GPS Map Camera

Varanasi, Uttar Pradesh, India

44-B3, Durgakund, Bhelupur, Varanasi, Uttar Pradesh 221001,
India

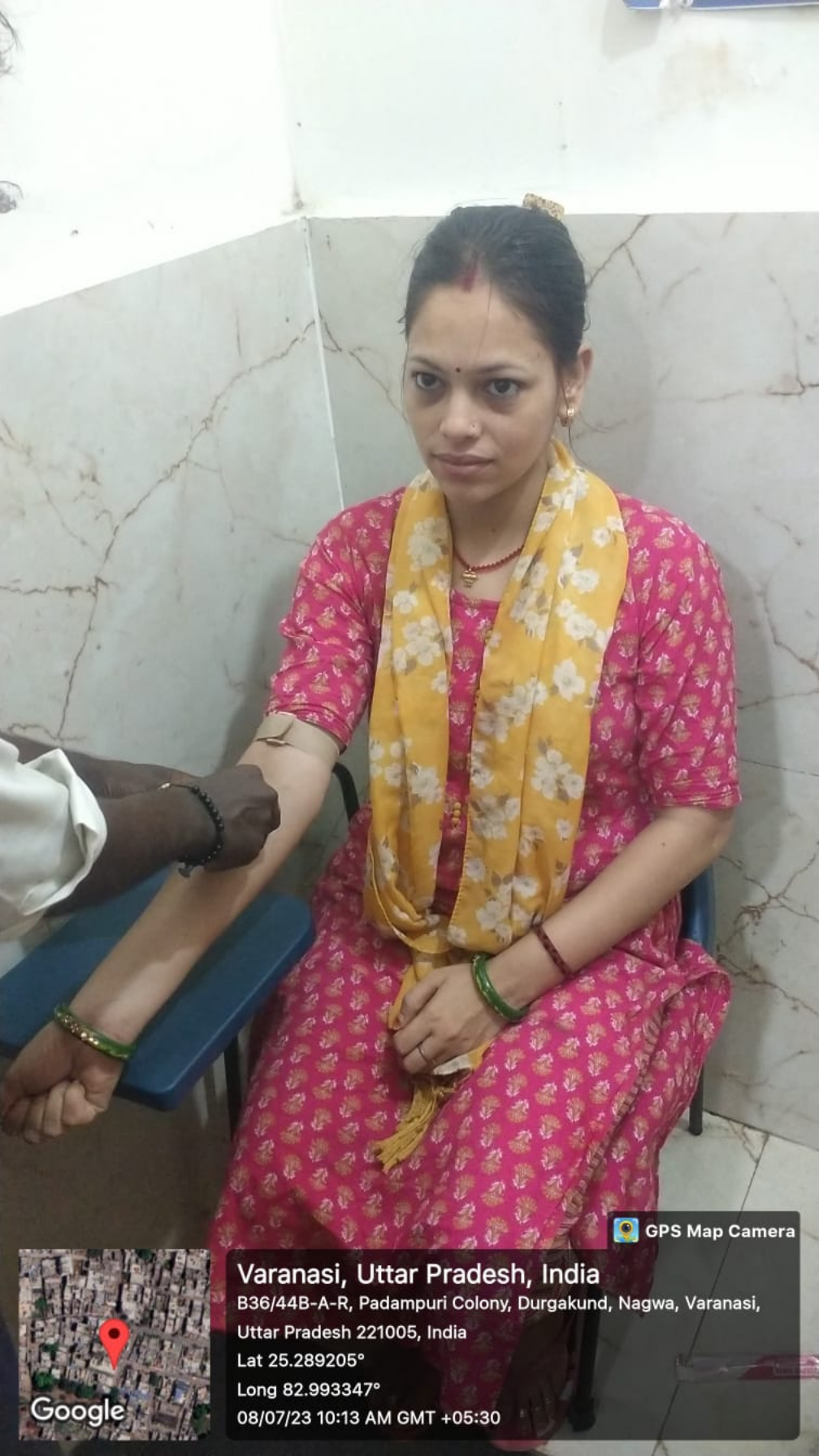Lat 25.289238°


Long 82.993319°

08/07/23 11:43 AM GMT +05:30



Google



 GPS Map Camera

Varanasi, Uttar Pradesh, India

B36/44B-A-R, Padampuri Colony, Durgakund, Nagwa, Varanasi,
Uttar Pradesh 221005, India

Lat 25.289205°

Long 82.993347°

08/07/23 10:13 AM GMT +05:30



होपताल/नर्सिंग होम/
बिच सेक्टर में तोड़-फोड़
कवरट एवं छटाक के साथ
चढ़ाव अबसा नारपीट
द जमाबती अपटास हे।
कानून
Medical Protection Act - 2013
एक हे कानूनी जमाने।
ए 50000- के सुधार।
एक हे सुधार में सुधरी सौ सुधरी के सुधरी।
एक हे सुधार में सुधरी सौ सुधरी के सुधरी।
एक हे सुधार में सुधरी सौ सुधरी के सुधरी।

Diabetic Care Organ
A Shelter For Many Hearts
Home For Many Lives

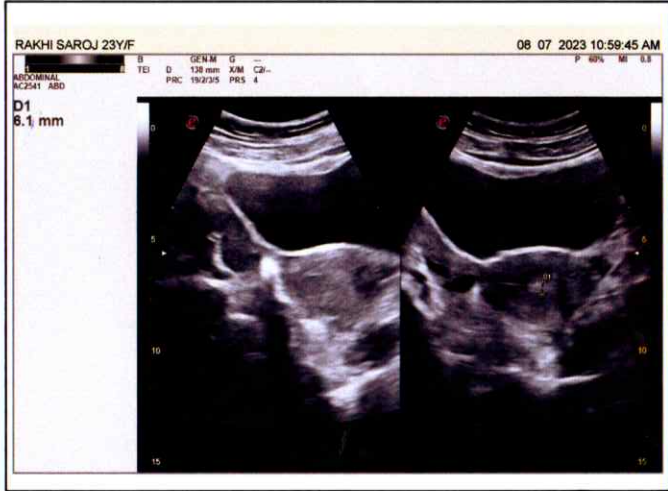
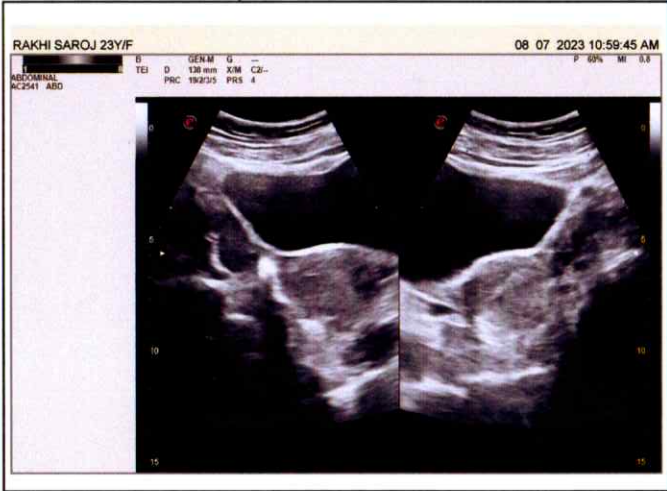
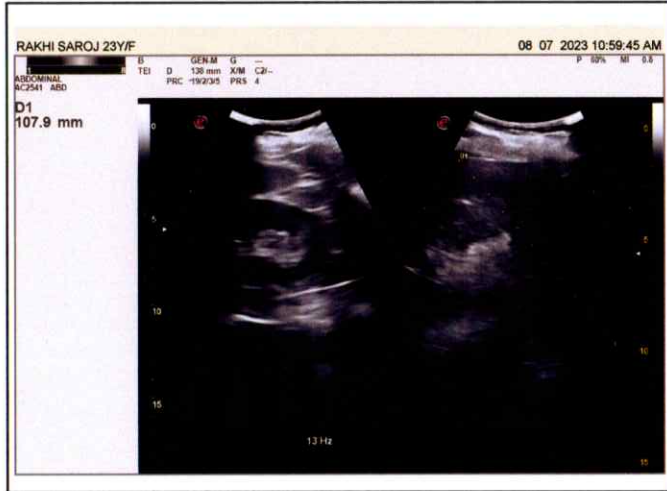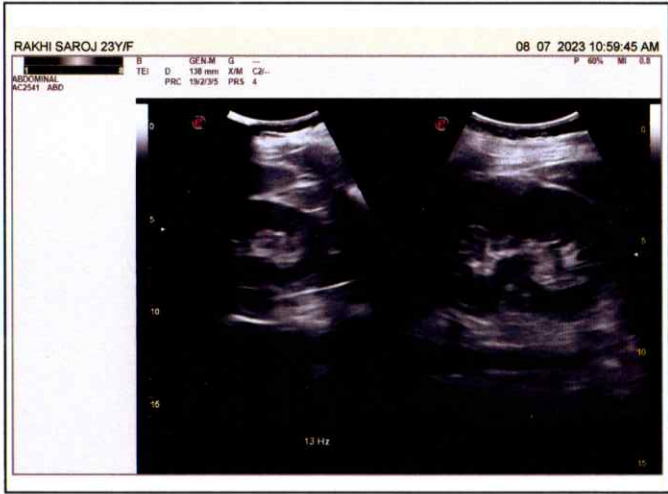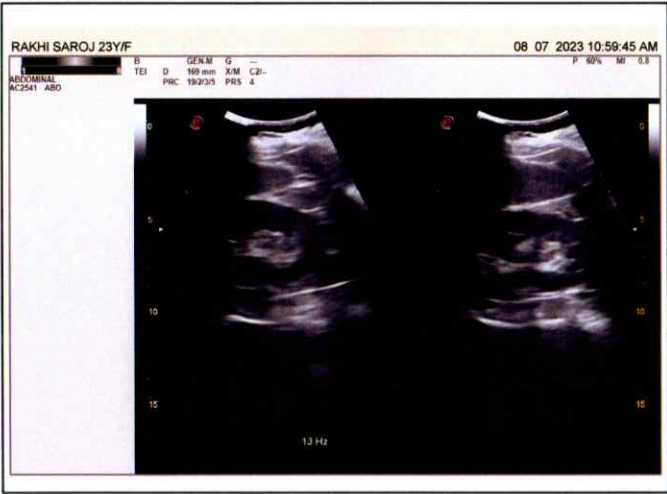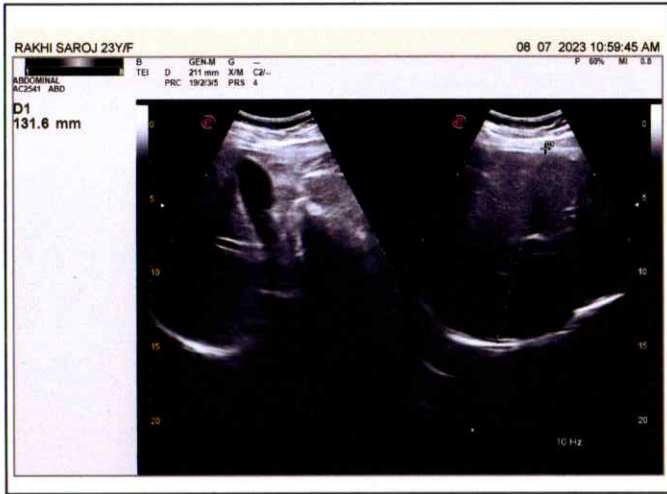MAY I H

GPS Map Camera

Varanasi, Uttar Pradesh, India
44-B3, Durgakund, Bhelupur, Varanasi, Uttar Pradesh 221001,
India
Lat 25.289295°
Long 82.993281°
08/07/23 10:15 AM GMT +05:30







Call Now - 1800-123-3070

PANACEA HOSPITAL

A shelter for many hearts A Home for many lives

(An ISO 9001:2008 Certified Organisation)

Lab Attached with CMC Vellore Under EQAS Scheme

PATIENT'S NAME : RAKHI SAROJ	AGE/SEX: 23 Y/F
REF. BY : Dr. VANDANA SINGH	Saturday, July 08, 2023

U/S. WHOLE ABDOMEN

- LIVER** : Liver is normal in size, shape & echotexture. Intra hepatic biliary radicals are normal. Portal venous channels are normal.
- G. B.** : Gall bladder is normal in size, lumen is clear. Wall thickness normal.
- C.B.D.** : C.B.D. is normal in caliber.
- PANCREAS** : Pancreas is normal in size, shape and echotexture. No evidence of any inflammatory disease or mass.
- SPLEEN** : Spleen is normal in size, shape and echotexture.
- B/L KIDNEY** : Normal in size, shape and echotexture. Renal sinus is normal
Cortico medullary differentiation is normal. P. C. system is normal.
- URI. BLADDER** : Urinary bladder is normal in size, position. Wall thickness normal.
No evidence of calculus or mass.
- UTERUS** : Uterus normal in size measuring approx 33x52x41mm
Endometrium measuring (10mm.)
- OVARIES** : Lt. Ovary:-Normal in size.
Rt. Ovary:-Normal in size.
No free fluid seen in P. O. D.
- IMPRESSION** : **NO OBVIOUS SONOLOGICAL ABNORMALITY SEEN.**


Radiologist.

Thanks for reference.

Address : Kabir Nagar (Near Sanjay Shiksha Niketan), Durgakund, Varanasi

Mobile : 9554572190 / 9453837595 / Recpn. 9389994334

E-mail : dramishra@gmail.com, drpallaviojha@gmail.com, Website: www.piire.org



Call Now - 1800-123-3070

PANACEA HOSPITAL

A shelter for many hearts A Home for many lives

(An ISO 9001:2008 Certified Organisation)

Lab Attached with CMC Vellore Under EQAS Scheme

P PATIENT'S NAME : RAKHI SAROJ

AGE/SEX: 23 Y/F

REF. BY

: Dr. VANDANA SINGH

Saturday, July 08, 2023

X-RAY CHEST PA

BOTH LUNG FIELDS AND PLEURAE:

Both lungs show normal bronchovascular pattern.

Right & left hila are normal

No focal mass or calcification is seen

There is no evidence of any fluid in the both the pleural cavities.

Both domes of diaphragms are normal in position.

MEDIASTINUM:

Trachea is central in position.

Cardiac silhouette is of normal size and configuration.

No evidence of pericardial effusion.

No significant lymphadenopathy is seen.

Visualized skeleton is normal.

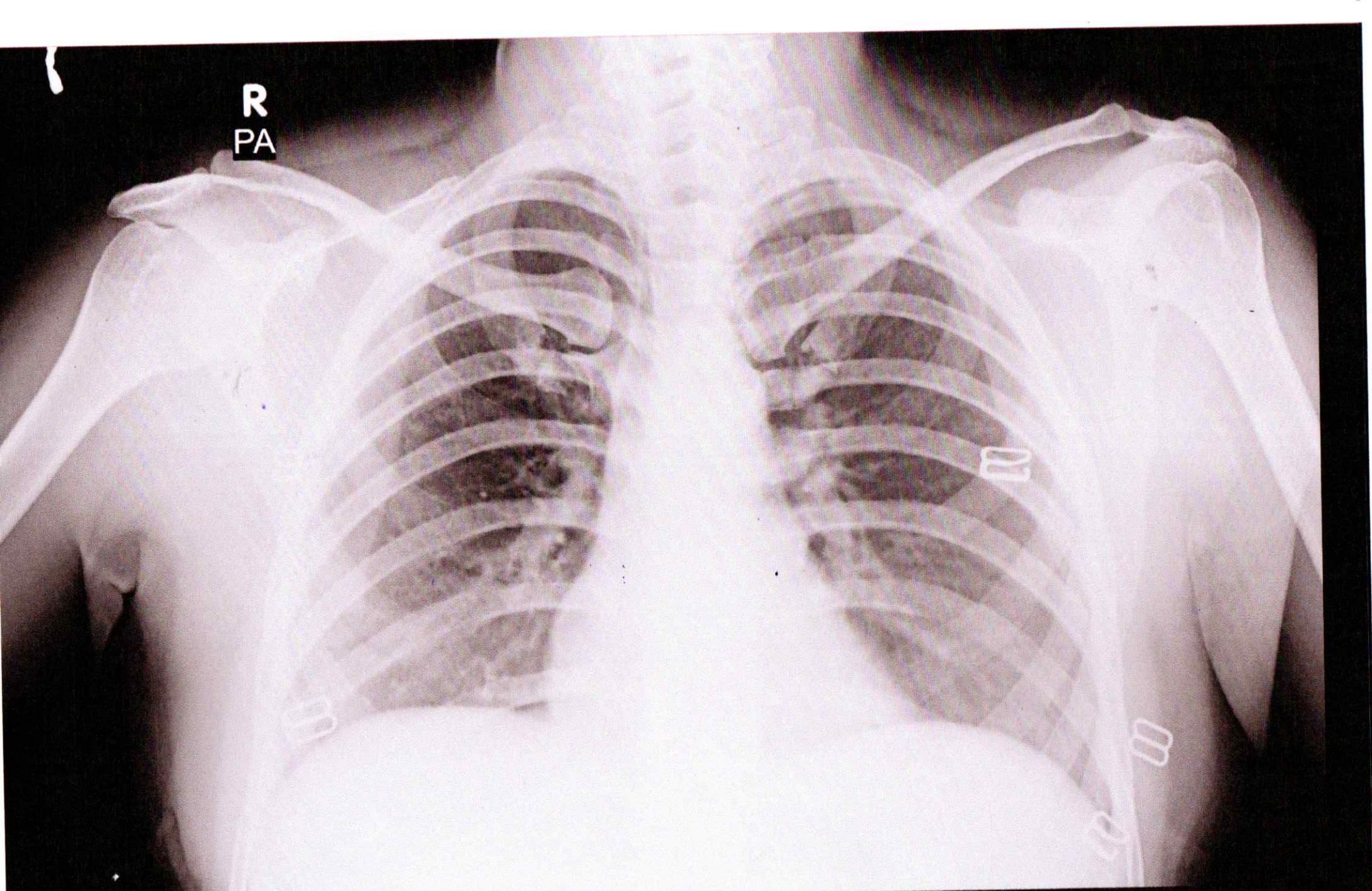
NO SIGNIFICANT RADIOGRAPHIC ABNORMALITY.

Radiologist

Address : Kabir Nagar (Near Sanjay Shiksha Niketan), Durgakund, Varanasi

Mobile : 9554572190 / 9453837595 / Recpn. 9389994334

E-mail : dramishra@gmail.com, drpallaviojha@gmail.com, Website: www.paire.org



R
PA

RAKHI SAROJ 23Y/F 1415 O CHEST P.A. 08-Jul-23 10:38 AM

PANACEA HOSPITAL, KABIR NAGAR, DURGAKUND, VARANASI