

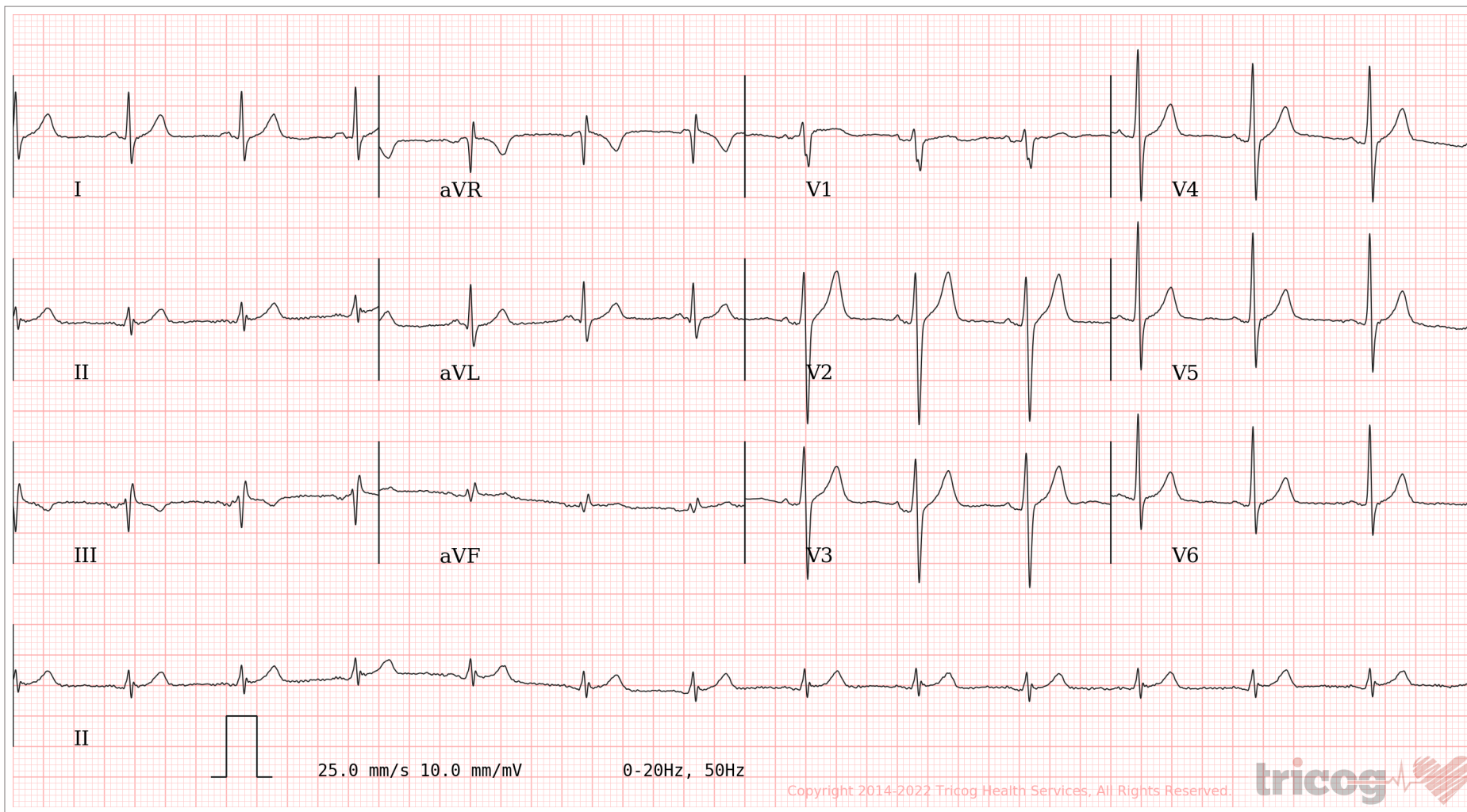


Age / Gender: 31/Male

Date and Time: 1st May 22 10:11 AM

Patient ID: IDUN0036662223

Patient Name: Mr.ANSHUL KUMAR -BOBE11694



AR: 81bpm VR: 81bpm QRSD: 84ms QT: 330ms QTc: 383ms PRI: 116ms P-R-T: -15° 6° 18°

ECG Within Normal Limits: Sinus Rhythm, Normal Axis. Please correlate clinically.

AUTHORIZED BY

Dr. Charit
MD, DM: Cardiology

REPORTED BY

Dr. Preethi Chandramouli