

Patient Name: ASIF AERUM

Date and Time: 4th Dec 21 4:10 PM

Patient ID: 2133838916

Age **35 11 23**  
years months days

Gender **Female**

Heart Rate **83 bpm**

**Patient Vitals**

BP: NA

Weight: NA

Height: NA

Pulse: NA

Spo2: NA

Resp: NA

Others: \_\_\_\_\_

**Measurements**

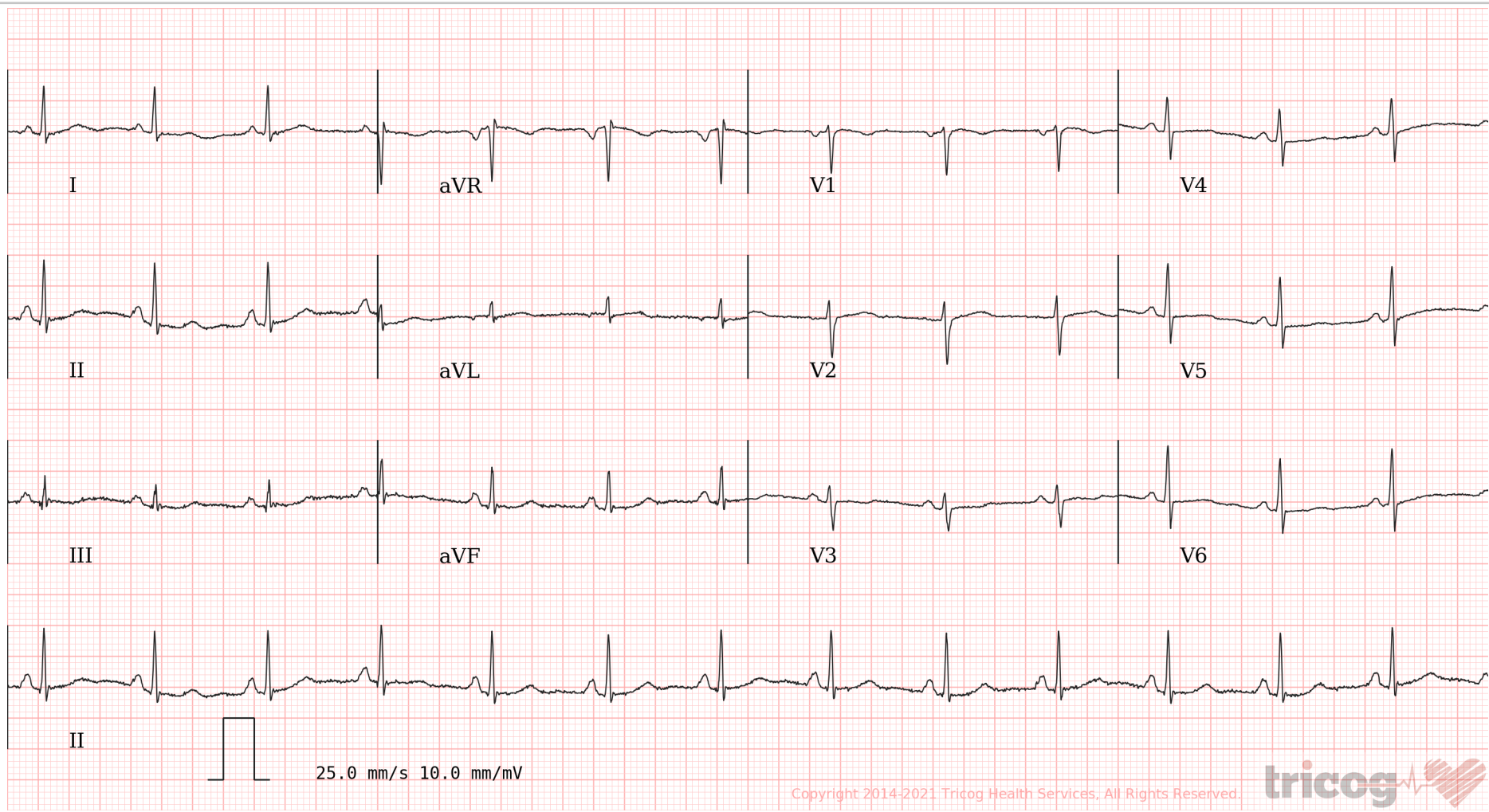
QSRD: 68 ms

QT: 352 ms

QTc: 413 ms

PR: 120 ms

P-R-T: 65° 47° 49°



Copyright 2014-2021 Tricog Health Services, All Rights Reserved.



Sinus Rhythm, Normal Axis, T wave flattening in V4-V6. Please correlate clinically.

REPORTED BY

Dr. Ajita Bhosale  
M.B.B.S/P.G.D.C.C (DIP. Cardiology)  
2013062200



CID : 2133838916  
Name : Ms ASIF AERUM  
Age / Sex : 35 Years/Female  
Ref. Dr :  
Reg. Location : Andheri West (Main Center)

Reg. Date : 04-Dec-2021 / 13:34  
Report Date : 04-Dec-2021 / 15:12  
Printed : 04-Dec-2021 / 15:12

## USG WHOLE ABDOMEN

### LIVER:

The liver is normal in size (12.6cm), shape and smooth margins. It shows normal parenchymal echo pattern. The intra hepatic biliary and portal radical appear normal.

**A well defined, hyperechoic lesion measuring 1.7 x 1.2cm is noted in the right lobe of the liver. Features could be suggestive of hemangioma.**

The main portal vein and CBD appears normal.

### GALL BLADDER:

The gall bladder is partially distended. No evidence of any obvious gall stones seen.

### PANCREAS:

The pancreas is well visualised and appears normal. No evidence of solid or cystic mass lesion.

### KIDNEYS:

Both the kidneys are normal in size shape and echotexture.

No evidence of any hydronephrosis or mass lesion seen.

Right kidney measures 10.2 x 4.2cm. Left kidney measures 9.7 x 3.9cm.

**Two calculi are noted in the lower pole of the right kidney measuring 7.9mm and 5.4mm**

### SPLEEN:

The spleen is normal in size (8.3cm) and echotexture. No evidence of focal lesion is noted.

There is no evidence of any lymphadenopathy or ascites.

### URINARY BLADDER:

The urinary bladder is well distended and reveal no intraluminal abnormality.

### UTERUS:

The uterus is anteverted. It measures 5.2 x 4.4 x 4.0cm in size. **Two subserosal fibroids are noted in the uterus measuring 2.3 x 1.9cm in the anterior wall and 1.2 x 1.0cm in the left lateral wall.**

The endometrial thickness is 6.6mm.



CID : 2133838916  
Name : Ms ASIF AERUM  
Age / Sex : 35 Years/Female  
Ref. Dr :  
Reg. Location : Andheri West (Main Center)

Reg. Date : 04-Dec-2021 / 13:34  
Report Date : 04-Dec-2021 / 15:12  
Printed : 04-Dec-2021 / 15:12

**OVARIES:**

Both the ovaries are well visualised and appears normal.

Right ovary = 2.3 x 1.4cm

Left ovary = 2.6 x 1.2cm

*Kindly correlate clinically and with further investigations.*

-----End of Report-----

DR. NIKHIL DEV  
M.B.B.S, MD (Radiology)  
Reg No – 2014/11/4764  
Consultant Radiologist

Click here to view images <http://202.143.96.162/Suburban/Viewer?ViewerType=3&AccessionNo=2021120413102399> Page 2 to 2

ADDRESS: 2<sup>nd</sup> Floor, Aston, Sundervan Complex, Above Mercedes Showroom, Andheri West - 400053

HEALTHLINE - MUMBAI: 022-6170-0000 | OTHER CITIES: 1800-266-4343

For Feedback - [customerservice@suburbandiagnosics.com](mailto:customerservice@suburbandiagnosics.com) | [www.suburbandiagnosics.com](http://www.suburbandiagnosics.com)



CID : 2133838916  
Name : Ms ASIF AERUM  
Age / Sex : 35 Years/Female  
Ref. Dr :  
Reg. Location : Andheri West (Main Center)

Reg. Date : 04-Dec-2021 / 15:58  
Report Date : 04-Dec-2021 / 17:08  
Printed : 04-Dec-2021 / 17:08

### X-RAY CHEST PA VIEW

Both lung fields are clear.

Both costo-phrenic angles are clear.

The cardiac size and shape are within normal limits.

The domes of diaphragm are normal in position and outlines.

The skeleton under review appears normal.

### IMPRESSION:

**NO SIGNIFICANT ABNORMALITY IS DETECTED.**

-----End of Report-----

Dr R K Bhandari  
M D , DMRE  
MMC REG NO. 34078

Click here to view images <http://202.143.96.162/Suburban/Viewer?ViewerType=3&AccessionNo=2021120413102406> Page 1 to 1

ADDRESS: 2<sup>nd</sup> Floor, Aston, Sundervan Complex, Above Mercedes Showroom, Andheri West - 400053

HEALTHLINE - MUMBAI: 022-6170-0000 | OTHER CITIES: 1800-266-4343

For Feedback - [customerservice@suburbandiagnosics.com](mailto:customerservice@suburbandiagnosics.com) | [www.suburbandiagnosics.com](http://www.suburbandiagnosics.com)



Use a QR Code Scanner  
Application To Scan the Code

CID : 2133838916  
Name : MS.AERUM ASIF  
Age / Gender : 35 Years / Female  
Consulting Dr. : -  
Reg. Location : Andheri West (Main Centre)

Collected : 04-Dec-2021 / 14:21  
Reported : 04-Dec-2021 / 16:12

**AERFOCAMI HEALTHCARE BELOW 40 MALE/FEMALE**  
**URINE EXAMINATION REPORT**

<u>PARAMETER</u>	<u>RESULTS</u>	<u>BIOLOGICAL REF RANGE</u>	<u>METHOD</u>
<b><u>PHYSICAL EXAMINATION</u></b>			
Color	Pale yellow	Pale Yellow	-
Reaction (pH)	7.0	4.5 - 8.0	Chemical Indicator
Specific Gravity	1.005	1.001-1.030	Chemical Indicator
Transparency	Slight hazy	Clear	-
Volume (ml)	40	-	-
<b><u>CHEMICAL EXAMINATION</u></b>			
Proteins	Absent	Absent	pH Indicator
Glucose	Absent	Absent	GOD-POD
Ketones	Absent	Absent	Legals Test
Blood	<b>Trace</b>	Absent	Peroxidase
Bilirubin	Absent	Absent	Diazonium Salt
Urobilinogen	Normal	Normal	Diazonium Salt
Nitrite	Absent	Absent	Griess Test
<b><u>MICROSCOPIC EXAMINATION</u></b>			
Leukocytes(Pus cells)/hpf	0-1	0-5/hpf	
Red Blood Cells / hpf	Occasional	0-2/hpf	
Epithelial Cells / hpf	1-2		
Casts	Absent	Absent	
Crystals	Absent	Absent	
Amorphous debris	Absent	Absent	
Bacteria / hpf	+(>20/hpf)	Less than 20/hpf	
Others	-		

\*Sample processed at SUBURBAN DIAGNOSTICS (INDIA) PVT. LTD CPL, Andheri West  
\*\*\* End Of Report \*\*\*



MC-2111

*Shashi D*  
**Dr.SHASHIKANT DIGHADE**  
**M.D. (PATH)**  
**Pathologist**



ADDRESS: 2<sup>nd</sup> Floor, Aston, Sundervan Complex, Above Mercedes Showroom, Andheri West - 400053

HEALTHLINE - MUMBAI: 022-6170-0000 | OTHER CITIES: 1800-266-4343

For Feedback - customerservice@suburbandiagnosics.com | www.suburbandiagnosics.com