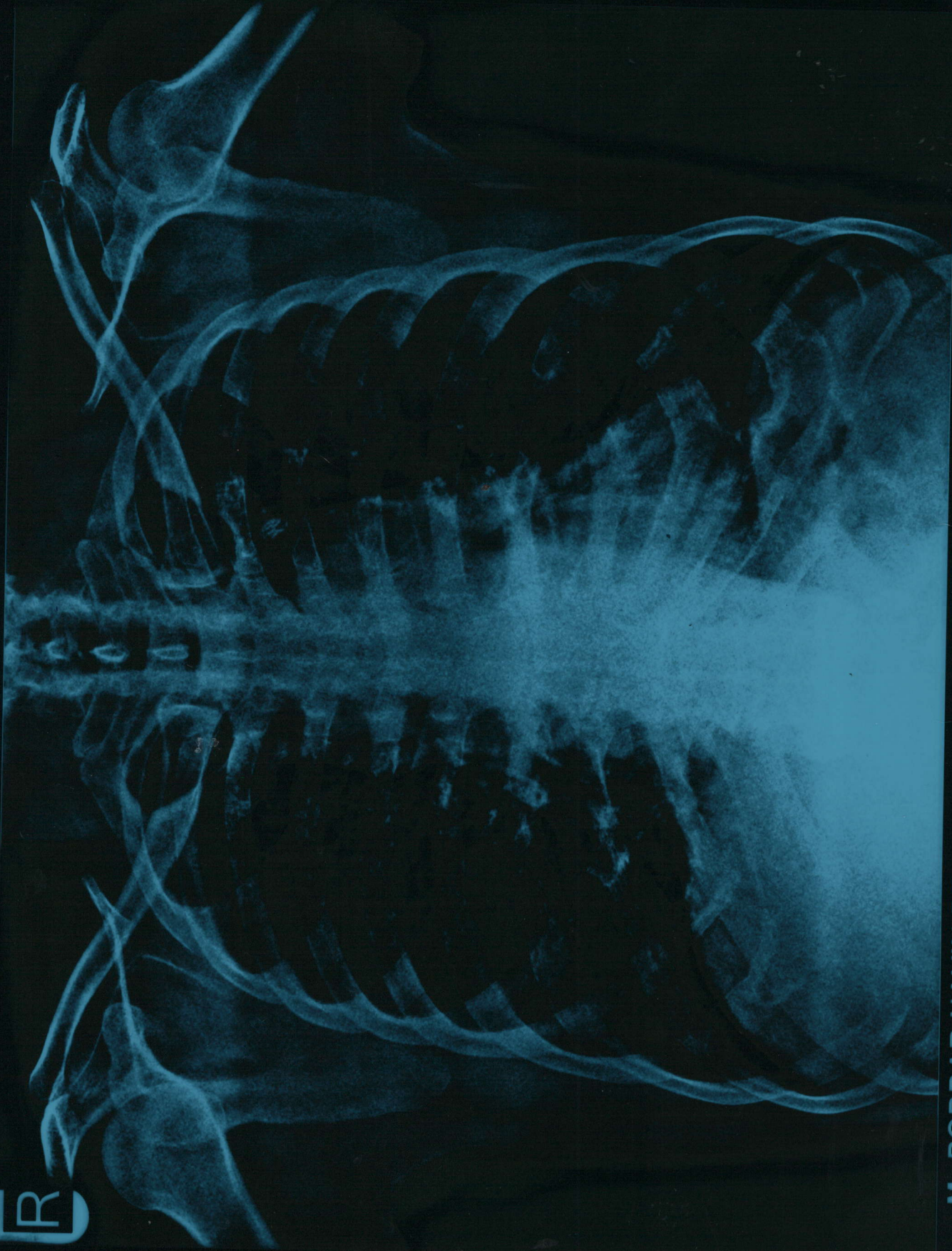
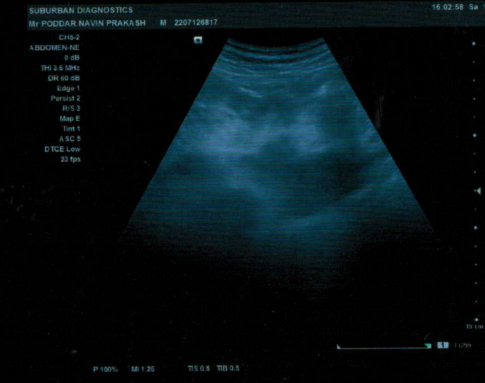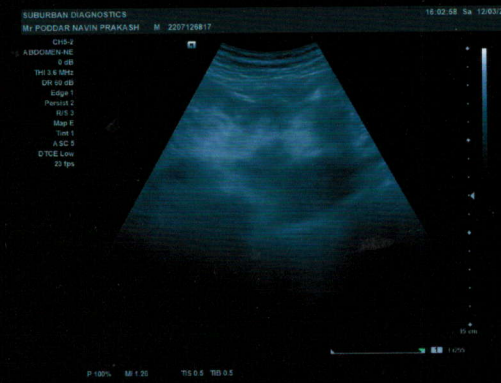
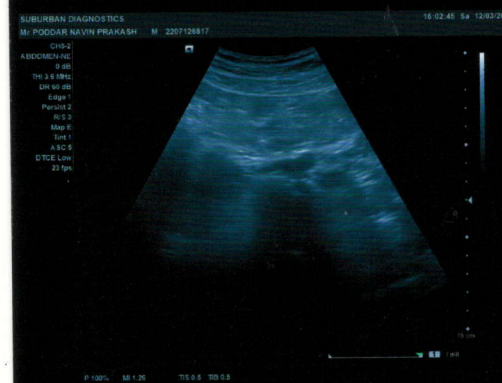
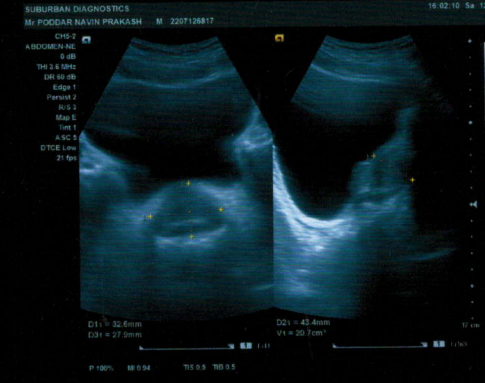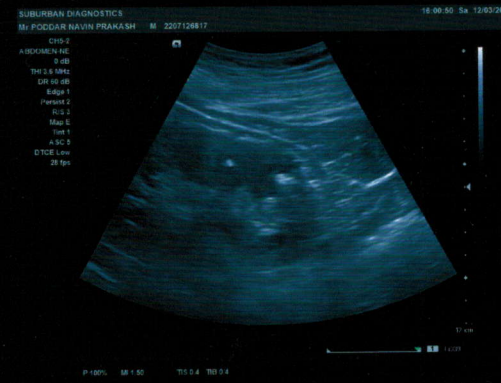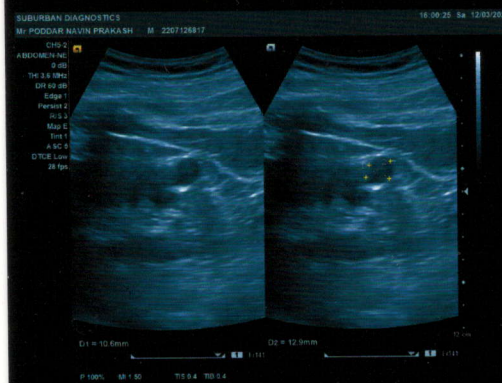
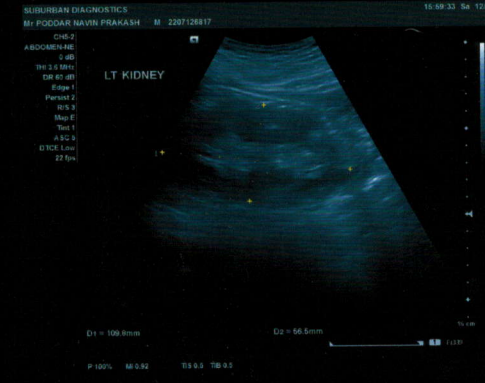
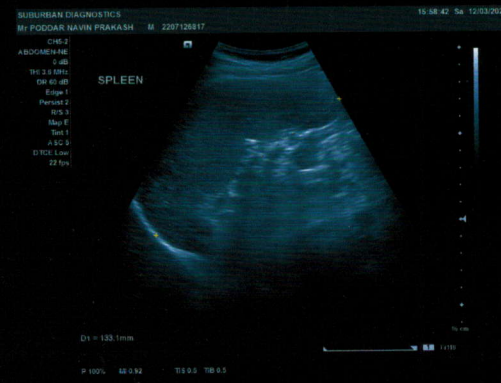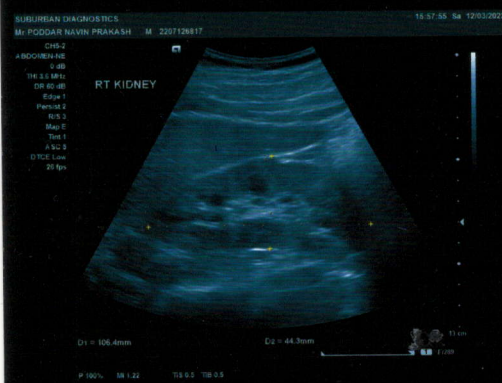
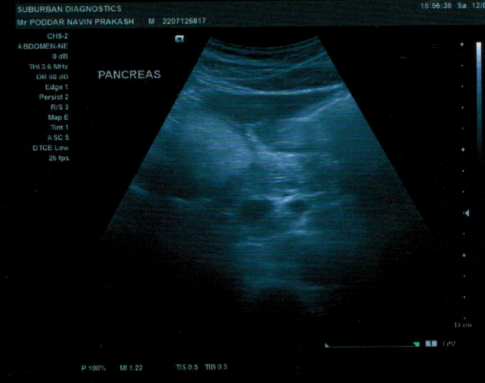
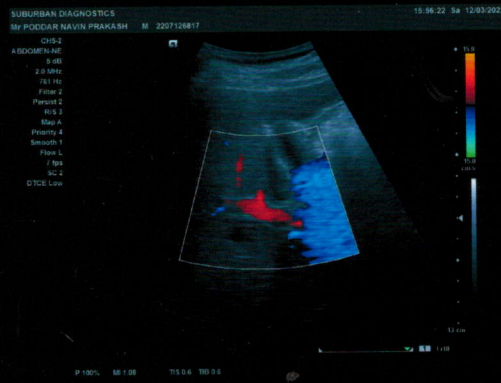


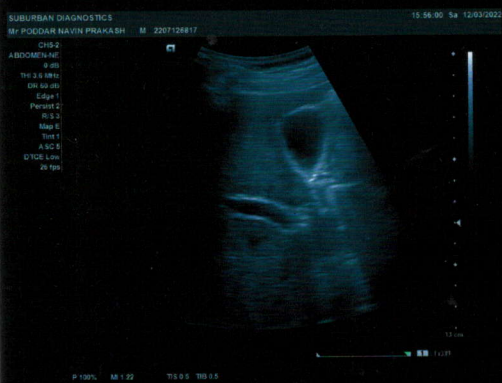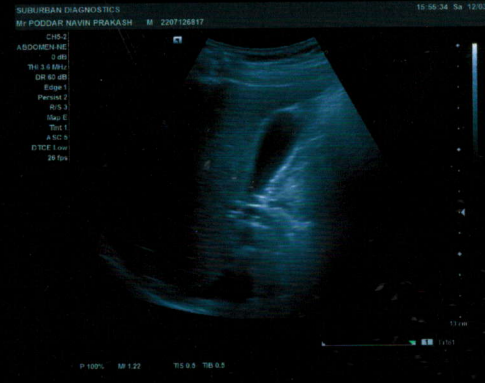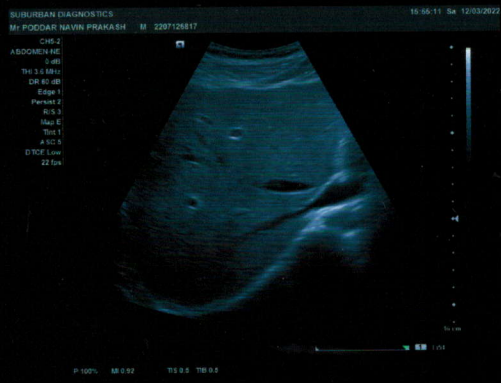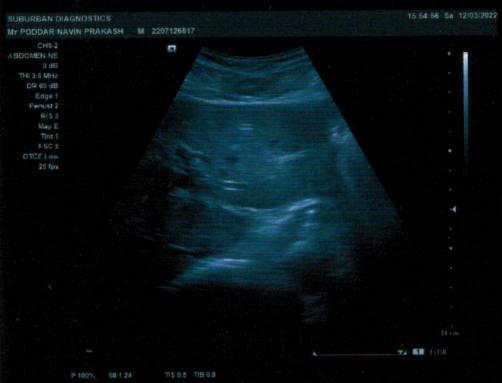R



Mr PODDAR NAVIN PRAKASH M 53 YRS 2207126817 CHEST PA 3/12/2022
SIJIBI PRAN DIAGNOSTICS PUNE



MT
Poddar Navin Prakash
53/M

12-3-22

PHY2.

R
E
P
O
R
T

History and Complaints:

NIL

EXAMINATION FINDINGS:

Height (cms):	168	Weight (kg):	65	BMI
Temp (0c):	Afebrile	Skin:	Normal	2 NAD
Blood Pressure (mm/hg):	110/80	Nails:	Healthy	
Pulse:	72	Lymph Node:	Not Palpable	

Systems

Cardiovascular:	S1,S2 Normal No Murmurs	2 NAD
Respiratory:	Air Entry Bilaterally Equal	
Genitourinary:	Normal	
GI System:	Soft non tender No Organomegaly	
CNS:	Normal	

IMPRESSION:

↓ HB ↑ Lymphocytes
Splenomegaly on USG
Other all reports WNL.

ADVICE:

- 1) Advised to update reading glasses.
- 2) Physician / hematologist advise


CHIEF COMPLAINTS:

1)	Hypertension:	2 NAD
2)	IHD:	
3)	Arrhythmia:	
4)	Diabetes Mellitus :	
5)	Tuberculosis :	
6)	Asthama:	
7)	Pulmonary Disease :	




PUNE LAB ADDRESS: Seraph Centre, Opp. BSNL Exchange, Shahu College Road, Off Pune-Satara Road, Behind Parichami Hotel, Pune - 411009


CENTRAL PROCESSING LAB: 2nd Floor, Aston, Sundervan Complex, Above Mercedes Showroom, Andheri West, Mumbai - 400053

HEALTHLINE - MUMBAI: 022-6170-0000 | OTHER CITIES: 1800-266-4343 | For Feedback - customerservice@suburbandiagnosics.com | www.suburbandiagnosics.com

8)	Thyroid/ Endocrine disorders :	
9)	Nervous disorders :	
10)	GI system :	
11)	Genital urinary disorder :	
12)	Rheumatic joint diseases or symptoms :	
13)	Blood disease or disorder :	
14)	Cancer/lump growth/cyst :	
15)	Congenital disease :	
16)	Surgeries :	

PERSONAL HISTORY:

1)	Alcohol	
2)	Smoking	
3)	Diet	
4)	Medication	



Dr. KRUTIKA INGLE

MBBS, D.DM, PG in Diabetology (USA)
MMC Regd - 2012 103018

Preventive Health Check-up | Pathology | Digital X-Ray | Sonography | Colour Doppler | Mammography | BMD (DXA Scan) | ECG | Stress Test/TMT | 2D Echo | Spirometry | Eye Examination | Dental Examination | Diet Consultation | Audiometry | OT Sterility | Water Sterility | Clinical Res

R
E
P
O
R
T

Date:- 12-3-22
Name:- Poddar Navin Prakash
CID:
Sex / Age: 53 / M

EYE CHECK UP

Chief complaints:

Systemic Diseases:

Past history:

Unaided Vision:

Aided Vision:

Refraction:

gms

NA

g corrected c specs

	(Right Eye)				(Left Eye)			
	Sph	Cyl	Axis	Vn	Sph	Cyl	Axis	Vn
Distance	_____				_____			
Near	_____				_____			
				N-12				N-12

Colour Vision: Normal / Abnormal

Remark:

Update reading glass number.

Krutika Ingle

Dr. KRUTIKA INGLE

MBBS, D.DM, PG in Diabetology (USA)
MMC Regd - 2012 103018

DENTAL CHECK - UP

Name:- Poddoy Navin P.

CID: 53 Sex / Age: / M

Occupation:-

Date: 12/3/22

Chief complaints:-

Medical / dental history:-

gone

GENERAL EXAMINATION:

1) Extra Oral Examination:

- a) TMJ:
- b) Facial Symmetry:

2) Intra Oral Examination:

- a) Soft Tissue Examination:
 - b) Hard Tissue Examination:
 - c) Calculus:
- Stains:

gone
NAD

18	17	16	15	14	13	12	11	21	22	23	24	25	26	27	28
48	47	46	45	44	43	42	41	31	32	33	34	35	36	37	38

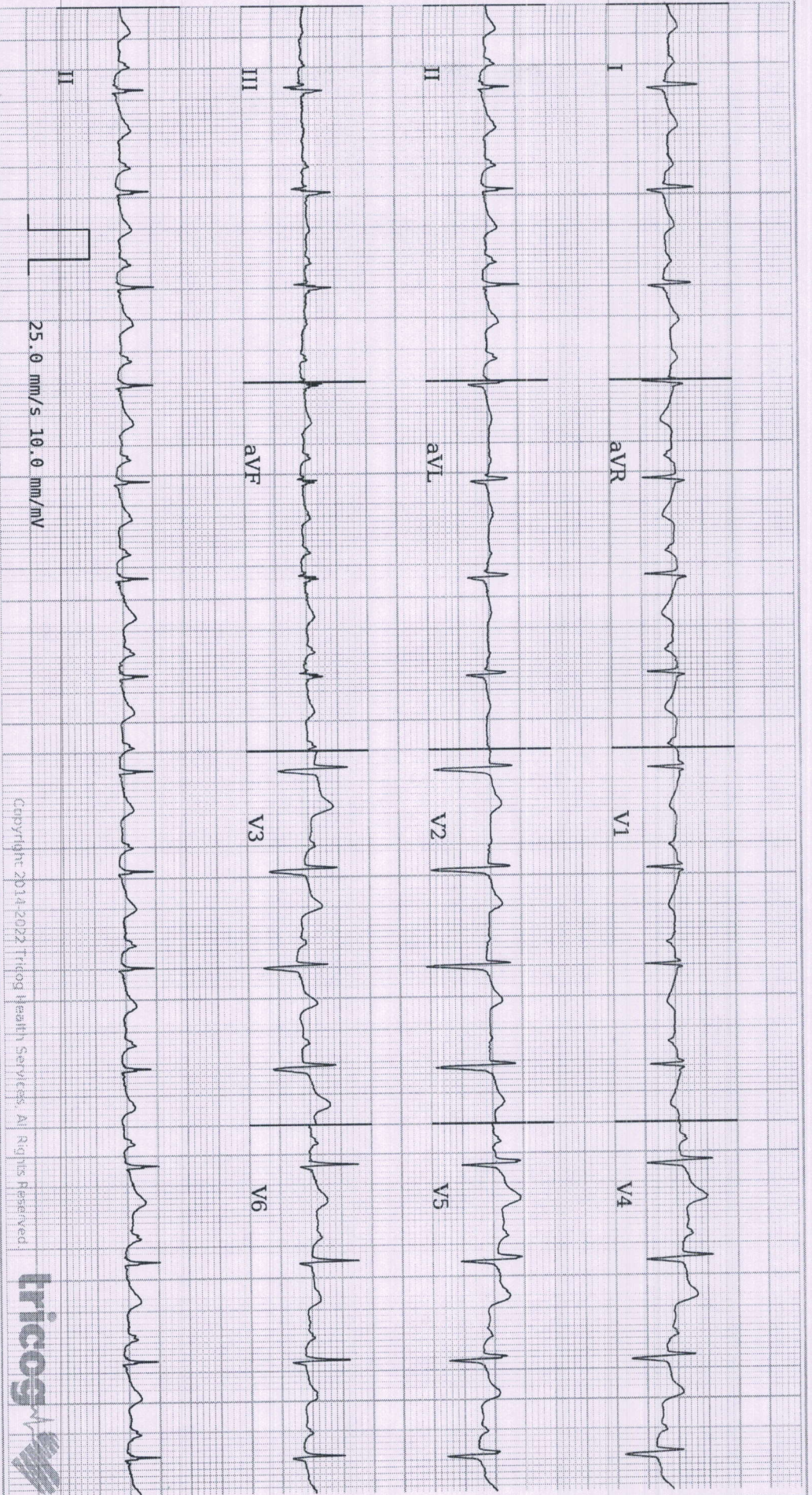
	Missing	#	Fractured
○	Filled/Restored	RCT	Root Canal Treatment
○	Cavity/Caries	RP	Root Piece

Advised: - NIL -

Provisional Diagnosis:-

Krutika Ingle
Dr. KRUTIKA INGLE

MBBS, D.DM, PG in Diabetology (USA)
MMC Regd - 2012 103018



Copyright 2014-2022 Tricog Health Services. All Rights Reserved.



Age **53** 3 11
 years months days

Gender **Male**

Heart Rate **95bpm**

Patient Vitals

BP: **110/80 mmHg**

Weight: **65 kg**

Height: **168 cm**

Pulse: **74 bpm**

Spo2: **NA**

Resp: **NA**

Others:

Measurements

QSRD: **72ms**

QT: **358ms**

QTc: **449ms**

PR: **162ms**

P-R-T: **47° 53° 37°**

REPORTED BY

Dr. Krutika Ingle

MBBS, DDM, PG in Diabetology (USA)

2012103018

ECG Within Normal Limits: Sinus Rhythm, Normal Axis. Please correlate clinically.



CID : 2207126817
Name : Mr PODDAR NAVIN PRAKASH
Age / Sex : 53 Years/Male
Ref. Dr : **Reg. Date** : 12-Mar-2022 / 15:54
Reg. Location : Pimple Saudagar, Pune Main Centre **Reported** : 12-Mar-2022 / 16:01

USG WHOLE ABDOMEN

Liver- Normal in size, shape and echo pattern. No focal lesion. Intrahepatic biliary and portal radicals appear normal. Visualised portion of CBD appears normal in calibre. Portal vein appears normal.

Gall bladder- partially distended with normal wall thickness. No calculus or mass lesion is visualized. No pericholecystic collection.

Pancreas- Head and body are visualized and appear normal in size, shape and echo pattern. No focal lesion seen. No peripancreatic collection noted.

Spleen - mildly enlarged in size (13.3cm) , appears normal in shape & echo pattern. No focal lesion seen.

Kidneys- Right kidney - 10.6 x 4.4 cm, Left kidney -10.5 x 4.9 cm, both kidneys appear normal in size, shape, position & echo pattern with maintained cortico-medullary differentiation. *Tiny papillary concretions are noted in both the kidneys. Simple cortical cyst of approximate size 10 x 13mm is noted at mid pole of left kidney with milk of calcium within.* No hydronephrosis, hydroureter or calculus noted.

Urinary bladder- Is partially distended & shows normal wall thickness. No calculus or mass lesion is noted.

Prostate - measures 3.2 x 4.3x 2.7 cm (vol 20.7cc) appears normal in size, shape and echo-pattern for age. No focal lesion .

No free fluid in abdomen and pelvis.

Visualized bowel loops are gaseously distended appear grossly normal and show normal peristalsis. No evidence of enlarged lymph nodes.

IMPRESSION:

- **Mild splenomegaly.**

Advice - clinical correlation and further evaluation if clinically indicated.

-----End of Report-----

Dr. SATYAJEET S. GHODAKE
MBBS, MD, DNB, MNAMS.
Regd. No. 2013/05/1417
Consultant Radiologist

This report is prepared and physically checked by DR SATYAJEET before dispatch.

Investigations have their own limitations. Solitary radiological investigation never leads to a final diagnosis. They should be always correlated with clinical and pathological examinations.

Click here to view images <http://202.143.96.162/Suburban/Viewer?ViewerType=3&AccessionNo=2022031209480461>

PUNE LAB ADDRESS: Seraph Centre, Opp. BSNL Exchange, Shahu College Road, Off Pune-Satara Road, Behind Panchami Hotel, Pune - 411009

CENTRAL PROCESSING LAB: 2nd Floor, Aston, Sundervan Complex, Above Mercedes Showroom, Andheri West, Mumbai - 400053

HEALTHLINE - MUMBAI: 022-6170-0000 | **OTHER CITIES:** 1800-266-4343 | **For Feedback -** customerservice@suburbandiagnosics.com | www.suburbandiagnosics.com



CID : 2207126817
Name : Mr PODDAR NAVIN PRAKASH
Age / Sex : 53 Years/Male
Ref. Dr :
Reg. Location : Pimple Saudagar, Pune Main Centre

Reg. Date : 12-Mar-2022 / 10:57
Reported : 12-Mar-2022 / 17:03

X-RAY CHEST PA VIEW

Trachea is central.
Slightly prominent bronchovascular markings are noted bilaterally.
Visualized bilateral lung fields otherwise appear grossly normal.
Both hila appear normal.
Cardio-aortic silhouette has grossly normal appearance for age.
Diaphragmatic domes have normal contours and positions.
Bilateral costophrenic and cardiophrenic angles appear normal.
Visualized bony thorax and soft-tissues are grossly normal for age.

IMPRESSION :

No other significant abnormality detected.

Advice – Clinical correlation and further evaluation if clinically indicated.

Dr. SATYAJEET S. GHODAKE
MBBS, MD, DNB, MNAMS.
Regd. No. 2013/05/1417
Consultant Radiologist

Investigations have their own limitations. Solitary radiological investigation never leads to a final diagnosis. They should be always correlated with clinical and pathological examinations.

This report is prepared and physically checked by DR SATYAJEET before dispatch.

Click here to view images <http://202.143.96.162/Suburban/Viewer?ViewerType=3&AccessionNo=2022031209480453>

 भारत सरकार
GOVERNMENT OF INDIA



नवीन प्रकाश पोतदार
Navin Prakash Poddar
जन्म वर्ष/YoB: 1968
पुरुष Male



5302 6705 8034

आधार - सामान्य माणसाचा अधिकार

Handwritten signature in blue ink

SUBURBAN DIAGNOSTIC (I) PVT. LTD.
"Fortuna" Ground Floor, Near Shivar
Garden Chowk Next to Radha Krishna
Hotel, Pimple Saudagar, Pune-411 027.