

DEPARTMENT OF RADIOLOGY X-RAY OF CHEST (PA) VIEW

MR. NO- FSIN.0000000

SEX-FEMALE

NAME: -MRS. SARBANI SARKAR

EXAMINATION DATE- 05.06.2021

AGE- 26 YRS

REPORT DATE- 05.06.2021

REF DR. SELF

FINDINGS:

- Bilateral lung fields are clear.
- Tracheal shadow is in the midline.
- Bilateral CP angle are clear
- Both hilum appear normal .
- CTR appears normal .
- No definite bone fracture is noted.


DR. ARNAB MANDAL

MD, Physician, PGDUS (Delhi) CEBT-USG (WBUHS KOLKATA)
Fellow of Jefferson Ultrasound Radiology and Education Institute
Philadelphia Ex-Radiology Resident (S.E.Railway)
Regd.No:72022(WBMC)

APOLLO CLINIC @ OM TOWER
Opp. of Rabindra Bharati University
Licensee : Satyam Credit Pvt. Ltd.
36C, B. T. Road, Kolkata - 700 002
E-mail : sinthimor@theapolloclinic.com
satyamcreditpvtltd@gmail.com



033 2556 3333



033 2556 5555



+91 98521 66666



+91 74392 97827

NAME: MRS. SARBANI SARKAR	AGE:26YRS	SEX:FEMALE
REF BY: SELF (CORPORATE)	MR NO:FSIN-0000	DATE: 05.06.2021

ULTRASOUND OF WHOLE ABDOMEN

LIVER: Liver is normal in size, shape, outline and echotexture. The intrahepatic tubular structures are normal.No focal area of altered echogenicity is noted. The porta hepatis is normal. The common bile duct at porta measures **0.29cm**. The portal vein measures **0.66cm** at porta.

GALL BLADDER: Gall bladder is distended .Wall is normal . No calculus or mass is seen within the gall bladder.

PANCREAS: It is normal size, Shape, Outline and echotexture. Pancreatic duct is not dilated.

SPLEEN: It is normal in size **10.33cm**, Shape, Outline and echotexture. No parenchymal lesion is noted.

RIGHT KIDNEY: Right kidney are normal in position, size, shape, outline and echotexture. The cortico medullary differentiation is maintained. No calculus or hydronephrosis is seen.

RIGHT KIDNEY- measures- **8.84cm**.

LEFT KIDNEY: Left kidney are normal in position, size, shape, outline and echotexture. The cortico medullary differentiation is maintained. No calculus or hydronephrosis is seen.

LEFT KIDNEY- measures- **10.08cm**.

URINARY BLADDER: Suboptimally distended.

UTERUS: It is normal in size,shape and echotexture.It is anteverted. No sol is seen in the myometrium. Uterine cavity is empty. Uterus measures- (**7.37cmX4.31cmX4.45cm**). Endometrial thickness is normal measures- **0.67cm**.


BOTH OVARIES: They are normal in size, shape, outline and echotexture.

RIGHT OVARIES: measures- (**1.61cmX2.26cm**)

LEFT OVARIES: measures- (**2.96cmX2.20cm**)

IMPRESSION:


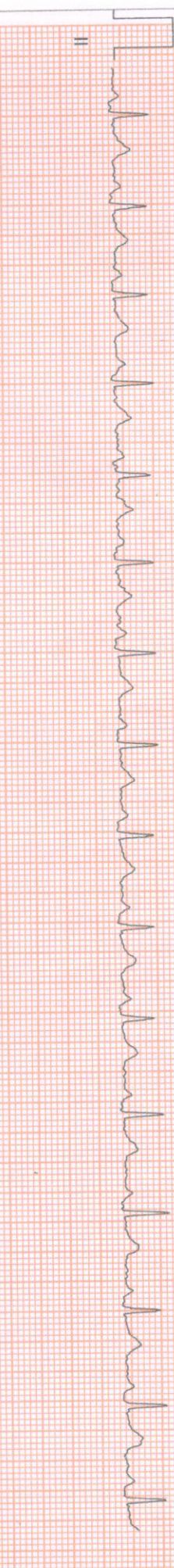
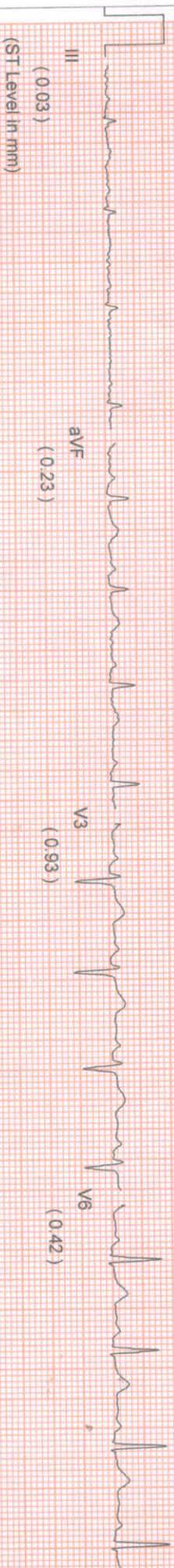
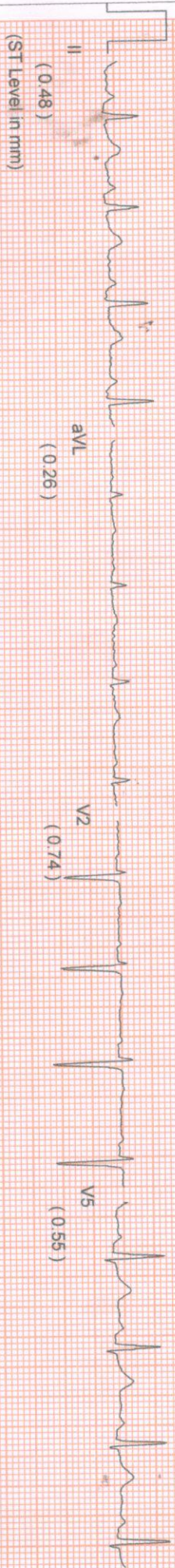
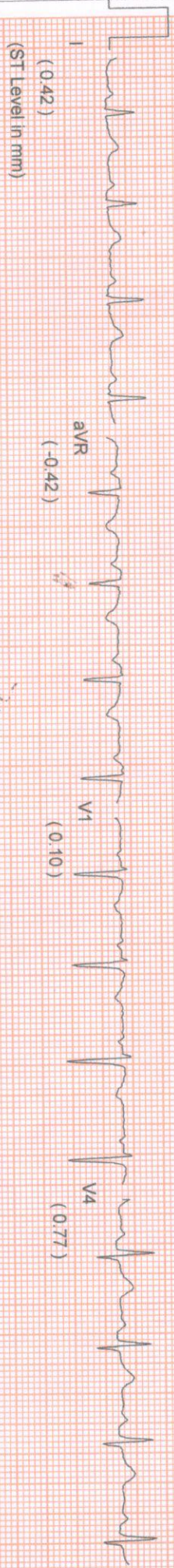
• NO SIGNIFICANT ABNORMALITIES ARE DETECTED IN USG EXAMINATION OF LIVER,GB,PANCREAS,SPLEEN, BOTH KIDNEYS,UB,UT,AND BOTH OVARIES.


DR.SUSMITA CHOWDHURY
MBBS,MD.
CONSULTANT SONOLOGIST

Patient Name: Ms SARBANI SARKAR 26/F

Resting ECG Report

June 05, 2021
Time: 11:38:40
QT/QTc: 0.280 / 0.357 Sec
P-RS-T Axis (36)-(34)-(37) deg
PR Interval: 0.15 sec
QRS Duration: 0.072 Sec
RR Interval: 0.61 sec
HR: 97 bpm
BP: 110/80 mmHg



Comments :-

Sarbani Sarkar

NAME: MRS. SARBANI SARKAR		MR NO: FSIN-0000	DATE : 05.06.2021
AGE: 26 YRS.	SEX: FEMALE	REF BY: SELF(CORPORATE)	

ECG REPORT

HR : 97b/min
AXIS : NORMAL
RHYTHM : SINUS
PR INTERVAL : 0.15 sec
QT INTERVAL : 0.357 sec
QRS DURATION : 0.072 sec
T-WAVE : NORMAL

IMPRESSION:

- RESTING ECG IS WITHIN NORMAL LIMITS.



Dr. SIDDHARTHA KUNDU

MBBS (Cal), PGDCC, CCEBDM

Clinical Cardiologist

Ex Sr Resident, Cardiology Dept

B.R Singh Hospital, Eastern Railwa;

APOLLO CLINIC @ OM TOWER
Opp. of Rabindra Bharati University
Licensee : Satyam Credit Pvt. Ltd.

36C, B.T. Road, Kolkata - 700 002

E-mail : sinthimor@theapolloclinic.com
satyamcreditpvtltd@gmail.com



033 2556 3333



033 2556 5555



+91 98521 66666



+91 74392 97827