

DEPARTMENT OF LABORATORY MEDICINE

Patient Name : Mrs. RUPA KUMARI	Order No : 1000096276
UHID : UHJ A24005597	Registered On : 16/09/2024 08:57:09 AM
Age/Sex : 32/Years Female	Collected On : 16/09/2024 09:07:51 AM
Ward / Bed No :	Reported On : 16/09/2024 01:11:27 PM
Reference : Dr. Preventive Health Check Up	Bill No : OPBJ A240007727
Station : At Hospital	Mobile No : 8896756311
Payer Name : Mediwheel	Report Status : Final Report

Test Name	Result	Unit	Bio. Ref. Interval
<u>BIOCHEMISTRY</u>			
FASTING GLUCOSE (Method: Hexokinase)	109	mg/dL	ADA Guidelines < 100 mg/dl - Normal 100 to 125 mg/dl - Prediabetes ≥ 126 mg/dl - Diabetes
POST PRANDIAL GLUCOSE (Method: Hexokinase)	90	mg/dL	70-140
GLYCOSYLATED HAEMOGLOBIN (HBA1C)			Sample: Whole blood (EDTA)
HBA1C (Method: HPLC)	5.1	%	ADA Guidelines < 5.7% - Normal 5.7 to 6.4% - Prediabetes ≥ 6.5% - Diabetes
Estimated Average Glucose (eAG) (Method: Calculated)	100	mg/dL	
THYROID PROFILE (TOTAL T3, TOTAL T4 & TSH)			Sample: Serum
TOTAL T3 (Method:CLIA)	0.91	ng/mL	0.87-1.78
TOTAL T4 (Method:CLIA)	10.58	ng/dL	5.1-14.1
THYROID STIMULATING HORMONE (TSH) (Method:CLIA: Ultra-sensitive)	1.54	μIU/mL	0.34 - 5.60 μIU/mL (Non Pregnant) 0.3 - 4.5 μIU/mL (I trimester) 0.5 - 5.2 μIU/mL (II & III trimester)
LIPID PROFILE			Sample: Serum
TOTAL CHOLESTEROL (Method:CHOD-POD)	163	mg/dL	ATP III Guidelines < 200 - Desirable 200-239 - Borderline high ≥ 240 - High
TRIGLYCERIDES (Method:Enzymatic GPO-POD)	80	mg/dL	< 150 - Normal 150-199 - Borderline High 200-499 - High ≥ 500 - Very High
HDL CHOLESTEROL (Method:ENZYMATIC METHOD)	35.9	mg/dL	< 40 - Low ≥ 60 - High

DEPARTMENT OF LABORATORY MEDICINE

Patient Name	: Mrs. RUPA KUMARI	Order No	: 1000096276
UHID	: UHJ A24005597	Registered On	: 16/09/2024 08:57:09 AM
Age/Sex	: 32/Years Female	Collected On	: 16/09/2024 09:07:51 AM
Ward / Bed No	:	Reported On	: 16/09/2024 01:11:27 PM
Reference	: Dr. Preventive Health Check Up	Bill No	: OPBJ A240007727
Station	: At Hospital	Mobile No	: 8896756311
Payer Name	: Mediwheel	Report Status	: Final Report

Test Name	Result	Unit	Bio. Ref. Interval
LDL CHOLESTEROL (Method: Calculated)	111.10	mg/dL	<100 - Optimal 100-129 - Near or above optimal 130-159 - Borderline high 160-189 - High ≥190 - Very high
VLDL CHOLESTEROL (Method: Calculated)	16.00	mg/dL	< 30
TOTAL CHOLESTEROL : HDL RATIO (Method: Calculated)	4.54		Low Risk: 3.3 - 4.4 Average Risk: 4.5 - 7.1 Moderate Risk: 7.2 - 11.0
LDL/HDL CHOLESTEROL RATIO (Method: Calculated)	3.09		< 2.5 Optimal
NON HDL CHOLESTEROL (Method: Calculated)	127.10	mg/dL	< 130
URIC ACID (Method:Uricase - POD(Enzymatic))	6.2	mg/dL	2.6-6.0
BLOOD UREA NITROGEN(BUN) (Method:Urease GLDH - Kinetic)	12	mg/dL	7.93-20.07
CREATININE (Method:Modified Jaffe, Kinetic)	0.70	mg/dL	0.6-1.1
LIVER FUNCTION TEST			
TOTAL BILIRUBIN (Method:Dichlorophenyl Diazotization)	1.08	mg/dL	0.3-1.2
DIRECT BILIRUBIN (Method:Dichlorophenyl Diazotization)	0.21	mg/dL	0.0-0.2
INDIRECT BILIRUBIN (Method: Calculated)	0.87	mg/dL	0.2-1.0
TOTAL PROTEIN (Method:BIURET)	7.0	g/dL	6.6-8.3
ALBUMIN (Method:BCG)	4.43	g/dL	3.5-5.2
GLOBULIN (Method: Calculated)	2.57	g/dL	2.3-3.5

Sample: Serum

DEPARTMENT OF LABORATORY MEDICINE

Patient Name : Mrs. RUPA KUMARI	Order No : 1000096276
UHID : UHJ A24005597	Registered On : 16/09/2024 08:57:09 AM
Age/Sex : 32/Years Female	Collected On : 16/09/2024 09:07:51 AM
Ward / Bed No :	Reported On : 16/09/2024 01:11:27 PM
Reference : Dr. Preventive Health Check Up	Bill No : OPBJ A240007727
Station : At Hospital	Mobile No : 8896756311
Payer Name : Mediwheel	Report Status : Final Report

Test Name	Result	Unit	Bio. Ref. Interval
AG RATIO (Method: Calculated)	1.72		2:1
SERUM SGOT (Method:IFCC without P5P)	25	U/L	< 35
SERUM SGPT (Method:IFCC without P5P)	27	U/L	< 35
ALKALINE PHOSPHATASE, SERUM (Method:PNPP AMP Buffer)	76	U/L	46-122
GGT (Method:IFCC)	16	U/L	< 38



Dr. Shobha Emmanuel
MBBS, M.D(Pathology)
CONSULTANT PATHOLOGIST
KMC:66136

DEPARTMENT OF LABORATORY MEDICINE

Patient Name : Mrs. RUPA KUMARI	Order No : 1000096276
UHID : UHJ A24005597	Registered On : 16/09/2024 08:57:09 AM
Age/Sex : 32/Years Female	Collected On : 16/09/2024 09:07:51 AM
Ward / Bed No :	Reported On : 16/09/2024 01:11:27 PM
Reference : Dr. Preventive Health Check Up	Bill No : OPBJ A240007727
Station : At Hospital	Mobile No : 8896756311
Payer Name : Mediwheel	Report Status : Final Report

Test Name	Result	Unit	Bio. Ref. Interval
-----------	--------	------	--------------------

HAEMATOLOGY
COMPLETE BLOOD COUNT(CBC)

Sample: Whole blood (EDTA)

HAEMOGLOBIN (Method:Photometric Measurement: Oxyhemoglobin method)	12.14	g/dL	12-16
PACKED CELL VOLUME/HEMATOCRIT (PCV/HCT) (Method: Calculated)	37.1	%	37-47
TOTAL WBC COUNT (TLC) (Method:Coulter Principle)	3600	Cells/Cum	4000-11000
DIFFERENTIAL COUNT			
NEUTROPHILS (Method:Optical/Impedance)	52.36	%	40-75
LYMPHOCYTES (Method:Optical/Impedance)	39.11	%	20-45
EOSINOPHILS (Method:Optical/Impedance)	1.29	%	0-6
MONOCYTES (Method:Optical/Impedance)	6.82	%	2-10
BASOPHILS (Method:Optical/Impedance)	0.42	%	0-2
RED BLOOD CORPUSCLES(RBC) (Method:Coulter Principle)	4.22	million/cum	4.0-5.2
MCV (Method:Derived from RBC Histogram)	87.8	fL	78-100
MCH (Method: Calculated)	28.8	pg	27-31
MCHC (Method: Calculated)	32.7	g/dL	31-37
RDW - CV (Method: Calculated)	14.7	%	11.5-14.5
PLATELET COUNT (Method:Electrical Impedance)	1.74	Lakhs/Cum	1.5-4.5

DEPARTMENT OF LABORATORY MEDICINE

Patient Name : Mrs. RUPA KUMARI	Order No : 1000096276
UHID : UHJ A24005597	Registered On : 16/09/2024 08:57:09 AM
Age/Sex : 32/Years Female	Collected On : 16/09/2024 09:07:51 AM
Ward / Bed No :	Reported On : 16/09/2024 01:11:27 PM
Reference : Dr. Preventive Health Check Up	Bill No : OPBJ A240007727
Station : At Hospital	Mobile No : 8896756311
Payer Name : Mediwheel	Report Status : Final Report

Test Name	Result	Unit	Bio. Ref. Interval
MEAN PLATELET VOLUME(MPV) (Method:Derived from PLT Histogram)	11.68	fl	9-13
PLATELET DISTRIBUTION WIDTH (PDW) (Method: Calculated)	17.2	fl	9-19
ERYTHROCYTE SEDIMENTATION RATE(ESR) (Method:Modified Westergren Method)	22	mm/hour	1-20
BLOOD GROUPING & RH TYPING			Sample: Whole blood (EDTA)
ABO Group (Method:Agglutination Method)	A		
Rh Factor (Method:Agglutination Method)	Positive		

Interpretation Notes

Note: Both forward and reverse grouping performed



Dr. Shobha Emmanuel
MBBS, M.D(Pathology)
CONSULTANT PATHOLOGIST
KMC:66136

DEPARTMENT OF LABORATORY MEDICINE

Patient Name : Mrs. RUPA KUMARI	Order No : 1000096276
UHID : UHJ A24005597	Registered On : 16/09/2024 08:57:09 AM
Age/Sex : 32/Years Female	Collected On : 16/09/2024 09:07:51 AM
Ward / Bed No :	Reported On : 16/09/2024 01:11:27 PM
Reference : Dr. Preventive Health Check Up	Bill No : OPBJ A240007727
Station : At Hospital	Mobile No : 8896756311
Payer Name : Mediwheel	Report Status : Final Report

Test Name	Result	Unit	Bio. Ref. Interval
-----------	--------	------	--------------------

CLINICAL PATHOLOGY
URINE EXAMINATION, ROUTINE

Sample: Urine

PHYSICAL EXAMINATION

VOLUME	20	mL	
COLOUR	Pale Yellow		
APPEARANCE	Clear		
PH	5.0		5.0-8.0
SPECIFIC GRAVITY	1.020		1.005-1.030

CHEMICAL EXAMINATION

PROTEIN (Method:Protein Error of pH Indicator)	Absent		Absent
GLUCOSE (Method:GOD-POD)	Absent		Absent
KETONE BODIES (Method:Nitroprusside method/ Rothera's test)	Absent		Absent
BILIRUBIN (Method:DIAZO/FOUCHET'S TEST)	Negative		Negative
BILE SALT (Method:Hay's sulfur test)	Absent		Absent
NITRITE (Method:Griess method)	Negative		Negative
UROBILINOGEN (Method:Azo coupling method)	Normal		
LEUKOCYTE ESTERASE (Method:Leukocyte Esterase activity)	Negative		Negative
BLOOD (Method:Peroxidase Reaction)	Negative		Negative

MICROSCOPIC EXAMINATION


DEPARTMENT OF LABORATORY MEDICINE

Patient Name	: Mrs. RUPA KUMARI	Order No	: 1000096276
UHID	: UHJ A24005597	Registered On	: 16/09/2024 08:57:09 AM
Age/Sex	: 32/Years Female	Collected On	: 16/09/2024 09:07:51 AM
Ward / Bed No	:	Reported On	: 16/09/2024 01:11:27 PM
Reference	: Dr. Preventive Health Check Up	Bill No	: OPBJ A240007727
Station	: At Hospital	Mobile No	: 8896756311
Payer Name	: Mediwheel	Report Status	: Final Report

Test Name	Result	Unit	Bio. Ref. Interval
EPITHELIAL CELLS	2-4	/HPF	0-5
PUS CELLS	0-2	/HPF	0-5
RBCs	0-2	/HPF	0-2
CASTS	Nil	/LPF	
CRYSTALS	Nil		
OTHERS	Nil		
URINE SUGAR, FASTING (Method:GOD-POD)	Absent		
URINE SUGAR (POST PRANDIAL)	Absent		

Verified By
Rashmita

---End of Report---



Dr. Shobha Emmanuel
MBBS, M.D(Pathology)
CONSULTANT PATHOLOGIST
KMC:66136

ID: 24-06597
Name: Mrs. rupe kumari

Sex: F
Age: 32 years
Birth date: / /

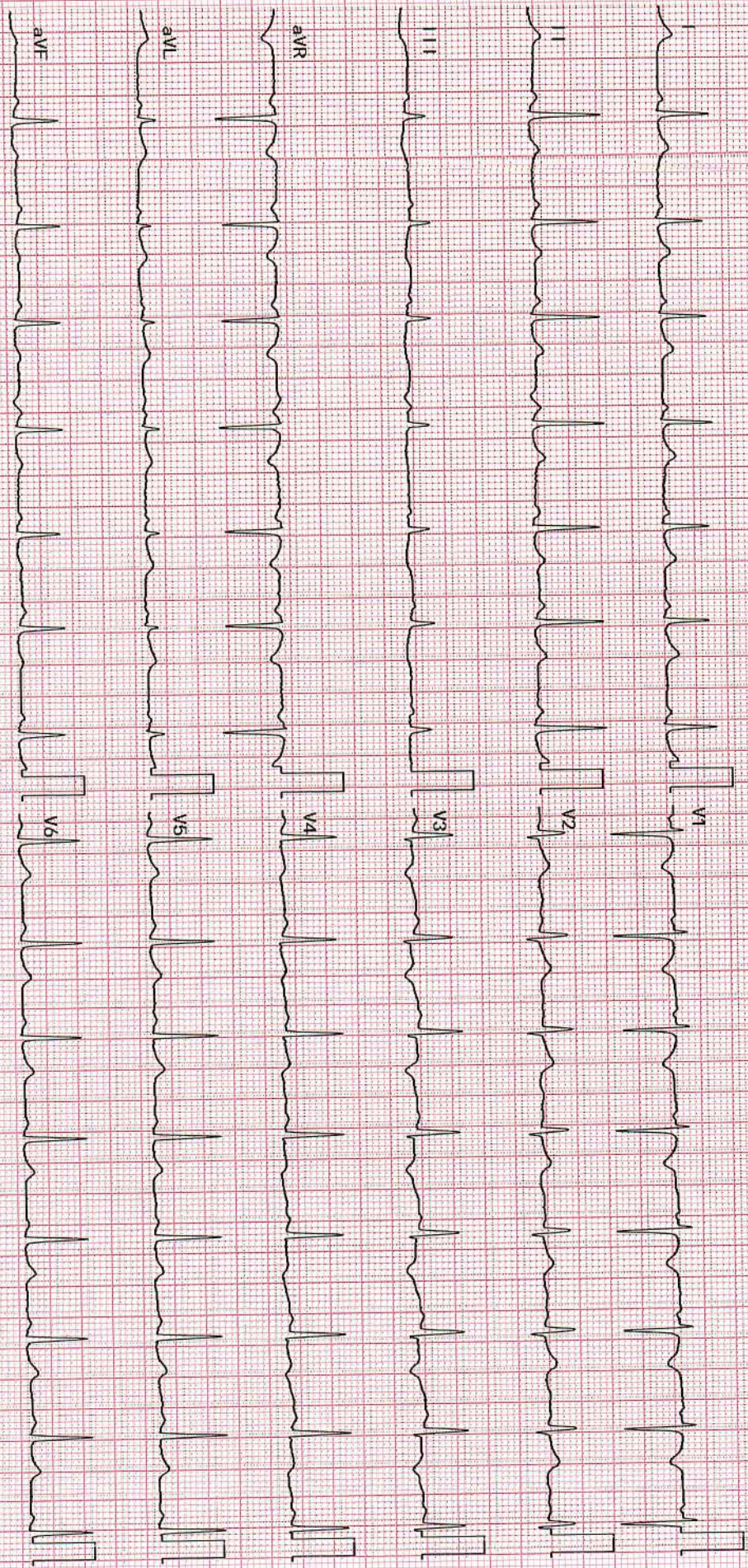
Weight: 50 kg
Height: 150 cm
Heart rate: 92 bpm
R int: 116 ms
RS dur: 68 ms
T/QTe(E) int: 316/366 ms
V/QRS/T axis: 33/48/25
V5/SV1 amp: 1.17/1.06 mV
V5+SV1 amp: 2.23 mV

1100 Sinus rhythm
2210 Short PR interval [PR int. < 120 ms]
4068 Nonspecific T wave abnormality [flat T or negative T (aVF, V3, V4)]
9150 ** abnormal ECG **

Unconfirmed Report
Reviewed by:

10 mm/mV 25 mm/s Filter: H50 D 35 Hz

10 mm/mV





Out Patient Record

NABH No.1
Patient Name : Mrs.RUPA KUMARI

UHID : UHJA24005597

Age / Sex : 32 Years / Female

OP NO/Reg Dt : 16-09-2024 08:57 AM

Spouse / Father Name : KUMAR ANIL

Department :

Address : , , Bengaluru Urban, Karnataka, INDIA,

Referred By :

Consultant : Dr.Preventive Health Check Up

KMC No. :

Complaints / Findings / Observations :

HT: 151 cm
WT: 65.3 kg
BP: 90/80 mmHg
SpO₂: 99%
PP: 97 bpm

Investigations:

Treatment / Care of Plan / Provisional Diagnosis :

Follow Up Advice :

Signature of the Doctor



NABH



No.1

PATIENT NAME :	Mrs.RUPA KUMARI	DATE :	16/09/24
AGE :	32 YEARS	GENDER : FEMALE	PATIENT ID : 5597
REF BY :	CMO	OP/ IP :	HEALTH CHECK

**2D- ECHOCARDIOGRAPHY
M - MODE AND DOPPLER MEASUREMENTS**

(cm)	(cm)	(cm/sec)	
AO : 2.9 (2.5-3.7)	LVIDD : 4.3 (3.5-5.5)	MV EV: 0.6	AV: 0.4 MR : NORMAL
LA : 3.1 (1.9-4.0)	LVIDS : 2.1 (2.4-4.2)	AV : 1.02	AR : NORMAL
RA : 3.6 (<4.4)	IVSD : 0.8 (0.6-1.1)	PV : 0.9	PR : NORMAL
RV : 2.4 (<3.5)	IVSS : 1.0 (0.9-1.2)	TV EV : ----	AV : ---- TR : NORMAL
TAPSE : 2.0 (>1.6)	LVPWD : 0.8 (0.6-1.1)	Diastolic Function : NO LVDD	
	LVPWS : 1.0 (0.9-1.2)		
	EF : 60%		

DESCRIPTIVE FINDINGS

Left Ventricle	: NORMAL
Right Ventricle	: NORMAL
Left Atrium	: NORMAL
Right Atrium	: NORMAL
Wall motion analysis	: NO RWMA
Mitral Valve	: NORMAL
Aortic Valve	: NORMAL
Tricuspid Valve	: NORMAL
Pulmonary Valve	: NORMAL
IAS	: INTACT
IVS	: INTACT
Pericardium	: NORMAL
Other Findings	: IVC NORMAL AND COLLAPSING

IMPRESSION:

NORMAL CHAMBER DIMENSIONS
 NORMAL LV SYSTOLIC FUNCTION EF : 60%
 NORMAL LV DIASTOLIC FUNCTION
 NO PULMONARY ARTERY HYPERTENSION
 NO REGIONAL WALL MOTION ABNORMALITIES
 NO CLOTS/ PERICARDIAL EFFUSION /VEGETATION



DR. RAHUL S PATIL
CONSULTANT CARDIOLOGIST



NABH



No.1



DEPARTMENT OF RADIODIAGNOSIS

Name	Rupa Kumari	Date	16/09/24
Age	32 years	Hospital ID	UHJA24005597
Sex	Female	Ref.	Health check

RADIOGRAPH OF THE CHEST (PA – VIEW)

FINDINGS:

Bilateral lung fields are normal.

Bilateral costo-phrenic angles are normal.

Cardia and mediastinal contours are normal.

The bony thorax is grossly normal.

IMPRESSION:

- No radiographic abnormality.

Dr. Elluru Santosh Kumar
Consultant Radiologist



NABH

No.1

DEPARTMENT OF RADIODIAGNOSIS

Name	Rupa Kumari	Date	16/09/24
Age	32 years	Hospital ID	UHJA24005597
Sex	Female	Ref.	Health check

ULTRASOUND ABDOMEN AND PELVIS

FINDINGS:

Liver is normal in size and *shows mildly increased echopattern*. No intra or extra hepatic biliary duct dilatation. No focal lesions. **Portal vein** is normal in size, course and caliber. **CBD** is not dilated.

Gall bladder is contracted. No obvious calculi are seen in the visualized portion of the lumen. Suggested review scan if any gallbladder pathology is suspected.

Pancreas - Visualized part of the pancreatic head and body appears normal in size, contour and echogenicity. Rest of the pancreas is obscured by bowel gas.

Spleen is normal in size, shape, contour and echopattern. No evidence of mass or focal lesions.

Right Kidney is normal in size (9.2 x 3.4 cms), position, shape and echopattern. Corticomedullary differentiation is maintained. No evidence of calculi or hydronephrosis.

Left Kidney is normal in size (9.1 x 3.2 cms), position, shape and echopattern. Corticomedullary differentiation is maintained. No evidence of calculi or hydronephrosis.

Retroperitoneum- Visualized aorta appeared normal. No obvious enlarged para-aortic nodes.

Urinary Bladder is distended, normal in contour and wall thickness. No evidence of calculi.

Uterus is anteverted and normal in size, measures 8.6 x 3.0 x 5.6 cms. Myometrial and endometrial echoes are normal. Endometrium measures 10.6 mm.

Right ovary is normal in size and echopattern, measures 2.8 cc.

Left ovary is normal in size and echopattern, measures 4.7 cc.

Both adnexa: Normal. No mass is seen.

There is no ascites or pleural effusion. Appendix could not be localized. No RIF probe tenderness.

IMPRESSION:

- Mild fatty infiltration of liver (Grade I).
- No other definite sonological abnormality detected.

UNITED HOSPITAL (A Unit of United Brothers Healthcare Services Private Limited) Kumar
Consultant Radiologist