

**Facilities:**

All clinical Biomedical & Hematology Investigations including Bone Marrow Examination  
VPT, Podiascan & Complete Foot Care (First Time in Purvanchal)  
All Hormonal Investigation by Chemiluminescent Method  
Visceral Fat by (AB-140) Ambulatory BP Monitoring  
CGMS & Insulin Pump Available  
PFT, 2D-ECHO (Color Doppler), Holter, TMT, Cardiac-3 available  
VIA, VILI, Colposcopy available  
Special Endocrinological Investigation Protocols.

ISO 9001:2008 Certified  
Mobile: 9389994334, 9554572190, 9453837595



# Panacea Pathology

## Clinical Reference Lab

Persistence, Preparedness and Precision  
EQAS (CMC Vellore Attached) & IQAS System  
पूर्वाचल की सर्वोत्तम गुणवत्ता वाली पैथोलॉजी

PATIENT NAME : KIRAN MAURYA

AGE/GENDER : 37YRS/FEMALE

REFD BY DR. : ARCO FEMI HEALTHCARE LTD.

RECEIVED DATE : 30-03-2023 (10:00 AM)

SAMPLE : BLOOD & URINE

REPORT DATE : 01-04-2023 (04:00 PM)

## PATHOLOGY REPORT

### COMPLETE BLOOD COUNT (CBC)

TEST	LAB TEST VALUES	NORMAL RANGE
<b>HEMOGRAM</b>		
HEMOGLOBIN (FLOW CYTOMETRY)	12.3	13 – 16 gm/dl
TOTAL LEUCOCYTE COUNT (TLC)	8,600	4000 – 11000
RBC COUNT	4.49	3.5 – 5.5
PCV (HCT)	39.6	37 – 47
MCV	88.1	80 – 95
MCH	27.5	28 – 34
MCHC	31.2	30 – 36
PLATELET COUNT	1,82,000	1,50,000 – 4,00,000
E.S.R. (WINTROBE FIRST HOURS)	18.0	20 mm/1 <sup>st</sup> hr
<b>DIFFERENTIAL LEUCOCYTE</b>		
NEUTROPHILS	61	40 – 75%
LYMPHOCYTES	34	20 – 45%
EOSINOPHILS	02	1 – 6%
MONOCYTES	03	2 – 8%
BASOPHILS	00	< 2%

### FASTING/RANDOM BLOOD SUGAR

TEST	LAB TEST VALUES	NORMAL RANGE
<b>FBS/RBS</b>		
RANDOM BLOOD SUGAR	261.0	125-140 mg/dl
FASTING BLOOD SUGAR	138.0	70-125 mg/dl

### GLYCOSYLATED HEMOGLOBIN (HBA1C)

TEST	LAB TEST VALUES	NORMAL RANGE
HBA1C	8.6	Normal : <5.97 % Good Control : 5.97 – 6.81% Fair Control : 6.81 – 7.65% Poor Control : >7.65%

PAGE 1

Lab Technician

**PANACEA HOSPITAL**  
(A UNIT OF AAROH HEALTH CARE PVT. LTD)  
REG. NO.: AL-1500  
B.36/44 B-4, KABIR NAGAR  
DURGAKUND, VARANASI  
M.D. Pathology

Timing : 8.00 a.m. to 9.00 p.m. (Sunday 8.00 a.m. to 3.00 p.m.)

This Report is not valid for medico legal purpose

**Note:** These tests have technical limitations. Clinico-pathological interpretation is necessary. In case of any disparity test may be repeated immediately.

Address : 36/44 FK Kabir Nagar, Durgakund, Varanasi – 221005

Email: [dramishra@gmail.com](mailto:dramishra@gmail.com), [drpallaviojha@gmail.com](mailto:drpallaviojha@gmail.com) Website: [panaceahospital.org](http://panaceahospital.org)

**Facilities:**

All clinical Biomedical & Hematology Investigations including Bone Marrow Examination  
VPT, Podiascan & Complete Foot Care (First Time in Purvanchal)  
All Hormonal Investigation by Chemiluminescent Method  
Visceral Fat by (AB-140) Ambulatory BP Monitoring  
CGMS & Insulin Pump Available  
PFT, 2D-ECHO (Color Doppler), Holter, TMT, Cardiac-3 available  
VIA, VILI, Colposcopy available  
Special Endocrinological Investigation Protocols.

ISO 9001:2008 Certified  
Mobile: 9389994334, 9554572190, 9453837595



# Panacea Pathology

## Clinical Reference Lab

Persistence, Preparedness and Precision  
EQAS (CMC Vellore Attached) & IQAS System  
पूर्वांचल की सर्वोत्तम गुणवत्ता वाली पैथोलॉजी

PATIENT NAME : KIRAN MAURYA

AGE/GENDER : 37YRS/FEMALE

REFD BY DR. : ARCO FEMI HEALTHCARE LTD.

RECEIVED DATE : 30-03-2023 (10:00 AM)

SAMPLE : BLOOD & URINE

REPORT DATE : 01-04-2023 (04:00 PM)

### PATHOLOGY REPORT

#### LIPID PROFILE, SERUM

TEST	LAB TEST VALUES	NORMAL RANGE
<b>BLOOD CHEMISTRY</b>		
TOTAL CHOLESTEROL (SERUM)	125.0	Desirable:- &lt; 200 mg/dl Borderline:- 200 – 239 mg/dl High:- &gt; 240 mg/dl
TRIGLYCERIDES (SERUM)	135.0	35 – 170 mg/dl
HDL CHOLESTEROL (SERUM)	38.0	35.30 – 79.50 mg/dl
LDL CHOLESTEROL (SERUM)	60.0	&lt; 130 mg/dl
VLDL	27.0	&lt; 40 mg/dl
CHOLESTROL/HDL RATIO	3.28	&lt; 3.0 Low Risk Ratio 3.0 – 5.0 Avg Risk &lt; 5.0 High Risk
LDL/HDL RATIO	1.57	&lt; 3 Ratio

#### BLOOD GROUP

TEST	LAB TEST VALUES
<b>BLOOD GROUP ABO &amp; RH FACTOR</b>	
BLOOD GROUP	"B"
RH FACTOR	POSITIVE

#### LIVER PROFILE TEST, SERUM

TEST	LAB TEST VALUES	NORMAL RANGE
<b>BIO CHEMISTRY</b>		
TOTAL BILIRUBIN	0.70	0.0 – 1.1 mg/dl
DIRECT BILIRUBIN	0.25	0.0 – 0.2 mg/dl
INDIRECT BILIRUBIN	0.45	< 0.90 mg/dl
SGOT (AST)	21.6	0 – 52 mg/dl
SGPT (ALT)	23.0	0 – 39 mg/dl
GGT (GYT)	21.0	< 55 U/L

#### THYROID PROFILE (T3, T4, TSH)

TEST	LAB TEST VALUES	NORMAL RANGE
<b>THYROID FUNCTION TEST</b>		
T3	1.16	0.60 – 1.81 ng/ml
T4	7.56	4.50 – 10.90 ug/dl
TSH	2.16	0.39 – 6.10 uIU/mL

PAGE 2

Lab Technician

**PANACEA HOSPITAL**  
(A UNIT OF AAROHA HEALTH CARE PVT. LTD.)  
REG. NO.: AL-1500  
B.36/44, B-1, KABIR NAGAR,  
DURGAKUND, VARANASI

Timing : 8.00 a.m. to 9.00 p.m. (Sunday 8.00 a.m. to 3.00 p.m.)

This Report is not valid for medico legal purpose

**Note:** These tests have technical limitations. Clinico-pathological interpretation is necessary. In case of any disparity test may be repeated immediately.

Address : 36/44 FK Kabir Nagar, Durgakund, Varanasi – 221005

Email: [dramishra@gmail.com](mailto:dramishra@gmail.com), [drpallaviojha@gmail.com](mailto:drpallaviojha@gmail.com) Website: [panaceahospital.org](http://panaceahospital.org)

**Facilities:**

All clinical Biomedical & Hematology Investigations including Bone Marrow Examination  
VPT, Podiascan & Complete Foot Care (First Time in Purvanchal)  
All Hormonal Investigation by Chemiluminescent Method  
Visceral Fat by (AB-140) Ambulatory BP Monitoring  
CGMS & Insulin Pump Available  
PFT, 2D-ECHO (Color Doppler), Holter, TMT, Cardiac-3 available  
VIA, VILI, Colposcopy available  
Special Endocrinological Investigation Protocols.

ISO 9001:2008 Certified  
Mobile: 9389994334, 9554572190, 9453837595



# Panacea Pathology

## Clinical Reference Lab

Persistence, Preparedness and Precision  
EQAS (CMC Vellore Attached) & IQAS System  
पूर्वाचल की सर्वोत्तम गुणवत्ता वाली पैथोलॉजी

PATIENT NAME : KIRAN MAURYA

AGE/GENDER : 37YRS/FEMALE

REFD BY DR. : ARCO FEMI HEALTHCARE LTD.

RECEIVED DATE : 30-03-2023 (10:00 AM)

SAMPLE : BLOOD & URINE

REPORT DATE : 01-04-2023 (04:00 PM)

## PATHOLOGY REPORT

### RENAL & KIDNEY PROFILE, SERUM

TEST	LAB TEST VALUES	NORMAL RANGE
<b>RENAL FUNCTION TESTS</b>		
BLOOD UREA NITROGEN (BUN)	8.00	10 – 50 mg/dl
SERUM CREATININE	0.63	0.60 – 1.60 mg/dl
URIC ACID	4.16	3.60 – 7.70 mg/dl
ALKALINE PHOSPHATASE (ALP)	67.0	142 – 353 mg/dl
TOTAL PROTIENS	7.44	0 – 39 mg/dl
ALBUMIN	4.21	3.8 – 5.4 mg/dl
SERUM GLOBULIN	3.23	2.1 – 3.5 mg/dl
AG RATIO	1.30	-

### URINE ROUTINE EXAMINATION

TEST	LAB TEST VALUES	NORMAL RANGE
<b>PHYSICAL EXAMINATION</b>		
QUANTITY	30	ML
COLOUR	STRAW	PALE YELLOW
APPEARANCE	CLEAR	CLEAR
SPECIFIC GRAVITY	1.010	1.01 – 1.03
PH	5.5	4.7 – 7.5
<b>CHEMICAL EXAMINATION</b>		
GLUCOSE	Not Detected	Not Detected
PROTEIN	NIL	Not Detected
<b>MICROSCOPIC EXAMINATION</b>		
PUS CELLS	02-03	0-5
RBC	Not Detected	Not Detected
EPITHELIAL CELLS	01-02	0-5
CASTS	Not Detected	Not Detected
CRYSTALS	Not Detected	Not Detected
BACTERIA	Not Detected	Not Detected

----- End of Report -----

Lab Technician

*P. Sharma*  
**PANACEA HOSPITAL**  
A UNIT OF AAROH HEALTH CARE PVT. LTD.  
REG. NO.: AL-1500  
B.36/44 B-4, KABIR NAGAR  
DURGAKUND, VARANASI  
M.D. Pathology

Timing : 8.00 a.m. to 9.00 p.m. (Sunday 8.00 a.m. to 3.00 p.m.)

This Report is not valid for medico legal purpose

**Note:** These tests have technical limitations. Clinico-pathological interpretation is necessary. In case of any disparity test may be repeated immediately.

Address : 36/44 FK Kabir Nagar, Durgakund, Varanasi – 221005

Email: [dramishra@gmail.com](mailto:dramishra@gmail.com), [drpallaviojha@gmail.com](mailto:drpallaviojha@gmail.com) Website: [panaceahospital.org](http://panaceahospital.org)



# PANACEA HOSPITAL

B 36/44 F.K KABIR NAGAR, DURGAKUND  
TOLLFREE NO-18001233070.  
Whatsapp No - 8795832852  
www.piiire.org



*Base*

## OP Slip

Print Date : 30-Mar-2023 10:35AM



<b>UHID No</b> :- UD-22230004219	<b>OP No</b> :- OP-22230015419	<b>OP Date</b> :- 30 Mar 2023 10:34AM
<b>Patient Name</b> :- Mrs KIRAN MORYA BOB	<b>Age/Sex</b> :- 37 Y/Female	<b>Mobile No</b> :- 8600108474
<b>Husband</b> :-	<b>Department</b> :- OBST. & GYNAECOLOGY	
<b>Pay Type</b> :- Cash	<b>Consultant</b> :- Dr VANDANA SINGH (MBBS,MS)	
<b>Token No</b> :- NOR. - 1	<b>Paid/Bal</b> :- 0.00 /30.00	
<b>Patient Type</b> :- Normal		
<b>Address</b> :- BOB, varanasi		

BP :- 100/70  
 height :-  
 Weight (kg) :- 60.4  
 BMI :-  
 SPO<sub>2</sub> - 96  
 PR - 85  
 RBS - 145

**Rx**  
 40- nil.  
 stress incontinence.  
 No gynaecological  
 complaint.  
 P<sub>2</sub>+L<sub>2</sub> → ♂ 8y NVD  
 → ♀ 18m NVD.

HbA1C - 8.6  
 FBS - 138.0  
 Lmo - Pap smear ✓  
 - U-C ✓

LMP- 7/3/2023.  
 Regular. 37d/2-3d.  
 (N) flow.  
 Refer to Dr. Ashutosh Sir.

*Delena Singh*

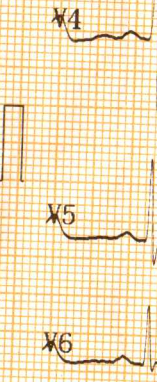
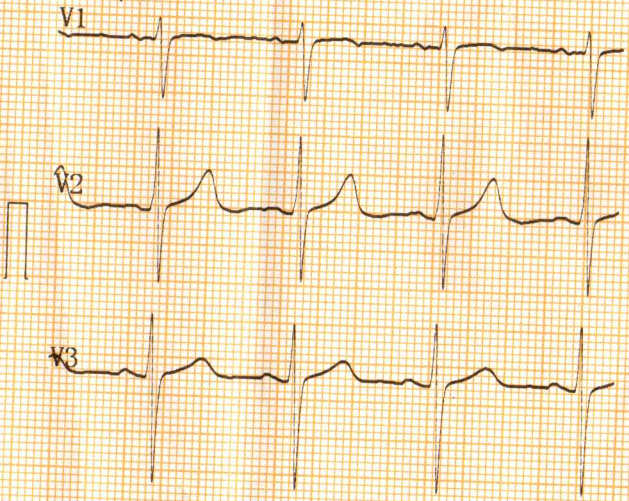
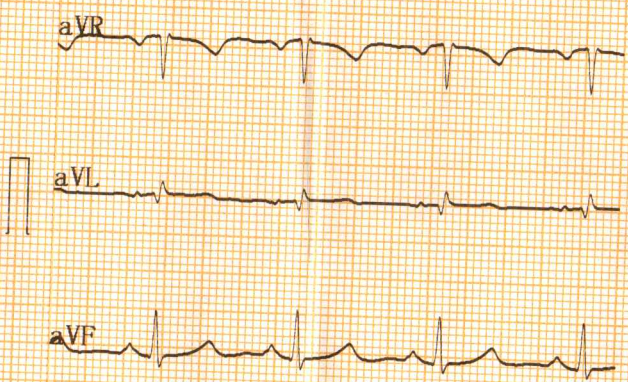
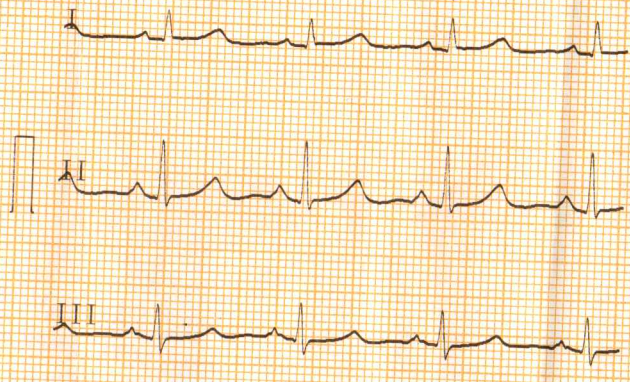
Printed By : Mr NITIN YADAV  
 Created By : Mr NITIN YADAV

AUTO 10mm/mV

10mm/mV

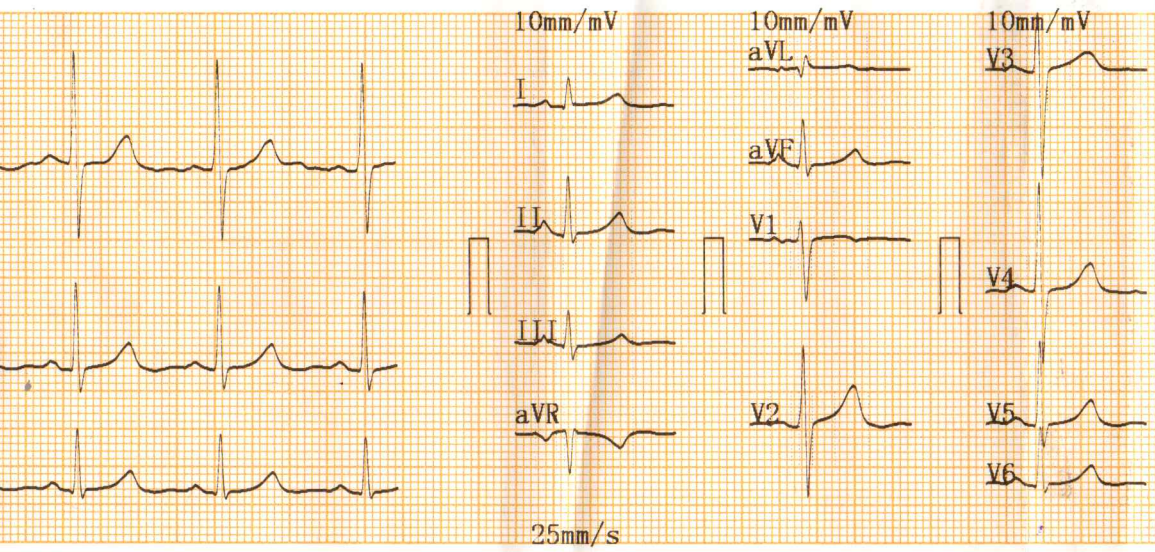
10mm/mV

BPL  
10mm/mV



25mm/s AC50Hz+EMG35Hz+DFT

CARDIART



2022-03-30 10:23

<< Conclusions >>

ID :  
 Name : **Kishan Maurya**  
 Sex : **F**      Age : **37 Y**  
 Height :      Weight : **kg**  
 SYS :  
 DIA :

Normal Sinus Rhythm  
 Cardiac electric axis normal  
 \*\*Report need physician confirm\*\*

HR : 79 bpm  
 PR Interval : 158 ms  
 P Duration : 115 ms  
 QRS Duration : 72 ms  
 T Duration : 181 ms  
 QT/QTc : 375/430 ms  
 P/QRS/T Axis : 68.8/51.8/56.0 deg  
 R(V5)/S(V1) : 1.11/0.79 mV  
 R(V5)-S(V1) : 1.90 mV

*Pallavi*  
**DR. PALLAVI MISHRA**  
 MBBS, MD (GENERAL MEDICINE)  
 MCI Reg. No. 52033

CARDIART

Physician \_\_\_\_\_



# PANACEA HOSPITAL

*A shelter for many hearts A Home for many lives*

(An ISO 9001:2008 Certified Organisation)

Lab Attached with CMC Vellore Under EQAS Scheme

**PATIENT'S NAME : MRS.KIRAN MOURYA**  
**REF. BY : Dr. ASHUTOSH MISHRA(MD)**

**AGE/SEX: 37 Y/F**  
**Thursday, March 30, 2023**

## Echo - Cardiography

MITRAL VALVE Doppler	AML - normal morphology MV Flow - E - 0.6 A-0.4 E/A=1.37	PML - normal morphology MVA - 3.0 cm <sup>2</sup> Mitral Regurgitation - <b>No</b>
TRICUSPID VALVE Doppler	Normal TV Flow -No	Tricuspid Regurgitation - <b>No</b>
PULMONARY VALVE Doppler	Normal PV Flow -No	Pulmonary Regurgitation - No
AORTIC VALVE Doppler	Trileaflet-No AV Flow - no	Aortic Regurgitation - no
MEASUREMENT	Aorta - 15.4 (20-38) mm IVS ed - 8.0 (6 -12) mm LVID ed -32.6 (35 - 55) mm LVPW ed - 14.3 (6 -12) mm OA - 7 (> 5) mm	LA - 35.4 (24-32) mm IVS es -13.1 (6 - 12) mm LVID es - 14.8 (24 - 40) mm LVPW es -14.3 (6 -12) mm EPSS - 4 (< 9) mm

**CONCLUSION** All cardiac chamber dimensions are WNL  
No valvular abnormalities  
Normal LV systolic function present Modified Simpson's method (4C, 2C) (LVEF=66%)  
No diastolic dysfunction present (E/A = 1.37) by tissue Doppler (E/e'=6.2)  
No RWMA  
No pericardial effusion  
Intact IAS / IV  
No PAH  
No intra cardiac mass /thrombus /vegetation

**IMPRESSION** **Normal Echocardiogram**

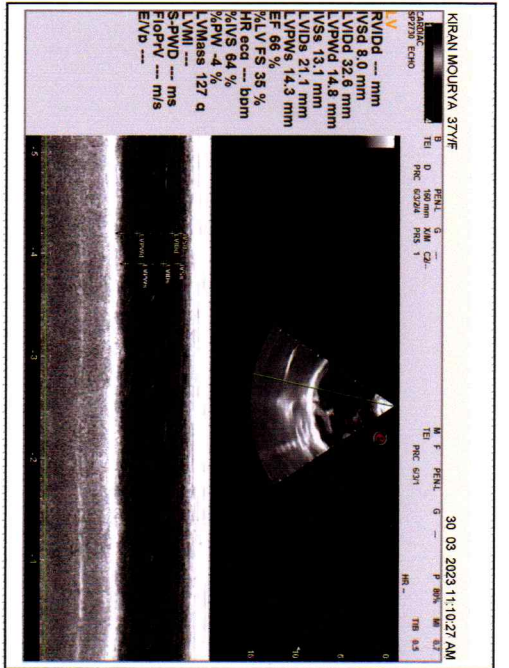
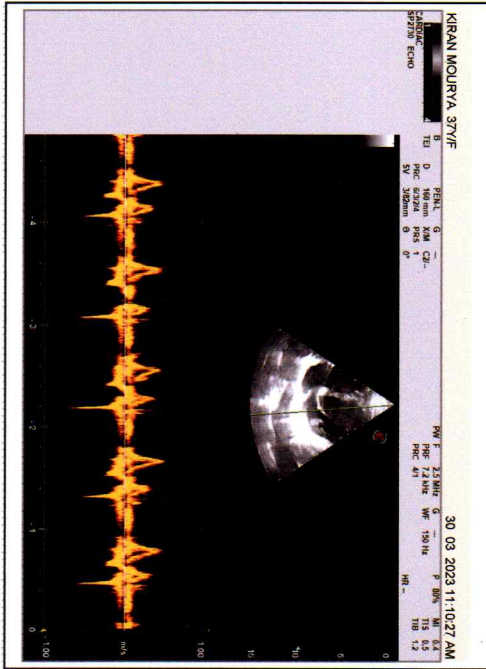
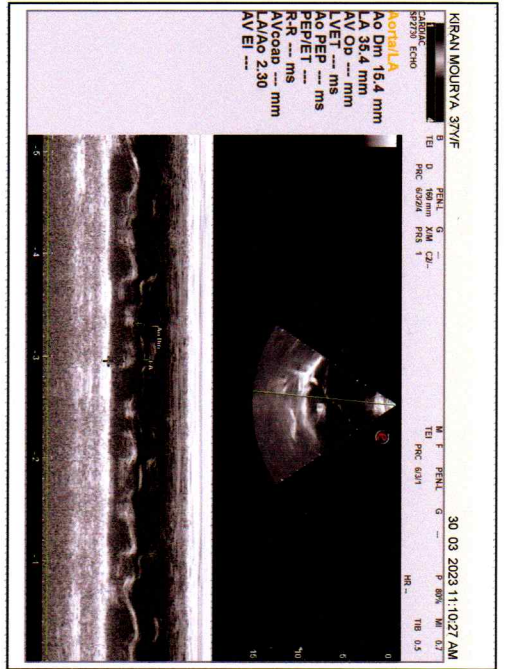
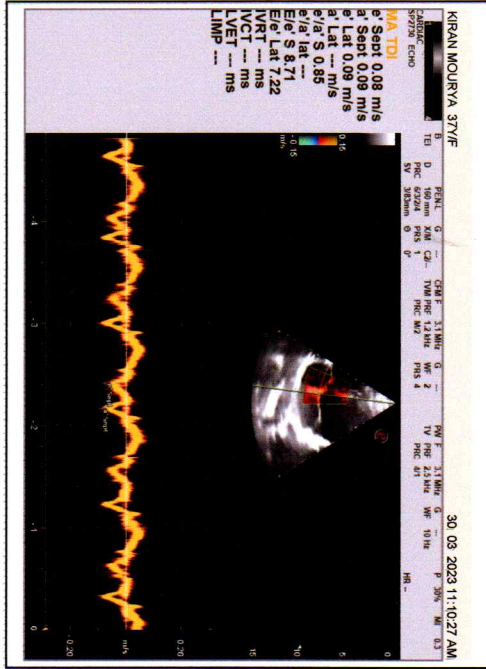
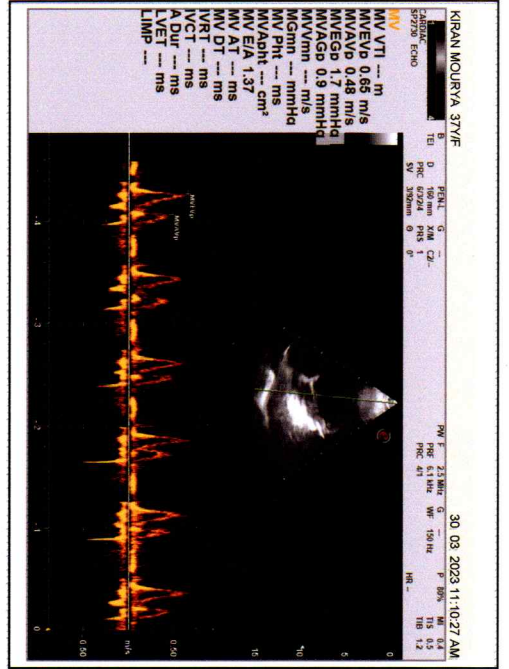
Niraj Mishra  
Physician Assistant  
(PIIRE)

Dr. Pallavi Mishra  
MBBS, MD (MED) Lucknow  
Echocardiography Specialist, MIAE  
Non-invasive cardiologist  
Women Cardiologist  
Diabetocardiologist

**Address : Kabir Nagar (Near Sanjay Shiksha Niketan), Durgakund, Varanasi**

**Mobile : 9554572190 / 9453837595 / Recpn. 9389994334**

**E-mail : dramishra@gmail.com, drpallaviojha@gmail.com, Website: www.piire.org**







Call Now - 1800-123-3070

# PANACEA HOSPITAL

*A shelter for many hearts A Home for many lives*

(An ISO 9001:2008 Certified Organisation)

Lab Attached with CMC Vellore Under EQAS Scheme

**PATIENT'S NAME : KIRAN MOURYA** **AGE/SEX: 37Y/F**  
**REF. BY : Dr. ASHUTOSH MISHRA ( M.D) Thursday, March 30, 2023**

## U/S. WHOLE ABDOMEN

- LIVER** : Liver is normal in size, shape & echotexture. Intra hepatic biliary radicals are normal. Portal venous channels are normal.
- G. B.** : Gall bladder is normal in size, lumen is clear. Wall thickness normal.
- C.B.D.** : C.B.D. is normal in caliber.
- PANCREAS** : Pancreas is normal in size, shape and echotexture. No evidence of any inflammatory disease or mass.
- SPLEEN** : Spleen is normal in size, shape and echotexture.
- Rt. KIDNEY** : Normal in size, shape and echotexture. Renal sinus is normal  
Cortico medullary differentiation is normal. P. C. system is normal.
- Lt. KIDNEY** : Normal in size, shape and echotexture. Renal sinus is normal  
Cortico medullary differentiation is normal. P. C. system is normal.
- URI. BLADDER** : Urinary bladder is normal in size, position. Wall thickness normal.  
No evidence of calculus or mass.
- UTERUS** : Normal in size. shape & echotexture. Endometrial echo is normal(6.0 cm).
- OVARIES** : Rt. Ovary:- Normal in size.  
Lt. Ovary:-Normal in size.  
No free fluid seen in P. O. D.
- IMPRESSION** : **NO OBVIOUS SONOLOGICAL ABNORMALITY SEEN.**

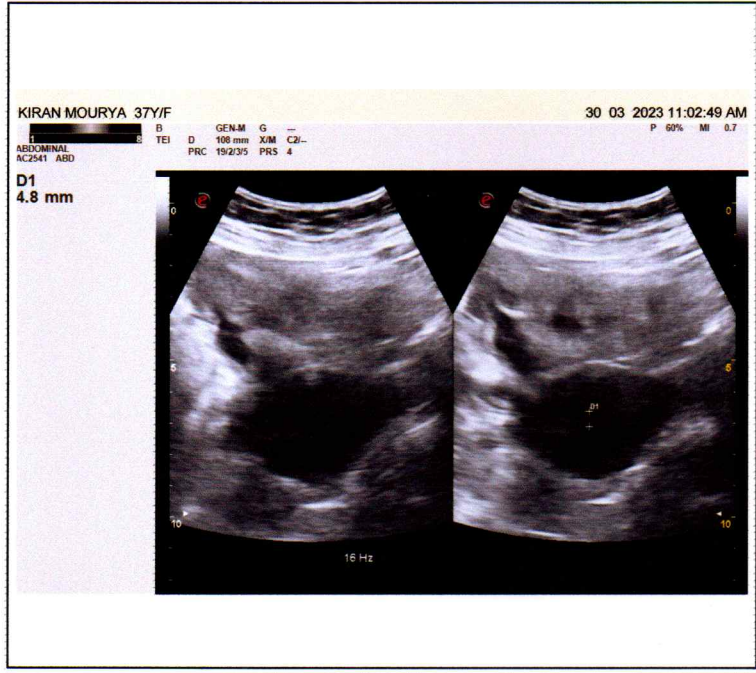
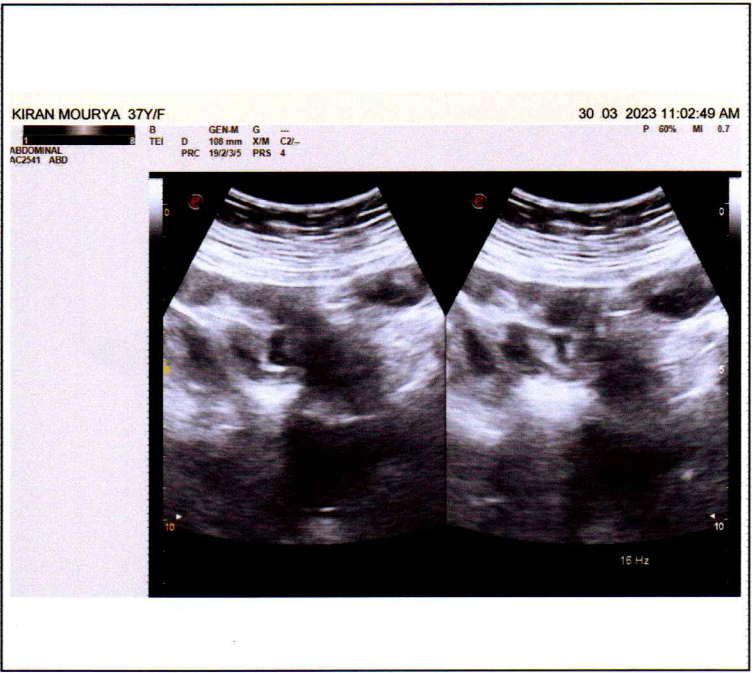
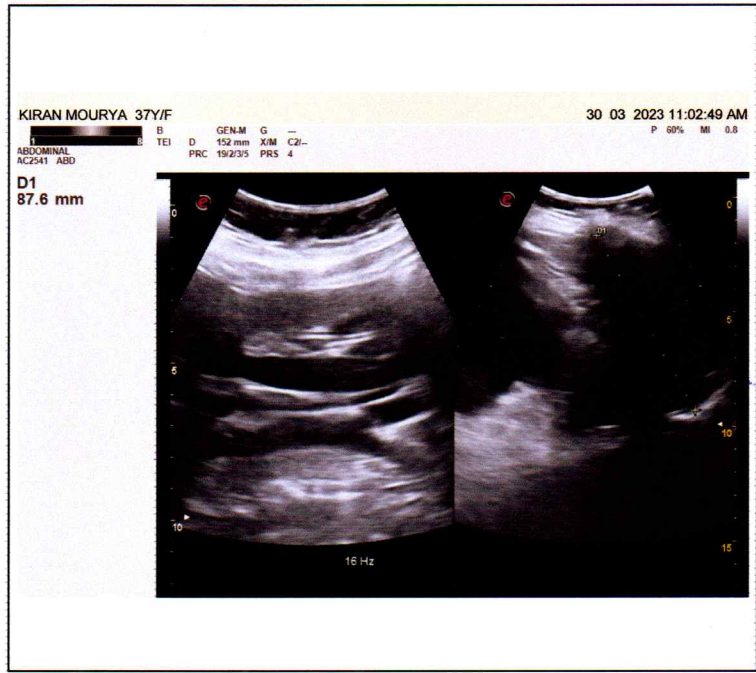
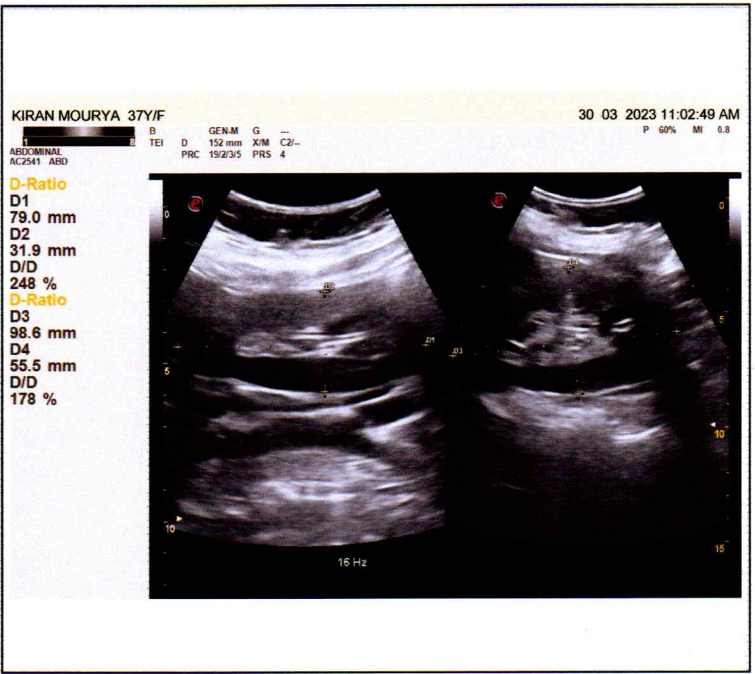
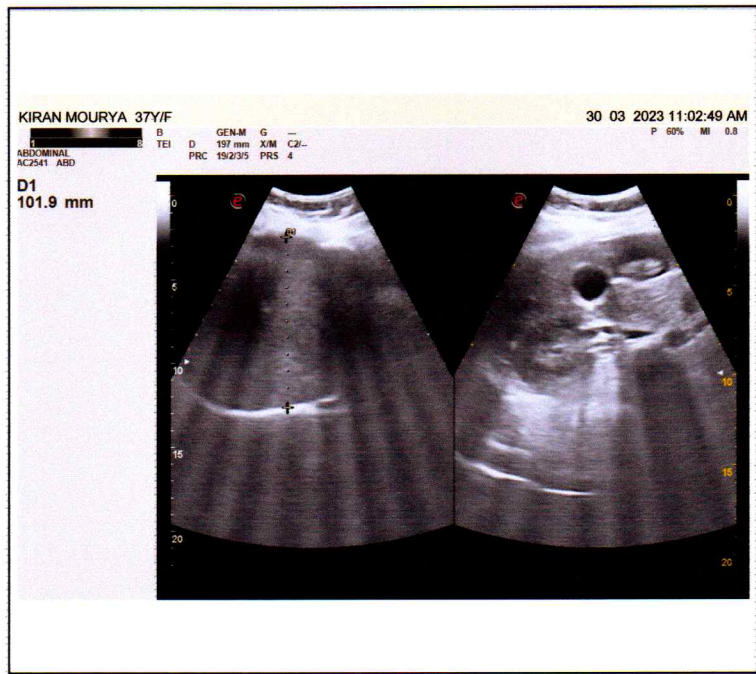
**DR. R. TIWARI**  
**(M.B.B.S, M.D.(KGMU, LKO)**  
**(RADIODIAGNOSIS).**

*Thanks for reference.*

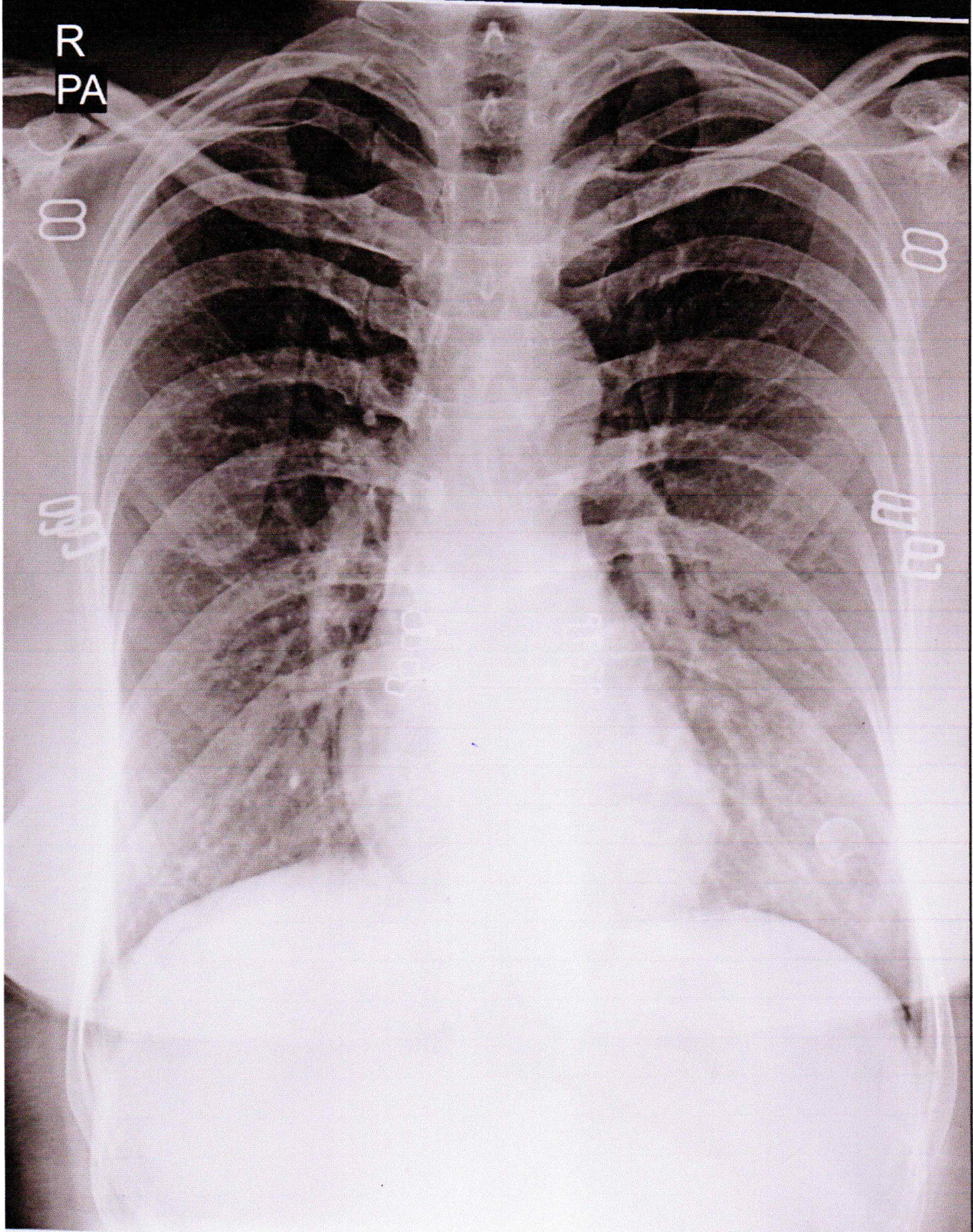
**Address : Kabir Nagar (Near Sanjay Shiksha Niketan), Durgakund, Varanasi**

**Mobile : 9554572190 / 9453837595 / Recpn. 9389994334**

**E-mail : dramishra@gmail.com, drpallaviojha@gmail.com, Website: www.piire.org**



R  
PA



KIRAN MAURYA 37Y/F

O CHEST P.A. 30-Mar-23 10:05 AM

PANACEA HOSPITAL, KABIR NAGAR, DURGAKUND, VARANASI