

**Facilities:**  
 All clinical Biomedical & Hematology Investigations  
 including Bone Marrow Examination  
 VPT, Podiascan & Complete Foot Care (First Time in Purvanchal)  
 All Hormonal Investigation by Chemiluminescent Method  
 Visceral Fat by (AB-140) Ambulatory BP Monitoring  
 CGMS & Insulin Pump Available  
 PFT, 2D-ECHO (Color Doppler), Holter, TMT, Cardiac-3 available  
 VIA, VILI, Colposcopy available  
 Special Endocrinological Investigation Protocols.

ISO 9001:2008 Certified  
 Mobile: 9389994334, 9554572190, 9453837595



## Panacea Pathology

### Clinical Reference Lab

Persistence, Preparedness and Precision  
 EQAS (CMC Vellore Attached) & IQAS System  
 पूर्वांचल की सर्वोत्तम गुणवत्ता वाली पैथोलॉजी

PATIENT NAME : SHYAM NARAYAN

AGE/GENDER : 45YRS/MALE

REFD BY DR. : ARCO FEMI HEALTHCARE LTD.

RECEIVED DATE : 11-03-2023 (09:00 AM)

SAMPLE : BLOOD & URINE

REPORT DATE : 11-03-2023 (06:00 PM)

## PATHOLOGY REPORT

### COMPLETE BLOOD COUNT (CBC)

TEST	LAB TEST VALUES	NORMAL RANGE
<b>HEMOGRAM</b>		
HEMOGLOBIN (FLOW CYTOMETRY)	12.3	13 – 16 gm/dl
TOTAL LEUCOCYTE COUNT (TLC)	3,500	4000 – 11000
RBC COUNT	3.39	3.5 – 5.5
PCV (HCT)	38.7	37 – 47
MCV	114.1	80 – 95
MCH	36.2	28 – 34
MCHC	31.8	30 – 36
PLATELET COUNT	1,16,000	1,50,000 – 4,00,000
E.S.R. (WINTROBE FIRST HOURS)	11.0	20 mm/1 <sup>st</sup> hr
<b>DIFFERENTIAL LEUCOCYTE</b>		
NEUTROPHILS	50	40 – 75%
LYMPHOCYTES	44	20 – 45%
EOSINOPHILS	03	1 – 6%
MONOCYTES	03	2 – 8%
BASOPHILS	00	< 2%

### RANDOM/FASTING BLOOD SUGAR

TEST	LAB TEST VALUES	NORMAL RANGE
<b>RBS/FBS</b>		
FASTING BLOOD SUGAR	80.7	70-125 mg/dl
RANDOM BLOOD SUGAR	114.0	125-140 mg/dl

### GLYCOSYLATED HEMOGLOBIN (HBA1C)

TEST	LAB TEST VALUES	NORMAL RANGE
HBA1C	5.5	Normal : <5.97 % Good Control : 5.97 – 6.81% Fair Control : 6.81 – 7.65% Poor Control : >7.65%

PAGE 1

Lab Technician

**PANACEA HOSPITAL**  
 A UNIT OF AAROH HEALTHCARE PVT. LTD  
 REG. NO. JAL/1500  
 B.36/44, B-4, KABIR NAGAR  
 DURGAKUND, VARANASI  
 M.D., Pathology

Timing : 8.00 a.m. to 9.00 p.m. (Sunday 8.00 a.m. to 3.00 p.m.)

This Report is not valid for medico legal purpose

**Note:** These tests have technical limitations. Clinico-pathological interpretation is necessary. In case of any disparity test may be repeated immediately.

Address : 36/44 FK Kabir Nagar, Durgakund, Varanasi – 221005

Email: [dramishra@gmail.com](mailto:dramishra@gmail.com), [drpallaviojha@gmail.com](mailto:drpallaviojha@gmail.com) Website: [panaceahospital.org](http://panaceahospital.org)

**Facilities:**

All clinical Biomedical & Hematology Investigations including Bone Marrow Examination  
VPT, Podiascan & Complete Foot Care (First Time in Purvanchal)  
All Hormonal Investigation by Chemiluminescent Method  
Visceral Fat by (AB-140) Ambulatory BP Monitoring  
CGMS & Insulin Pump Available  
PFT, 2D-ECHO (Color Doppler), Holter, TMT, Cardiac-3 available  
VIA, VILI, Colposcopy available  
Special Endocrinological Investigation Protocols.

ISO 9001:2008 Certified  
Mobile: 9389994334, 9554572190, 9453837595



# Panacea Pathology

## Clinical Reference Lab

Persistence, Preparedness and Precision  
EQAS (CMC Vellore Attached) & IQAS System  
पूर्वाचल की सर्वोत्तम गुणवत्ता वाली पैथोलॉजी

PATIENT NAME : SHYAM NARAYAN

AGE/GENDER : 45YRS/MALE

REFD BY DR. : ARCO FEMI HEALTHCARE LTD.

RECEIVED DATE : 11-03-2023 (09:00 AM)

SAMPLE : BLOOD & URINE

REPORT DATE : 11-03-2023 (06:00 PM)

### PATHOLOGY REPORT

#### LIPID PROFILE, SERUM

TEST	LAB TEST VALUES	NORMAL RANGE
<b>BLOOD CHEMISTRY</b>		
TOTAL CHOLESTEROL (SERUM)	168.0	Desirable:- &lt; 200 mg/dl Borderline:- 200 – 239 mg/dl High:- &gt; 240 mg/dl
TRIGLYCERIDES (SERUM)	162.0	35 – 170 mg/dl
HDL CHOLESTEROL (SERUM)	48.0	35.30 – 79.50 mg/dl
LDL CHOLESTEROL (SERUM)	87.6	&lt; 130 mg/dl
VLDL	32.4	&lt; 40 mg/dl
CHOLESTROL/HDL RATIO	3.5	&lt; 3.0 Low Risk Ratio 3.0 – 5.0 Avg Risk &lt; 5.0 High Risk
LDL/HDL RATIO	1.82	&lt; 3 Ratio

#### BLOOD GROUP

TEST	LAB TEST VALUES
<b>BLOOD GROUP ABO &amp; RH FACTOR</b>	
BLOOD GROUP	"A"
RH FACTOR	POSITIVE

#### LIVER PROFILE TEST, SERUM

TEST	LAB TEST VALUES	NORMAL RANGE
<b>BIO CHEMISTRY</b>		
TOTAL BILIRUBIN	0.72	0.0 – 1.1 mg/dl
DIRECT BILIRUBIN	0.24	0.0 – 0.2 mg/dl
INDIRECT BILIRUBIN	0.48	< 0.90 mg/dl
SGOT (AST)	29.4	0 – 52 mg/dl
SGPT (ALT)	32.0	0 – 39 mg/dl
GGT (GYT)	23.0	< 55 U/L

#### THYROID PROFILE (T3, T4, TSH)

TEST	LAB TEST VALUES	NORMAL RANGE
<b>THYROID FUNCTION TEST</b>		
T3	1.01	0.60 – 1.81 ng/ml
T4	7.56	4.50 – 10.90 ug/dl
TSH	2.15	0.39 – 6.10 uIU/mL

PAGE 2

Lab Technician

**PANACEA HOSPITAL**  
(A UNIT OF AAROHA HEALTH CARE PVT. LTD.)  
REG. NO. AL-1500  
M.D. Pathology  
B.36/44, B-4, KABIR NAGAR  
DURGAKUND, VARANASI

Timing : 8.00 a.m. to 9.00 p.m. (Sunday 8.00 a.m. to 3.00 p.m.)

This Report is not valid for medico legal purpose

**Note:** These tests have technical limitations. Clinico-pathological interpretation is necessary. In case of any disparity test may be repeated immediately.

Address : 36/44 FK Kabir Nagar, Durgakund, Varanasi – 221005

Email: [dramishra@gmail.com](mailto:dramishra@gmail.com), [drpallaviojha@gmail.com](mailto:drpallaviojha@gmail.com) Website: [panaceahospital.org](http://panaceahospital.org)

**Facilities:**

All clinical Biomedical & Hematology Investigations including Bone Marrow Examination VPT, Podiascan & Complete Foot Care (First Time in Purvanchal) All Hormonal Investigation by Chemiluminescent Method Visceral Fat by (AB-140) Ambulatory BP Monitoring CGMS & Insulin Pump Available PFT, 2D-ECHO (Color Doppler), Holter, TMT, Cardiac-3 available VIA, VILI, Colposcopy available Special Endocrinological Investigation Protocols.

ISO 9001:2008 Certified  
Mobile: 9389994334, 9554572190, 9453837595



# Panacea Pathology

## Clinical Reference Lab

Persistence, Preparedness and Precision  
EQAS (CMC Vellore Attached) & IQAS System  
पूर्वांचल की सर्वोत्तम गुणवत्ता वाली पैथोलॉजी

PATIENT NAME : SHYAM NARAYAN

AGE/GENDER : 45YRS/MALE

REFD BY DR. : ARCO FEMI HEALTHCARE LTD.

RECEIVED DATE : 11-03-2023 (09:00 AM)

SAMPLE : BLOOD & URINE

REPORT DATE : 11-03-2023 (06:00 PM)

## PATHOLOGY REPORT

### RENAL & KIDNEY PROFILE, SERUM

TEST	LAB TEST VALUES	NORMAL RANGE
<b>RENAL FUNCTION TESTS</b>		
BLOOD UREA NITROGEN (BUN)	9.24	10 – 50 mg/dl
SERUM CREATININE	0.78	0.60 – 1.60 mg/dl
URIC ACID	4.16	3.60 – 7.70 mg/dl
ALKALINE PHOSPHATASE (ALP)	81.0	142 – 353 mg/dl
TOTAL PROTIENS	7.56	0 – 39 mg/dl
ALBUMIN	4.12	3.8 – 5.4 mg/dl
SERUM GLOBULIN	3.44	2.1 – 3.5 mg/dl
CALCIUM	9.2	8.80 – 10.20
PHOSPHORUS	3.04	2.50 – 5.00
SERUM SODIUM NA+	140.6	135.00 – 155.00 mEq/Ltr
SERUM POTASIUM K+	4.32	3.60 – 5.50 mEq/Ltr
ICALCIUM	1.24	1.10 – 1.35 mmol/L
SERUM CHLORIDE CL+	105.9	98.00 – 110.00 mEq/Ltr

### URINE ROUTINE EXAMINATION

TEST	LAB TEST VALUES	NORMAL RANGE
<b>PHYSICAL EXAMINATION</b>		
QUANTITY	30	ML
COLOUR	STRAW	PALE YELLOW
APPEARANCE	CLEAR	CLEAR
SPECIFIC GRAVITY	1.015	1.01 – 1.03
PH	6.5	4.7 – 7.5
<b>CHEMICAL EXAMINATION</b>		
GLUCOSE	Not Detected	Not Detected
PROTEIN	NIL	Not Detected
<b>MICROSCOPIC EXAMINATION</b>		
PUS CELLS	02-03	0-5
RBC	Not Detected	Not Detected
EPITHELIAL CELLS	01-02	0-5
CASTS	Not Detected	Not Detected
CRYSTALS	Not Detected	Not Detected
BACTERIA	Not Detected	Not Detected

----- End of Report -----

Lab Technician

**PANACEA HOSPITAL**  
(A UNIT OF AARON HEALTH CARE PVT. L.)  
REG. NO.: AL-1500  
BMD Pathology  
DURGAKUND, VARANASI

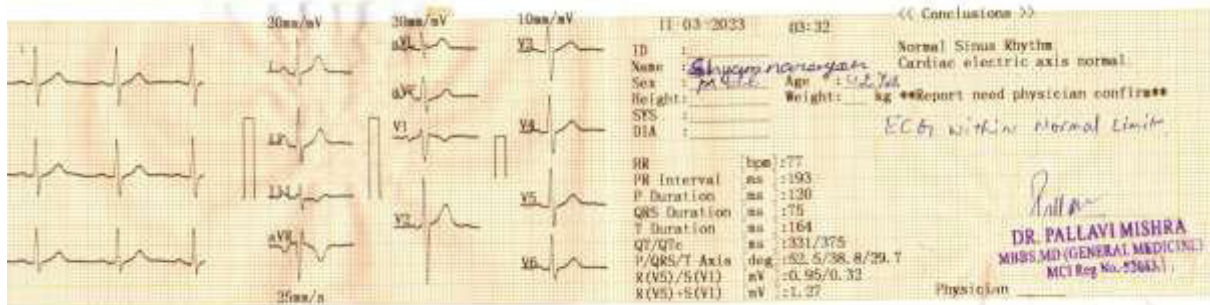
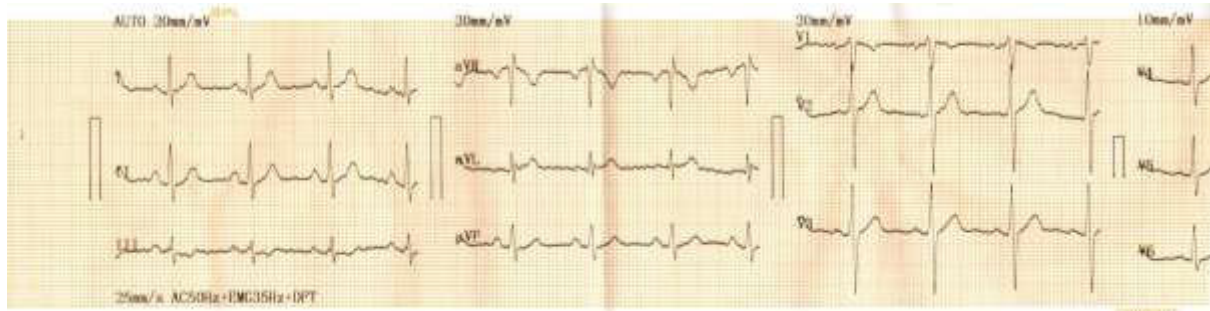
Timing : 8.00 a.m. to 9.00 p.m. (Sunday 8.00 a.m. to 3.00 p.m.)

This Report is not valid for medico legal purpose

**Note:** These tests have technical limitations. Clinico-pathological interpretation is necessary. In case of any disparity test may be repeated immediately.

**Address :** 36/44 FK Kabir Nagar, Durgakund, Varanasi – 221005

**Email:** [dramishra@gmail.com](mailto:dramishra@gmail.com), [drpallaviojha@gmail.com](mailto:drpallaviojha@gmail.com) **Website:** [panaceahospital.org](http://panaceahospital.org)





# PANACEA HOSPITAL

*A shelter for many hearts A Home for many lives*

(An ISO 9001:2008 Certified Organisation)

Lab Attached with CMC Vellore Under EQAS Scheme

Name	MR.SHAYAM NARAYAN	Sex /Age	44/M	Date	11/03/2023
Ref. by	Dr.Pallavi Mishra(MD)	BSA - m <sup>2</sup>		Echo window	fair

## Echo - Cardiography


MITRAL VALVE Doppler	AML - normal morphology MV Flow - E - 0.6 A-0.4 E/A=1.32	PML - normal morphology MVA - 3.0 cm <sup>2</sup> Mitral Regurgitation - <b>No</b>
TRICUSPID VALVE Doppler	Normal TV Flow -No	Tricuspid Regurgitation - <b>No</b>
PULMONARY VALVE Doppler	Normal PV Flow -No	Pulmonary Regurgitation - No
AORTIC VALVE Doppler	Trileaflet-No AV Flow - no	Aortic Regurgitation - no
MEASUREMENT	Aorta - 30.8 (20-38) mm IVS ed - 13.7 (6 -12) mm LVID ed - 49.1 (35 - 55) mm LVPW ed - 12.0 (6 -12) mm OA - 7 (> 5) mm	LA - 30.3 (24-32) mm IVS es -14.8 (6 - 12) mm LVID es - 35.4 (24 - 40) mm LVPW es - 15.4 (6 -12) mm EPSS - 6 (< 9) mm


## CONCLUSION

All cardiac chamber dimensions are WNL  
No valvular abnormalities  
Good LV systolic function present Modified Simpson's method (4C, 2C) (LVEF-54%)  
No diastolic dysfunction present (E/A = 1.32) by tissue Doppler (E/e'=6.2)  
No RWMA  
No pericardial effusion  
Intact IAS / IV  
No PAH  
No intra cardiac mass /thrombus /vegetation

## IMPRESSION

**Normal Echocardiogram**

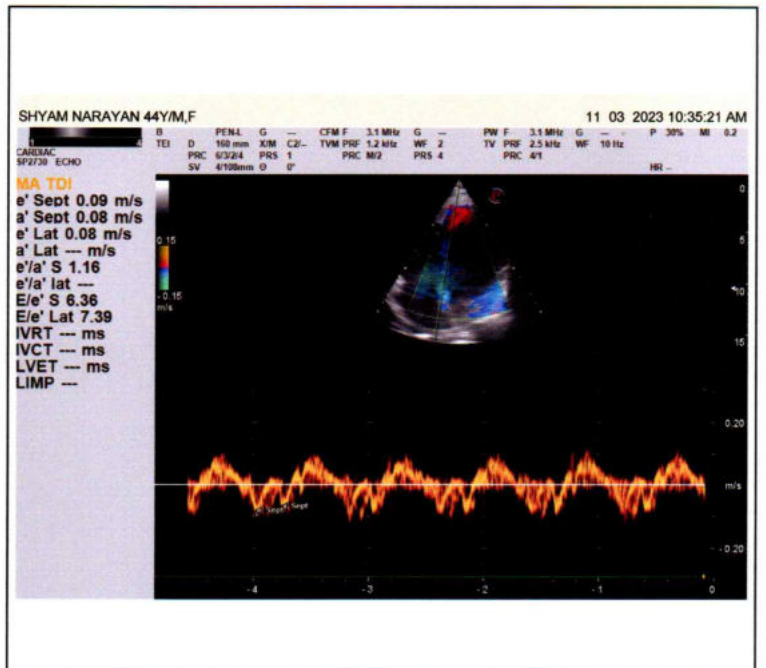
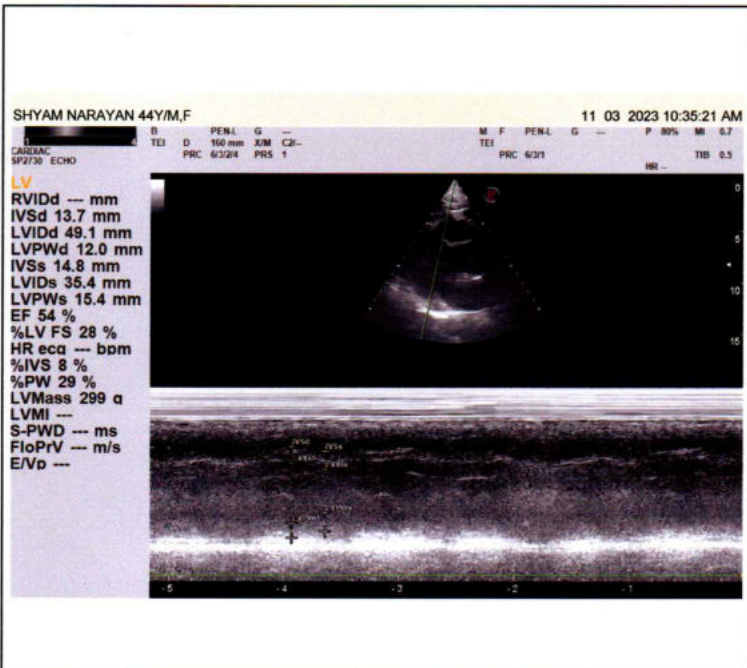
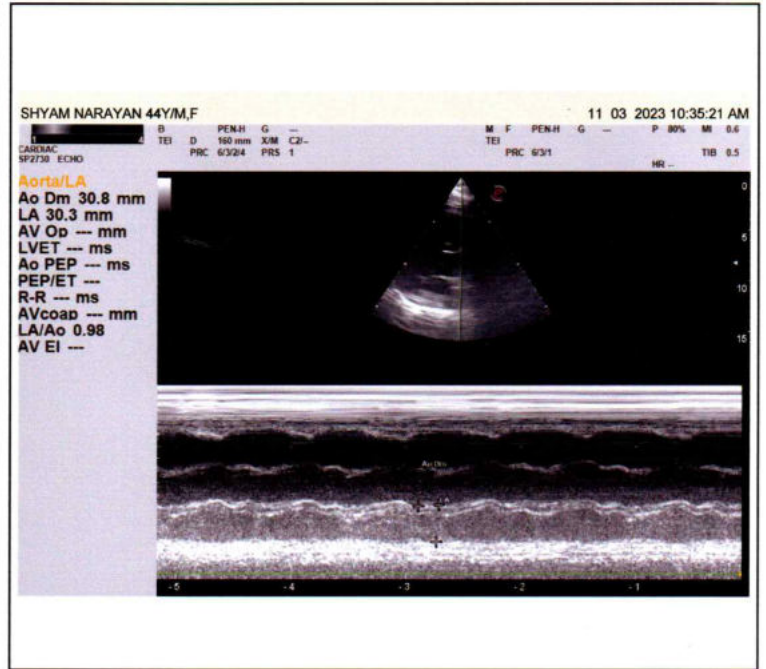
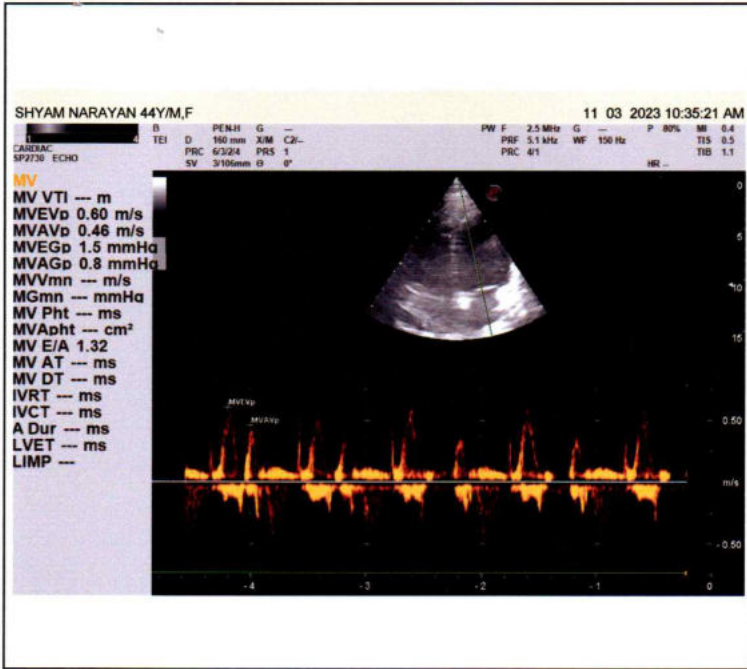
  
Niraj Mishra  
Physician Assistant  
(PIIRE)

  
**DR. PALLAVI MISHRA**  
MBBS, MD (GENERAL MEDICINE)  
MCI Reg.No. 52033  
Dr. Pallavi Mishra  
MBBS, MD (MED) Lucknow  
Echocardiography Specialist, MIAE  
Non-invasive cardiologist  
Women Cardiologist  
Diabetocardiologist

Address : Kabir Nagar (Near Sanjay Shiksha Niketan), Durgakund, Varanasi

Mobile : 9554572190 / 9453837595 / Recpn. 9389994334

E-mail : dramishra@gmail.com, drpallaviojha@gmail.com, Website: www.piire.org





# PANACEA HOSPITAL

*A shelter for many hearts A Home for many lives*

(An ISO 9001:2008 Certified Organisation)

Lab Attached with CMC Vellore Under EQAS Scheme

**NAME:** MR.SHAYM NARAYAN

**AGE/SEX:** 44 YRS / MALE

**REF BY:** DR. ASHUTOSH MISHRA (MD)

**DATE:** 11/03/2023

## ULTRA SOUND FOR ABDOMEN REPORT

- Liver:** Normal in shape and size and shows smooth and regular margin.
- Gall bladder** Normal distended with normal wall thickness and echo-free lumen.
- CBD** Visualized part normal in course & caliber.
- Pancreas:** Normal in size, shape & echogenicity. Margins are smooth & regular. No diffuse/ focal lesion seen. Pancreatic tail obscured.
- Spleen:** Normal in size shape & echogenicity. Margins are smooth & regular. No diffuse / focal lesion seen. Splenic vessels at hilum is normal.
- Kidney:** Right kidney: 11.0 X 5.1cm Left kidney: 11.0 X 4.4 cm Normal cortical echogenicity with well maintained Cortical-medullary differentiation., Pelvicalyceal system normal. No calculus/mass lesion seen. No hydronephrosis/ hydroureter seen.
- Urinary bladder:** Normally distended, wall thickness is normal. No echogenic foci lumen or diverticula seen. Both VUJ appears normal. No E.R. calculus / mass lesion seen
- Prostate** Prostate is normal in size. No ascites & retro peritoneal lymphadenopathy seen.
- Others:** No free fluid in peritoneal cavity.  
No free fluid in bilateral pleural cavity.

### **Impression:**

- **NO SIGNIFICANT SONOLOGICAL ABNORMALITY DETECTED.**

REPORTED BY

DR. R. K. TIWARI

MD RADIODIAGNOSIS (GOLD MEDALIST)

KGMU, LUCKNOW

Reg.No. 57557

Please correlate clinically and further investigations.

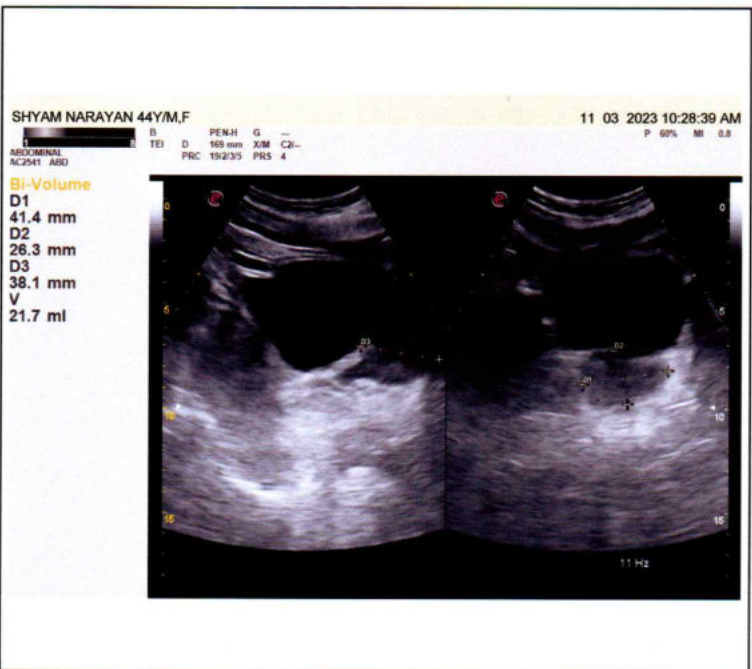
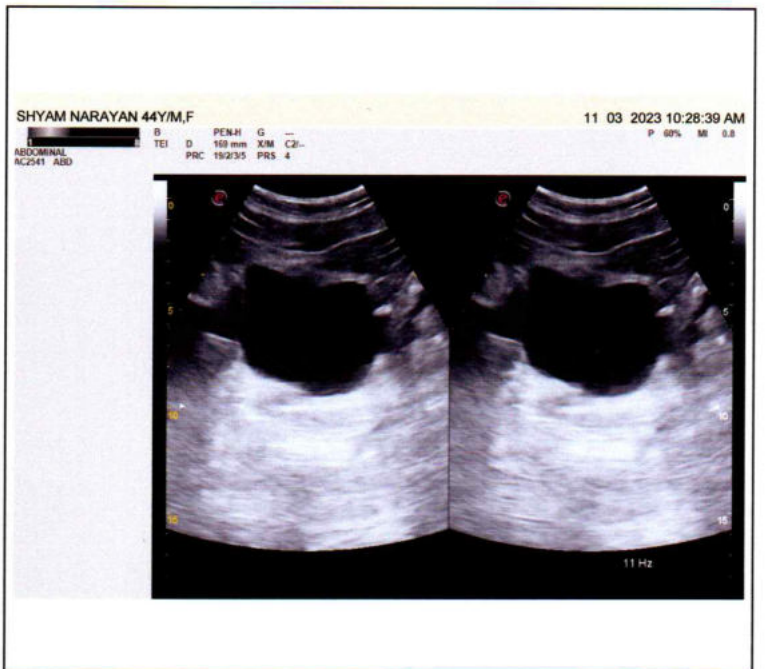
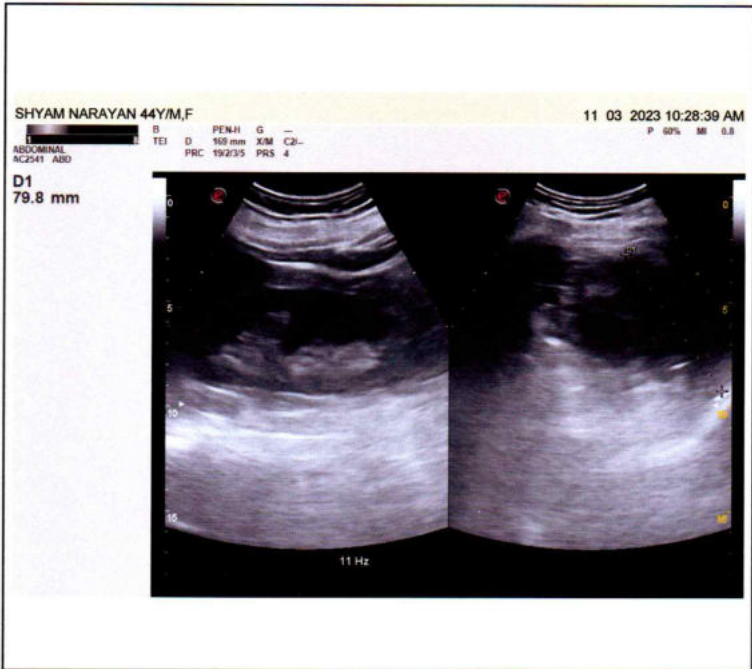
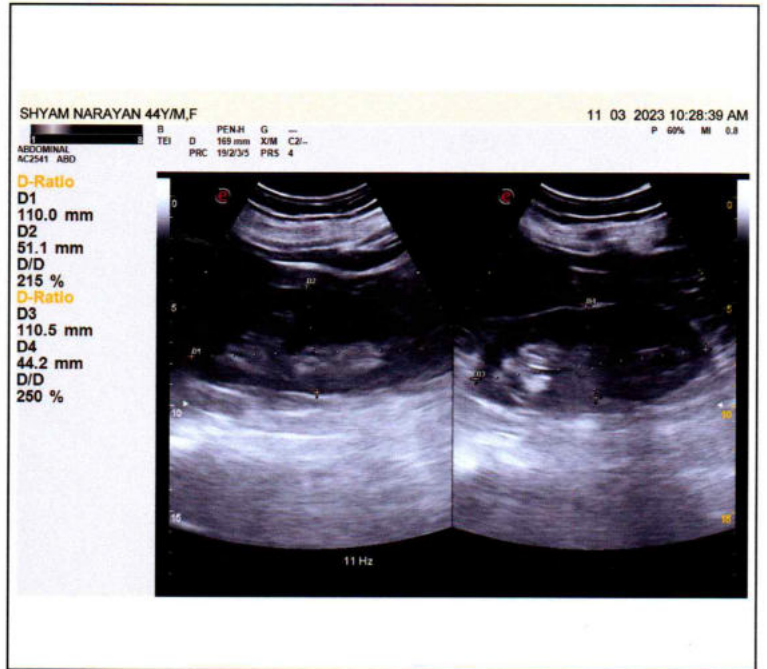
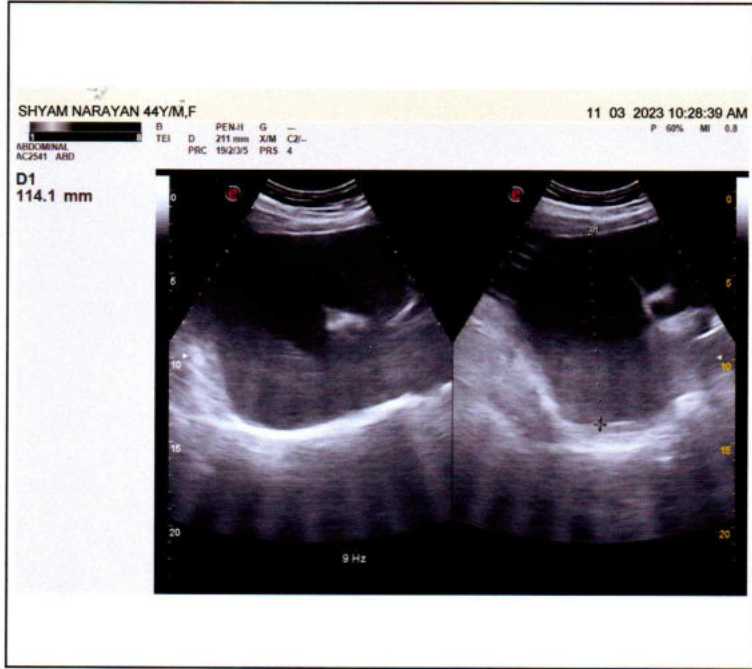
Note: (1) This report is not valid for medico-legal purposes.

(2) In case of any discrepancy due typing error, please get it Rectified immediately.

**Address :** Kabir Nagar (Near Sanjay Shiksha Niketan), Durgakund, Varanasi

**Mobile :** 9554572190 / 9453837595 / Recpn. 9389994334

**E-mail :** dramishra@gmail.com, drpallaviojha@gmail.com, Website: www.piire.org







# PANACEA HOSPITAL

*A shelter for many hearts A Home for many lives*

(An ISO 9001:2008 Certified Organisation)

Lab Attached with CMC Vellore Under EQAS Scheme

**NAME:** MR.SHAYM NARAYAN  
**REF BY:**DR. ASHUTOSH MISHRA (MD)

**AGE/SEX:** 44 YRS / MALE  
**DATE:**11/03/2023

## X-RAY CHEST PA

### BOTH LUNG FIELDS AND PLEURAE:

Both lungs show normal bronchovascular pattern.

Right & left hila are normal

No focal mass or calcification is seen

There is no evidence of any fluid in the both the pleural cavities.

Both domes of diaphragms are normal in position.

### MEDIASTINUM:

Trachea is central in position.

Cardiac silhouette is of normal size and configuration.

No evidence of pericardial effusion.

No significant lymphadenopathy is seen.

Visualized skeleton is normal.

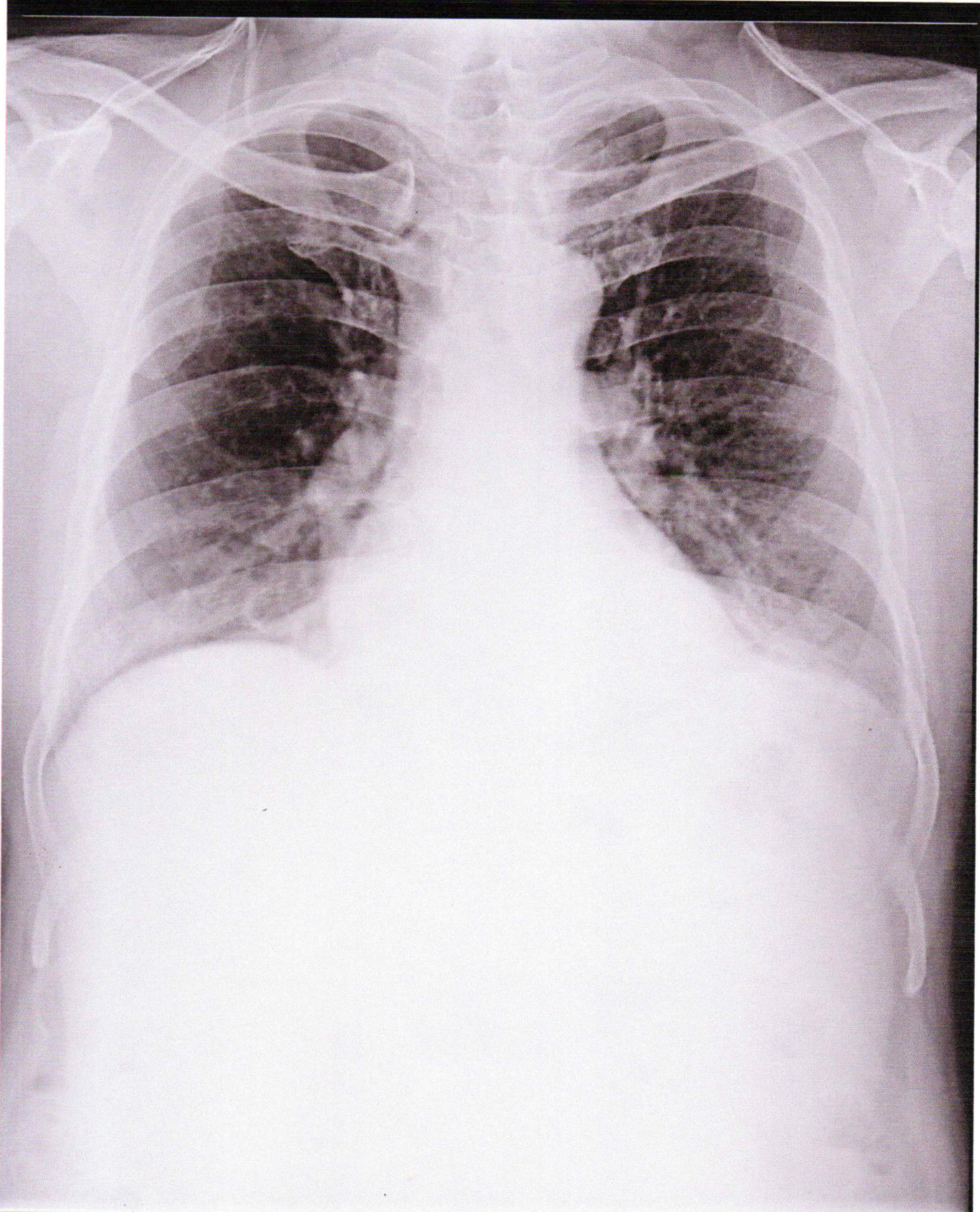
-----  
NO SIGNIFICANT RADIOGRAPHIC ABNORMALITY.

*Re*  
**REPORTED BY**  
**DR. Rahul Kumar Tiwari**  
MBBS, MD (Radio Diagnosis)  
Reg.No. 57557

**Address :** Kabir Nagar (Near Sanjay Shiksha Niketan), Durgakund, Varanasi

**Mobile :** 9554572190 / 9453837595 / Recpn. 9389994334

**E-mail :** dramishra@gmail.com, drpallaviojha@gmail.com, Website: www.piire.org



SHYAM NARAYAN YADAV 44Y/M 2564 O CHEST P.A. 11-Mar-23 02:48 PM

PANACEA HOSPITAL, KABIR NAGAR, DURGAKUND, VARANASI