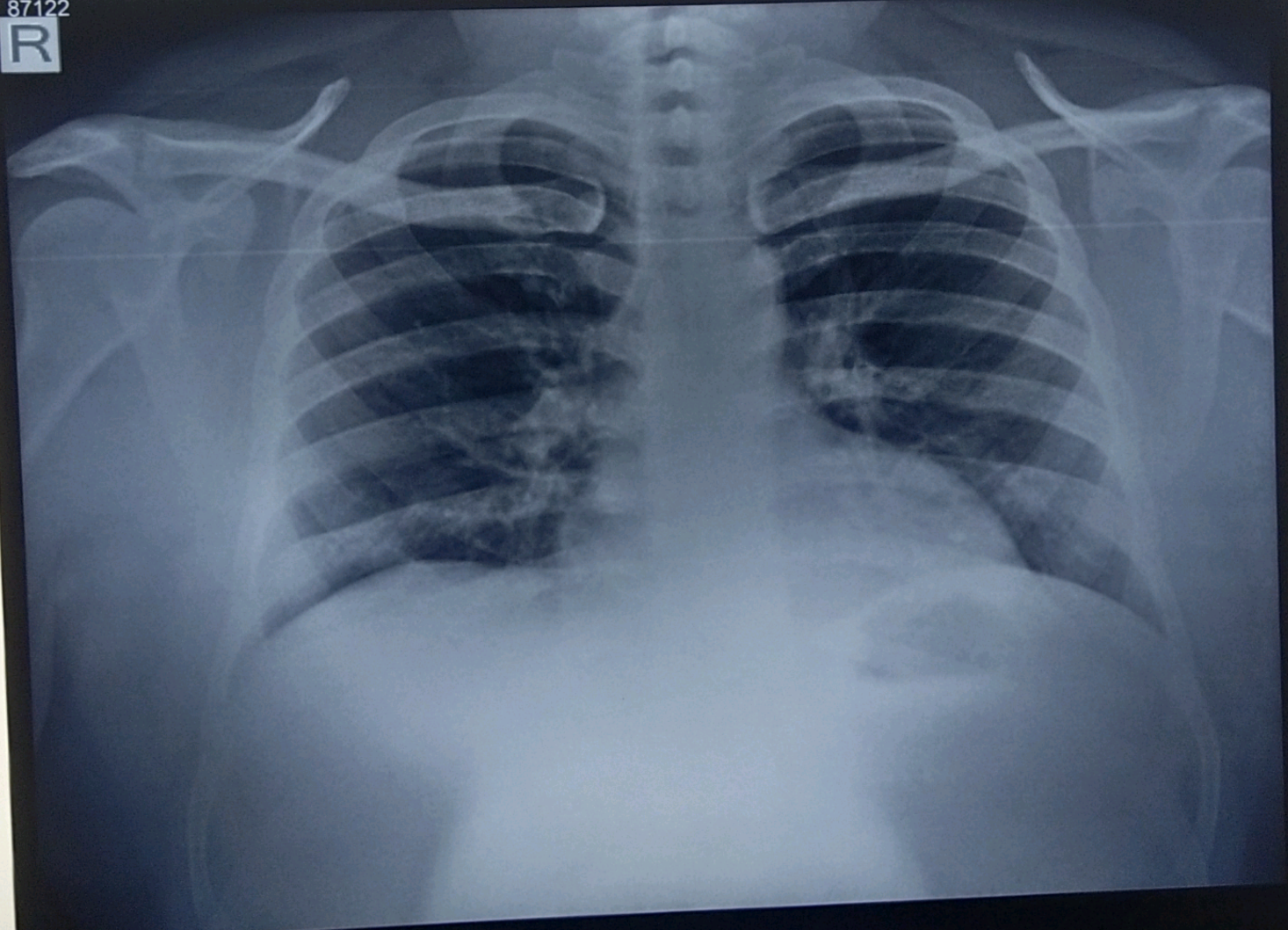


MR. ARUN JOSE 35Y M.,
87122

06/02/2022
09:01:25

R





ABI SCANS & LABS

A unit of Aarthi Scans and Labs

| | | | |
|--------------|--------------|------------|-------------|
| Name | MR.ARUN JOSE | Patient ID | 87122 |
| Accession No | 83846 | Age/Gender | 35 Y / Male |
| Referred By | MEDIWHEEL | Date | 6-Feb-2022 |

X-RAY - CHEST PA VIEW

OBSERVATION:

The trachea is central.

The mediastinal and cardiac silhouette are normal.

Cardiothoracic ratio is normal.

Cardiophrenic and costophrenic angles are normal.

Both hila are normal.

Lung zones are clear.

Bones of the thoracic cage are normal.

Soft tissues of the chest wall are normal.

IMPRESSION:

- No significant abnormality seen.

Dr. Abinaya R MDRD.,
Consultant Radiologist

Door No. 452/493, PN Road, Millar Stop,
Tirupur - 641 602. Phone: 99434 99994

Obli Towers, #594, D. B. Road - Cowly Brown Road Jn.,
Coimbatore - 641 002. Phone: 99430 99994

email: info@abiscans.com

www.abiscans.com

Page 1 of 1



ABI SCANS & LABS

A unit of Aarthi Scans and Labs

| | | | |
|--------------|--------------|------------|------------|
| Name | MR.ARUN JOSE | Patient ID | 83846 |
| Accession No | 87122 | Age/Gender | 35Y / male |
| Referred By | Dr.MEDIWHEEL | Date | 6-Feb-2022 |

USG REPORT - ABDOMEN AND PELVIS

LIVER:

Liver is normal in size (measures ~ 14.6 cm) and shows increased echotexture.

No focal liver lesion. No intra hepatic biliary radical dilatation seen.

GALL BLADDER:

Is adequately distended.

Few calculi are seen with in the lumen of gall bladder, largest measuring ~ 6 mm. Wall thickness is normal (measures ~2mm). No evidence of pericholecystic fluid.

PANCREAS:

Appears normal in size and shows uniform echo texture. The pancreatic duct is normal. No calcifications are seen.

SPLEEN:

Appears normal in size and it shows uniform echo texture. It measures ~ cm in long axis.

RIGHT KIDNEY:

Right kidney measures ~ 10.4 x 4.7 cm.

The shape, size and contour of the right kidney appear normal.

Cortico medullary differentiation is within normal. No evidence of pelvicalyceal dilatation.

No calculi seen.

LEFT KIDNEY:

Left kidney measures ~ 9.1 x 4.7 cm.

The shape, size and contour of the left kidney appear normal.

Door No. 452/493, PN Road, Millar Stop,
Tirupur - 641 602. Phone: 99434 99994

Obli Towers, #594, D. B. Road - Cowly Brown Road Jn.
Coimbatore - 641 002. Phone: 99430 99994

email: info@abiscans.com

www.abiscans.com

Page 1 of 2



ABI SCANS & LABS

A unit of Aarthi Scans and Labs

| | | | |
|--------------|--------------|------------|------------|
| Name | MR.ARUN JOSE | Patient ID | 83846 |
| Accession No | 87122 | Age/Gender | 35Y / male |
| Referred By | Dr.MEDIWHEEL | Date | 6-Feb-2022 |

USG REPORT - ABDOMEN AND PELVIS

Cortico medullary differentiation is within normal. No evidence of pelvicalyceal dilatation.

No calculi seen.

URINARY BLADDER:

Is normal contour. No intra luminal echoes are seen.

PROSTATE:

Prostate appears normal for age.

RIGHT ILIAC FOSSA:


No focal fluid collections seen.

No evidence of hernia seen in anterior abdominal wall.

IMPRESSION:

- ❖ Grade I fatty liver.
- ❖ Cholelithiasis. No evidence of cholecystitis.

- Suggested clinical correlation.


Dr. Karthikeyan., MBBS., DMRD.,
Radiologist

Thank you for the courtesy of this referral

Foot Note: Patient's identity is not verified. Report is not valid for medico legal purpose.

ABI SCANS AND LABS

MR. ARUN JOSE /M 83846 06-Feb-2022 09:19:28 AM

