



PARKLINE DIAGNOSTICS PVT. LTD.

L.G. 3, 4 & 5, Bhuvana Towers, S.D. Road, Secunderabad - 500 003.
Tel : +91 40-2784 5852, 6649 1787, 7995421787, 7093445852, Fax : +91 40 2784 7864
Email parklinediagnostics@gmail.com www.parklinediagnostics.com



NABL Accredited
Certificate No.MC-2566

MEDICAL EXAMINATION REPORT

Name	MS. Mohammed Reshma Aijum		Date :	21/08/2021
Company	clo: medtwheel		Reg. No. :	449585
Contact No.	8125555520		Sex	<input checked="" type="checkbox"/> F
			Age :	30
Type	Pre-Emp		Emp. No.:	178211
	Overseas		Height	158 cm
	Annual	<input checked="" type="checkbox"/>	Weight	103 kg
Remarks	<p>BE v G/B without glasses H/o BE lasik for -4.0 sph in 2015 <input checked="" type="checkbox"/> NV BE Nb.</p> <p>Dr. KATTA M.B.B.S., D.O., F.R.F Regd. 8901 (AMC)</p> <p>- Advised to improve haemoglobin - Known hypothyroid - on treatment. TSH marginally ↑. Advised follow-up - Advised to reduce weight.</p>			
Fitness Status	Medically Fit / Unfit		<p>Dr. K. VIKRAM Physician's Signature Reg.No. 8603</p>	

Distant Vision : Near Vision :

Right Eye: 6/6

With glasses / Without glasses

left Eye : 6/6

with glasses / without glasses

*Hlo lasik Both eyes 2015
for BE -4.0 spm*

Colour Vision : BE normal

Right Eye: N6

With glasses / Without glasses

left Eye : N6

with glasses / without glasses

Ophthalmologist's Signature
DR. [Signature]

Left Ear
M.B.D.S., D.O., F.R.C.S.
Regd: 8961 (AMC)

Right Ear

Hearing :

Rinee's Test ;

Weber Test :

Discharge :

SYSTEMIC EXAMINATION

Pulse : 72/4.0

B.P. : 110/80 = 11g

- Lungs :**
- A. Shape of Chest
 - B. Breath Sounds
 - C. Adventitious Sounds

- Heart :**
- A. Sounds
 - B. Murmurs

- Abdomen :**
- A. Liver
 - B. Spleen
 - C. Piles
 - D. Any Lump

- General :**
- A. Hernia
 - B. Hydrocele
 - C. Varicocele

Nervous System

- A. Higher Function :
- B. Cranial Nerves :
- C. Sensory System :
- D. Motor System :
- E. Jerks :

Breast : Rt _____ Lt. _____

CANDIDATE'S DECLARATION

I hereby solemnly declare that I am not suffering from Asthma, Hypertension, Diabetes, Occult Psychological disorders or any other ailment which can be suppressed without my voluntary declaration.

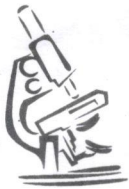Date :



Signature

Place :

Note : General Physical Examination and Investigation included in the health check-up Have certain limitations and may not be able to detect all latent and asymptomatic diseases. Any new symptoms developing after the health check-up or persisting thereafter should be brought to the attention of the treating physician.



PARKLINE DIAGNOSTICS PVT. LTD.

L.G. 3, 4 & 5, Bhuvana Towers, S.D. Road, Secunderabad - 500 003. Tel : +91 40-2784 5852, 6649 1787, 7995421787, 7093445852, Fax : +91 40 2784 7864 Email parklinediagnostics@gmail.com www.parklinediagnostics.com



NABL Accredited
Certificate No.MC-2566

ENT CONSULTATION

S.No. 449585 Emp.No. _____ Date 31/8/21
 Name MS. Mohammed Age 30 Yrs Sex M/F
Roshma Ayum

EARS :

Right

Left

EAC : patent. no cerumen. -do-
 TM : Intact, pearly white. -do-
Cone of light (+)
 TFT : Rinne's +ve Rinne's +ve
Weber's - centralised

NOSE

: Septum (+). Bil. Turbinates (+). Polyps - (+). non tender

THROAT

: Oropharynx (+). Bil. v. cords (+) normal.
Acute tonsillitis bil.

NECK

: (+)

IMPRESSION:

ENT clinically NAD.

Dr. D. Hari Krishna Reddy
 MS (ENT)
 Head & Neck Surgeon
 Reg. No: 65079




PARKLINE DIAGNOSTICS PVT. LTD.

L.G. 3, 4 & 5, Bhuvana Towers, S.D. Road, Secunderabad - 500 003 Tel :+91 40-2784 5852, 6649 1787
Fax : +91 40 2784 7864 Email parklinediagnostics@gmail.com www.parklinediagnostics.com



NABL Accredited
Certificate No.MC-2566

TEST REPORT

Req No. : 449585	Referred By : -
Name : Ms.MOHAMMED RESHMA ANJUM [178711]	Registration Date/Time: 31/08/2021/09:15
R/o : --	Sampling Date/Time : 31/08/2021/
Age/Sex : 30 Years/Female	Sample : -
Barcode : 	Center : MEDIWHEEL

ULTRA SONOGRAPHY

ULTRA SOUND SCAN OF ABDOMEN*

LIVER : Normal in size and echotexture. No focal lesions.

No IHBD /CBD dilatation. Portal vein is normal.

SPLEEN: Normal in size and echotexture. No focal lesion seen.

GALL BLADDER: Well distended. No sludge / gall stones / sol.
Gall bladder - Wall thickness is normal.
No pericholecystic oedema.

PANCREAS : Normal in size and echotexture.No calcification / sol.
Pancreatic duct is normal. No peripancreatic fluid collection.

RIGHT KIDNEY : 10.61 x 4.20 cms
Normal in size and echotexture.
Cortical thickness is normal.
No evidence of calculi / sol.
Pelvi calyceal system is normal.

LEFT KIDNEY : 10.37 x 4.60 cms
Normal in size and echotexture.
Cortical thickness is normal.
No evidence of calculi / sol.
Pelvi calyceal system is normal.

URINARY BLADDER : Well distended.Normal in contour.
Wall thickness is normal. No calculus / sol.

UTERUS : Anteverted measuring 6.08 x 3.18 x 3.26 cms - Normal in size and echotexture.
No space occupying lesion is seen.
Cervix is normal in size and echopattern.

ENDOMETRIUM : Normal.

OVARIES : Right ovary : 2.16 x 1.35 cms Left ovary : 2.01 x 1.47 cms
Both ovaries normal in size and echotexture.
Ovaries overlapped by bowel gas - grossly normal.
No adnexal mass seen.
No fluid in POD.

IMPRESSION : No obvious US Abnormality.

Clinical correlation.

The Test marked with *are not accredited by NABL

Lab Timings (Weekdays) : 7.00 am to 8.30 pm


Sundays & Holidays :7.00 am to 1.00 pm

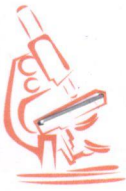Radiologists Timings(Weekdays) : 7.30 am to 1.30 pm
& 5.30 pm to 7.30 pm

Sundays & Holidays : 7.30 am to 1.30 pm

Free Home Visit for Sample Collection.

Call : 7995421787, 7093445852,8121147282, 9885202212


Dr. D.J. MOHAN
MD DMRD
(Reg No. 8995)
Consultant Radiologist



PARKLINE DIAGNOSTICS PVT. LTD.


L.G. 3, 4 & 5, Bhuvana Towers, S.D. Road, Secunderabad - 500 003 Tel :+91 40-2784 5852, 6649 1787

Fax : +91 40 2784 7864 Email parklinediagnostics@gmail.com www.parklinediagnostics.com



NABL Accredited
Certificate No.MC-2566

TEST REPORT

Req.No : 449585 Referred By : SELF
Name : Ms. MOHAMMED RESHMA ANJUM [178711] Req Date/Time : 31/08/2021 /09:15
R/O : --- Sampling Date/Time : 31/08/2021 /09:39
Age / Sex : 30 Years / Female Sample : -
Bar Code :  Centre : MEDIWHEEL

CARDIOLOGY

TEST(Methodology)	RESULT
Mitral Valve	Normal
Aortic valve	Normal
Tricuspid valve	Normal
Pulmonary valve	Normal
Aorta	2.30 cm
Left Atrium	2.43 cm
Left Ventricle	LVDd: 4.91 cm IVSd : 0.9 cm EF: 63 % LVDs: 3.22 cm LVPwd: 1.0 cm FS: 34 %
RWMA	Nil
Right Atrium	Normal
Right Ventricle	Normal
Pulmonary Artery	Normal
IAS	Intact
IVS	Intact
Pericardium	Normal
Svc / Ivc	Normal
Intracardiac Masses	Nil
Doppler Study	Mitral flow: E: 0.92 m/sec A: 0.61 m/sec E/A ratio : 1.49 Aortic flow : 1.0 m/sec Pulmonary flow : 0.92 m/sec
Colour Doppler	No MR / AR / TR / PR.
CONCLUSION	No RWMA. Normal valves/ Normal chambers. No MR/ AR/ TR /PR. Good LV/ RV function. No PE/ clot/ vegetation.

MEDIWHEEL FEMALE 30 YRS AND BELOW

**** END OF REPORT ****

Reported on : 31/08/2021 / 09:41

Printed on : 31/08/2021 / 09:41

Dr PANDURANGA
MD., DI
Consultant Interventional Cardiologist
Reg No TSMC/FMR/09054

The Test marked with *are not accredited by NABL

Lab Timings (Weekdays) : 7.00 am to 8.30 pm

Sundays & Holidays : 7.00 am to 1.00 pm

Radiologists Timings(Weekdays) : 7.30 am to 1.30 pm

& 5.30 pm to 7.30 pm
Sundays & Holidays : 7.30 am to 9.30 am




PARKLINE DIAGNOSTICS PVT. LTD.

L.G. 3, 4 & 5, Bhuvana Towers, S.D. Road, Secunderabad - 500 003 Tel :+91 40-2784 5852, 6649 1787
Fax : +91 40 2784 7864 Email parklinediagnostics@gmail.com www.parklinediagnostics.com



NABL Accredited
Certificate No.MC-2566

TEST REPORT

Req No. : 449585	Referred By : -
Name : Ms.MOHAMMED RESHMA ANJUM [178711]	Registration Date/Time: 31/08/2021/09:15
R/o : - -	Sampling Date/Time : 31/08/2021/
Age/Sex : 30 Years/Female	Sample : -
Barcode : 	Center : MEDIWHEEL

RADIOLOGY

X-RAY CHEST PA VIEW*

Lung fields are clear.

Cardia is normal.


Hila are normal.

C P angles are free.

Bony cage is normal.

Soft tissues are normal.

IMPRESSION : NORMAL CHEST X-RAY.


Dr. PRAJAKTA SUKHADEVE
DNB RADIOLOGY
Reg. No. 68493

****End of Report****

Printed on : 31/08/2021 / 11.42

The Test marked with *are not accredited by NABL

Lab Timings (Weekdays) : 7.00 am to 8.30 pm

Sundays & Holidays : 7.00 am to 1.00 pm

Radiologists Timings(Weekdays) : 7.30 am to 1.30 pm

& 5.30 pm to 7.30 pm

Sundays & Holidays : 7.30 am to 1.30 pm

Free Home Visit for Sample Collection.

Call : 7995421787, 7093445852,8121147282, 9885202212

ID: 449585 31-08-2021 09:58:23 AM
MS.MOHAMMED RESHMA ANJUM
Female 30Years

CARDIART

HR : 72 bpm
P : 97 ms
PR : 125 ms
QRS : 81 ms
QT/QTc : 392/432 ms
P/QRS/T : 34/58/47 °
RV5/SV1 : 1.519/0.592 mV

Diagnosis Information:
Sinus Rhythm
Normal ECG

Dr PANDURANGA
MBBS, DM
Consultant Interventional Cardiac Catheterisation
Reg No TMO/RI/10500

Report Confirmed by: