

## HEALTH CHECK UP

Name : Kamya Redi

Date : 13/4/24

Age : 49

Sex : Male / Female

Marital status : Married / Single

### PERSONAL HISTORY

Habits : Smoking / Tobacco & Snuff / Alcohol No

Drug allergy if any : .....

Medical : ..... nil

Surgical : .....

Height 157 cm Weight 57 Kg. BP 130/80 Pulse 76 mt

Vision : Rt 6/12 Lt 6/12 With Spectacles ..... Rt. .... Lt. ....

Colour Vision : Normal / Abnormal Near Vision N/G / BE

### FAMILY HISTORY

Father ..... Mother ..... Siblings .....

CVS : Heart Sound ..... Normal Murmurs ..... Absent Thrills ..... Absent

RS : Rate ..... /mt Breath sounds ..... Normal Adventitious ..... Absent

ABDOMEN : Tenderness ..... Absent Rigidity ..... Absent Bowel sound ..... Normal

Liver ..... NAD Kidney ..... NAD Hernia ..... Absent

CNS : Cranial Nerves ..... NAD Sensory System ..... NAD Motor System ..... NAD

ENT ..... NAD

Remarks

---

Dr. Bharti Jeswani MBBS	Dr. Seema Kale MBBS, MD	Dr. S. K. Suri MBBS	Dr. Meenakshi MBBS
----------------------------	----------------------------	------------------------	-----------------------

HOME SAMPLE COLLECTION FACILITY AVAILABLE

*Licensee* : Bharti Medicare Pvt. Ltd. The Apollo Clinic, C-70, Major Sudesh Kumar Marg, Opp. Madhav Park, Near Main Market, Rajouri Garden, New Delhi-110 027  
Phone : (011) 2591 8222 / 8333 / 8444, 9811061009, E-mail : rajourigarden@theapolloclinic.com, Website : www.apolloclinicrajourigarden.com

MSME UAM NO. : DL11E0021531

**Health Check up Booking Confirmed Request(35D5049),Package Code-  
PKG10000474, Beneficiary Code-311056**

Mediwheel <wellness@mediwheel.in>  
To: theapolloclinicrajourigarden@gmail.com  
Cc: customercare@mediwheel.in

Wed, Apr 10, 2024 at 6:50 PM



011-41195959

Hi **Apollo Bharti Apollo Bharti Medicare Pvt. Ltd.** ,

The following booking has been confirmed. It is requested to honor the said booking & provide priority services to our client

**Hospital Package Name** : Mediwheel Full Body Health Checkup Male Below 40

*Female Above 40y*

**Patient Package Name** : Executive Health Checkup Male

**Hospital Address** : C70, Opp. Madhav Park, Major Sudesh Kumar Marg -110027

**Contact Details** : 9769401103

**Appointment Date** : 13-04-2024

**Confirmation Status** : Booking Confirmed

**Preferred Time** : 9:00am

Member Information		
Booked Member Name	Age	Gender
Kavita Rathi	49 year	Female

We request you to facilitate the employee on priority.

Thanks,  
Mediwheel Team  
Please Download Mediwheel App



You have received this mail because your e-mail ID is registered with **Arcofemi Healthcare Limited** This is a system-generated e-mail please don't reply to this message.

Please visit to our Terms & Conditions for more informaion. Click here to unsubscribe.

NAME: MS KAVITA RATHI  
REF

AGE: 49 / Sex / F  
DATE 13/04 /2024

**ECHO ADULT (COLOUR DOPPLER)**

DIMENSIONS	NORMAL	DIMENSIONS	NORMAL
Ao (ed) 28.0 mm	(1.5 cm/m <sup>2</sup> )	IVS (Ed) 09.5 mm	(0.6-1.2cm)
LA (es) 29.0 mm	(1.5 cm/m <sup>2</sup> )	LVPW (Ed) 09.0 mm	(.6-1.1cm)
RVID (ed) Normal	(0.9cm/m <sup>2</sup> )	EF	58.0 % (0.62-0.85)
LVID (ed) 38.6 mm	(2.6-3.4 cm/m <sup>2</sup> )	FS	30.0
LVID (es) 25.0 mm			

**MORPHOLOGICAL DATA**

Mitral Valve Normal

Interatrial Septum Normal

Aortic Valve Normal

Interventricular Septum Normal

Tricuspid Valve Normal

Pulmonary Artery Normal

Pulmonary Valve Normal

Aorta Normal

Right Ventricle Normal

Right Atrium Normal

Left Ventricle Normal

Left Atrium Normal

Pericardium Normal

Colour Doppler TRACE TR, NO PAH, IVC NORMAL, LV DIASTOLIC FUNCTION NORMAL

Wall motion Normal

IMPRESSION : NORMAL STUDY

  
DR SEEMA KALE MD  
SEN. (PHYSICIAN)

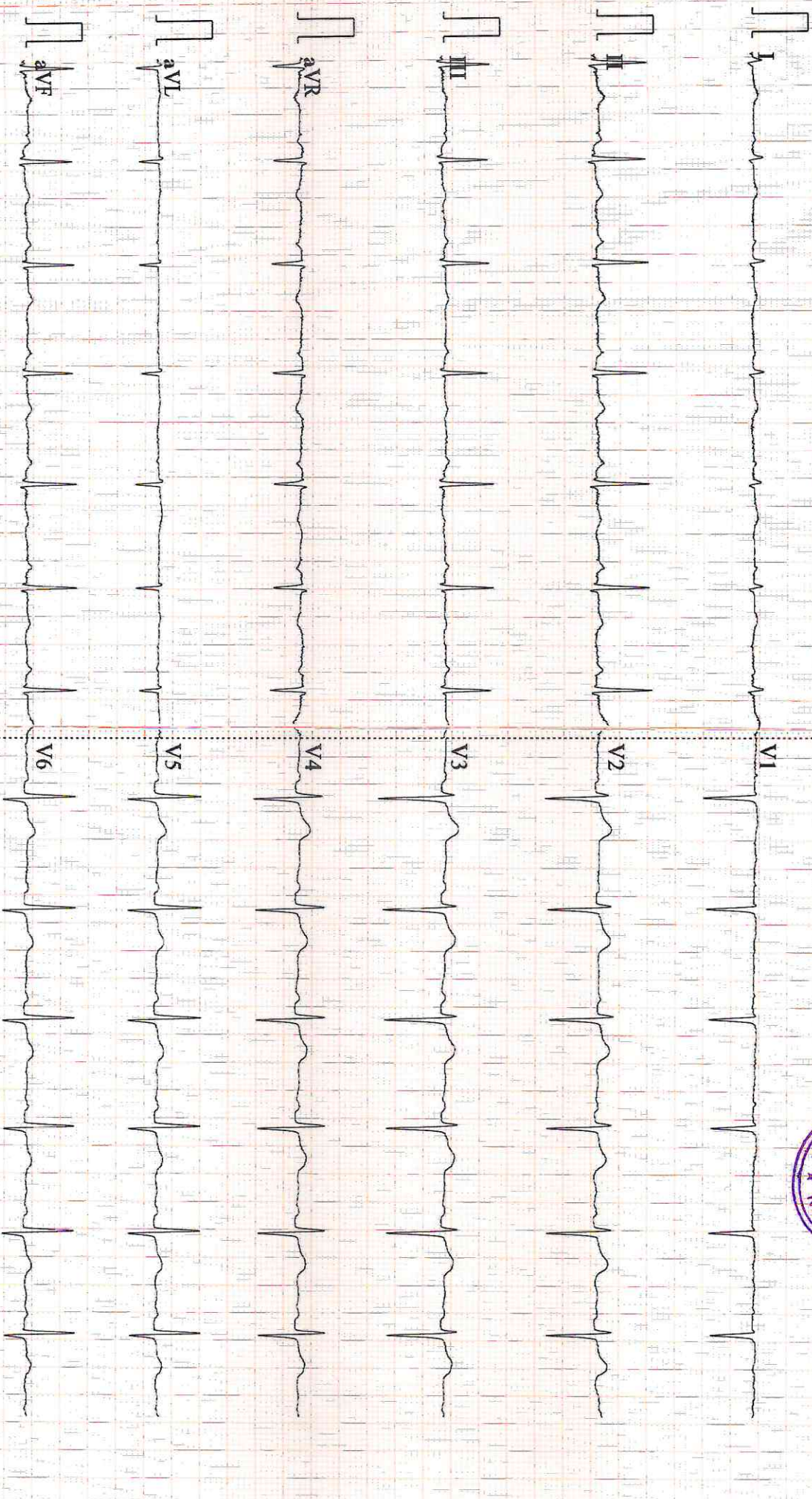
THE APOLLO CLINIC  
Rajouri Garden  
Dr. Seema Kale  
MBBS MD  
DMC Reg No-14927

kavita rathi  
Female 49 Years  
151cm 57kg 133/80 mmHg  
Req. No. :  
Room No. : 5

HR : 76 bpm  
P : 96 ms  
PR : 160 ms  
QRS : 78 ms  
QT/QTcBz : 382/430 ms  
P/QRS/T : 66/81/54 °  
RV5/SV1 : 0.831/0.809 mV

Diagnosis Information:  
Sinus rhythm  
Normal ECG

Report Confirmed by:



Kavita  
13/4/24

I am not interesting for  
stool sample

Kavita  
9892409732

• CLINICAL CORRELATION IS ESSENTIAL FOR FINAL DIAGNOSIS. • IF THE TESTS RESULTS ARE UNEXPECTED PLEASE CONTACT THE LABORATORY.  
• ALL THE CONGENITAL ANAMOLIES IN THE FETUS MAY NOT BE DIAGNOSED IN ULTRASONOGRAPHY. • THIS REPORT IS NOT VALID FOR MEDICOLEGAL PURPOSE.

Licensee : Bharti Medicare Pvt. Ltd. The Apollo Clinic, C-70, Major Sudesh Kumar Marg, Opp. Madhav Park, Near Main Market, Rajouri Garden, New Delhi-110 027  
Phone : (011) 2591 8222 / 8333 / 8444, 📞 9811061009, E-mail : rajourigarden@theapolloclinic.com, Website : www.apolloclinicrajourigarden.com

**MSME UAM NO. : DL11E0021531**

**Patient Name** : Mrs. Kavita Rathi  
**UHID/MR No.** : FRAJ.0000245723  
**Visit Date** : 13-04-2024 08:45  
**Sample Collected on** : 13-04-2024 08:50  
**Sample No** : WHB1404058  
**Ref Doctor** : SELF  
**Emp/Auth/TPA ID** : 32432  
**Sponsor Name** : MEDIWHEELS HEALTH CARE

**Age / Gender** : 49Y/Female  
**OP Visit No** : FRAJOPV121278  
**Reported on** : 13-04-2024 14:19  
**Specimen** : Whole Blood (Edta)  
**Pres Doctor:** :


**DEPARTMENT OF LABORATORY MEDICINE**

TEST NAME	RESULT	BIOLOGICAL REFERENCE INTERVALS	UNITS
<b>COMPLETE BLOOD COUNT</b>			
Hb (Haemoglobin) Method: Non Cyanide	10.1*	11 - 15	gm/dl
PCV/Haematocrit Method: RBC pulse height detect	32.6*	36 - 46	%
ESR. Method: Westergren's Method	18	0 - 20	mm/1st Hr
TLC Method: DC Detection Method	5800	4000 - 10000	/cumm.
RBC COUNT. Method: DC Detection Method	3.82	3.8 - 4.8	Million/cmm
PLATELET COUNT Method: DC Detection Method	2.91	1.5 - 4.1	lakh/cumm.
MCV Method: Derived	85.5	77 - 98	fl
MCH Method: Derived	26.5*	27 - 32	pg
MCHC Method: Derived	31.1*	31.5 - 34.5	gm/dl
NEUTROPHIL Method: Microscopy	70	40 - 70	%
LYMPHOCYTE Method: Microscopy	25	20 - 40	%
EOSINOPHIL Method: Microscopy	02	1.0 - 6.0	%
MONOCYTE Method: Microscopy	03	2.0 - 10.0	%
<b>BLOOD GROUP AND RH TYPE</b>			
ABO Group	B		
RH	Positive		

**End of the report**

*Results are to be correlated clinically*

Lab Technician/Technologist  
Yogita

  
Dr. Prashant Purwar  
MBBS, DCP  
Consultant Pathologist

• CLINICAL CORRELATION IS ESSENTIAL FOR FINAL DIAGNOSIS. • IF THE TESTS RESULTS ARE UNEXPECTED PLEASE CONTACT THE LABORATORY.  
 • ALL THE CONGENITAL ANAMOLIES IN THE FETUS MAY NOT BE DIAGNOSED IN ULTRASONOGRAPHY. • THIS REPORT IS NOT VALID FOR MEDICOLEGAL PURPOSE.

Licensee : Bharti Medicare Pvt. Ltd. The Apollo Clinic, C-70, Major Sudesh Kumar Marg, Opp. Madhav Park, Near Main Market, Rajouri Garden, New Delhi-110 027  
 Phone : (011) 2591 8222 / 8333 / 8444, 9811061009, E-mail : rajourigarden@theapolloclinic.com, Website : www.apolloclinicrajourigarden.com

**MSME UAM NO. : DL11E0021531**

**Patient Name** : Mrs. Kavita Rathi  
**UHID/MR No.** : FRAJ.0000245723  
**Visit Date** : 13-04-2024 08:45  
**Sample Collected on** : 13-04-2024 10:17  
**Sample No** : PLF1340276  
**Ref Doctor** : SELF  
**Emp/Auth/TPA ID** : 32432  
**Sponsor Name** : MEDIWHEELS HEALTH CARE

**Age / Gender** : 49Y/Female  
**OP Visit No** : FRAJOPV121278  
**Reported on** : 14-04-2024 10:25  
**Specimen** : Plasma(Fluoride)  
**Pres Doctor:** :

## DEPARTMENT OF LABORATORY MEDICINE

TEST NAME	RESULT	BIOLOGICAL REFERENCE INTERVALS	UNITS
<b>GLUCOSE - ( FASTING )</b>			
GLUCOSE - ( FASTING ) Method: (GOD-POD).	88	70 - 110	mg/dL
<b>GLUCOSE - ( POST PRANDIAL )</b>			
GLUCOSE - ( POST PRANDIAL ) Method: (GOD-POD)	122	70-140	mg/dl
<b>GLYCOSYLATED HEMOGLOBIN (HBA1C)</b>			
GLYCOSYLATED HEMOGLOBIN (HBA1C) - WHOLE BLOOD Method: BORONATE AFFINITY	5.8	4.2 - 6.0	%
<b>LIPID PROFILE TEST (PACKAGE)</b>			
CHOLESTEROL Method: CHOD - PAP	173	Desirable < 200 Borderline High : 200-239 High : > 240	mg/dl
Triglyceride Method: GPO-PAP	74	50-200	mg/dl
HDL Method: DIRECT	55.5	30 - 70	mg/dl
LDL Method: DIRECT	102.7*	60 - 100	mg/dl
VLDL Method: Calculated	14.8	<40	mg/dl
CHOLESTEROL / HDL RATIO Method: Calculated.	3.1	0 - 4.5	
<b>Thyroid Profile 2(Free T4, Free T3 And TSH)</b>			
Serum FT3	4.0	3.2 - 5.9	pmol/l
Serum FT4	12.9	10.6 - 21.0	pmol/l
Serum TSH	2.6	0.38 - 5.0	uIU/ml

End of the report

Results are to be correlated clinically

Lab Technician / Technologist  
Yogita

Dr. Prashant Purwar  
MBBS, DCP  
Consultant Pathologist

• CLINICAL CORRELATION IS ESSENTIAL FOR FINAL DIAGNOSIS. • IF THE TESTS RESULTS ARE UNEXPECTED PLEASE CONTACT THE LABORATORY.  
• ALL THE CONGENITAL ANAMOLIES IN THE FETUS MAY NOT BE DIAGNOSED IN ULTRASONOGRAPHY. • THIS REPORT IS NOT VALID FOR MEDICOLEGAL PURPOSE.

Licensee : Bharti Medicare Pvt. Ltd. The Apollo Clinic, C-70, Major Sudesh Kumar Marg, Opp. Madhav Park, Near Main Market, Rajouri Garden, New Delhi-110 027  
Phone : (011) 2591 8222 / 8333 / 8444, 9811061009, E-mail : rajourigarden@theapolloclinic.com, Website : www.apolloclinicrajourigarden.com

MSME UAM NO. : DL11E0021531

**Patient Name** : Mrs. Kavita Rath  
**UHID/MR No.** : FRAJ.0000245723  
**Visit Date** : 13-04-2024 08:45  
**Sample Collected on** : 13-04-2024 08:50  
**Sample No** : SR01912971  
**Ref Doctor** : SELF  
**Emp/Auth/TPA ID** : 32432  
**Sponsor Name** : MEDIWHEELS HEALTH CARE

**Age / Gender** : 49Y/Female  
**OP Visit No** : FRAJOPV121278  
**Reported on** : 14-04-2024 10:26  
**Specimen** : Serum  
**Pres Doctor:** :


### DEPARTMENT OF LABORATORY MEDICINE

TEST NAME	RESULT	BIOLOGICAL REFERENCE INTERVALS	UNITS
<b>LIVER FUNCTION TEST (PACKAGE)</b>			
BILIRUBIN - TOTAL. Method: Jendrassik	0.71	0.1 - 1.3	mg/dl
Bilirubin (Direct)-Serum Method: Diazo.	0.18	0 - 0.3	mg/dl
A/G Method: Calculated	1.4	1.0 - 2.0	
BILIRUBIN - INDIRECT. Method: Calculated.	0.53	<1.1	
SGOT /AST Method: IFCC (With P5P)	24.3	0 - 35	U/L
SGPT/ALT Method: IFCC (With P5P)	29.1	0 - 45	U/L
ALKALINE PHOSPHATE Method: AMP BUFFER	75.1	30 - 117	U/L
GGT. Method: SZAZ	12.0	10 - 50	U/L
TOTAL PROTEIN Method: Biuret	7.0	5.8-8.0	g/dl
ALBUMIN Method: BCG	4.1	3.7-5.2	g/dl
GLOBULIN Method: Calculated	2.9	2.5 - 3.5	mg/dL

End of the report

Results are to be correlated clinically

  
 Lab Technician / Technologist  
 Yogita

  
 Dr. Prashant Purwar  
 MBBS, DCP  
 Consultant Pathologist

• CLINICAL CORRELATION IS ESSENTIAL FOR FINAL DIAGNOSIS. • IF THE TESTS RESULTS ARE UNEXPECTED PLEASE CONTACT THE LABORATORY.  
 • ALL THE CONGENITAL ANAMOLIES IN THE FETUS MAY NOT BE DIAGNOSED IN ULTRASONOGRAPHY. • THIS REPORT IS NOT VALID FOR MEDICOLEGAL PURPOSE.

Licensee : Bharti Medicare Pvt. Ltd. The Apollo Clinic, C-70, Major Sudesh Kumar Marg, Opp. Madhav Park, Near Main Market, Rajouri Garden, New Delhi-110027  
 Phone : (011) 2591 8222 / 8333 / 8444, 9811061009, E-mail : rajourigarden@theapolloclinic.com, Website : www.apolloclinicrajourigarden.com

MSME UAM NO. : DL11E0021531



**Patient Name** : Mrs. Kavita Rathi  
**UHID/MR No.** : FRAJ.0000245723  
**Visit Date** : 13-04-2024 08:45  
**Sample Collected on** : 13-04-2024 08:50  
**Sample No** : SR01912971  
**Ref Doctor** : SELF  
**Emp/Auth/TPA ID** : 32432  
**Sponsor Name** : MEDIWHEELS HEALTH CARE

**Age / Gender** : 49Y/Female  
**OP Visit No** : FRAJOPV121278  
**Reported on** : 14-04-2024 10:27  
**Specimen** : Serum  
**Pres Doctor:** :

**DEPARTMENT OF LABORATORY MEDICINE**


TEST NAME	RESULT	BIOLOGICAL REFERENCE INTERVALS	UNITS
<b>KFT - RENAL PROFILE-SERUM</b>			
UREA Method: Urease	17.3	10-50	mg/dl
Creatinine Method: Jaffe	0.88	0.5 - 1.3	mg/dl
Uric Acid Method: Uricase	3.9	2.6 - 6	mg/dl
Sodium(Na) Method: ISE	136.0	136 - 142	mmol/L
Potassium(K) Method: ISE	4.5	3.8 - 5.0	mmol/L
Chloride(Cl) Method: ISE	101.9	95 - 103	mmol/L
Calcium. Method: OCPC	9.3	9.2 - 11.0	mg/dl
Phosphorus Method: Molybdate UV	3.4	2.3 - 4.7	mg/dl

End of the report

*Results are to be correlated clinically*

Lab Technician/Technologist  
Yogita



  
 Dr. Prashant Purwar  
 MBBS, DCP  
 Consultant Pathologist

• CLINICAL CORRELATION IS ESSENTIAL FOR FINAL DIAGNOSIS. • IF THE TESTS RESULTS ARE UNEXPECTED PLEASE CONTACT THE LABORATORY.  
 • ALL THE CONGENITAL ANOMALIES IN THE FETUS MAY NOT BE DIAGNOSED IN ULTRASONOGRAPHY. • THIS REPORT IS NOT VALID FOR MEDICOLEGAL PURPOSE.

**Licensee** : Bharti Medicare Pvt. Ltd. The Apollo Clinic, C-70, Major Sudesh Kumar Marg, Opp. Madhav Park, Near Main Market, Rajouri Garden, New Delhi-110 027  
 Phone : (011) 2591 8222 / 8333 / 8444, 9811061009, E-mail : rajourigarden@theapolloclicin.com, Website : www.apolloclicinrajourigarden.com

**MSME UAM NO. : DL11E0021531**

**Patient Name** : Mrs. Kavita Rathi  
**UHID/MR No.** : FRAJ.0000245723  
**Visit Date** : 13-04-2024 08:45  
**Sample Collected on** : 13-04-2024 08:50  
**Sample No** : UR1050711  
**Ref Doctor** : SELF  
**Emp/Auth/TPA ID** : 32432  
**Sponsor Name** : MEDIWHEELS HEALTH CARE

**Age / Gender** : 49Y/Female  
**OP Visit No** : FRAJOPV121278  
**Reported on** : 13-04-2024 15:59  
**Specimen** : Urine  
**Pres Doctor:** :

**DEPARTMENT OF LABORATORY MEDICINE**

**URINE ROUTINE EXAMINATION**

**URINE EXAMINATION TEST REPORT**

Test Name	Observed Value	Unit	Reference Range
<b>Urine R/M Examination</b>			
Quantity	30	ml.	
Colour	Pale Yellow		Pale Yellow
Tranparency	Clear		Clear
Urine Specific Gravity	1.020		1.005 - 1.030
Dipstick			
pH	6.0		5.5 - 7.5
Dipstick / pH paper			
<b>Chemical Examination</b>			
Protein	Nil		Nil
Dipstick/Heat & acetic acid			
Sugar	Nil		Nil
Dipstick/Benedicts reagent			
<b>Microscopic Examination</b>			
Pus Cells	1-2	/HPF	1-2
RBC'S	Nil	/HPF	Nil
Casts	Nil	/HPF	Nil
Crystals	Nil		Nil
Epithelial Cells	2-4	/HPF	1-2
Bacteria	Nil	/HPF	Nil

**End of the report**

*Results are to be correlated clinically*

Lab Technician / Technologist  
Rakesh

  
Dr. Prashant Purwar  
MBBS, DCP  
Consultant Pathologist

Patient Name : Mrs Kavita Rath	MR No	: FRAJ0000
Age/Sex : 49Y/F	Visit No	: FRAJOPV
Pres Doctor :	Bill Date	: 13.04.2024
Ref.by :	Report Date	: 13.04.2024

**MAMMOGRAPHY**

(Cranio-caudal and mediolateral oblique views were taken for bilateral breasts with optimal compression technique.)

Bilateral breasts show predominantly fatty tissue with interspersed fibroglandular tissue (ACR TYPE A).

No definite space occupying lesion is noted in either breast.

No microcalcification is seen in either breast.

No architectural distortion is noted.


Nipples are normal in position and no nipple retraction is noted.

No definite skin thickening is noted on either side.

**IMPRESSION : NORMAL STUDY.**

To be correlate clinically.

**BIRADS-0**

  
Dr. Rahul Gera  
Consultant Radiologist.

• CLINICAL CORRELATION IS ESSENTIAL FOR FINAL DIAGNOSIS. • IF THE TESTS RESULTS ARE UNEXPECTED PLEASE CONTACT THE LABORATORY.  
• ALL THE CONGENITAL ANOMALIES IN THE FETUS MAY NOT BE DIAGNOSED IN ULTRASONOGRAPHY. • THIS REPORT IS NOT VALID FOR MEDICOLEGAL PURPOSE.

Licensee : Bharti Medicare Pvt. Ltd. The Apollo Clinic, C-70, Major Sudesh Kumar Marg, Opp. Madhav Park, Near Main Market, Rajouri Garden, New Delhi-110 027  
Phone : (011) 2591 8222 / 8333 / 8444, 9811061009, E-mail : rajourigarden@theapolloclicin.com, Website : www.apolloclicinrajourigarden.com

**MSME UAM NO. : DL11E0021531**

Patient Name : Mrs.Kavita Rathi	MR No	: FRAJ0000
Age/Sex : 49Y/F	Visit No	: FRAJOPV
Pres Doctor :	Bill Date	: 13.04.2024
Ref.by :	Report Date	: 13.04.2024


---

**X-RAY CHEST PA VIEW**

- Both lungs fields do not show any active parenchymal lesion.
- Both costophrenic angles are normal.
- B/L hila appear normal in size & density.
- Both domes of diaphragm are normal.
- Cardiac silhouette appears normal.
- Visualised soft tissues and bony cage appear normal.

**IMPRESSION:- NORMAL STUDY.**

To be correlate clinically.

  
**Dr. Rahul Gera**  
Consultant Radiologist.

• CLINICAL CORRELATION IS ESSENTIAL FOR FINAL DIAGNOSIS. • IF THE TESTS RESULTS ARE UNEXPECTED PLEASE CONTACT THE LABORATORY.  
• ALL THE CONGENITAL ANAMOLIES IN THE FETUS MAY NOT BE DIAGNOSED IN ULTRASONOGRAPHY. • THIS REPORT IS NOT VALID FOR MEDICOLEGAL PURPOSE.

Licensee : Bharti Medicare Pvt. Ltd. The Apollo Clinic, C-70, Major Sudesh Kumar Marg, Opp. Madhav Park, Near Main Market, Rajouri Garden, New Delhi-110 027  
Phone : (011) 2591 8222 / 8333 / 8444, 9811061009, E-mail : rajourigarden@theapolloclinic.com, Website : www.apolloclinicrajourigarden.com

**MSME UAM NO. : DL11E0021531**

Patient Name : Kavita Rathi	MR No	: FRAJ0000
Age/Sex : 49Y/F	Visit No	: FRAJOPV
Pres Doctor :	Bill Date	: 13.04.2024
Ref.by :	Report Date	: 13.04.2024

### ULTRASOUND WHOLE ABDOMEN

**LIVER:** Liver is normal in shape, size and echotexture. No focal intra-hepatic lesion detected. Intra-hepatic biliary radicals are not dilated. Portal vein is normal in calibre.

**GALL BLADDER:** Gall bladder is well visualized. It is normal in size, shape & position. Its wall thickness is normal. No calculus or mass lesion is seen in gall bladder. Common bile duct is normal (not dilated).

**PANCREAS:** Pancreas appears normal in size and echopattern.

**SPLEEN:** Spleen appears normal in size and echopattern.

**KIDNEYS:** Both kidneys are normal in position, size and outline. Cortico-medullary differentiation of both kidneys is maintained. Central sinus echoes are compact. No calculus / hydronephrosis seen. Visualised parts of retroperitoneum do not show any lymphadenopathy.

**URINARY BLADDER:** Urinary bladder is well distended and shows clear contents.

**UTERUS:** Uterus is anteverted and normal .

Endometrium is central and appears normal .

Myometrial echogenicity appears normal.


**OVARY:** B/L ovaries are normal in size, shape & echopattern.

.Both adnexal regions are normal.

No free fluid is seen in cul-de-sac.

**IMPRESSION: - NORMAL STUDY.**

To be correlate clinically.

Dr. Shailza Minocha   
Consultant Radiologist.

• CLINICAL CORRELATION IS ESSENTIAL FOR FINAL DIAGNOSIS. • IF THE TESTS RESULTS ARE UNEXPECTED PLEASE CONTACT THE LABORATORY.  
• ALL THE CONGENITAL ANAMOLIES IN THE FETUS MAY NOT BE DIAGNOSED IN ULTRASONOGRAPHY. • THIS REPORT IS NOT VALID FOR MEDICOLEGAL PURPOSE.

Licensee : Bharti Medicare Pvt. Ltd. The Apollo Clinic, C-70, Major Sudesh Kumar Marg, Opp. Madhav Park, Near Main Market, Rajouri Garden, New Delhi-110 027  
Phone : (011) 2591 8222 / 8333 / 8444, 9811061009, E-mail : rajourigarden@theapolloclicin.com, Website : www.apolloclicinrajourigarden.com

**MSME UAM NO. : DL11E0021531**