

DR. NETRAVALKAR'S ASHWINI PATHOLOGY LABORATORY

(For all investigations in Histopathology, Cytopathology, Haematology, Clinical Pathology, Microbiology & Hormonal Chemistry)

Consultant Pathologist : **Dr. Prasad Netravalkar** MBBS, MD. (Path) BOM.

(HOME COLLECTION FACILITY AVAILABLE)

Panaji : 1st, Floor, Rizvi Sadan, Above Saroj Emporium, Near Inox Theatre, Opp. Municipal Market, Panaji.
Ph.: 2229142, 8407912840, 8390242524

E-mail : ashwinilabpanaji@gmail.com, drprasadnetravalkar@gmail.com

Mapusa : F8, Ramchandra Chambers, 1st Floor, Mapusa Clinic Road, Mapusa - Bardez, Goa. Ph.: 2252320

Pt.No. : 66 080624

Pt.Name : - Navita Narayan Hiroji

Age : 48 Yrs. Sex : F

Ref. By : -

Date : 08-06-2024

Normal Range

COMPLETE HEMOGRAM

Haemoglobin	: 13.5 g/dl	11.5 - 16.5 g/dl
W.B.C Count	: 13600 cells/ cu-mm	4000 - 11000 cells/ cu-mm
R.B.C Count	: 4.75 millions / cu-mm	3.8 - 4.5 millions / cu-mm
MCV	: 80.6 fl	80 - 99 fl
MCH	: 28.3 Pg	27 - 33 Pg
MCHC	: 35.2 %	32 - 37 %
PCV	: 38.2 %	37 - 47 %
Platelet Count	: 3.69 lakhs /cu mm	1.5 - 4.5 lakhs /cu mm
E.S.R (Westergren)	: 11 mm/hr	0 - 20 mm/hr


DIFFERENTIAL COUNT

Stab Cells	: 03 %	1-5 %
Neutrophils	: 57 %	40- 60 %
Lymphocytes	: 30 %	20 - 45 %
Eosinophils	: 06 %	1 - 6 %
Monocytes	: 04 %	0 - 10 %
Basophils	: 00 %	0 - 1 %
Abnormal Cells	: Nil	

SMEAR EXAMINATION

RBC Morphology	: Normocytic , Normochromic
W.B.C Morphology	: Within Normal Limits
Platelets on Smear	: Adequate
Parasites	: Absent

Blood Group : 'O' Rh Positive



Pathologist

Dr. Prasad Netravalkar
MBBS, MD (Bom)
GMC Reg. No. 1294

We Care

All Diagnostic facilities under one roof in Panaji centre - Lab, ultrasound, X ray, ECG, TMT, ECHO

DR. NETRAVALKAR'S ASHWINI PATHOLOGY LABORATORY

(For all investigations in Histopathology, Cytopathology, Haematology, Clinical Pathology, Microbiology & Hormonal Chemistry)

Consultant Pathologist : **Dr. Prasad Netravalkar** MBBS, MD. (Path) BOM.

(HOME COLLECTION FACILITY AVAILABLE)

Panaji : 1st, Floor, Rizvi Sadan, Above Saroj Emporium, Near Inox Theatre, Opp. Municipal Market, Panaji.
Ph.: 2229142, 8407912840, 8390242524

E-mail : ashwinilabpanaji@gmail.com, drprasadnetravalkar@gmail.com

Mapusa : F8, Ramchandra Chambers, 1st Floor, Mapusa Clinic Road, Mapusa - Bardez, Goa. Ph.: 2252320

Pt.No. : 66 080624

Pt.Name : - Navita Narayan Hiroji

Ref. By : -

Age : 48 Yrs. Sex : F

Date : 08-06-2024

		<u>Normal Range</u>
Fasting Blood Sugar	: 120.0 mg/dl	70-110 mg/dl
2 Hrs. Blood Sugar	: 108.0 mg/dl	110-140 mg/dl

GLYCOSYLATED HAEMOGLOBIN IN BLOOD (HPLC METHOD)

HbA1C : 6.60 %

Mean Blood Glucose : 142 mg %

INTERPRETATION:

HbA1c %

NORMAL

Below 6.5 %

GOOD DIABETIC CONTROL

6.5 % - 7.5 %

FAIR CONTROL

7.5 % - 8.0 %

UNSATISFACTORY CONTROL

8.0 % - 10.0 %

POOR CONTROL

Above 10.0 %



Pathologist

Dr. Prasad Netravalkar
MBBS, MD (Bom)
GMC Reg. No. 1294

We Care

All Diagnostic facilities under one roof in Panaji centre - Lab, ultrasound, X ray, ECG, TMT, ECHO

DR. NETRAVALKAR'S ASHWINI PATHOLOGY LABORATORY

(For all investigations in Histopathology, Cytopathology, Haematology, Clinical Pathology, Microbiology & Hormonal Chemistry)

Consultant Pathologist : **Dr. Prasad Netravalkar** MBBS, MD. (Path) BOM

(HOME COLLECTION FACILITY AVAILABLE)

Panaji : 1st, Floor, Rizvi Sadan, Above Saroj Emporium, Near Inox Theatre, Opp. Municipal Market, Panaji.
Ph.: 2229142, 8407912840, 8390242524

E-mail : ashwinilabpanaji@gmail.com, drprasadnetravalkar@gmail.com

Mapusa : F8, Ramchandra Chambers, 1st Floor, Mapusa Clinic Road, Mapusa - Bardez, Goa. Ph.: 2252320

Pt.No. : 66 080624

Pt.Name : - Navita Narayan Hiroji

Ref. By : -

Age : 48 Yrs. Sex : F

Date : 08-06-2024

BIOCHEMISTRY REPORTS

Fasting Urine Glucose : Present (++)

2 Hrs. Urine Glucose : Absent



Pathologist

Dr. Prasad Netravalkar
MBBS, MD (Bom)
GMC Reg. No. 1294

We Care

All Diagnostic facilities under one roof in Panaji centre - Lab, ultrasound, X ray, ECG, TMT, ECG

DR. NETRAVALKAR'S ASHWINI PATHOLOGY LABORATORY

(For all investigations in Histopathology, Cytopathology, Haematology, Clinical Pathology, Microbiology & Hormonal Chemistry)

Consultant Pathologist : **Dr. Prasad Netravalkar** MBBS, MD (Path) BOM

(HOME COLLECTION FACILITY AVAILABLE)

Panaji : 1st, Floor, Rizvi Sadan, Above Saroj Emporium, Near Inox Theatre, Opp. Municipal Market, Panaji.
Ph.: 2229142, 8407912840, 8390242524

E-mail : ashwinilabpanaji@gmail.com, drprasadnetravalkar@gmail.com

Mapusa : F8, Ramchandra Chambers, 1st Floor, Mapusa Clinic Road, Mapusa - Bardez, Goa. Ph.: 2252320

Pt.No. : 66 080624

Pt.Name : - Navita Narayan Hiroji

Age : 48 Yrs. Sex : F

Ref. By : -

Date : 08-06-2024

Normal Range

LIPID PROFILE

Total Cholesterol	: 206.0 mg/dl	130 - 220 mg/dl
S. Triglycerides	: 168.0 mg/dl	35 - 170 mg/dl
HDL Cholesterol	: 44.0 mg/dl	> 45 mg/dl
LDL Cholesterol	: 128 mg/dl	< 130 mg/dl
VLDL Cholesterol	: 34 mg/dl	Upto 35 mg/dl
TC/HDL Ratio	: 4.7	< 4.5
LDLC/HDL Ratio	: 2.9	2.5 - 3.5



Pathologist

Dr. Prasad Netravalkar
MBBS, MD (Bom)
GMC Reg. No. 1294

We Care

All Diagnostic facilities under one roof in Panaji centre - Lab, ultrasound, X ray, ECG, TMT, Echo

DR. NETRAVALKAR'S ASHWINI PATHOLOGY LABORATORY

(For all investigations in Histopathology, Cytopathology, Haematology, Clinical Pathology, Microbiology & Hormonal Chemistry)

Consultant Pathologist : **Dr. Prasad Netravalkar** MBBS, MD. (Path) BOM.

(HOME COLLECTION FACILITY AVAILABLE)

Panaji : 1st, Floor, Rizvi Sadan, Above Saroj Emporium, Near Inox Theatre, Opp. Municipal Market, Panaji.
Ph.: 2229142, 8407912840, 8390242524

E-mail : ashwinilabpanaji@gmail.com, drprasadnetravalkar@gmail.com

Mapusa : F8, Ramchandra Chambers, 1st Floor, Mapusa Clinic Road, Mapusa - Bardez, Goa. Ph.: 2252320

Pt.No. : 66 080624

Pt.Name : - Navita Narayan Hiroji

Ref. By : -

Age : 48 Yrs. Sex : F

Date : 08-06-2024

Normal Range

LIVER FUNCTION TEST

S. Bilirubin (Total)	: 0.49	mg/dl	0 - 1 mg/dl
S. Bilirubin (Direct)	: 0.19	mg/dl	0 - 0.25 mg/dl
S. Bilirubin (Indirect)	: 0.3	mg/dl	0 - 0.75 mg/dl
S.G.O.T	: 22.0	U/L	0 - 42 U/L
S.G.P.T	: 24.0	U/L	0 - 42 U/L
S. Alkaline Phosphatase	: 61.0	IU/L	15 - 112 IU/L
GGTP	: 20.0	U/L	9-37 U/L
Total Proteins	: 6.81	g/dl	6.0 - 10.0 g/dl
S. Albumin	: 3.99	gm%	3.2 - 5.5 gm%
S. Globulin	: 2.8	g/dl	2.3 - 3.5 g/dl
A/G Ratio	: 1.4 : 1		



Pathologist

Dr. Prasad Netravalkar
MBBS, MD (Bom)
GMC Reg. No. 1294

We Care

All Diagnostic facilities under one roof in Panaji centre - Lab, ultrasound, X ray, ECG, TMT, ECHO

DR. NETRAVALKAR'S ASHWINI PATHOLOGY LABORATORY

(For all investigations in Histopathology, Cytopathology, Haematology, Clinical Pathology, Microbiology & Hormonal Chemistry)

Consultant Pathologist : **Dr. Prasad Netravalkar** MBBS, MD. (Path) BOM.

(HOME COLLECTION FACILITY AVAILABLE)

Panaji : 1st, Floor, Rizvi Sadan, Above Saroj Emporium, Near Inox Theatre, Opp. Municipal Market, Panaji.
Ph.: 2229142, 8407912840, 8390242524

E-mail : ashwinilabpanaji@gmail.com, drprasadnetravalkar@gmail.com

Mapusa : F8, Ramchandra Chambers, 1st Floor, Mapusa Clinic Road, Mapusa - Bardez, Goa. Ph.: 2252320

Pt.No. : 66 080624

Pt.Name : - Navita Narayan Hiroji

Age : 48 Yrs. Sex : F


Ref. By : -

Date : 08-06-2024

Normal Range

KIDNEY FUNCTION TESTS

Blood Urea	: 24.0 mg/dl	15 - 40 mg/dl
S. Creatinine	: 0.78 mg/dl	0.5 - 1.2 mg/dl
S. Uric Acid.	: 4.80 mg/dl	1.5 - 6.0 mg/dl
S. Sodium	: 131.6 mEq/L	135 - 155 mEq/L
S. Potassium	: 4.60 mEq/L	3.5 - 5.5 mEq/L
S. Chlorides	: 102.9 mEq/L	99 - 108 mEq/L



Pathologist

Dr. Prasad Netravalkar
MBBS, MD (Bom)
GMC Reg. No. 1294

We Care

All Diagnostic facilities under one roof in Panaji centre - Lab, ultrasound, X ray, ECG, TMT, ECHO

DR. NETRAVALKAR'S ASHWINI PATHOLOGY LABORATORY

(For all investigations in Histopathology, Cytopathology, Haematology, Clinical Pathology, Microbiology & Hormonal Chemistry)

Consultant Pathologist : **Dr. Prasad Netravalkar** MBBS, MD. (Path) BOM.

(HOME COLLECTION FACILITY AVAILABLE)

Panaji : 1st, Floor, Rizvi Sadan, Above Saroj Emporium, Near Inox Theatre, Opp. Municipal Market, Panaji.
Ph.: 2229142, 8407912840, 8390242524

E-mail : ashwinilabpanaji@gmail.com, drprasadnetravalkar@gmail.com

Mapusa : F8, Ramchandra Chambers, 1st Floor, Mapusa Clinic Road, Mapusa - Bardez, Goa. Ph.: 2252320

Pt.No. : 66 080624

Pt.Name : - Navita Narayan Hiroji

Age : 48 Yrs. Sex : F

Ref. By : -

Date : 08-06-2024

EXAMINATION OF URINE

PHYSICAL EXAMINATION

Quantity : 20 ml
Colour : Pale Yellow
Appearance : Slightly Hazy
pH : 6.5
Specific Gravity : 1.010

CHEMICAL EXAMINATION

Proteins : Present (+)
Glucose : Absent
Ketone Bodies : Absent
Bile Salts : Absent
Bile Pigments : Absent
Occult Blood : Negative
Urobilinogen : Normal

MICROSCOPIC EXAMINATION [As per hpf]

Epithelial Cells : 1 - 2 /hpf
Pus Cells : 0 - 1 /hpf
Red Blood Cells : Absent
Casts : Absent
Crystals : Absent



Pathologist

Dr. Prasad Netravalkar
MBBS, MD (Bom)
GMC Reg. No. 1294

We Care

All Diagnostic facilities under one roof in Panaji centre - Lab, ultrasound, X ray, ECG, TMT, ECHO

DR. NETRAVALKAR'S ASHWINI PATHOLOGY LABORATORY

(For all investigations in Histopathology, Cytopathology, Haematology, Clinical Pathology, Microbiology & Hormonal Chemistry)

Consultant Pathologist : **Dr. Prasad Netravalkar** MBBS, MD. (Path) BOM

(HOME COLLECTION FACILITY AVAILABLE)

Panaji : 1st, Floor, Rizvi Sadan, Above Saroj Emporium, Near Inox Theatre, Opp. Municipal Market, Panaji.

Ph.: 2229142, 8407912840, 8390242524

E-mail : ashwinilabpanaji@gmail.com, drprasadnetravalkar@gmail.com

Mapusa : F8, Ramchandra Chambers, 1st Floor, Mapusa Clinic Road, Mapusa - Bardez, Goa. Ph.: 2252320

Patient Name : NAMITA NARAYAN HIROJI

Referral : SELF

Age / Gender : 48 / Female

Reporting Time : Jun 08, 2024, 04:16 p.m.

Patient ID : 32964

Sample ID :



Source : DIRECT

Test Description	Value(s)	Reference Range	Unit
Thyroid Profile			
T3 (Total)	2.05	1.30 - 3.10	nmol/l
Method : Serum ECL			
T4 (Total)*	99.18	66.0 - 181.0	nmol/l
Method : Serum ECL			
TSH(Ultrasensitive)*	0.702	0.270 - 4.20	uIU/ml
Method : Serum ECL			

END OF REPORT



Pathologist

Dr. Prasad Netravalkar
MBBS, MD (Bom)
GMC Reg. No. 1294

We Care

All Diagnostic facilities under one roof in Panaji centre - Lab, ultrasound, X ray, ECG, TMT, ECHO



भारत सरकार
Unique Identification Authority of India
Government of India

Enrolment No.: 2076/12789/01924

Download Date: 08/01/2018

To
Navita Narayan Hiroji
W/O Narayan Sajo Hiroji
H.No.295/1/A
Carrem-Vaddem,Socorro
Near Shree Vetel Temple
Porvorim
Porvorim
North Goa Goa - 403501
9545008589

Generation Date: 08/12/2018

Signature valid

Digitally signed by Navita Narayan Hiroji
UIDAI, INDIA
Date: 2018.12.08 19:49:42
+05'30'



QR Code with Photograph

आपका आधार क्रमांक / Your Aadhaar No. :

4528 1784 5205

VID : 9157 9347 2524 4309

मेरा आधार, मेरी पहचान



भारत सरकार
Government of India



Navita Narayan Hiroji
Date of Birth/DOB: 11/12/1975
Female/ FEMALE



4528 1784 5205

VID : 9157 9347 2524 4309

मेरा आधार, मेरी पहचान



Handwritten signature: Hiroji

Handwritten signature: [unclear]

**DR. NETRAVALKAR'S
ASHWINI PATHOLOGY LABORATORY**

(For all investigations in Histopathology, Cytopathology, Haematology, Clinical Pathology, Microbiology & Hormonal Chemistry)
Consultant Pathologist : **Dr. Prasad Netravalkar** MBBS, MD. (Path) BOM.
(HOME COLLECTION FACILITY AVAILABLE)

Panaji : 1st, Floor, Rizvi Sadan, Above Saroj Emporium, Near Inox Theatre, Opp. Municipal Market, Panaji.
Ph.: 2229142, 8407912840, 8390242524
E-mail : ashwinilabpanaji@gmail.com, drprasadnetravalkar@gmail.com

Mapusa : F8, Ramchandra Chambers, 1st Floor, Mapusa Clinic Road, Mapusa - Bardez, Goa. Ph.: 2252320

Patients Name : Navita Hiroji 48yrs/F

Date : 11/06/24

Ref. by Dr :

CYTOPATHOLOGY REPORT

Specimen Sent : Pap Smears.

Report : Pap smears show moderate sheets of intermediate epithelial cells, few sheets of superficial epithelial cells and occasional groups of endocervical epithelial cells.

The epithelial cells show normal nucleus:cytoplasm ratio. Their nuclear chromatin is regular and well scattered.

Occasional neutrophils & Dod. Bacilli are seen in background.

No fungi or protozoa seen.

No evidence of dysplasia or malignancy seen.

Opinion : Pap smears show no significant pathology.




Pathologist

Dr. Prasad Netravalkar
MBBS, MD (Bom)
GMC Reg. No. 1294


We Care

All Diagnostic facilities under one roof in Panaji centre - Lab, ultrasound, X ray, ECG, TMT, ECHO



Dr. Netravalkar's
Dr. Prasad Netravalkar
M.B.B.S. M.D. (Pain)
GMC Reg. No. 1254
Astivini Pathology Lab

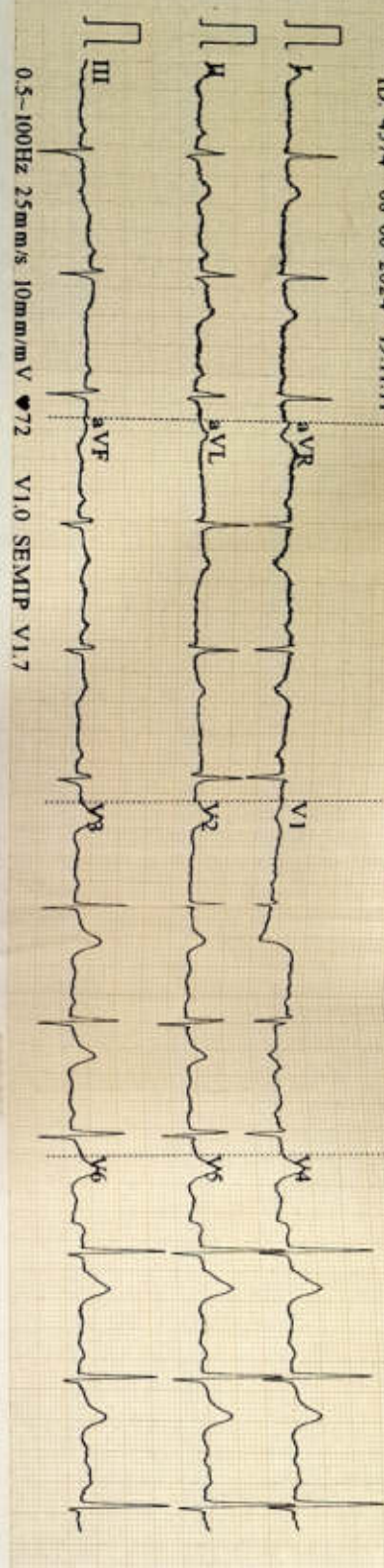
GPS Map Camera



Google

Panaji, Goa, India
B 165, New Municipal Market, Panaji, Goa 403001, India
Lat 15.498467°
Long 73.822404°
08/06/24 08:43 AM GMT +05:30

ID: 4574 08-06-2024 19:11:11



ID: 4574

Female / mmHg
 48Years cm kg

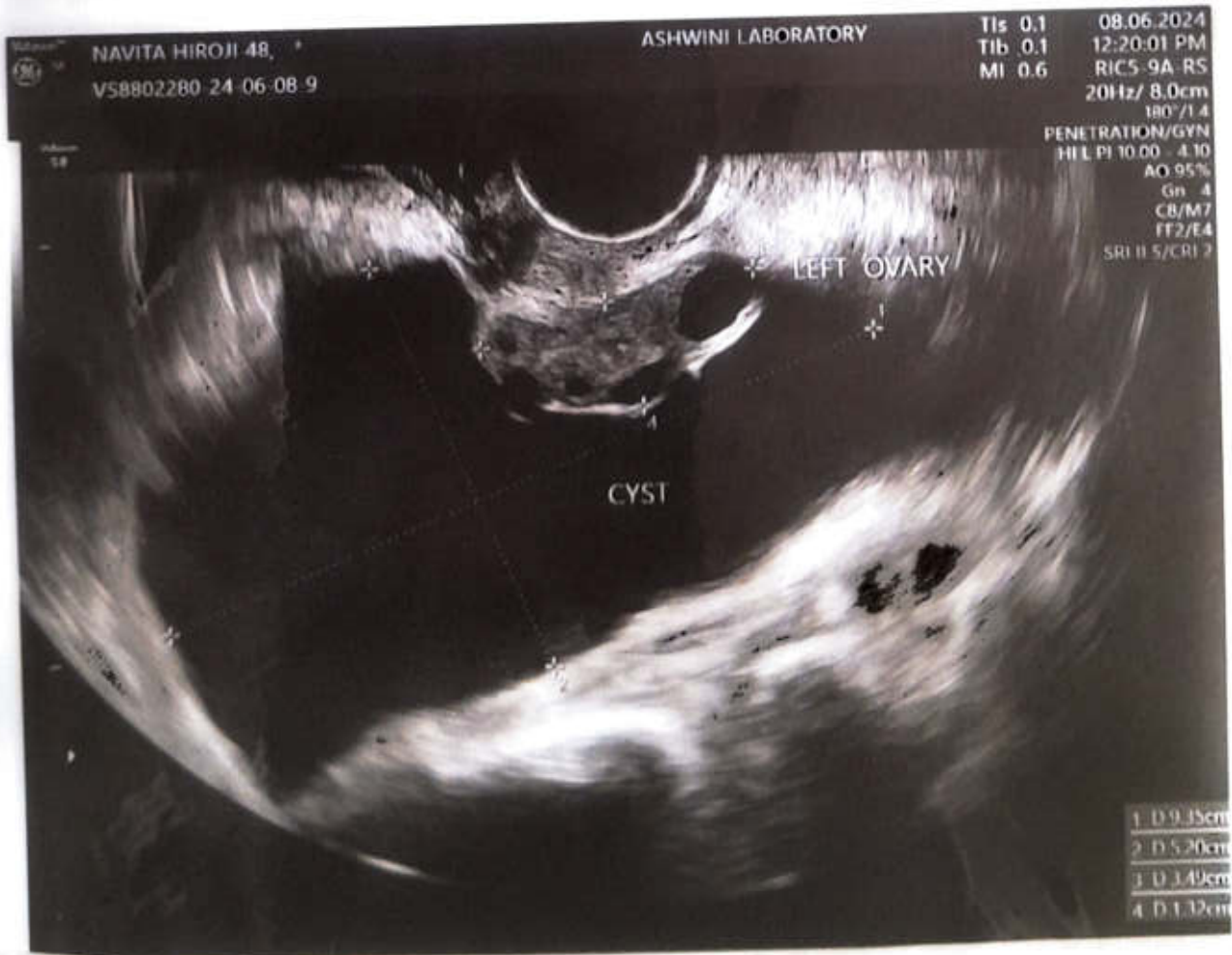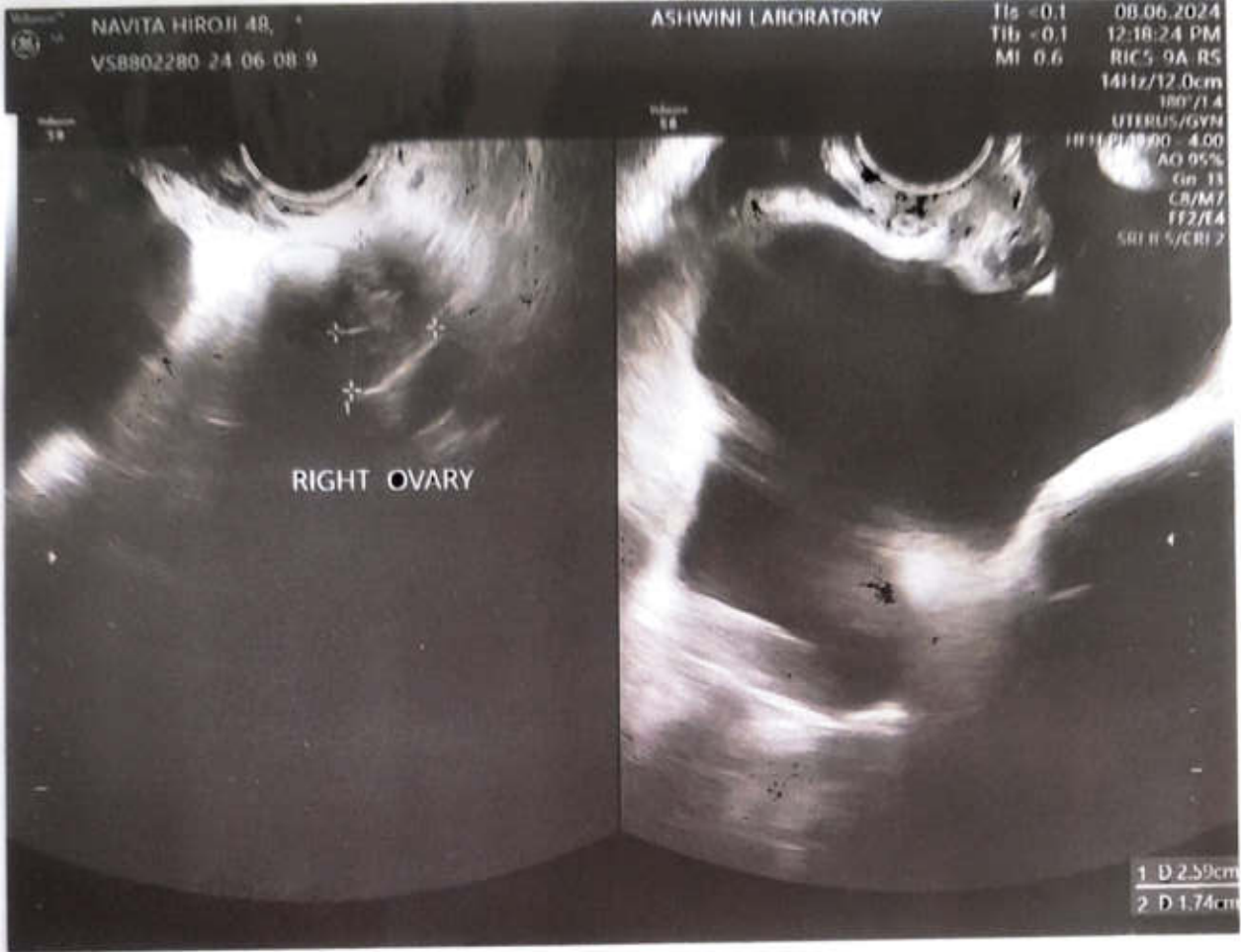HR 71 bpm
 P 119 ms
 PR 177 ms
 QRS 80 ms
 QTc 400.438 ms
 PQRS 492/35
 RV5/SVI 1.425/0.566 mV

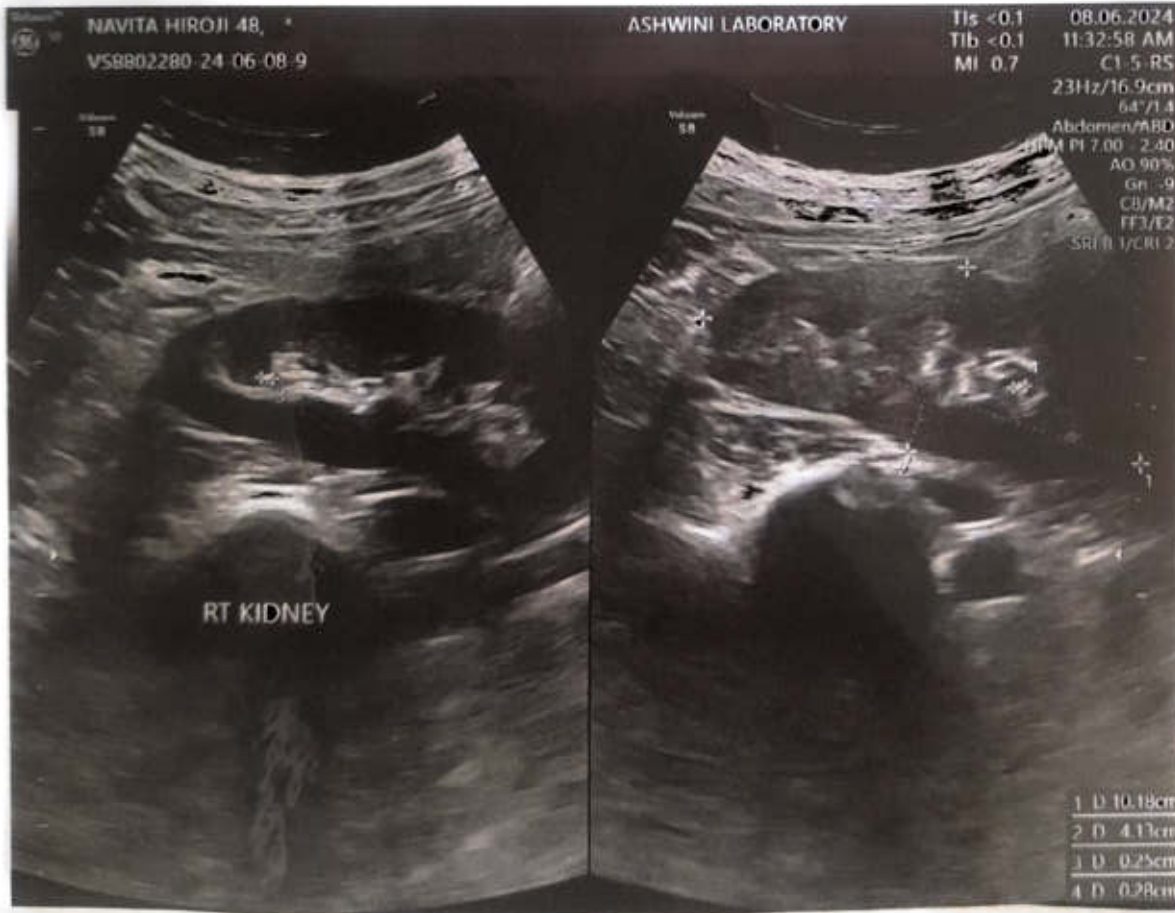
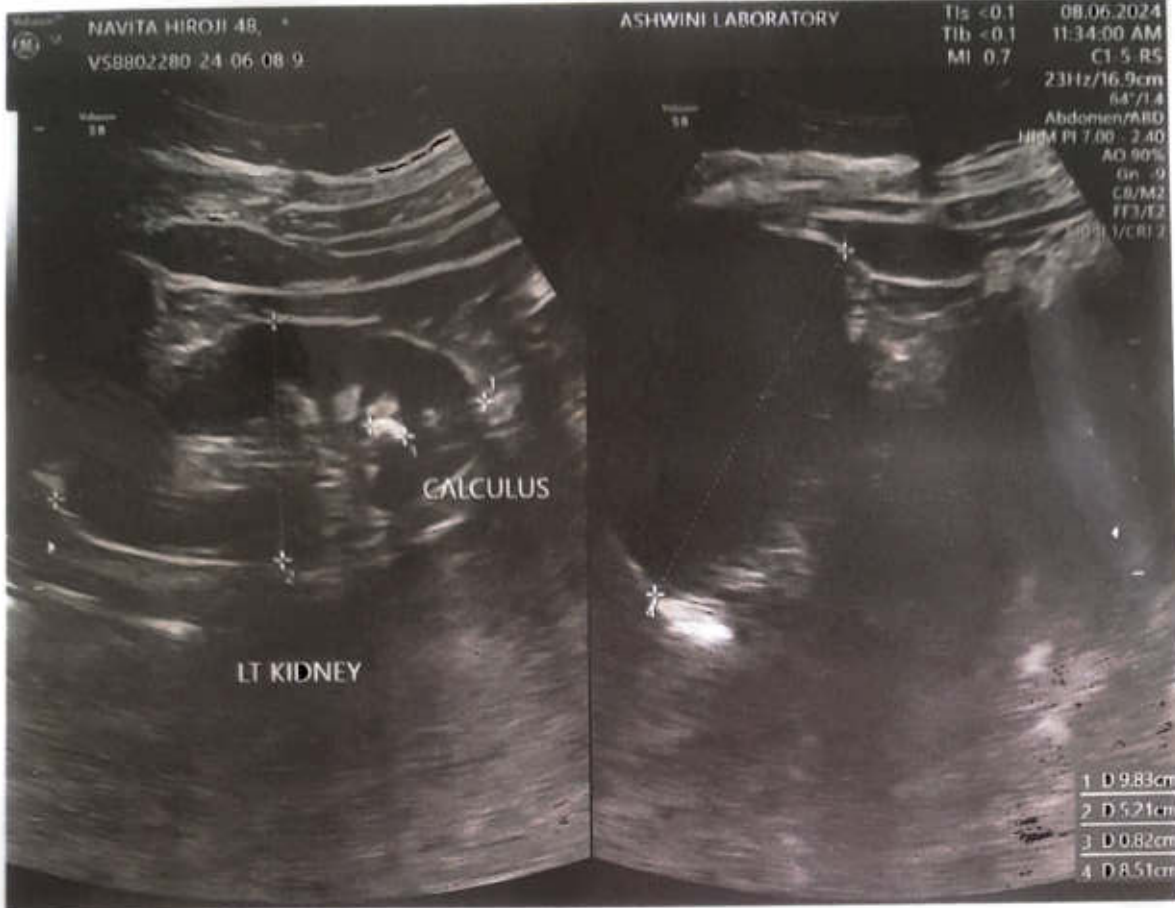
ECG is

Normal
Sign

DR. SIGN.





201,202,203, Rizvi Sadan, 2nd Floor, Near Municipal Market, Next to Vaidya Hospital, Panaji - Goa.
Tel.: 0832-2238122 | Email: drashanetravalkar@gmail.com

NAME: MRS.NAVITA HIROJI
AGE: 48/YRS
REF BY: DR.SELF

DATE: 08/06/2024
SEX: F

ULTRASONOGRAPHY OF ABDOMEN AND PELVIS

LIVER – It shows mild increase in echotexture and normal size. No focal lesions are seen. Intrahepatic biliary and portal radicals appear normal. Length of liver is 13.2cm.PV -8mm.

PANCREAS— It shows normal echotexture and size. No focal lesions are seen.

GALL BLADDER—It is moderately distended. No calculus is seen. Pericholecystic space is normal.CBD is normal.

SPLEEN----- It shows normal echotexture and size. Length of spleen is 8.5cm.

BOTH KIDNEYS show normal echotexture and size. Corticomedullary differentiation is seen well.No hydronephrosis is seen in both kidneys. Perirenal space is normal.

Right kidney--measures 10.1cm x 4.1cms .

Two calculi measuring 3mm each are seen in upper pole and lower pole resp.

Left kidney—measures 9.8cms x5.2cms.

A calculus measuring 8mm in lower pole.

Urinary Bladder is well distended.No calculus and mass is seen.Both VUJ's are normal.

UTERUS : It is not visualised.H/O hysterectomy.

Both ovaries show normal echotexture and size.

Right ovary—measures 2.6cms x 1.7cms.

Left ovary -measures 3.4cms x 1.3cms.

An irregular cyst measuring 9.3cmx5.2cm is seen in left adnexa adjacent to ovary.No septae/nodules/calcification is seen.

No free fluid is seen in pelvis.Plenty of bowel gases are seen.

Impression: Bilateral renal calculi.

Fatty liver grade 1.

Cyst in left adnexa.

With regards,


DR.ASHADEVINETRAVALKAR,MD
RADIOLOGIST

DR. ASHADEVINETRAVALKAR
MBBS., MD, AFIH
Consultant Radiologist
2nd Floor, Rizvi Sadan Panaji
Tel: 0832-2238122 / 8822125224

201,202,203, Rizvi Sadan, 2nd Floor, Near Municipal Market, Next to Vaidya Hospital, Panaji - Goa.
Tel.: 0832 2238122 | Email : drashanetravalkar@gmail.com

NAME: MRS.NAVITA HIROJI
AGE: 48/YRS
REF BY: DR.SELF

DATE: 08/06/2024
SEX: F

USG OF BOTH BREASTS

BOTH BREASTS:

Normal fibroglandular and fatty tissue is seen in both breasts.

Both areolar and retroareolar and axillary areas are normal.

No mass or cystic lesion is seen.

No calcification is seen.

No Lymphnodes are seen.

IMPRESSION—NORMAL STUDY.

With regards,



DR.ASHADEVI NETRAVALKAR,MD
RADIOLOGIST

DR. ASHADEVI NETRAVALKAR
MBBS, MD, AFIH
Consultant Radiologist
2nd Floor, Rizvi Sadan Panaji
Tel: 0832-2238122 / 0832225224

201,202,203, Rizvi Sadan, 2nd Floor, Near Municipal Market, Next to Vaidya Hospital, Panaji - Goa.
Tel.: 0832 2238122 | Email : drashanetravalkar@gmail.com

Cardiology Report

Page 1/2

ASHWINI LABORATORY

Date of Exam: 08.06.2024

Patient / Exam Information

Patient ID	VS8802280-24-06-08-6	Height
Name	NAVITA HIROJI 48	Weight
DOB, Age		BSA
Sex	F	HR

Perf. Phys.	Ref. Phys.	Sonographer
Comment	Indication	

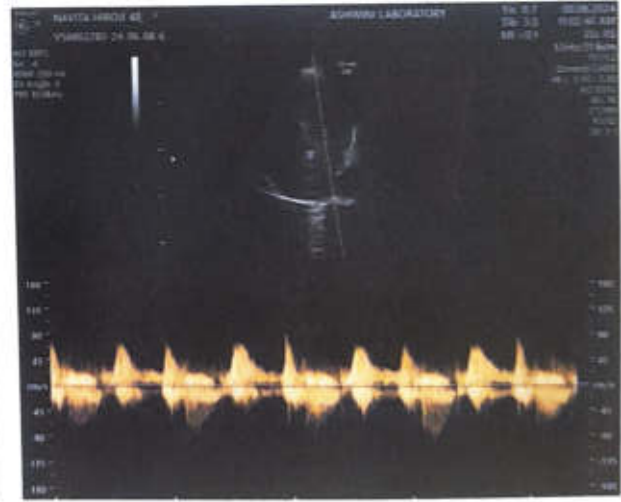
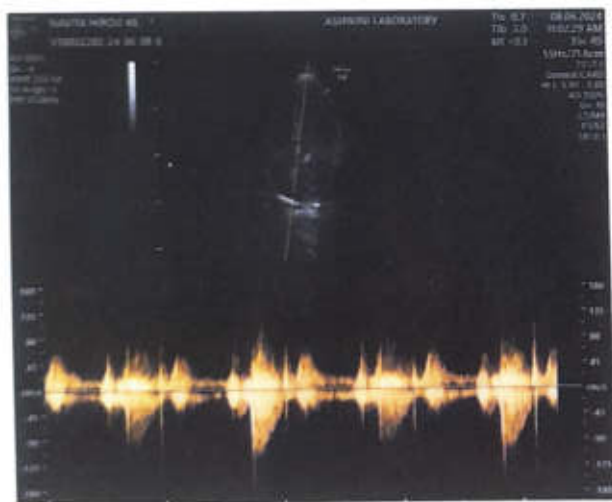
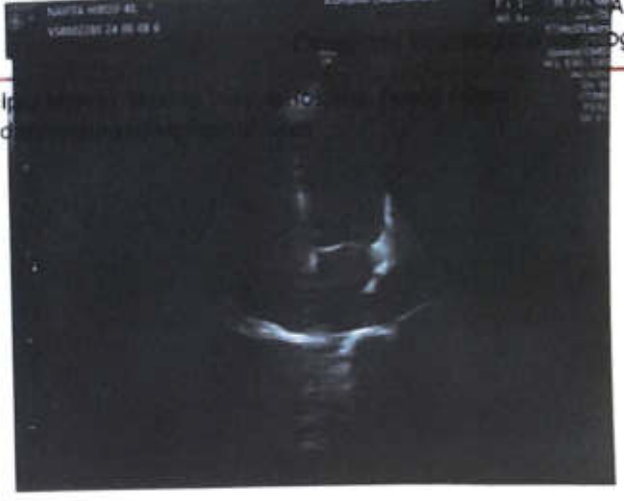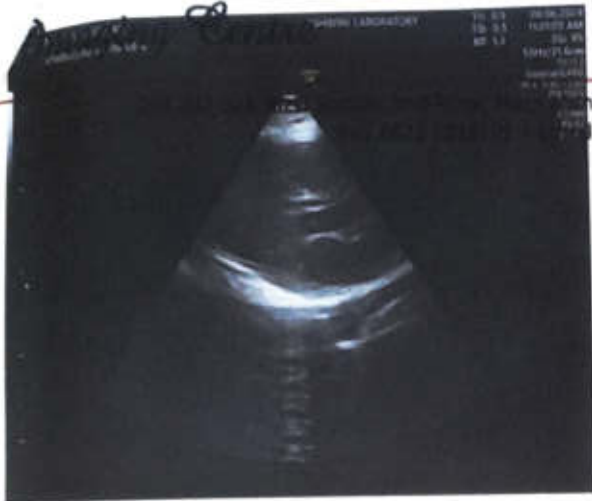M-Mode Measurements	Value	m1	m2	m3	m4	m5	m6	Meth.
AVILA								
Ao Root Diam.	3.15 cm	3.15						avg.
LA Diam.	2.76 cm	2.76						avg.
Left Ventricle								
IVSd	0.99 cm	0.99						avg.
LVDd	3.86 cm	3.86						avg.
LVPWd	0.94 cm	0.94						avg.
IVSs	1.43 cm	1.43						avg.
LVDs	2.26 cm	2.26						avg.
LVPWs	1.49 cm	1.49						avg.
EDV (Teich)	64.311 ml	64.311						
EDV (Cubed)	57.512 ml	57.512						
ESV (Teich)	17.340 ml	17.340						
ESV (Cubed)	11.543 ml	11.543						
SV (Teich)	46.971 ml	46.971						
SV (Cube)	45.969 ml	45.969						
EF (Teich)	73.04 %	73.04						
EF (Cube)	79.93 %	79.93						
Fract. Short.	41.45 %	41.45						
LV Mass	128.46 g	128.46						

Comment

NORMAL CARDIAC CHAMBERS DIMENSIONS. NORMAL BI VENTRICLE SYSTOLIC FUNCTION. NO REGIONAL WALL MOTION ABNORMALITIES. VALVES ARE NORMAL. AORTIC ROOT IS NORMAL. PERICARDIUM IS NORMAL.

Ashadevi

08.06.2024 11:05:01 AM



201,202,203, Rizvi Sadan, 2nd Floor, Near Municipal Market, Next to Valdy Hospital, Panaji - Goa.
Tel.: 0832 2238122 | Email : drashanetravalkar@gmail.com

NAME: MRS. NAVITA HIROJI
AGE: 48/YRS
REF BY: DR.SELF

DATE: 08/06/2024
SEX: F

X-RAY CHEST--- PA VIEW

Lung fields are clear.

Both costophrenic angles are clear.

Cardiac size is normal

Both domes of diaphragm are normal.

Rib cage is normal.

IMPRESSION : *Normal study.*

With regards,



DR.ASHADEVI NETRAVALKAR,MD
RADIOLOGIST

DR. Ashadevi Netravalkar, MD
MBBS., MD, AFH
Consultant Radiologist
2nd Floor, Rizvi Sadan Panaji
Tel: 0832 2238122 / 08322235224