

R

PIURNIMA 35Y/F PI210448 CHEST PA 08-01-2024 10:09 AM
RADIOLOGY OF THE CARE OF THE PATIENT



UHID	PT210448	LAB No.	XRY2311574
Name	Mrs. PURNIMA	Regn. No.	GEN2400919
Age / Sex	35 Yrs / F	Receiving Dt/Time	08-Apr-2024 10:04
		Reporting Dt/Time	08-Apr-2024 04:41 PM



XRAY

CHEST (PA)

Both lung fields are normal.

Cp angles are clear.

Hila are normal...

Heart size appears within normal limits.

Soft tissue shadows and bony thorax are normal.

IMP- NORMAL CHEST X-RAY

Advised....please correlate clinically.

***** END OF REPORT *****

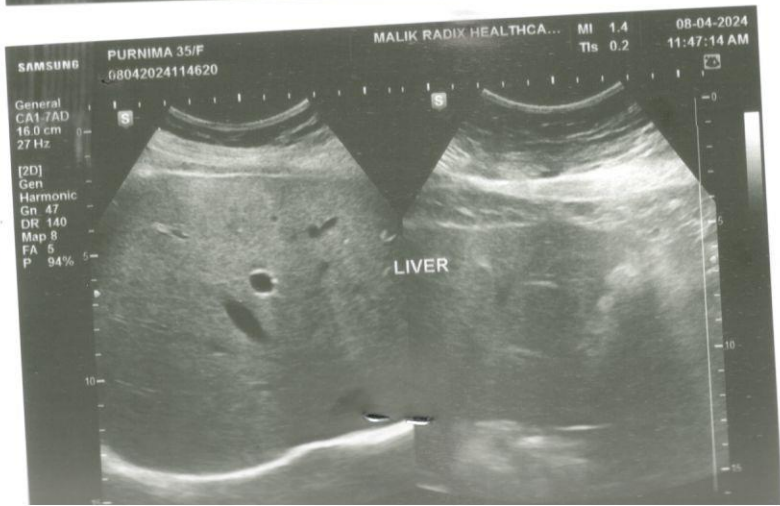
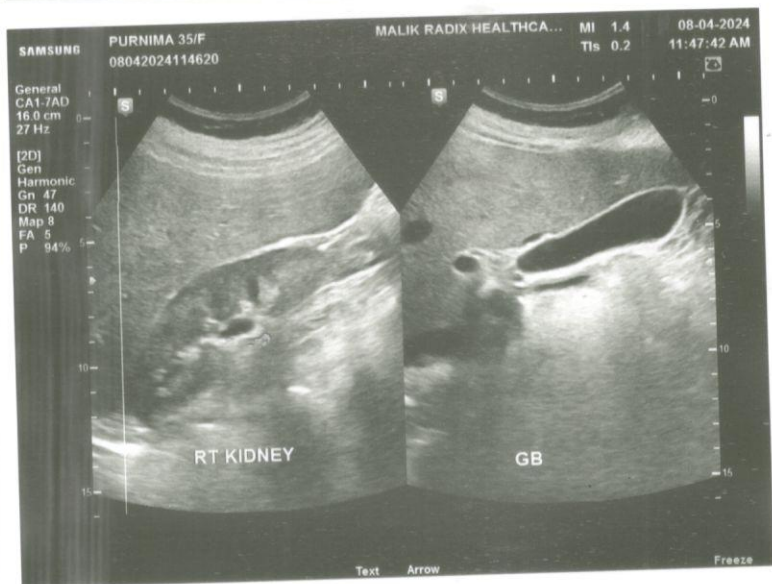
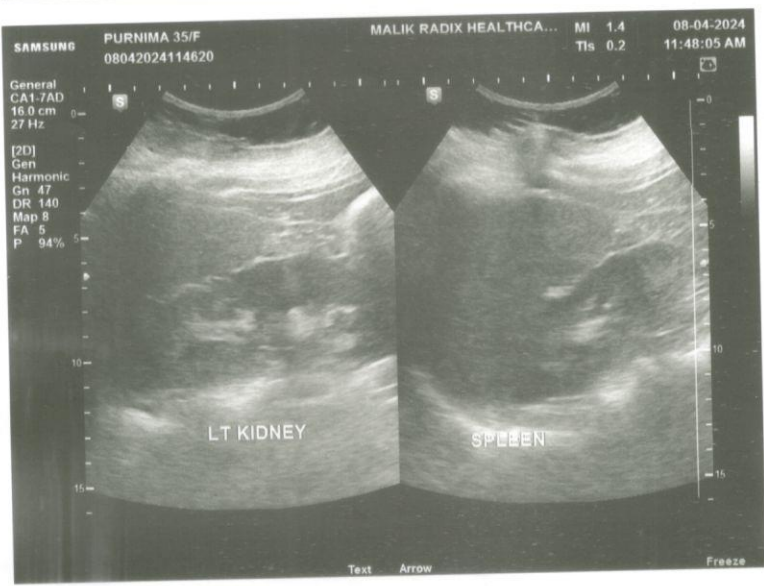
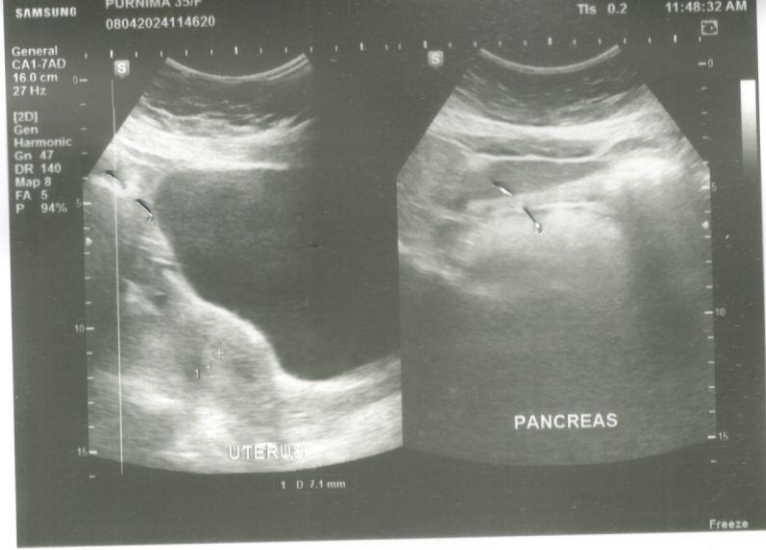
DR. K.K. SINHA
M.B.E.S. / D.M.R.D.
SENIOR CONSULTANT
Reg. No. 25437 (DMC)

DR. RAJESH MALHOTRA
MBBS, MD (RADIOLOGY)
CONSULTANT RADIOLOGY
Reg.No.DMC9299

DR. T. K VOHRA
MD (RADIOLOGY)
SENIOR CONSULTANT
Reg. No. 3272 (DMC)

DR. MUKESH KOSHAL
MBBS, MD (RADIOLOGY)
CONSULTANT RADIOLOGY
Reg.No.DMC10407

DR. SHREYASH TIWARY
MBBS, MD (RADIOLOGY)
CONSULTANT RADIOLOGY
Reg.No.DMC85802





NAME	MRS PURNIMA	AGE	35 Y/F
REFD. BY.	HEALTH CHECK UP	DATE	08.04.24

Ultrasound Examination of Whole Abdomen & Pelvis :

Liver: Liver shows normal parenchymal echotexture. No focal SOL is seen in liver. IHBR & portal radicles are normal.

Gallbladder: Gallbladder shows normal anechoic pattern . No evidence of cholecystitis or cholelithiasis is seen. Common bile duct is normal in course & caliber.

Pancreas: Pancreas shows normal size & echotexture.

Spleen: Spleen shows normal size, outline & echotexture.

Kidneys: Kidneys show normal size, shape, position & echotexture. No calculus, hydronephrosis or SOL is seen in kidneys. Cortico- medullary differentiation and cortical thickness is normal on both sides.

No supra- renal mass seen.

Great abdominal vessels are normal.

Domes of diaphragm are seen to move normally & synchronously in respiration. No supra- or infra diaphragmatic collection is seen.

No ascites or pericardial effusion seen.

No para aortic lymph nodes seen.

Urinary bladder: Urinary bladder shows normal anechoic pattern. No calculus, SOL or diverticulum seen.

Uterus: Uterus is anteverted and normal in size & echotexture. No intrinsic SOL is seen in uterus. Endometrial thickness is 7.1 mm.

Adnexa: Adnexal regions including the ovaries are sonographically normal.

Regards.

Dr Mukesh Koshal MD (Rad-diag)

Regn. No. DMC 10407

RADIOLOGIST :

Facilities Available

5

35

भारत सरकार
Government of India

पूर्णमा
Purnima
जन्म तिथि / DOB : 07/05/1988
महिला / FEMALE

Issue Date: 17/07/2011

2809 6576 8268

मेरा आधार, मेरी पहचान

Purnima

भारतीय विशिष्ट पहचान प्राधिकरण
Unique Identification Authority of India

पता: फ्लैट न ए-3 प्लॉट न 215, ज्ञान खंड,
इन्दिरापुरम गाज़ियाबाद, आई.इ.साहिबाबाद,
गाज़ियाबाद, उत्तर प्रदेश, 201010
Address: FLAT NO A-3 PLOT NO 215,
GYAN KHAND 1, INDIRAPURAM
GHAZIABAD, I.E. Sahibabad, Ghaziabad,
Uttar Pradesh, 201010

Print Date: 22/02/2021

2809 6576 8268

1947 help@uidai.gov.in www.uidai.gov.in

MALIK RADIX HEALTH CARE PVT. LTD.
C-217, C-218, Nirman Vihar,
Delhi-110092
Ph.: 011-49287456, 011-61381379
Regd. No. 607



CONSULTANTS ON PANEL

PAEDIATRICS

Dr Ravi Malik (MBBS, MD)
Dr Harit Prasad (MBBS, MD, Pdi)
Dr Ritu Jain (MBBS, MD)

GYNAECOLOGY

Dr Renu Malik (MBBS, MD)
Dr Meena Malhotra (MBBS, MD)
Dr Rajni (MBBS, MD)
Dr Manju Gupta (MBBS, MS)
Dr Vaishali Saini (MBBS, DGO)
Dr Rupam Arora (MBBS, MD)

DENTAL

Dr Shruti Malik (BDS, MDS)
Dr Annu Saini (BDS, MDS)
Dr Rachit Thukral (BDS, MDS)
Dr Mohit Mangla (BDS, MDS)
Dr Tarun Mittal (BDS, MDS)
Dr Geetika Sharma (BDS)
Dr Shilpa Verma (BDS)

CHILD GASTROENTEROLOGY

Dr S. K Mittal (MBBS, MD)

MEDICINE

Dr A S Tahwar (MBBS, MD)
Dr Sunny Uppal (MBBS, MD)
Dr Surendra Rajpal (MBBS, MD)

RESPIRATORY MEDICINE / PULMONOLOGY

Dr Abhinav Bhanot (MBBS, DNB)

LAPAROSCOPY SURGERY

Dr Ajay Jain (MBBS, MS)
Dr Deepak Saran (MBBS, MS)
Dr Pradeep Saini (MBBS, MS)
Dr G. S Garg (MBBS, MS)

ORTHOPAEDICS

Dr Vikas Bhardwaj (MBBS, MS ORTHO, DNB)
Dr Prabhath Aggarwal (MBBS, MS ORTHO)
Dr KB Tiwari (MBBS, MS ORTHO)
Dr Deepak Kumar Arora (MBBS, MS ORTHO)

EYE/OPTHALMOLOGY

Dr Nidhi Gupta (MBBS, MS, DNB, PGDM)
Dr Himanshu Singh Pundir (MBBS, MS)

ENT

Dr Sharad Kumar Singhi (MBBS, MS)
Dr Prateek Sharma (MBBS, MS)
Dr Ashok Singh (MBBS, MS)
Dr A K Lahiri (MBBS, MS)

RADIOLOGY (ULTRASOUND)

Dr K K Sinha (MBBS DNRB)
Dr T K Vohra (MBBS, MD)
Dr Rajesh Malhotra (MBBS, MD)
Dr Ashish Tomar (MBBS, MD)

PATHOLOGY

Dr Reema Dahiya (MBBS, MD PATH)
Dr Meenu Aggarwal (MBBS, MD PATH)

ANAESTHESIA

Dr Rajesh Dhall (MBBS, MD)
Dr Rakesh Atrey (MBBS, MD)
Dr R K Arora (MBBS, MD)
Dr Swaraj Garg (MBBS, MD)

DERMATOLOGY

Dr Nihanika Jha (MBBS, MD)

PLASTIC & COSMETIC SURGERY

Dr Ayush Jain (MBBS, MS, MCh)

PAEDIATRIC SURGERY

Dr Dharmendra Singh (MBBS, MS, M.Ch)
Dr Satish Aggarwal (MBBS, MS, M.Ch)

PAEDIATRIC NEPHROLOGY

Dr A S Vasudev (MD, Dip.in. Paed.)

NEPHROLOGY

Dr Javed (MBBS, MD, Nephro)

CARDIOLOGY

Dr Nishant Tyagi (MBBS, MD)

NEUROLOGY

Dr Amit Batra (MBBS, MD)

GASTROENTEROLOGY

Dr Deepak Lahoti (MBBS, MD)
Dr Naresh Aggarwal (MBBS, MD)
Dr Ashok Goyal (MBBS, MD)
Dr Ankur Singhal (MBBS, MD)

UROLOGY

Dr Nikhil Sharma (MBBS, Mch)
Dr Ankur Singhal (MBBS, MD)

PSYCHIATRY

Dr Mohit Sharma (MBBS, MD)

PHYSIOTHERAPY

Dr Kirti Dwivedi
Dr Ravi Kumar

NUTRITIONIST

Dr Deepika Kohli
Dr Sakshi Rana

CLINICAL PSYCHOLOGIST

Dr. Sarika Singh

Dr. Shruti Malik

BDS, MDS (Endodontics)
☎ +91-9899561092

Name : Poojira
Age/Sex : 35yrs / F.
Date : 08/04/23

**Timings : 10:00 am. to 2:00 pm.
6:00 pm. to 8:30 pm.**

For Appointment

☎ 011-45152510
☎ +91-9999254639

CLINICAL EXAMINATION:-

clo - Routine checkup.

1. TMJ:-

*I/o - Calculus - ++
Stains - +*

2. DENTAL STATUS:

- a. Caries Teeth :
- b. Fracture Teeth :
- c. Root Stumps :
- d. Gingivitis :
- e. Periodontitis :
- f. Impacted Teeth :
- g. Malaligned Teeth :

Caries 7 7

7	7
7	7

Adv - P. kit

3. ORAL LESIONS:-

Leu

4. DIAGNOSIS:-

5. TREATMENT PLANNING:

6. FOLLOW UP:-

Referral To Other Consultant: Yes/ No

If Yes, please mention the Name:

Doctor's Signature

Facilities Available :

- ★ MULTI-SPECIALITY HOSPITAL ★ MODULAR FULLY EQUIPPED OT ★ NURSERY ★ LAPROSCOPIC SURGERY
- ★ 24X7 EMERGENCY ★ OPG ★ DENTAL ★ 24X7 DIAGNOSTICS ★ LABOUR ROOM ★ ECHO ★ EEG ★ DIGITAL X-RAY ★ CT SCAN
- ★ ECG ★ ULTRASOUND ★ RICU/ICU ★ ALL SPECIALITY OPD ★ PLASTIC & COSMETIC SURGERY ★ DIALYSIS ★ PHARMACY

RADIX HEALTH care



Malik Radix Healthcare

C/217, C/218, Vikas Marg, Nirman Vihar, New Delhi-110092
A Unit of Malik Radix Healthcare
Toll Free - 1800-120-5457, Tel.: 011 49287456, 61381379
Whatsapp No. - 9811550650
E-mail: info@radixhealthcare.org
Website: www.radixhealthcare.org



Mrs. Purnima
Age - 35yrs / Female

Pre-Insurance Department
(Health Checkup)

08/04/24

Annual Health Checkup

Vision 6/6 ~~6/6~~ ⊕
6/6 ~~6/6~~ ⊕

Eye 16
16

Mean 4 ^{N6}
120

CUS ⁺
(100/day)

Color V. WNL

Adv

PEARL TEARS RA/
MYOIS

Cap Berfonelge XL ⊕
15

Dr. Nidhi Gupta

MBBS, MS, DNB
Casualty Ophthalmologist
Malik Radix Healthcare Pvt. Ltd.
DMC No. 121661

Facilities Available

- Multispeciality Hospital - 24 Hours Emergency - X-Ray/ ECG/ Ultrasound/ CT Scan - Dental- Fully Equipped Operation Theatre
- Fully Functional Lab - 24/7 Casualty/ ICU-Nursery 24/7 Pharmacy - Labour Room - All Speciality OPD - Laproscopic Surgery - ECHO - Plastic Surgery



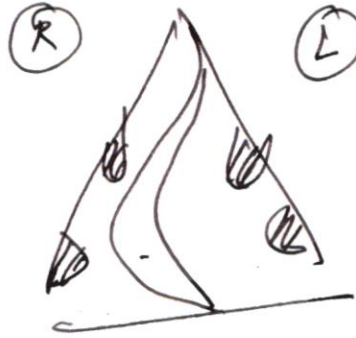
Name - Purnima
Age - 35/F

Annual Health checkup

08/07/24

B/L ear wax

Not - DNS
Che sinuaitis



Plain CT scan PNS
(coronal + Axial + sagittal views)

Adv

① Daily aerobic exercises

② wax off ear

7 days

Dr. SHARAD KUMAR SINGHI
MBBS, MS (ENT), ENT Surgeon
MALIK RADIX HEALTHCARE
C-217, 218, Nirman Vihar, New Delhi-110092
Reg. No. 192
8/7/24

Facilities Available

- Multispeciality Hospital - 24 Hours Emergency - X-Ray/ ECG/ Ultrasound/ CT Scan - Dental- Fully Equipped Operation Theatre
- Fully Functional Lab - 24/7 Casualty/ ICU-Nursery 24/7 Pharmacy - Labour Room - All Speciality OPD - Laproscopic Surgery - ECHO - Plastic Surgery

Running

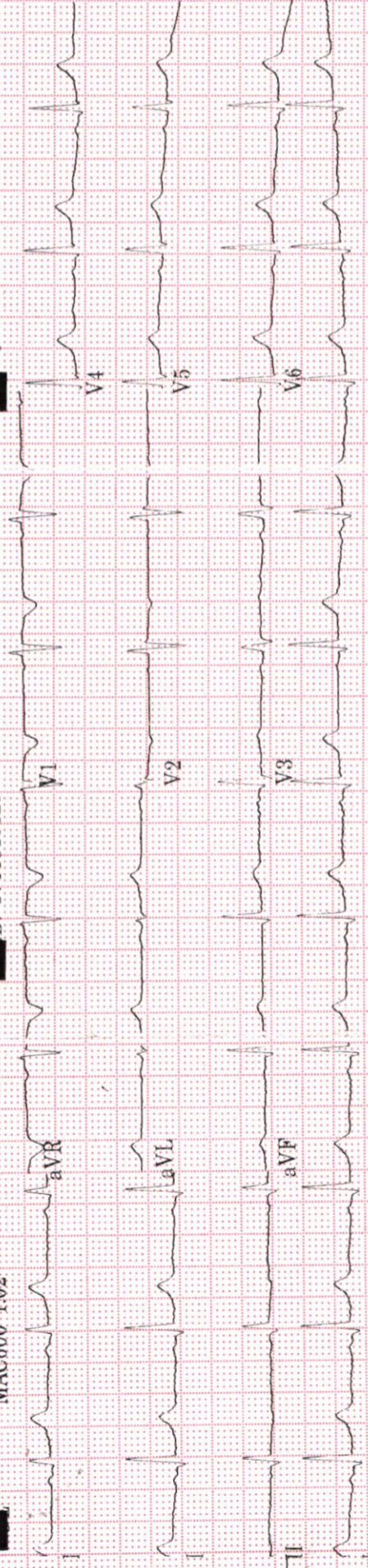
Apr-2024 10:14:36

ID: 9711810128

MAC600 1.02

ID: 9711810128

35years Female



Vent. rate 69 bpm
 QRS duration 86 ms
 QT/QTc 410/439 ms
 PR interval 130 ms
 P duration 78 ms
 RR interval 869 ms
 P-R-T axes 16 64 26

Dr. Mohamed

12SL™ v239

MAC600 1.02

4 by 2.5s + 1 rhythm 1d

69 bpm

50Hz

25.0 mm/s 10.0 mm/mV

016-20Hz

Malik Radix HealthCare.

ELECTROCARDIOGRAM

Name: MRS. PURNIMA Age & Sex: 35YR/ FEMALE Ref By: MEDIWHEEL Date: 08/04/2024

ECG FINDINGS:

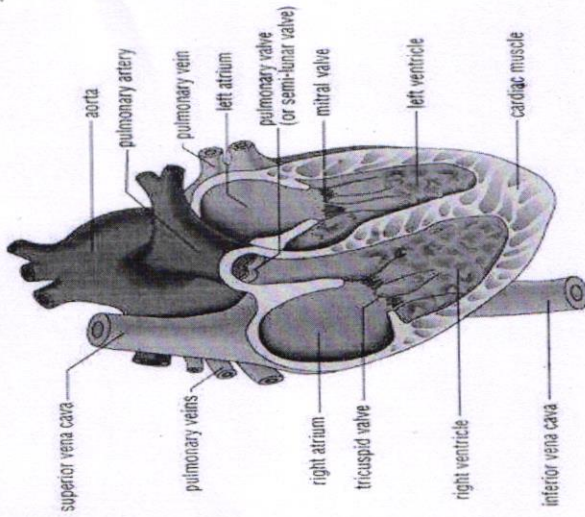
Rate 70 bpm Rhythm Sinus Mechanism Normal

Axis Normal P Wave Normal PR Interval 0.13/Sec

QRS Complex Normal QT Interval Normal Q Wave Normal

ST Segment Normal T Wave Normal

Conclusion Sinus Rhythm, Normal Axis, To be correlate.



Doctors Signature Dr. SHEKH NAZIR AHMED
M.D. "Physician"
PGDCC
DMC-46499



LAB REPORT

Reg. Date	08/04/2024	Patient Id	2404080003	DOB.	07/05/1988
Name	MRS. PURNIMA	Gender	F	Perm. ID	
Age	35 Yrs. 11 Mn. 2 Day	Panel	MEDIWHEEL	Reported	08/04/2024 17:58:26
Ref. By	MEDIWHEEL				

Test Name	Result	Units	Ref. Range
-----------	--------	-------	------------

MEDIWHEEL AHC STARTER FEMALE

HAEMATOLOGY

COMPLETE HAEMOGRAM

HAEMOGLOBIN (HB%)	11.6	gm/dl	12 - 15
TOTAL LEUCOCYTE COUNT (TLC)	6,200	/cumm	4000 - 11000

DIFFERENTIAL LEUCOCYTE COUNT (DLC)

NEUTROPHIL	65	%	40 - 80
LYMPHOCYTE	31	%	28 - 55
MONOCYTE	03	%	02 - 10
EOSINOPHIL	01	%	01 - 06
BASOPHIL	00	%	0 - 0
ESR (WESTEGREN'S METHOD)	20	mm/1st hr.	0 - 15
R B C COUNT	4.00	Millions/cmm	4.247 - 5.4
P.C.V / HAEMATOCRIT	36.8	%	35 - 45
M C V	92.0	fl.	80 - 100
M C H	29.0	Picogram	27.0 - 31.0
M C H C	31.5	gm/dl	33 - 37
PLATELET COUNT	2.32	Lakh/cu mm	1.50 - 4.50
BLOOD GROUP ABO	" O "		
RH TYPING	Positive		
BLOOD SUGAR FASTING	96.73	mg/dl	70 - 100

THYROID PROFILE

Free T3 ELFA	3.23	ng/ml	02 - 04
Free T4 ELFA	1.17	ug/dl	0.8 - 2.7
TSH Serum/ELFA	2.180	uIU/ml	

Checked by : _____
Page 1 Contd...2

If test results are alarming or unexpected, patient is advised to contact the laboratory immediately for possible remedial action.

Facilities Available

- Multispeciality Hospital - 24 Hours Emergency - X-Ray/ ECG/ Ultrasound/ CT Scan - Dental- Fully Equipped Operation Theatre
- Fully Functional Lab - 24/7 Casualty/ ICU-Nursery 24/7 Pharmacy - Labour Room - All Speciality OPD - Laproscopic Surgery - ECHO - Plastic Surgery



LAB REPORT

Reg. Date	08/04/2024	Patient Id	2404080003	DOB.	07/05/1988
Name	MRS. PURNIMA	Gender	F	Perm. ID	
Age	35 Yrs. 11 Mn. 2 Day	Panel	MEDIWHEEL	Reported	08/04/2024 17:58:26
Ref. By	MEDIWHEEL				

Test Name	Result	Units	Ref. Range
			0.25 - 5.50 uIU/ml

Interpretation

Clinical Use

- Diagnose Hypothyroidism and Hyperthyroidism
- Monitor T4 replacement or T4 suppressive Therapy
- Quantify TSH levels in the subnormal range

Increased Levels : Primary Hypothyroidism Subclinical Hypothyroidism, TSH dependent, Thyroid Hormone Resistance.

Decreased Levels : Grave's Disease, Autonomous Thyroid Hormone Secretion, TSH Deficiency

LIPID PROFILE

TOTAL CHOLESTEROL	163.00	mg/dL	130.0 - 200.0 (<200)
TRIGLYCERIDES	86.20	mg/dL	80.5 - 150.0 (<150)
H D L CHOLESTEROL DIRECT	47.12	mg/dL	42.0 - 60.0 (<40->59)
V L D L	17.2	mg/dL	4.0 - 30. (23-45)
L D L CHOLESTEROL	98.7	mg/dL	50.0 - 150.0 (50-150)
TOTAL CHOLESTEROL / HDL RATIO	3.5		3.3 - 5.1
LDL / HDL CHOLESTEROL RATIO	2.1		1.5 - 3.5

LIVER FUNCTION TEST (LFT)

BILIRUBIN TOTAL	1.04	mg/dl	0.2 - 1.2
CONJUGATED (D. BILIRUBIN)	0.40	mg/dl	0.00 - 0.3
UNCONJUGATED (I.D.BILIRUBIN)	0.64	mg/dl	0.2 - 0.9

Checked by : _____
Page 2 Contd...3

If test results are alarming or unexpected, patient is advised to contact the laboratory immediately for possible remedial action.

Facilities Available

- Multispeciality Hospital - 24 Hours Emergency - X-Ray/ ECG/ Ultrasound/ CT Scan - Dental- Fully Equipped Operation Theatre
- Fully Functional Lab - 24/7 Casualty/ ICU-Nursery 24/7 Pharmacy - Labour Room - All Speciality OPD - Laproscopic Surgery - ECHO - Plastic Surgery



LAB REPORT

Reg. Date	08/04/2024	Patient Id	2404080003	DOB.	07/05/1988
Name	MRS. PURNIMA	Gender	F	Perm. ID	
Age	35 Yrs. 11 Mn. 2 Day	Panel	MEDIWHEEL	Reported	08/04/2024 17:58:26
Ref. By	MEDIWHEEL				

Test Name	Result	Units	Ref. Range
SGOT / AST	14.40	IU/L	0 - 35
SGPT / ALT	15.2	IU/L	0 - 35
ALKALINE PHOSPHATASE	67.20	U/L	64 - 306
TOTAL PROTEIN	7.74	gm/dl	6.0 - 8.3
ALBUMIN	4.14	gm/dl	3.2 - 5.0
GLOBULIN	3.60	gm/dl	2.5 - 5.6
A/G RATIO	1.15		0.9 - 2.0
GAMMA GT	20.14	IU/L	0.0 - 35.0
SERUM CREATININE	0.70	mg/dl	0.6 - 1.2
SERUM URIC ACID	5.16	mg/dl	2.4 - 6.0
BLOOD UREA NITROGEN (BUN)	16.31	mg/dl	6.0 - 21.0
BUN/CREAT RATIO	23.3	mg/dl	10 - 20

Urine Routine Examination

PHYSICAL EXAMINATION

QUANTITY	30	ml.	
COLOUR	Pale Yellow		Pale Yellow
TRANSPARENCY	Turbid		
SPECIFIC GRAVITY	1.015		
PH	6.0		

CHEMICAL EXAMINATION

ALBUMIN	Nil
SUGAR	Nil

MICROSCOPIC EXAMINATION

PUS CELLS	1-2	/HPF
RBC'S	Nil	/HPF
CASTS	Nil	

Checked by : _____
Page 3 Contd...4

If test results are alarming or unexpected, patient is advised to contact the laboratory immediately for possible remedial action.

Facilities Available

- Multispeciality Hospital - 24 Hours Emergency - X-Ray/ ECG/ Ultrasound/ CT Scan - Dental- Fully Equipped Operation Theatre
- Fully Functional Lab - 24/7 Casualty/ ICU-Nursery 24/7 Pharmacy - Labour Room - All Speciality OPD - Laproscopic Surgery - ECHO - Plastic Surgery



LAB REPORT

Reg. Date 08/04/2024

Name MRS. PURNIMA

Age 35 Yrs. 11 Mn. 2 Day

Ref. By MEDIWHEEL

Patient Id 2404080003

Gender F

Panel MEDIWHEEL

DOB. 07/05/1988

Perm. ID

Reported 08/04/2024 17:58:26

Test Name	Result	Units	Ref. Range
CRYSTALS	NIL		
EPITHELIAL CELLS	1-2	/HPF	
BACTERIA	Nil		
OTHERS	Nil		

Dr. REENA DABHYA

M.B.B.S, MD (Path.)

Checked by: _____

Malik Radix Healthcare Pvt. Ltd.

G-217, C-218, Nirman Vihar,

Delhi-110092

DR. MEENU AGGARWAL

M.B.B.S, MD (Path.)

If test results are alarming or unexpected, patient is advised to contact the laboratory immediately for possible remedial action.

Facilities Available

- Multispeciality Hospital - 24 Hours Emergency - X-Ray/ ECG/ Ultrasound/ CT Scan - Dental- Fully Equipped Operation Theatre
- Fully Functional Lab - 24/7 Casualty/ ICU-Nursery 24/7 Pharmacy - Labour Room - All Speciality OPD - Laproscopic Surgery - ECHO - Plastic Surgery

Patient Name : Mrs PURNIMA
DOB/Age/Gender : 35 Y/Female
Patient ID / UHID : 7876884/OF7876884
Referred By : Dr. DR. SELF
Sample Type : Whole blood EDTA

Sample Collected : Apr 08, 2024, 01:17 PM
Report Date : Apr 08, 2024, 06:42 PM
Barcode No : HY431640
Report Status : Final Report



Test Description	Value(s)	Unit(s)	Reference Range
------------------	----------	---------	-----------------

HbA1C (Glycosylated Haemoglobin)

Glycosylated Hemoglobin (HbA1c) HPLC	4.7	%	<5.7
Estimated Average Glucose	88.19		

Interpretation:

Interpretation For HbA1c% As per American Diabetes Association (ADA)

Reference Group	HbA1c in %
Non diabetic adults >=18 years	<5.7
At risk (Prediabetes)	5.7 - 6.4
Diagnosing Diabetes	>= 6.5
Therapeutic goals for glycemic control	Age > 19 years Goal of therapy: < 7.0 Age < 19 years Goal of therapy: <7.5

Note:

1. Since HbA1c reflects long term fluctuations in the blood glucose concentration, a diabetic patient who is recently under good control may still have a high concentration of HbA1c. Converse is true for a diabetic previously under good control but now poorly controlled.
2. Target goals of < 7.0 % may be beneficial in patients with short duration of diabetes, long life expectancy and no significant cardiovascular disease. In patients with significant complications of diabetes, limited life expectancy or extensive co-morbid conditions, targeting a goal of < 7.0 % may not be appropriate

Comments :

HbA1c provides an index of average blood glucose levels over the past 8 - 12 weeks and is a much better indicator of long term glycemic control as compared to blood and urinary glucose determinations ADA criteria for correlation between HbA1c & Mean plasma glucose levels.

HbA1c(%)	Mean Plasma Glucose (mg/dL)	HbA1c(%)	Mean Plasma Glucose (mg/dL)
6	126	12	298
8	183	14	355
10	240	16	413

*** End Of Report ***

Sohini Sengupta

Dr. Sohini Sengupta
MD (Cl Biochemistry), DNB,
FNB (Lab Medicine)
Medical Laboratory Director
HOD (Biochemistry & Special Assays)

Booking Centre :- Malik Radix Healthcare (Delhi), C-218, Nirman Vihar, Vikas Marg

Processing Lab :- Redcliffe Lifetech Pvt. Ltd. H-55, Sector-63, Noida, Uttar Pradesh - 201301


928-909-0609

csupp@redcliffelabs.com

www.redcliffelabs.com

All Lab results are subject to clinical interpretation by qualified medical professional and this report is not subject to use for any medico-legal purpose.





LAB REPORT

UHID	PT210448	LAB No.	LAB2332664
Name	Mrs. PURNIMA	Regn. No.	GEN2400921
Father's/Husb Name	W/O	Receiving Dt/Time	08/Apr/2024 11:32 AM
Age/Sex	35 Yrs/F	Reporting Dt/Time	09/Apr/2024 02:08 PM



CYTOLOGY

PAP SMEAR

CYTOPATHOLOGY REPORT

2001 BETHESDA SYSTEM

SPECIMEN: CERVICOVAGINAL SMEAR.

SPECIMEN ADEQUENCY:

Smear is satisfactory for evaluation. Smear shows both squamous cells and endocervical cells. Background shows shift in flora with moderate severe neutrophilic infiltrate.

INTERPRETATION:

Negative for intra-epithelial lesion and malignancy .

IMPRESSION:

Shift in flora suggestive of bacterial vaginosis.

DISCLAIMER:

It is a screening procedure subject to both false negative or false Positive.
 Result must be interpreted in context of historic and current Clinical information
 in case of any mismatch biopsy and HPE may be considered.

Dr.Reema Dahiya
 M.B.B.S, MD(PATH)
 CONSULTANT PATHOLOGY
 DMC/R/04578

The Test are not conducted under NABL scope

If test results are alarming or unexpected, patient is advised to contact the laboratory immediately for possible remedial action.

Facilities Available

- Multispeciality Hospital - 24 Hours Emergency - X-Ray/ ECG/ Ultrasound/ CT Scan - Dental- Fully Equipped Operation Theatre
- Fully Functional Lab - 24/7 Casualty/ ICU-Nursery 24/7 Pharmacy - Labour Room - All Speciality OPD - Laproscopic Surgery - ECHO - Plastic Surgery