



Medicover Hospitals

VENKOJIPALAM VISAKHAPATNAM - 530017
ANDHRA PRADESH - INDIA
PHONE NO : 0891-6829999



MEDICOVER HOSPITALS

A UNIT OF SAHRUDAYA HEALTHCARE PVT LTD.

Dr. RAKESH P
MD
GENERAL PHYSICIAN

NAME : Thabita . M AGE 35 / M

WT: 77 kg's
HT: 159 cm's
BP: 140/90 mmHg
PR 85/min

Medicover Unit - I
18-1-3, KGH Down, Maharani-peta,
Jagadamba Junction, Visakhapatnam
Andhrapradesh - 530 002.
Ph: +91 96526 69351

Medicover Unit -III
Sry. No.27, Plot No.05, BRTS Road,
Health City, Arilova, Chinnagadhili Mandal,
Visakhapatnam, Andhrapradesh - 530 040.
Ph: +91 0891 6677888

Medicover - MVP
1-1-83, Sector-6, Venkojipalem,
MVP Colony, Visakhapatnam,
Andhrapradesh-530017.
Ph: +91 8886655677



Medicover Hospitals

VENKOJIPALAM VISKHAPATNAM -530017
ANDHRA PRADESH -INDIA
PHONO NO : 0891-6829999



MEDICOVER HOSPITALS

A UNIT OF SAHRUDAYA HEALTHCARE PVT LTD.

OPHTHALMOLOGIST CONSULTATION

NAME: Thabita . M AGE: 35/F

DATE: 13/04/29

Un of 6/11
6/6

NO cataract

NO DM

As was

low of 0.2u /u
0.2u /u

of = 2u

e

Medicover Unit - I

18-1-3, KGH Down, Maharanipecta,
Jagadamba Junction, Visakapatnam,
Andhrapradesh - 530 002.
Ph: +91 96526 69351

Medicover Unit - III

Sry.No. 27, Plot No. 05, BRTS Road,
Health City, Arilova, Chinnagadalu Mandal,
Visakhapatnam, Andhrapradesh - 530 040.
Ph: +91 08916677888

Medicover - MVP

1-1-83, Sector -6, Venkojipalem,
MVP Colony, Visakapatnam,
Andhrapradesh-530017.
Ph: +91 8886655677



**MEDICOVER
HOSPITALS**

A UNIT OF SAHRUDAYA HEALTHCARE PVT LTD.

MEDICOVER HOSPITALS


VENKOJIPALEM VISAKHAPATNAM -530017
ANDHRA PRADESH -INDIA
PHOpppNE NO ; 0891-6829999

Dr. DENTAL CONSULTATION CONSULTANT DENTAL

NAME : Thabita H

AGE : 35/F

pt clo ulcer on the tongue since
1 week



Steis +
Colony +

Adv ~~...~~
extraction -

Muciper gel -

4-5 times
(week)

tra



Medicover Hospitals
VENKOJIPALAM VISKHAPATNAM -530017
ANDHRA PRADESH -INDIA
PHONO NO : 0891-6829999



MEDICOVER
HOSPITALS

A UNIT OF SAHRUDAYA HEALTHCARE PVT LTD.

DIETICIAN CONSULTATION
CONSULTANT DIETICIAN

NAME : Thabita

AGE : 35/12

DATE : 13/04/24

wt - 77 kg's

Ht - 154 cm's

Bp - 140/90 mm

PR - 85/min



Medicover Hospitals

VENKOJIPALAM VISAKHAPATNAM - 530017
ANDHRA PRADESH - INDIA



MEDICOVER HOSPITALS

A UNIT OF SAHRUDAYA HEALTHCARE PVT LTD.

Lab Report

Patient Name	: Mrs. THABITA MYLABATHULA	Age /Gender	: 35 Y(s)/Female
Bill No/ UMR No	: V4BC224199/V4U180793	Referred By	: Dr. CMO
Received Dt	: 13-Apr-24 08:37 am	Report Date	: 13-Apr-24 10:34 am
Lab No	: 240401938		

<u>Parameters</u>	<u>Result</u>	<u>Biological Reference Intervals</u>
-------------------	---------------	---------------------------------------

CUE (COMPLETE URINE EXAMINATION)

CHEMISTRY TEST

UROBILINOGEN	NIL	Negative
BILIRUBIN	Neagative	Negative
KETONE BODIES	Neagative	Negative
BLOOD	Neagative	Negative
PROTEIN	2+	NIL
NITRITE	Neagative	Negative
LEUCOCYTES	Neagative	
GLUCOSE	2+	NIL
SPECIFIC GRAVITY	1.010	1.005 - 1.030
PH	6.0	5.0 - 8.0

MICROSCOPY MORPHOLOGY

RBC	NIL	0 - 3 /HPF
WBC (WHITE BLOOD CELL)	* 4-6	0 - 5 /HPF
SQEP (SQUAMOUS EPITHELIAL CELL)	* 1-2	0 - 5 /HPF
UNCC (PATHOLOGICAL CAST)	NIL	0 - 0 /HPF
UNCX (UNCLASSIFIED CRYSTALS)	NIL	0 - 5 /HPF

*** End Of Report ***

Doctor Incharge

Dr.MUDUGANTI SRINIVAS
MBBS, MD
CONSULTANT PATHOLOGIST

Dr.SRUJANA
MBBS, MD PATHOLOGY
CONSULTANT PATHOLOGIST

Dr.MOHAMMAD SIMI IQBAL
M.B.B.S, M.D
CONSULTANT BIOCHEMIST

Medicover Unit - I

18-1-3, KGH Down, Maharanipecta,
Jagadamba Junction, Visakapatnam,
Andhrapradesh - 530 002.
Ph: +91 96526 69351

Medicover Unit - III

Sry. No. 27, Plot No. 05 BRTS Road,
Health City, Arilova, Chinnagadalu Mandal,
Visakhapatnam, Andhrapradesh - 530 040.
Ph: +91 08916677888

Medicover - MVP

1-1-83, Sector -6, Venkojipalem,
MVP Colony, Visakapatnam,
Andhrapradesh-530017.
Ph: +91 8886655677



Medicover Hospitals

VENKOJIPALAM VISAKHAPATNAM - 530017
ANDHRA PRADESH - INDIA



MEDICOVER HOSPITALS

A UNIT OF SAHRUDAYA HEALTHCARE PVT LTD.

Lab Report

Patient Name : **Mrs. THABITA MYLABATHULA** Age /Gender : **35 Y(s)/Female**
Bill No/ UMR No : **V4BC224199/V4U180793** Referred By : **Dr. CMO**
Received Dt : **13-Apr-24 08:37 am** Report Date : **13-Apr-24 09:57 am**
Lab No : **120000603341**

<u>Parameter</u>	<u>Result Values</u>	<u>Biological Reference</u>
CBC(COMPLETE BLOOD COUNT)		
RBC		
HAEMOGLOBIN	14.3	12.0 - 15.0 g/dl
R B C COUNT	4.8	3.8 - 4.8 $10^6/\mu\text{L}$
PCV/HCT	42	36 - 46 %
MCV	88	83 - 101 fl
MCH	30	27 - 32 pg
MCHC	34	31.5 - 34.5 g/dL
RDW(cv)	* 15.6	11.6 - 14.0 %
WBC		
TC (TOTAL LEUCOCYTE COUNT)	7700	4000 - 11000 cells/cumm
DIFFERENTIAL COUNT		
NEUTROPHILS	65	40 - 80 %
LYMPHOCYTES	26	20 - 40 %
MONOCYTES	05	02 - 10 %
EOSINOPHILS	04	00 - 06 %
BASOPHILS	00	00 - 01 %
PLATELET COUNT		
PLATELET COUNT	3.93	1.50 - 4.50 Lakhs/cumm
ESR	20	0 - 20 mm/1st hour

*** End Of Report ***

Doctor Incharge

Dr.MUDUGANTI SRINIVAS
MBBS, MD
CONSULTANT PATHOLOGIST

Dr.SRUJANA
MBBS, MD PATHOLOGY
CONSULTANT PATHOLOGIST

Dr.MOHAMMAD SIMI IQBAL
M.B.B.S, M.D
CONSULTANT BIOCHEMIST

Medicover Unit - I

18-1-3, KGH Down, Maharani-peta,
Jagadamba Junction, Visakapatnam,
Andhrapradesh - 530 002.
Ph: +91 96526 69351

Medicover Unit - III

Sry.No. 27, Plot No. 05, BRTS Road,
Health City, Arilova, Chinnagadalu Mandal,
Visakhapatnam, Andhrapradesh - 530 040.
Ph: +91 08916677888

Medicover - MVP

1-1-83, Sector -6, Venkojipalem,
MVP Colony, Visakapatnam,
Andhrapradesh-530017.
Ph: +91 8886655677



Medicover Hospitals

VENKOJIPALAM VISAKHAPATNAM - 530017
ANDHRA PRADESH - INDIA



MEDICOVER HOSPITALS

A UNIT OF SAHRUDAYA HEALTHCARE PVT LTD.

Lab Report

Patient Name	: Mrs. THABITA MYLABATHULA	Age /Gender	: 35 Y(s)/Female
Bill No/ UMR No	: V4BC224199/V4U180793	Referred By	: Dr. CMO
Received Dt	: 13-Apr-24 08:37 am	Report Date	: 13-Apr-24 10:23 am
Lab No	: 120000603342		

<u>Parameters</u>	<u>Result</u>	<u>Biological Reference Intervals</u>
LIPID PROFILE		
TOTAL CHOLESTEROL	355	No risk : < 200 mg/dL Moderate risk : 200 - 239 High risk : > 240
HDL CHOLESTEROL	27	<40 Low >60 High
LDL CHOLESTEROL	* Not Calculated	Border line : 100 - 130 mg/dL High : > 130 mg/dL Desirable : < 100 mg/dL 100 - 130 mg/dL
VLDL	Not Calculated	
SERUM TRYGLYCERIDES	1247	Very High : > 500 mg/dL High : >= 200 - 499 mg/dL Border line High : >= 150 - 199 mg/dL
CHO/HDL RATIO	* 13.15	Normal : < 150 mg/dL Normal : < 4.0 Low risk : 4.0 - 6.0 High risk : > 6.0
COMMENT	TGL >400 mg/dL LDL &VLDL CANN(
FBS (FASTING BLOOD GLUCOSE)		
FASTING BLOOD GLUCOSE	387	Normal : 70-99 mg/dL Impaired : 100-125 mg/dL Diabetic : >= 126 mg/dL
CREATININE	0.7	0.6 - 1.1 mg/dL
LFT(LIVER FUNCTION TEST)		
TOTAL BILIRUBIN	0.3	< 1.2 mg/dL
DIRECT BILIRUBIN	0.1	<= 0.20 mg/dL
INDIRECT BILIRUBIN	0.2	<= 1.0 mg/dL
SGPT (ALT)	* 38	<= 33 U/L
SGOT (AST)	22	<= 32 U/L
ALKALINE PHOSPHATASE (ALP)	* 107	35 - 105 U/L
TOTAL PROTEINS	8.1	1-2 years : 5.6-7.5 g/dL > 3 years : 6.0-8.0 g/dL Adults : 6.4-8.3 g/dL

Medicover Unit - I

18-1-3, KGH Down, Maharanipecta, Jagadamba Junction, Visakapatnam, Andhrapradesh - 530 002.
Ph: +91 96526 69351

Medicover Unit - III

Sry. No. 27, Plot No. 05, BRTS Road, Health City, Arilova, Chinnagadalu Mandal, Visakhapatnam, Andhrapradesh - 530 040.
Ph: +91 08916677888

Medicover - MVP

1-1-83, Sector -6, Venkojipalem, MVP Colony, Visakapatnam, Andhrapradesh-530017.
Ph: +91 8886655677



Medicover Hospitals

VENKOJIPALAM VISAKHAPATNAM - 530017
ANDHRA PRADESH - INDIA



MEDICOVER HOSPITALS

A UNIT OF SAHRUDAYA HEALTHCARE PVT LTD.

Lab Report

Patient Name : **Mrs. THABITA MYLABATHULA** Age /Gender : **35 Y(s)/Female**
Bill No/ UMR No : **V4BC224199/V4U180793** Referred By : **Dr. CMO**
Received Dt : **13-Apr-24 08:37 am** Report Date : **13-Apr-24 10:23 am**
Lab No : **120000603342**

<u>Parameters</u>	<u>Result</u>	<u>Biological Reference In Method</u>
SERUM ALBUMIN	3.7	NewBorn: 0-4 days : 2.8 - 4.4 g/dL Children: 4 days - 14 years : 3.8 - 5.4 g/dL 14-18 years : 3.2 - 4.5 g/dL Adults : 3.5- 5.2 g/dL
GLOBULINS	* 4.4	2.5 - 3.5 g/dL
A/G RATIO	* 0.84	1.2 - 2.5
TOTAL PROTEIN		
TOTAL PROTEINS	8.1	1-2 years : 5.6-7.5 g/dL > 3 years : 6.0-8.0 g/dL Adults : 6.4-8.3 g/dL
HBA1C (GLYCOSYLATED HAEMOGLOBIN)		
HBA1C	* 28.4	Non -Diabetic : <= 5.6 % Pre Diabetic : 5.7 - 6.4 % Diabetic : >= 6.5 %
T3,T4 AND TSH		
T3	* 0.78	0.8 - 2.0 ng/mL
T4	* 4.26	5.1 - 14.1 ug/dL
TSH(THYROID STIMULATING HORMONE)	* 19.17	0.270 - 4.20 uIU/mL
BUN(BLOOD UREA NITROGEN)	16.02	7.0 - 21.0 mg/dL
GAMMA GT		
GAMMA GLUTAMYL TRANSFERASE(GGT)	8.26	6 - 42 U/L
BUN(BLOOD UREA NITROGEN)	11.21	
PLBS (POST LUNCH BLOOD GLUCOSE)		
PLBS (POST LUNCH BLOOD GLUCOSE)	452	Normal : 70- 139 mg/dL Impaired : 140 - 199 mg/dL Diabetic : >= 200 mg/dL

*** End Of Report ***

Doctor Incharge



Medicover Hospitals

VENKOJIPALAM VISAKHAPATNAM - 530017
ANDHRA PRADESH - INDIA



MEDICOVER HOSPITALS

A UNIT OF SAHRUDAYA HEALTHCARE PVT LTD.

Lab Report

Patient Name	: Mrs. THABITA MYLABATHULA	Age /Gender	: 35 Y(s)/Female
Bill No/ UMR No	: V4BC224199/V4U180793	Referred By	: Dr. CMO
Received Dt	: 13-Apr-24 12:35 pm	Report Date	: 13-Apr-24 02:19 pm
Lab No	: 120000603679		

Parameters

Result

Biological Reference In Method

Dr.MUDUGANTI SRINIVAS
MBBS, MD
CONSULTANT PATHOLOGIST

Dr.SRUJANA
MBBS, MD PATHOLOGY
CONSULTANT PATHOLOGIST

Dr.MOHAMMAD SIMI IQBAL
M.B.B.S, M.D
CONSULTANT BIOCHEMIST

Medicover Unit - I

18-1-3, KGH Down, Maharanieta,
Jagadamba Junction, Visakapatnam,
Andhrapradesh - 530 002.
Ph: +91 96526 69351

Medicover Unit - III

Sry. No. 27, Plot No. 05, RTI Road,
Health City, Arilova, Chinnagadalu Mandal,
Visakhapatnam, Andhrapradesh - 530 040.
Ph: +91 08916677888

Medicover - MVP

1-1-83, Sector -6, Venkojipalem,
MVP Colony, Visakapatnam,
Andhrapradesh-530017.
Ph: +91 8886655677



Medicover Hospitals

VENKOJIPALAM VISAKHAPATNAM - 530017
ANDHRA PRADESH - INDIA



MEDICOVER HOSPITALS

A UNIT OF SAHRUDAYA HEALTHCARE PVT LTD.

DEPARTMENT OF RADIOLOGY

Patient Name : Mrs. THABITA MYLABATHULA	Age / Gender : 35 Y(s)/Female
Bill No/ UMR No : V4BC224199/V4U180793	Referred By : Dr. CMO
Received Dt : 13-Apr-24 08:31 am	Report Date : 13-Apr-24 11:42 am

USG ABDOMEN (FEMALE)

LIVER

Measuring 17.7 cm. Enlarged in size with increased echotexture.
There is no evidence of IHBR/EHBR dilatation seen.
The portal and hepatic vessels are normal. No S.O.L. noted.

GALL BLADDER

Distended. Wall thickness is normal.
No evidence of intraluminal calculi/ masses seen.
Common bile duct appears normal with no intraluminal mass/ calculi.

PANCREAS

Head, Body & Tail are identified with normal echopattern & smooth outlines.
The pancreatic duct system appears normal.
The peri pancreatic fat planes are well preserved.

SPLEEN

Normal in size (10.6 cm) and homogenous echotexture.

RIGHT KIDNEY

Measuring 12.7 x 4.3 cm. Normal in size and echopattern.
Cortico-Medullary differentiation maintained.
No evidence of mass / calculi / hydroureteronephrosis seen.

LEFT KIDNEY

Measuring 11.6 x 5.5 cm. Normal in size and echopattern.
Cortico-Medullary differentiation maintained.
No evidence of mass / calculi / hydroureteronephrosis seen.
No evidence of suprarenal / retroperitoneal mass noted.

URINARY BLADDER

Distended. Wall thickness is normal.
No intraluminal mass / calculi noted.

UTERUS

Measuring 9.6 x 5.8 x 5.1 cm. Normal in size with normal myometrial echoanatomy. The Endometrium measuring 5 mm in thickness with regular outlines and homogenous echopattern.

RIGHT OVARY

Measuring 3.1 x 1.4 cm

Medicover Unit - I

18-1-3, KGH Down, Maharanipecta,
Jagadamba Junction, Visakapantam,
Andhrapradesh - 530 002.
Ph: +91 96526 69351

Medicover Unit - III

Sry. No. 27, Plot No. 05, BRTS Road,
Health City, Arilova, Chinnagadalu Mandal,
Visakhapatnam, Andhrapradesh - 530 040.
Ph: +91 08916677888

Medicover - MVP

1-1-83, Sector -6, Venkojipalem,
MVP Colony, Visakapatnam,
Andhrapradesh-530017.
Ph: +91 8886655677



Medicover Hospitals

VENKOJIPALAM VISAKHAPATNAM - 530017
ANDHRA PRADESH - INDIA



MEDICOVER HOSPITALS

A UNIT OF SAHRUDAYA HEALTHCARE PVT LTD.

DEPARTMENT OF RADIOLOGY

Patient Name : Mrs. THABITA MYLABATHULA	Age /Gender : 35 Y(s)/Female
Bill No/ UMR No : V4BC224199/V4U180793	Referred By : Dr. CMO
Received Dt : 13-Apr-24 08:31 am	Report Date : 13-Apr-24 11:42 am

LEFT OVARY


Measuring 3.2 x 1.8 cm

Both ovaries are normal in size, echopattern.
No evidence of adnexal solid / cystic mass lesion seen.
No evidence of ascites/ pleural effusion seen.
No detectable bowel pathology seen.

IMPRESSION

* Fatty hepatomegaly.

*** End Of Report ***


DR. VULAPU CHENNAKRISHNA RAO, .
MBBS, DNB
CONSULTANT RADIOLOGIST

1. This report is not valid for medico-legal purpose.

2. In case of any discrepancy due to machine error, please get it rectified immediately. ~~Medicover Unit~~ ~~Medicover Unit~~ ~~Medicover Unit~~

Medicover Unit
18-1-3, KGH Down, Maharanipeta,
Jagadamba Junction, Visakapatnam,
Andhrapradesh - 530 002.
Ph: +91 96526 69351

Medicover Unit
Sry. No. 27, Plot No. 05, BRTS Road,
Health City, Arilova, Chinnagadalu Mandal,
Visakhapatnam, Andhrapradesh - 530 040.
Ph: +91 08916677888

Medicover - MVP
1-1-83, Sector -6, Venkojipalem,
MVP Colony, Visakapatnam,
Andhrapradesh-530017.
Ph: +91 8886655677



Medicover Hospitals

VENKOJIPALAM VISAKHAPATNAM - 530017
ANDHRA PRADESH - INDIA



MEDICOVER HOSPITALS

A UNIT OF SAHRUDAYA HEALTHCARE PVT LTD.

Lab Report

Patient Name	: Mrs. THABITA MYLABATHULA	Age /Gender	: 35 Y(s)/Female
Bill No/ UMR No	: V4BC224199/V4U180793	Referred By	: Dr. CMO
Received Dt	: 13-Apr-24 08:31 am	Report Date	: 13-Apr-24 11:58 am
Lab No	: 0		

2D ECHO WITH COLOUR DOPPLER

MEASUREMENTS

LVID(D)	4.1 Cms
LVID(s)	2.6 Cms
LVEF	66 %
IVS (d)	0.9 Cms
PWD (d)	0.9 Cms

VALVES

MITRAL VALVE	NORMAL
AORTIC VALVE	NORMAL
TRICUSPID VALVE	NORMAL
PULMONARY VALVE	NORMAL

CHAMBER

RIGHT ATRIUM	NORMAL
RIGHT VENTRICLE	NORMAL
LEFT ATRIUM	2.5 Cms
LEFT VENTRICLE	NORMAL
RWMA	NO
SYSTOLIC FUNCTION	GOOD
DIASTOLIC DYSFUNCTION	NO
CLOT	NO

SEPTAE

INTER ATRIAL SEPTUM	INTACT
INTER VENTRICULAR SEPTUM	INTACT

GREAT ARTERY AND OTHERS

AORTA	2.6 Cms
PULMONARY ARTERY	NORMAL
PERICARDIUM	NORMAL
IVC/SVC/CS	NORMAL

DOPPLER STUDY

MITRAL FLOW	E > A
AORTIC FLOW	1.2 M/sec
PULMONARY FLOW	1.0 M/sec
TRICUSPID FLOW	NORMAL
OTHER FLOWS	NIL

COLOUR DOPPLER

MR	NO
AR	NO
TR	NO
PR	NO

FINAL IMPRESSION

Medicover Unit - I

18-1-3, KGH Down, Maharanipecta,
Jagadamba Junction, Visakapantam,
Andhrapradesh - 530 002.
Ph: +91 96526 69351

Medicover Unit - III

Sry. No. 27, Plot No. 05, BRTS Road,
Health City, Arilova, Chinmagadalu Mandal,
Visakhapatnam, Andhrapradesh - 530 040.
Ph: +91 08916677888

Medicover - MVP

1-1-83, Sector -6, Venkojipalem,
MVP Colony, Visakapantam,
Andhrapradesh-530017.
Ph: +91 8886655677



Medicover Hospitals

VENKOJIPALAM VISAKHAPATNAM - 530017
ANDHRA PRADESH - INDIA



MEDICOVER HOSPITALS

A UNIT OF SAHRUDAYA HEALTHCARE PVT LTD

Lab Report

Patient Name	: Mrs. THABITA MYLABATHULA	Age /Gender	: 35 Y(s)/Female
Bill No/ UMR No	: V4BC224199/V4U180793	Referred By	: Dr. CMO
Received Dt	: 13-Apr-24 08:31 am	Report Date	: 13-Apr-24 11:58 am
Lab No	: 0		

- * NO RWMA OF LV
- * GOOD LV SYSTOLIC FUNCTION (EF : 66 %)
- * NO MR / AR / TR/ PAH

*** End Of Report ***

Doctor Incharge

Dr.ARCHANA BEHRA
MD.,DNB(CARDIOLOGY)
CONSULTANT CARDIOLOGIST

Dr.BODEPUDI SRIKANTH
MD, DM
CONSULTANT CARDIOLOGIST

Dr.K P RANGANAYAKULU
MD., DM.
INTERVENTIONAL CARDIOLOGIST

Dr.S.SRIKARA SAMIR NANDAN
MD., DM.
INTERVENTIONAL CARDIOLOGIST

Dr.RAVIKUMAR GURUGUBELLI
MD, DM
CONSULTANT CARDIOLOGIST

Dr.A.SURESH
MBBS,MD(GM),DM-CARDIOLOGY,
SENIOR CONSULTANT

Medicover Unit - I

18-1-3, KGH Down, Maharanipecta,
Jagadamba Junction, Visakapatnam,
Andhrapradesh - 530 002.
Ph: +91 96526 69351

Medicover Unit - III

Sry.No. 27, Plot No. 05, BRIS Road,
Health City, Arilova, Chinnagadalu Mandal,
Visakhapatnam, Andhrapradesh - 530 040.
Ph: +91 08916677888

Medicover - MVP

1-1-83, Sector -6, Venkojipalem,
MVP Colony, Visakapatnam,
Andhrapradesh-530017.
Ph: +91 8886655677



Medicover Hospitals

VENKOJIPALAM VISAKHAPATNAM - 530017
ANDHRA PRADESH - INDIA



MEDICOVER HOSPITALS

A UNIT OF SAHRUDAYA HEALTHCARE PVT LTD.

DEPARTMENT OF RADIOLOGY

Patient Name : Mrs. THABITA MYLABATHULA	Age / Gender : 35 Y(s)/Female
Bill No/ UMR No : V4BC224199/V4U180793	Referred By : Dr. CMO
Received Dt : 13-Apr-24 08:31 am	Report Date : 13-Apr-24 11:43 am

X-RAY CHEST PA VIEW

FINDINGS

- The cardiac size & configuration appear normal.
The Aorta and pulmonary vasculature appear normal.
There is no evidence of mediastinal widening.
Both the lungs and CP angles are clear.
The soft tissues and the bones of the rib cage displayed no abnormality.

IMPRESSION

- * Normal study.
- Kindly correlate clinically.

*** End Of Report ***

Dr. DEVARA ANIL K V, MD,DNB,DMRE
CONSULTANT INTERVENTIONAL
RADIOLOGIST

1. This report is not valid for medico-legal purpose.

2. In case of any discrepancy due to machine error or typing error, please get it rectified immediately.

Medicover Unit - I
48-1-3, RCF Colony, Manarampeta,
Jagadamba Junction, Visakapatnam,
Andhrapradesh - 530 002.
Ph: +91 96526 69351

Medicover Unit - II

Sry. No. 27, Plot No. 05, BRTS Road,
Health City, Arilova, Chinnagadalu Mandal,
Visakhapatnam, Andhrapradesh - 530 040.
Ph: +91 08916677888

Medicover - MVP

1-1-83, Sector -6, Venkojipalem,
MVP Colony, Visakapatnam,
Andhrapradesh-530017.
Ph: +91 8886655677

M THABITA
Female

13/04/2024 08:38:48

MEDCOVER HOSPITALS MVP VZAG

35 Years

WELLNESS

Rate 73 . SINUS RHYTHM.....normal P axis, V-rate 50- 99

. BASELINE WANDER IN LEAD(S) V3

PR 140
QRSD 94
QT 380
QTC 419

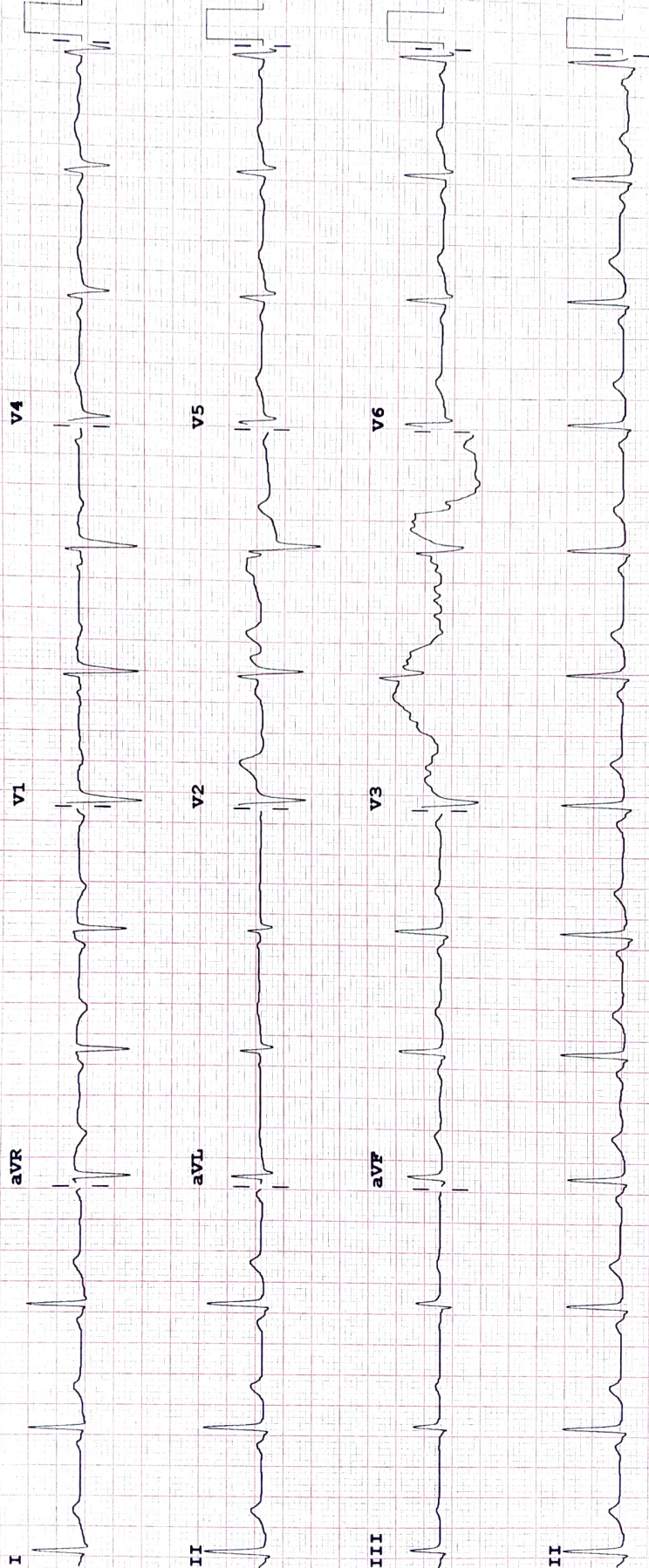
--AXIS--

P 47
QRS 48
T 45

12 Lead; Standard Placement

- NORMAL ECG -

Unconfirmed Diagnosis



Device:

Speed: 25 mm/sec Limb: 10 mm/mV Chest: 10.0 mm/mV

F 50~ 0.50- 40 Hz W

PE090A CL