



भारत सरकार  
Government of India

अनिल कुमार गोयल  
Anil Kumar Goyal  
जन्म तिथि / DOB : 05/12/1972  
पुरुष / Male

3896 8807 7036

मेरा आधार, मेरी पहचान

*Anil Kumar*

ONEPLUS ULTRASOUND LAB  
47 Harsh Vihar, Pitam Pura,  
Delhi-110034  
Ph: 011-42480101, 9599913051  
E-mail: oneplusul@gmail.com

Dr. NITIN AGARWAL  
MBBS, MD  
Regn. No. DMC-R-1436

आधार  
Unique Identification Authority of India

पता:  
275 - 276, बी- 6, रोहिणी सेक्टर-७,  
रोहिणी सेक्टर ७, उत्तर पश्चिमी,  
दिल्ली, 110085

Address:  
C/O. , 275 - 276, B-6, Rohini  
Sector-7, Rohini Sector-7 North  
West Delhi, Delhi, 110085

3896 8807 7036

1947 help@uidai.gov.in www.uidai.gov.in

# ONEPLUS ULTRASOUND LAB

47, HARSH VIHAR, PITAMPURA, DELHI- 110034

MR. ANIL KUMAR GOYAL

Age : 51/M

Ref. by : MEDWHEEL

Indication1 :

Indication2 :

Indication3 :

COMMENTS : Normal ECG.

ID : 2583

Recorded : 11-5-2024 9:25

Medication1 :

Medication2 :

Medication3 :

BPM : 77

BP : 122/84

P Axis : 53 deg

QRS Axis : 50 deg

T Axis : 44 deg

P duration : 96 msec

PR duration : 140 msec

QRS duration : 100 msec

QT interval : 323 msec

QTc interval : 352 msec

Raw E.C.G.(Sec)

Unconfirmed Report Reviewed By:

Cardiologist

*P.K. GUPTA*  
Dr. P.K. GUPTA  
MBBS, MD  
Reg. No-1071

ONEPLUS ULTRASOUND LAB

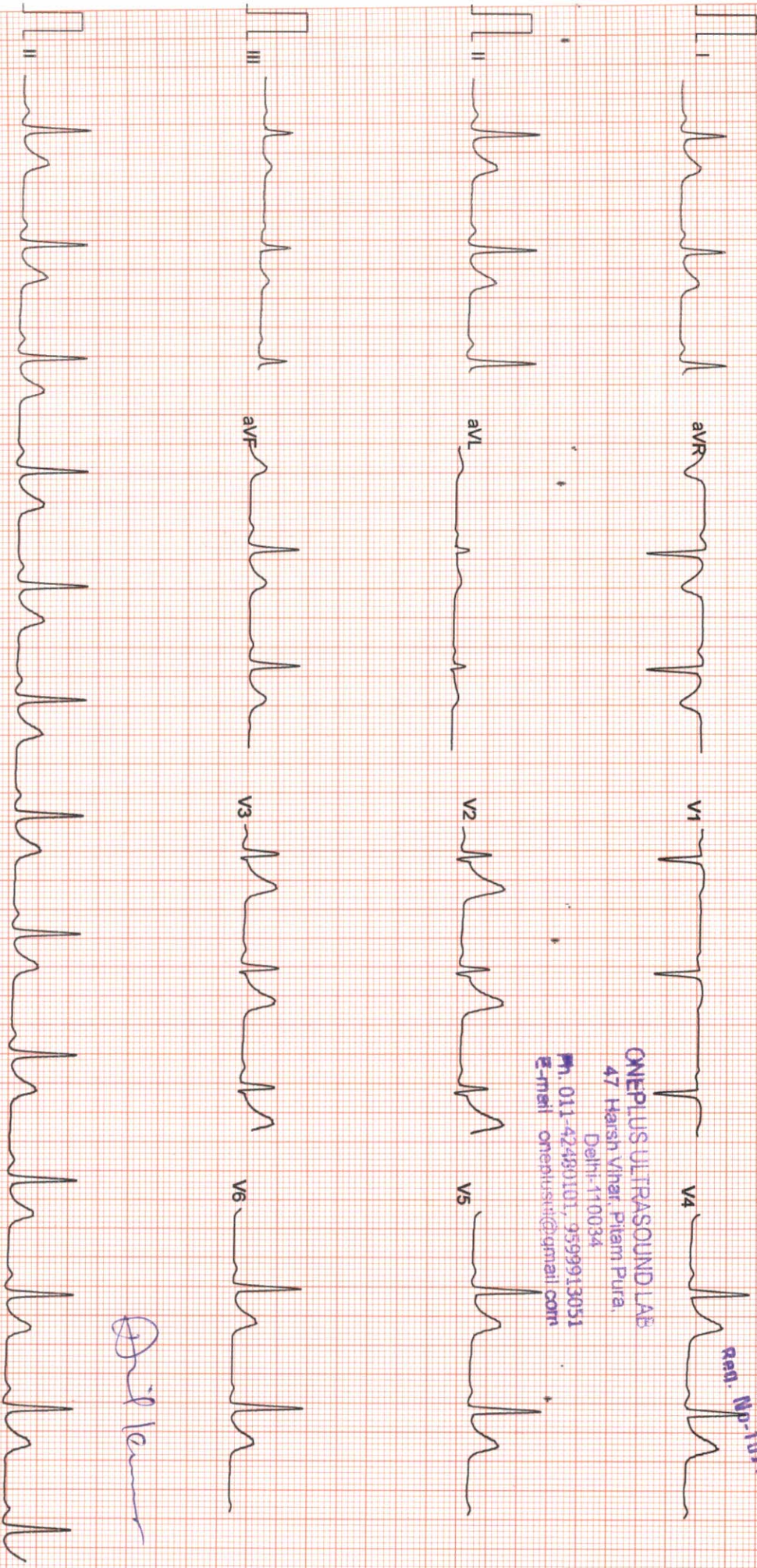47 Harsh Vihar, Pitam Pura,

Delhi-110034

Ph. 011-42480101, 9599913051

E-mail: oneplusul@gmail.com

*Anil Kumar*



Filtered

25mm/sec 10mm/mV

CardiCom, INDIA

# ONEPLUS ULTRASOUND LAB

47, HARSH VIHAR PITAMPURA DELHI 110034

MR. ANIL KUMAR GOYAL  
 ID : 997  
 HWVW : 172/111  
 Recorded : 11-5-2024 9:27

Age/Sex : 51/M  
 Ref by : MEDWHEEL  
 Indication1 :  
 Indication2 :  
 Indication3 :

TREADMILL TEST SUMMARY REPORT  
 Protocol: BRUCE  
 History:  
 Medication1 :  
 Medication2 :  
 Medication3 :

PHASE	PHASE TIME	STAGE TIME	SPEED (Km./Hr.)	*GRADE (%)	H.R. (BPM)	B.P. (mmHg)	RPP X100 <sup>4</sup>	II	ST LEVEL (mm) V2	V5	METS
SUPINE STANDING					75	122/84	91	0.7	26	1.2	
STAGE 1	2:59	2:59	2.70	10.00	108	134/86	144	0.5	2.3	1.0	4.80
STAGE 2	5:59	2:59	4.00	12.00	121	146/88	176	0.2	2.6	1.3	7.10
STAGE 3	6:59	0:59	5.40	14.00	146	160/90	233	0.4	2.0	0.5	8.06
PEAK EXER	7:07	1:07			147	160/90	235	0.3	2.1	0.6	8.19
RECOVERY	2:59	2:59	0.00	0.00	78	130/84	101	0.0	1.1	0.2	

**RESULTS**  
 Exercise Duration : 7.07 Minutes  
 Max Heart Rate : 147 bpm 86% of target heart rate 169 bpm  
 Max Blood Pressure : 160/90 mmHg  
 Max Work Load : 8.19 METS  
 Reason of Termination :  
 IMPRESSIONS : Negative for well run

**Dr. P. K. GUPTA**  
 MBBS, MD  
 Reg. No-1071  
 Cardiologist

*Anil Kumar*

**ONEPLUS ULTRASOUND LAB**  
 47 Harsh Vihar Pitampura  
 Delhi-110034  
 Ph: 011-42-467101, 9999913051  
 E-mail: onepplusul@gmail.com

# ONEPLUS ULTRASOUND LAB

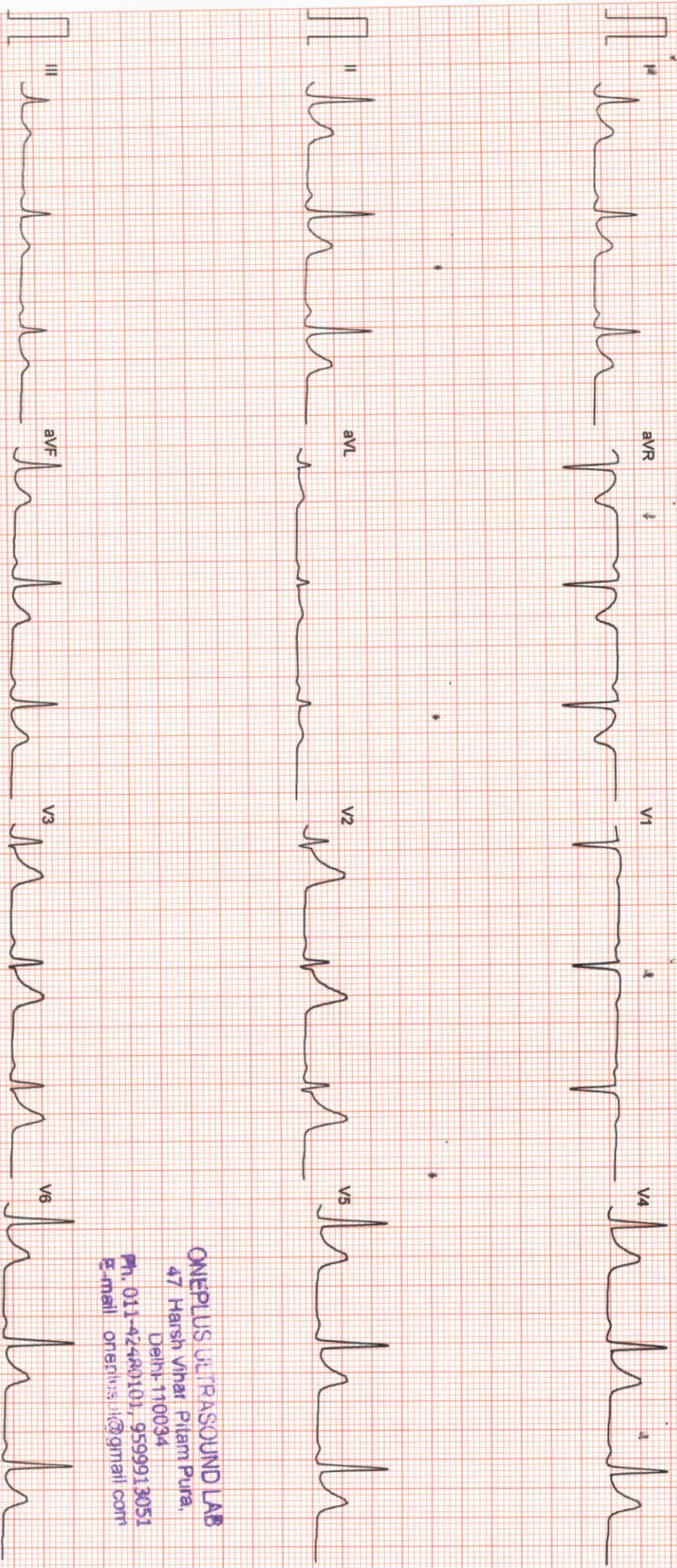
SUPINE  
PRETEST

ST @ 10mm/mV  
80ms PostJ

MR. ANIL KUMAR GOYAL  
I.D. : 997  
AGE/SEX : 51/M  
RECORDED : 11-5-2024 9:27

RATE : 75 BPM  
B.P. : 122/84 mmHg

RAW E.C.G.



ONEPLUS ULTRASOUND LAB  
47 Harsh Vihar Pitam Pura,  
Delhi-110034  
Ph. 011-42480101, 9599913051  
E-mail onedics.in@gmail.com

Filtered

25mm/sec 10mm/mV

CardiCom, INDIA Ph:091-731-2620740, Telefax:091-731-2431214

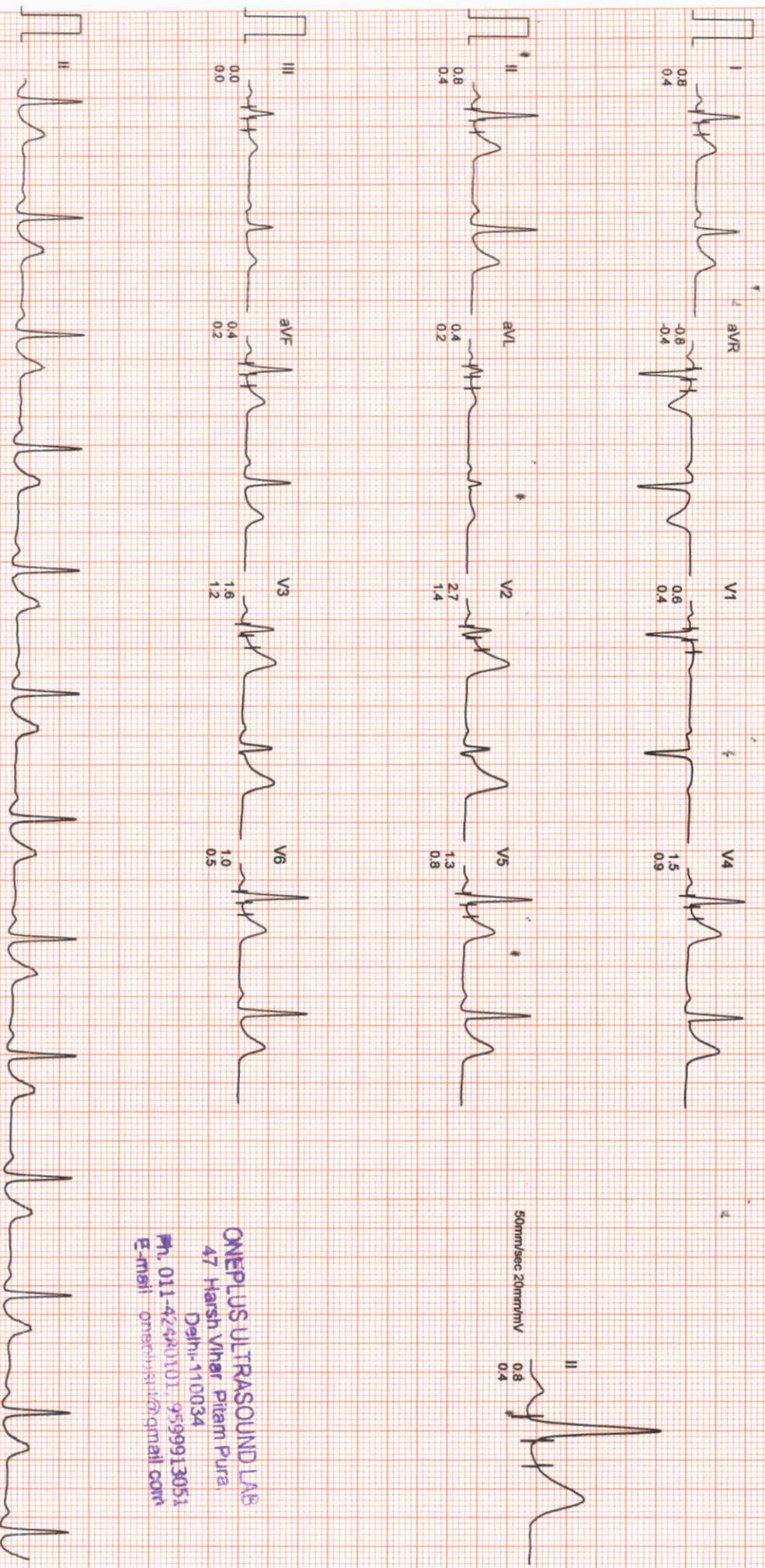
# ONEPLUS ULTRASOUND LAB

STANDING  
PRETEST

ST @ 10mm/mV  
80ms PostU

Mr. ANIL KUMAR GOYAL  
I.D : 997  
AGE/SEX : 51/M  
RECORDED : 11-5-2024 9:27  
RATE : 75 BPM  
B.P. : 122/84 mmHg

LINKED MEDIAN



ONEPLUS ULTRASOUND LAB  
47 Harsh Vihar Pitam Pura  
Delhi-110034  
Ph. 011-42201101, 9599913051  
E-mail: onepplus@177@gmail.com

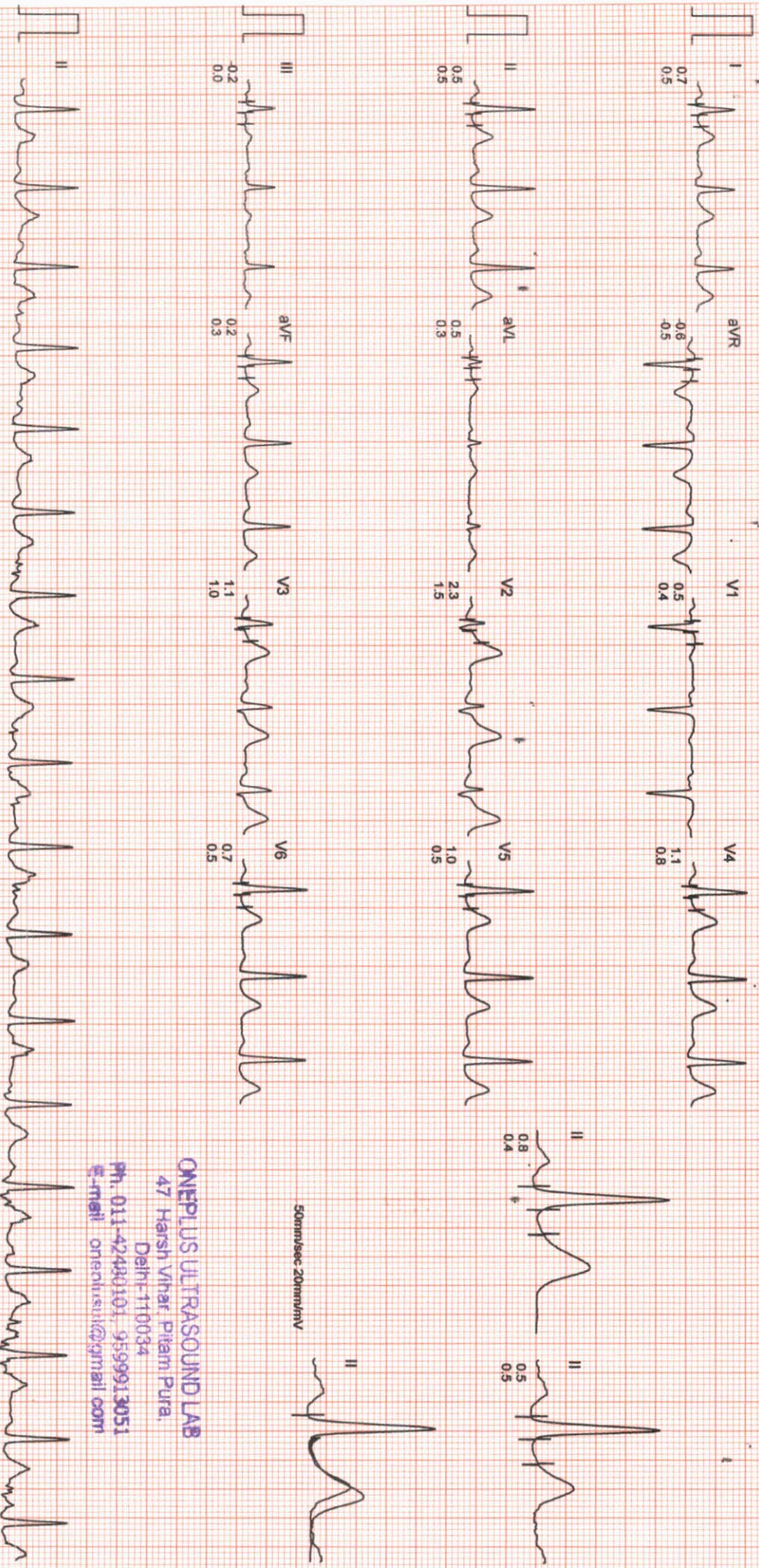
# ONEPLUS ULTRASOUND LAB

Mr. ANIL KUMAR GOYAL  
I.D. : 997  
AGE/SEX : 51/M  
RECORDED : 11-5-2024 9:27

BRUCE  
EXERCISE 1  
PHASE TIME : 2:59  
STAGE TIME : 2:59

ST @ 10mm/mV  
80ms PostJ  
SPEED : 2.7 Km./Hr.  
GRADE : 10.0 %

LINKED MEDIAN



**ONEPLUS ULTRASOUND LAB**  
47 Harsh Vihar Pitam Pura,  
Delhi-110034  
Ph. 011-42480101, 9599913051  
E-mail oneplusul@gmail.com

Filtered Computer Corrected Baseline

25mm/sec 10mm/mV

CardiCom, INDIA Ph.:091-731-2620740, TeleFax:091-731-2431214

# ONEPLUS ULTRASOUND LAB

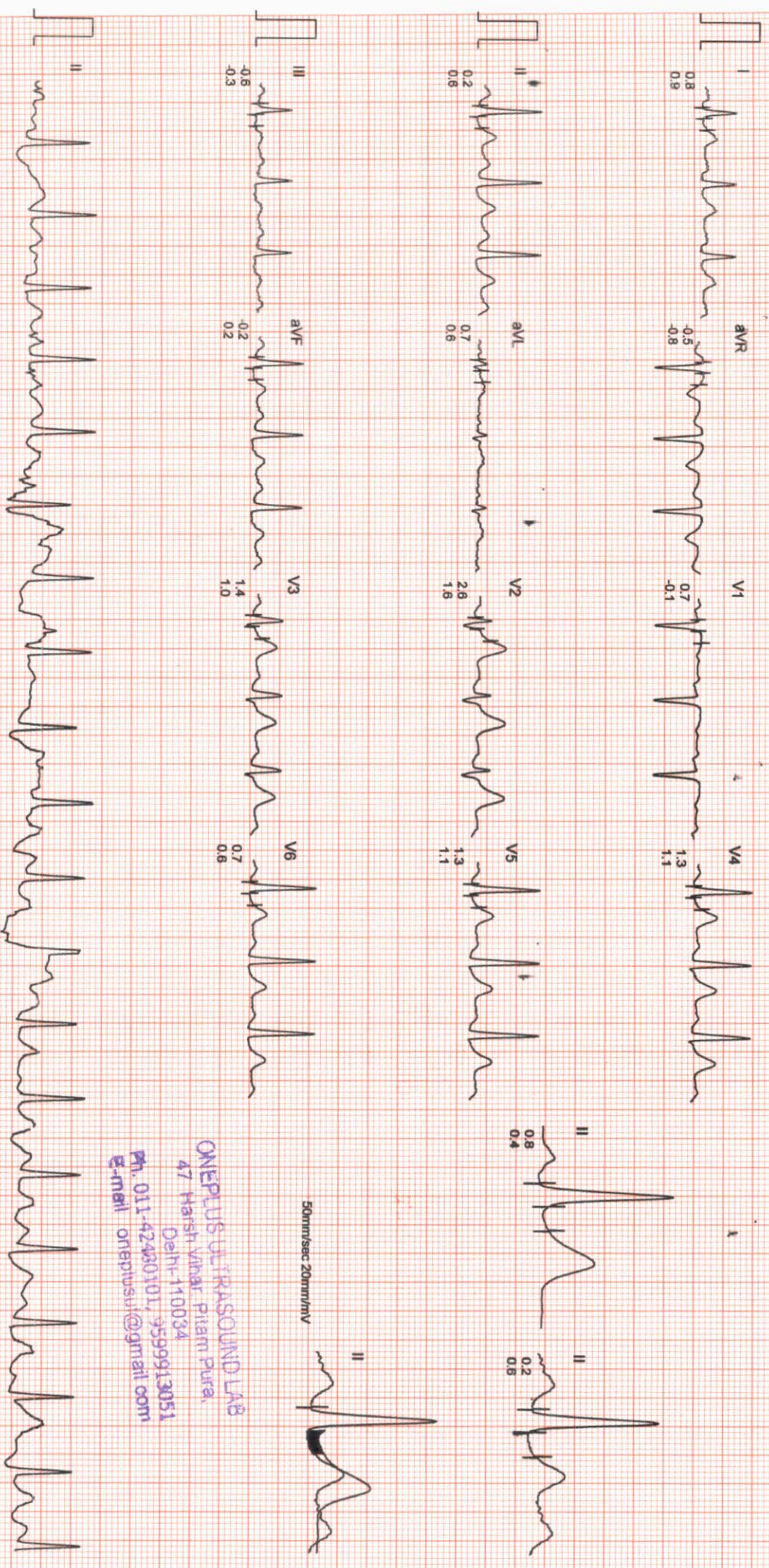
Mr. ANIL KUMAR GOYAL  
I.D. : 997  
AGE/SEX : 51/M  
RECORDED : 11-5-2024 9:27

RATE : 121 BPM  
B.P. : 146/88 mmHg

BRUCE  
EXERCISE 2  
PHASE TIME : 5:59  
STAGE TIME : 2:59

ST @ 10mm/mV  
80ms PostJ  
SPEED : 4.0 Km./Hr.  
GRADE : 12.0 %

LINKED MEDIAN



50mm/sec 20mm/mV

ONEPLUS ULTRASOUND LAB  
47 Harsh Vihar Pitam Pura,  
Delhi-110034  
Ph. 011-42480101, 9599913051  
E-mail onepiusuf@gmail.com

Filtered Computer Corrected Baseline

25mm/sec 10mm/mV

CardiCom, INDIA Ph.:091-731-2620740, Telefax:091-731-2431214



# ONEPLUS ULTRASOUND LAB

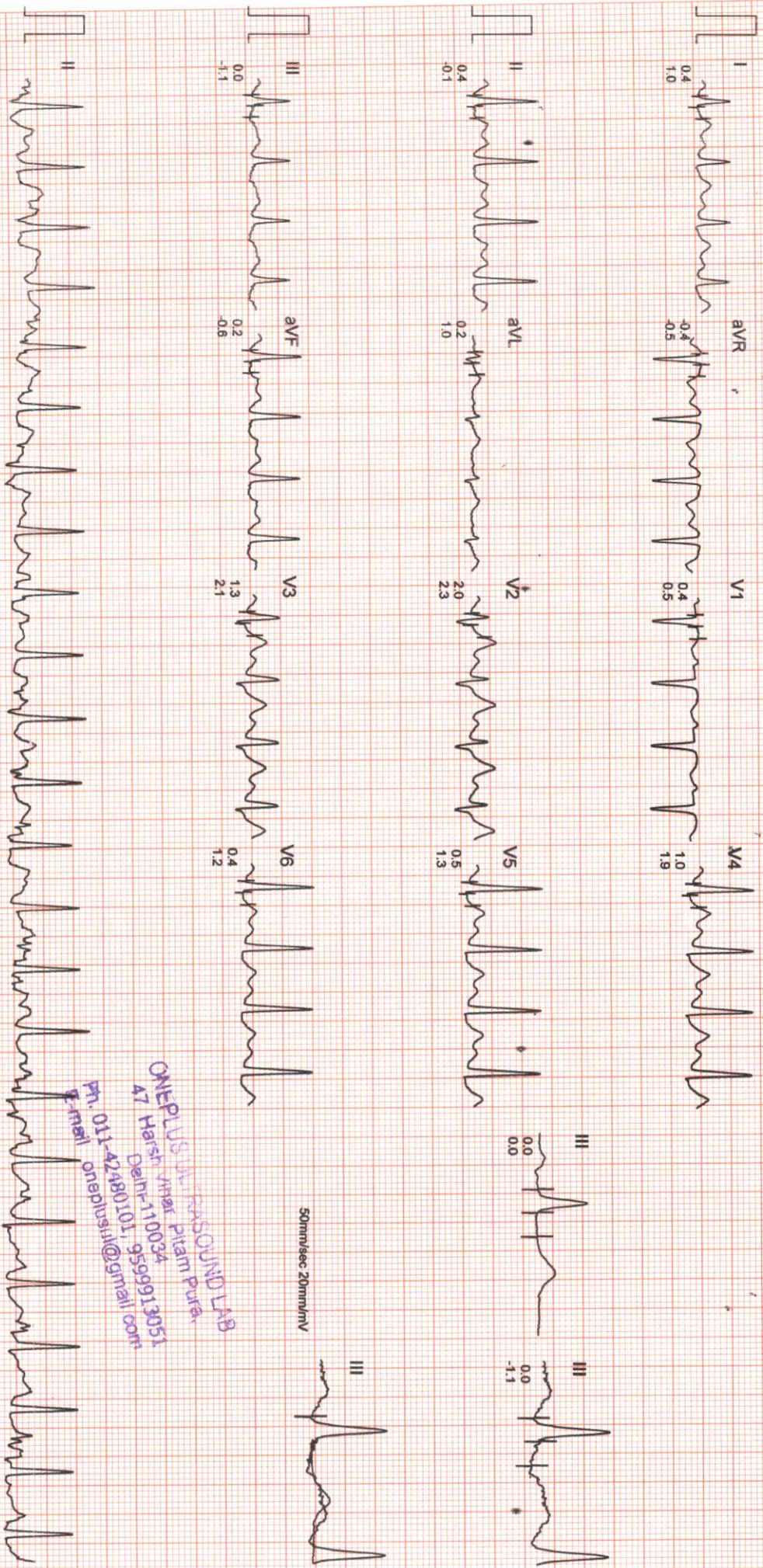
Mr. ANIL KUMAR GOYAL  
I.D. : 997  
AGE/SEX : 51/M  
RECORDED : 11-5-2024 9:27

RATE : 146 BPM  
B.P. : 160/90 mmHg

BRUCE  
EXERCISE 3  
PHASE TIME : 6:59  
STAGE TIME : 0:59

ST @ 10mm/mV  
80ms PostJ  
SPEED : 5.4 Km./Hr.  
GRADE : 14.0 %

LINKED MEDIAN



ONEPLUS ULTRASOUND LAB  
47 Harsh Vihar Pitampura,  
Delhi-110034  
Ph: 011-42490101, 9599913051  
E-mail: oneplusul@gnmail.com

Filtered Computer Corrected Baseline

25mm/sec 10mm/mV

CardiCom, INDIA Ph.:091-731-2620740, TeleFax:091-731-2431214

# ONEPLUS ULTRASOUND LAB

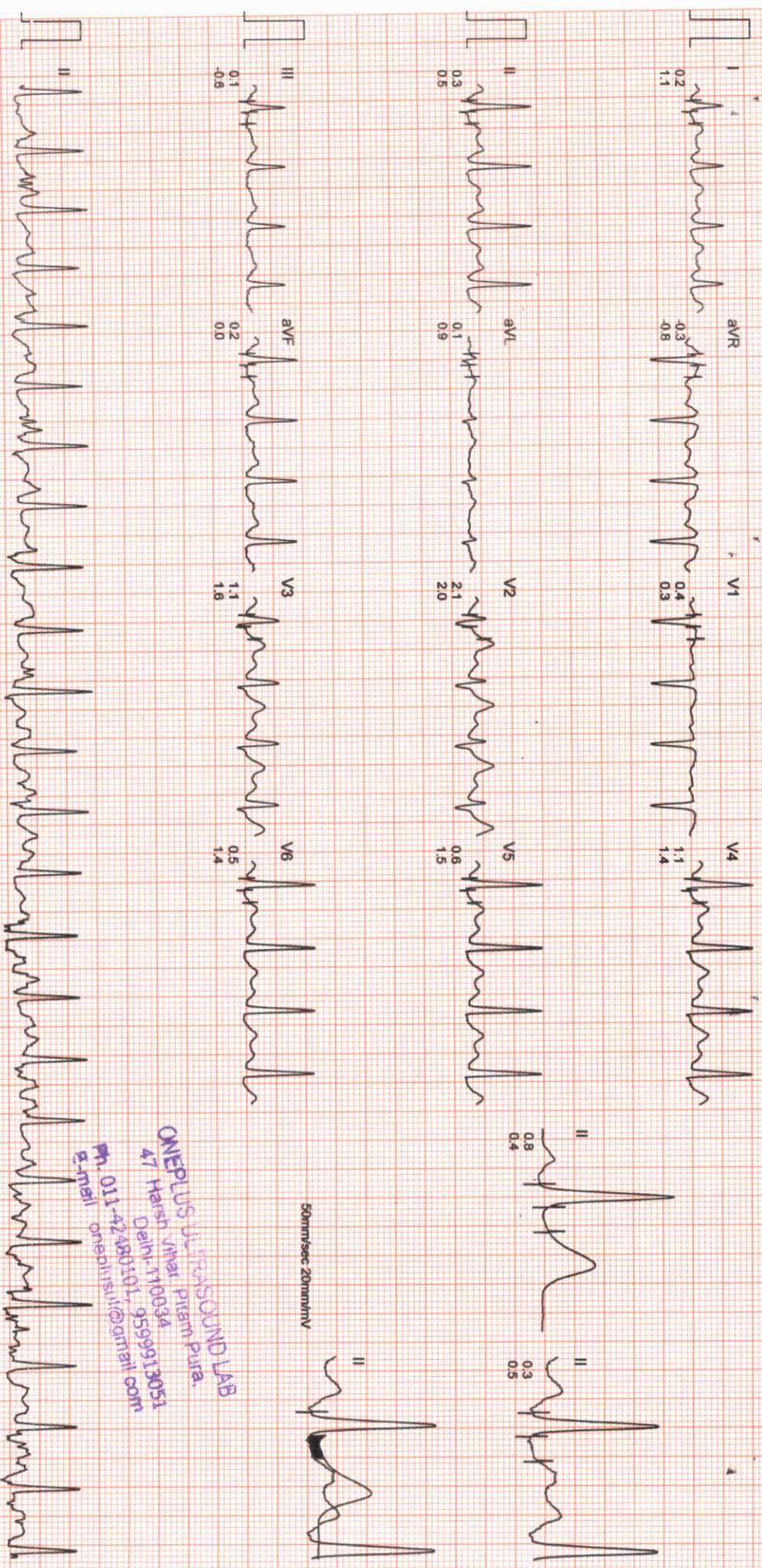
Mr. ANIL KUMAR GOYAL  
I.D. : 997  
AGE/SEX : 51/M  
RECORDED : 11-5-2024 9:27

RATE : 147 BPM  
B.P. : 160/90 mmHg

BRUCE  
PEAK EXER  
PHASE TIME : 7:07  
STAGE TIME : 1:07

ST @ 10mm/mV  
80ms PostJ  
SPEED : 5.4 Km./Hr.  
GRADE : 14.0 %

LINKED MEDIAN



50mm/sec 20mm/mV

ONEPLUS ULTRASOUND LAB  
47 Harsh Vihar Pitambara,  
Delhi-110034  
Ph. 011-42480101, 9599913051  
E-mail oneplusul@gmail.com

# ONEPLUS ULTRASOUND LAB

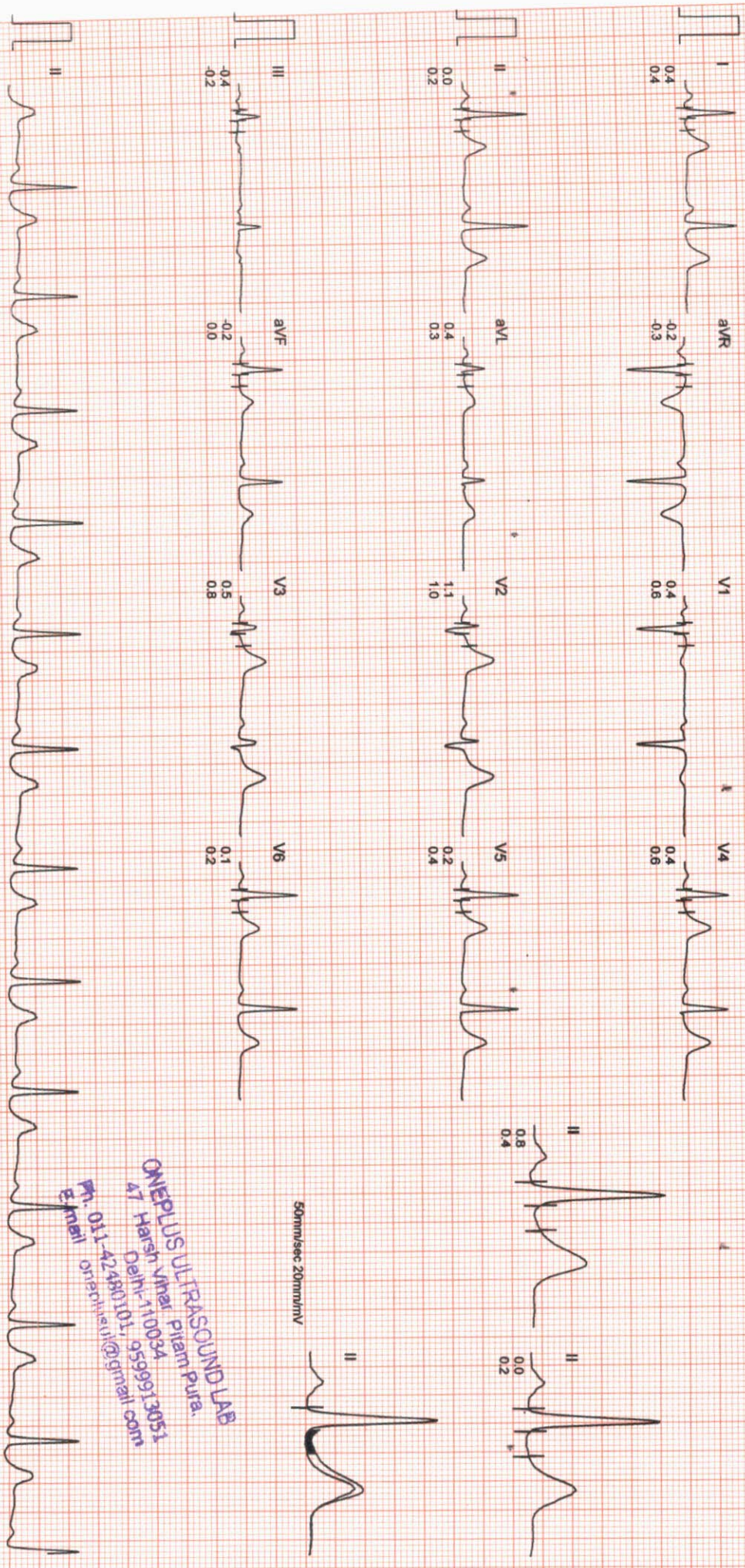
Mr. ANIL KUMAR GOYAL  
I.D. : 997  
AGE/SEX : 51/M  
RECORDED : 11-5-2024 9:27

RATE : 78 BPM  
B.P. : 130/84 mmHg

BRUCE  
RECOVERY  
PHASE TIME : 2:59

ST @ 10mm/mV  
80ms PostJ  
SPEED : 0.0 Km./Hr.  
GRADE : 0.0%

LINKED MEDIAN

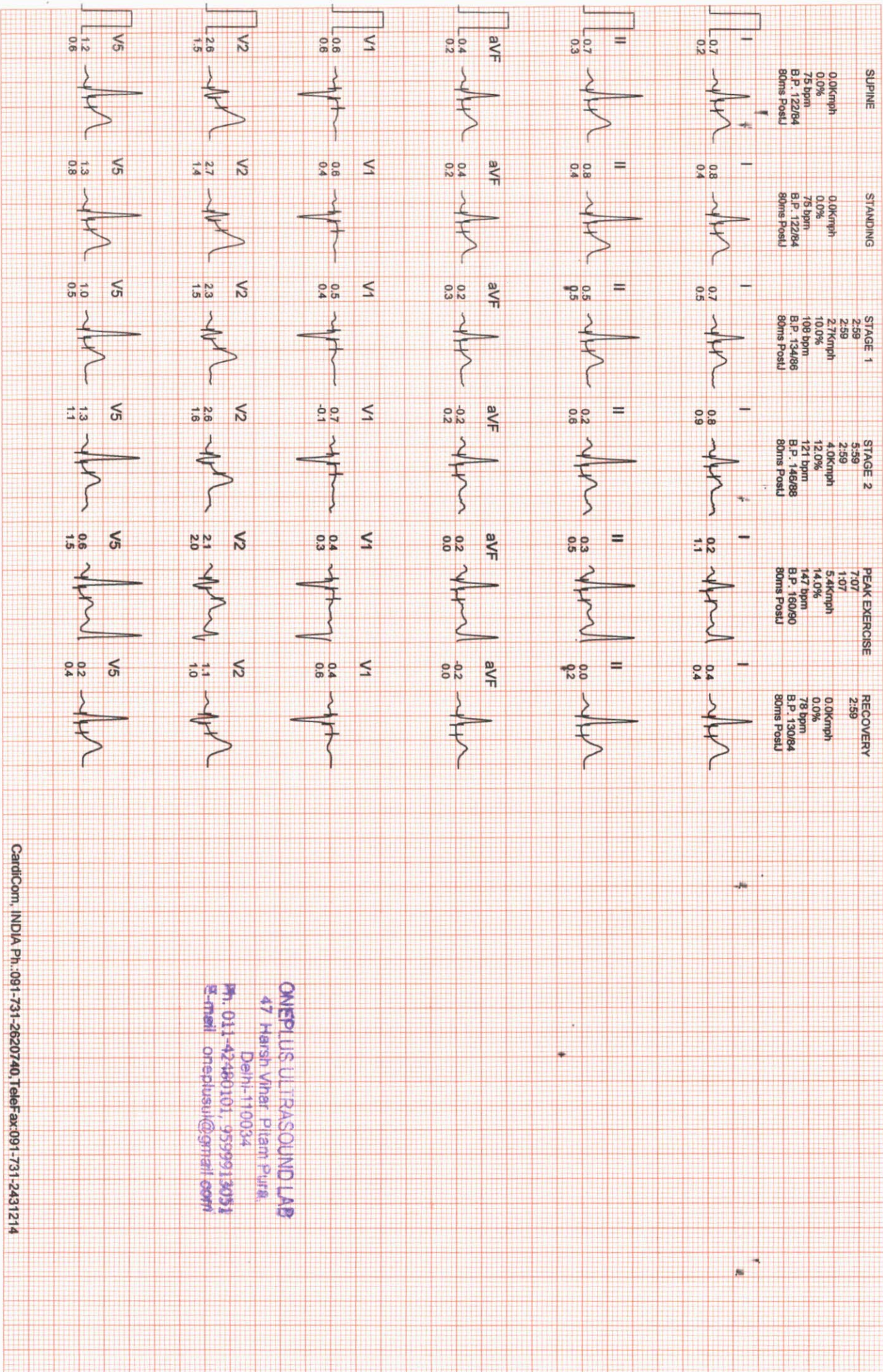

ONEPLUS ULTRASOUND LAB  
47 Harsih Vihar, Pritam Purva,  
Dhehr-Dhehr-1, 95999313051  
Mr. Anil Kumar Goyal  
E-mail: anilgoyal101@gmail.com  
Ph: 011-42480101

Filtered Computer Corrected Baseline

25mm/sec 10mm/mV

CardiCom, INDIA Ph.-091-731-2620740, TeleFax:091-731-2431214



ONEPLUS ULTRASOUND LAB  
 47 Harsih Vihar, Pitam Pura,  
 Delhi-110034  
 Ph. 011-42440101, 9599913051  
 E-mail onepusul@gmail.com

# ONEPLUS ULTRASOUND LAB

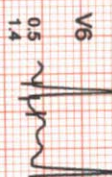
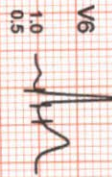
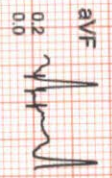
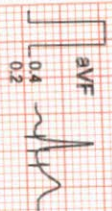
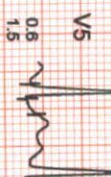
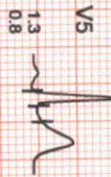
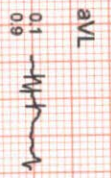
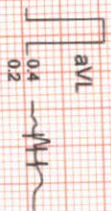
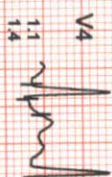
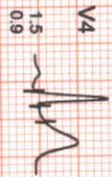

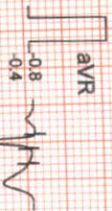
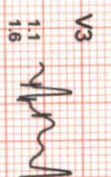

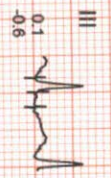
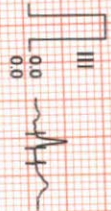
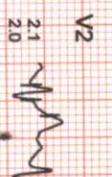
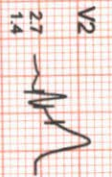
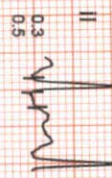
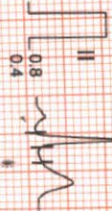
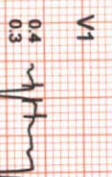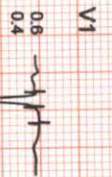
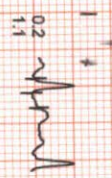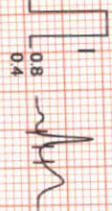
## COMPARISON REPORT

STANDING  
 0.0kmph  
 0.0%  
 75 bpm  
 B.P. 122/84  
 80ms PostU

PEAK EXERCISE  
 7:07  
 1:07  
 5.4kmph  
 14.0%  
 147 bpm  
 B.P. 160/90  
 80ms PostU

STANDING  
 0.0kmph  
 0.0%  
 75 bpm  
 B.P. 122/84  
 80ms PostU

PEAK EXERCISE  
 7:07  
 1:07  
 5.4kmph  
 14.0%  
 147 bpm  
 B.P. 160/90  
 80ms PostU



ONEPLUS ULTRASOUND LAB  
 47 Harsh Vihar Pitam Pura,  
 Delhi-110034  
 Ph. 011-42480101, 9599913051  
 E-mail onepiusul@gmail.com



NAME	:Mr. ANIL KUMAR GOYAL	Barcode No	:10171927
AGE/GENDER	:51 YRS/Male	SPECIMEN DATE	:11/May/2024 08:36AM
PATIENT ID	:135986	SPECIMEN RECEIVED	:11/May/2024 08:46AM
REFERRED BY	:Dr. MEDIWHEEL	REPORT DATE	:11/May/2024 03:27PM
CENTRE NAME	:ONEPLUS ULTRASOUND LAB	LAB NO.	:012405110004

Test Name	Result	Unit	Ref. Range
-----------	--------	------	------------

**HAEMATOLOGY**

**MediWheel Health Checkup >40 Male**

Sample Type:EDTA Blood

<b>Glycosylated Hemoglobin (HbA1c)</b> HPLC	5.6	%	Non Diabetic adults <5.7 Prediabetic (at risk) 5.7-6.4 Diabetes >6.4
--	-----	---	--

<b>Estimated average blood glucose (eag)</b> CALCULATED	114		
--	-----	--	--

Reference range (mg/dl):

90 - 120:Excellent control, 121 - 150:Good Control, 151 - 180:Average Control, 181 - 210:Action Suggested

>211:Panic value

**Dr. NITIN AGARWAL**  
MBBS, MD  
Regn. No. DMC-R-1436

  
**DR. NITIN AGARWAL**  
MBBS,MD(PATHOLOGIST)

Checked By.

47, Harsh Vihar, Pitampura, Delhi-34 ☎ 011-4248 0101, 9599913051

✉ Email: [oneplusul@gmail.com](mailto:oneplusul@gmail.com) 🌐 [www.oneplusul.in](http://www.oneplusul.in)

Page 1 of 9

- Clinical correlation is essential for final diagnosis. • If test results are unsatisfactory please contact personally or on phone.
- This report is for perusal of doctors only. • All disputes are subject to Delhi jurisdiction only. • Not for medico legal case.
- All congenital anomalies in a foetus may not be diagnosed in routine obstetric ultrasound.



# OnePLUS Ultrasound Lab

— QUALITY FIRST... ALWAYS! —

**Dr. Nitin Agarwal**

Pathologist & Director  
MBBS, MD, FAGE  
Ex. Chief of Lab  
Dr. Lal Path labs.

**Dr. Pooja (Garg) Agarwal**

Radiologist & Director  
MBBS (MAMC) DMRD (MAMC)  
Imaging Expert In Fetal And Maternal Medicine,  
University of Barcelona, Spain  
Fetal Medicine Foundation (UK) Accreditation



ITDOSE INFOSYSTEMS PVT. LTD.

NAME	:Mr. ANIL KUMAR GOYAL	Barcode No	:10171927
AGE/GENDER	:51 YRS/Male	SPECIMEN DATE	:11/May/2024 08:36AM
PATIENT ID	:135986	SPECIMEN RECEIVED	:11/May/2024 08:46AM
REFERRED BY	:Dr. MEDIWHEEL	REPORT DATE	:11/May/2024 03:27PM
CENTRE NAME	:ONEPLUS ULTRASOUND LAB	LAB NO.	:012405110004

Test Name	Result	Unit	Ref. Range
-----------	--------	------	------------

### HAEMATOLOGY

#### BLOOD GROUP (ABO)

Forward and Reverse grouping (Slide & Tube)

AB

#### Rh typing

POSITIVE

#### NOTE :

- \* Apart from major A,B,H antigens which are used for ABO grouping and Rh typing, many minor blood group antigens exist. Agglutination may also vary according to titre of antigen and antibody.
- \* So before transfusion, reconfirmation of blood group as well as cross-matching is needed.
- \* Presence of maternal antibodies in newborns, may interfere with blood grouping.
- \* Auto agglutination (due to cold antibody, falciparum malaria, sepsis, internal malignancy etc.) may also cause erroneous result.

Checked By.

**Dr. NITIN AGARWAL**  
MBBS MD  
Regn. No. DMC-R-1436

**DR. NITIN AGARWAL**  
MBBS,MD(PATHOLOGIST)

47, Harsh Vihar, Pitampura, Delhi-34 ☎ 011-4248 0101, 9599913051

✉ Email: [oneplusul@gmail.com](mailto:oneplusul@gmail.com) 🌐 [www.oneplusul.in](http://www.oneplusul.in)

Page 2 of 9

- Clinical correlation is essential for final diagnosis. • If test results are unsatisfactory please contact personally or on phone.
- This report is for perusal of doctors only. • All disputes are subject to Delhi jurisdiction only. • Not for medico legal case.
- All congenital anomalies in a foetus may not be diagnosed in routine obstetric ultrasound.



NAME	:Mr. ANIL KUMAR GOYAL	Barcode No	:10171927
AGE/GENDER	:51 YRS/Male	SPECIMEN DATE	:11/May/2024 08:36AM
PATIENT ID	:135986	SPECIMEN RECEIVED	:11/May/2024 08:46AM
REFERRED BY	:Dr. MEDIWHEEL	REPORT DATE	:11/May/2024 03:27PM
CENTRE NAME	:ONEPLUS ULTRASOUND LAB	LAB NO.	:012405110004

Test Name	Result	Unit	Ref. Range
-----------	--------	------	------------

**HAEMATOLOGY**

**CBC**

Haemoglobin Non cyanide Hb analysis	12.8	g/dl	13.0-17.0
Total Leucocyte Count Electrical Impedance	9600	/cumm	4000-10000
<b>Differential leucocyte count</b>			
Neutrophils Electrical Impedance & Microscopic	55.5	%	40-80
Lymphocyte Electrical Impedance & Microscopic	37.40	%	20-40
Monocytes Electrical Impedance & Microscopic	5.00	%	2-10
Eosinophils Electrical Impedance & Microscopic	2.0	%	1-6
Basophils Electrical Impedance & Microscopic	0.1	%	0-2
RBC Count Electrical Impedance	4.10	million/cumm	4.5 - 5.5
Hematocrit(PCV) Flow Cytometry	40.1	%	40-50
MCV Calculated	97.6	fl	83-101
MCH Calculated	31.2	pg	27-32
MCHC Calculated	31.9	g/dL	31.5-34.5
RDW-CV Calculated	14.6	%	11.4-14.0
Platelet count Electrical Impedance	180000	/cumm	150000-410000

**BIOCHEMISTRY**

Sample Type:Fluoride F

<b>Blood sugar fasting</b> GOD-POD	96	mg/dl	70-100 mg/dl
---------------------------------------	----	-------	--------------

Checked By.

Dr. NITIN AGARWAL  
MBBS, MD  
Regn. No. DMC-R-1436

  
DR. NITIN AGARWAL  
MBBS,MD(PATHOLOGIST)

47, Harsh Vihar, Pitampura, Delhi-34 ☎ 011-4248 0101, 9599913051

✉ Email: oneplusul@gmail.com 🌐 www.oneplusul.in





NAME	:Mr. ANIL KUMAR GOYAL	Barcode No	:10171927
AGE/GENDER	:51 YRS/Male	SPECIMEN DATE	:11/May/2024 08:36AM
PATIENT ID	:135986	SPECIMEN RECEIVED	:11/May/2024 08:46AM
REFERRED BY	:Dr. MEDIWHEEL	REPORT DATE	:11/May/2024 03:27PM
CENTRE NAME	:ONEPLUS ULTRASOUND LAB	LAB NO.	:012405110004

Test Name	Result	Unit	Ref. Range
<b>Sample Type:Fluoride PP</b>			
<b>Blood sugar pp</b> GOD-POD	149	mg/dL	70.0-140.0
<b>Sample Type:Serum</b>			
<b>Bun (blood urea nitrogen )</b> Calculated	11.60	mg/dl	8.4-25.7
<b>Uric Acid, serum</b> Uricase- PAP	4.6	mg/dl	3.5-7.2
<b>Creatinine, serum</b> Enzymatic	0.7	mg/dl	0.71-1.16
<b>LFT(LIVER FUNCTION TEST)</b>			
Bilirubin Total Modified tab	0.56	mg/dl	0.1-1.2
Bilirubin Conjugated Diazotied sulfanilic acid	0.24	mg/dL	0.11-0.42
Bilirubin Unconjugated Calculated	0.32	mg/dl	up to 0.7
SGOT (AST) Tris buffer	11	U/L	0-46
SGPT (ALT) Tris buffer	29	U/L	0-49
Alkaline phosphatase Amp buffer	95	U/L	40-129
GAMMA GT Szasz Method	29	U/L	10-45
Total Protein Biuret	6.9	gm/dl	6.60 - 8.70
Albumin serum BCG	3.8	g/dL	3.0-5.2
Globulin Calculated	3.10	gm/dl	1.8-3.4
Albumin/Globulin Ratio Calculated	1.23		1.10 - 2.50
<b>LIPID PROFILE</b>			
Cholesterol CHOD-PAP	157	mg/dl	50-200

Checked By.

**Dr. NITIN AGARWAL**  
MBBS, MD  
Regn. No. DMC-1436

  
**DR. NITIN AGARWAL**  
MBBS,MD(PATHOLOGIST)

47, Harsh Vihar, Pitampura, Delhi-34 ☎ 011-4248 0101, 9599913051

✉ Email: oneplusul@gmail.com 🌐 www.oneplusul.in

Page 4 of 9

- Clinical correlation is essential for final diagnosis. • If test results are unsatisfactory please contact personally or on phone.
- This report is for perusal of doctors only. • All disputes are subject to Delhi jurisdiction only. • Not for medico legal case.
- All congenital anomalies in a foetus may not be diagnosed in routine obstetric ultrasound.



NAME	:Mr. ANIL KUMAR GOYAL	Barcode No	:10171927
AGE/GENDER	:51 YRS/Male	SPECIMEN DATE	:11/May/2024 08:36AM
PATIENT ID	:135986	SPECIMEN RECEIVED	:11/May/2024 08:46AM
REFERRED BY	:Dr. MEDIWHEEL	REPORT DATE	:11/May/2024 03:27PM
CENTRE NAME	:ONEPLUS ULTRASOUND LAB	LAB NO.	:012405110004

Test Name	Result	Unit	Ref. Range
Triglycerides GPO-PAP	159	mg/dL	25-150
HDL Cholesterol Selective Inhibition	48	mg/dL	40 - 60
LDL cholesterol Calculated	77	mg/dL	<100
VLDL cholesterol Calculated	31.8	mg/dL	5-40
Cholesterol/HDL Ratio Calculated	3.3		Low Risk 3.3-4.97 Average Risk 4.4-7.1 Moderate Risk 7.1-11.0 High Risk >11.0
LDL/HDL Ratio Calculated	1.6		0 - 3.55

LDL Cholesterol	Total Cholesterol	HDL Cholesterol
<100 Optimal	<200 Desirable	<40 Low
100-129 Near optimal	200-239 Borderline high	>60 High
130-159 Borderline high	>240 High	
160-189 High		
>190 Very high		

*According to NCEP, ATP-III Guidelines*

**BUN/Creatinine ratio**

UREA UREASE-GLDH	25.00	mg/dl	15-45.
Bun (blood urea nitrogen ) Calculated	11.68	mg/dl	8.4-25.7
CREATININE ENZYMATIC	0.70	mg/dl	0.30-1.10
Bun/Creatinine Ratio Calculated	16.69		10.0 - 20.0

Checked By.

**Dr. NITIN AGARWAL**  
MBBS, MD  
Regn. No. DMC K 1436

  
**DR. NITIN AGARWAL**  
MBBS,MD(PATHOLOGIST)

47, Harsh Vihar, Pitampura, Delhi-34 ☎ 011-4248 0101, 9599913051

✉ Email: [oneplusul@gmail.com](mailto:oneplusul@gmail.com) 🌐 [www.oneplusul.in](http://www.oneplusul.in)

Page 5 of 9



**OnePLUS**  
Ultrasound Lab

— QUALITY FIRST... ALWAYS! —

**Dr. Nitin Agarwal**

Pathologist & Director  
MBBS, MD, FAGE  
Ex. Chief of Lab  
Dr. Lal Path labs.

**Dr. Pooja (Garg) Agarwal**

Radiologist & Director  
MBBS (MAMC) DMRD (MAMC)  
Imaging Expert In Fetal And Maternal Medicine,  
University of Barcelona, Spain  
Fetal Medicine Foundation (UK) Accreditation



ITDOSE INFOSYSTEMS PVT. LTD.

NAME	:Mr. ANIL KUMAR GOYAL	Barcode No	:10171927
AGE/GENDER	:51 YRS/Male	SPECIMEN DATE	:11/May/2024 08:36AM
PATIENT ID	:135986	SPECIMEN RECEIVED	:11/May/2024 08:46AM
REFERRED BY	:Dr. MEDIWHEEL	REPORT DATE	:11/May/2024 03:27PM
CENTRE NAME	:ONEPLUS ULTRASOUND LAB	LAB NO.	:012405110004

Test Name	Result	Unit	Ref. Range
-----------	--------	------	------------

**ENDOCRINOLOGY**

**PSA TOTAL**

Prostatic specific antigen, Total 0.37 ng/ml <4.0

< 40 years	0.21 to 1.72 ng/ml
40 - 49	0.27 to 2.19 ng/ml
50 - 59	0.27 to 3.42 ng/ml
60 - 69	0.22 to 6.16 ng/ml
> 69	0.21 to 6.77 ng/ml

**Notes:**

PSA is principally produced by the glandular epithelium of the prostate, and is secreted in the seminal fluid. PSA is also present in urine and blood. PSA acts on seminal fluid to fluidify and increase sperm mobility. PSA levels rise in prostatic pathologies such as benign prostatic hyperplasia (BPH) or prostate cancer.

**THYROID PROFILE(T3,T4,TSH)**

<b>Triiodothyronine total [t3]</b> ECLIA	0.68	ng/dl	0.52-1.9
<b>Thyroxine total [t4]</b> ECLIA	7.50	µg/dl	4.4 - 10.8
<b>TSH (Thyroid Stimulating Hormone)</b> Enzyme linked fluorescent assay	3.70	µIU/ml	0.25-5.0

**AGE WISE VARIATION IN TSH**

AGE	TSH(µIU/ml)	AGE	TSH(µIU/ml)
1-4 weeks	1.00 - 19.0	16-20 yrs	0.25 - 5.0
1-12 mths	1.70 - 9.1	21 - 80 yrs	0.25 - 5.0
1-5 yrs	0.80 - 8.2	I <sup>st</sup> trimester	0.25 - 5.0
6-10 yrs	0.25 - 5.0	II <sup>nd</sup> trimester	0.50 - 5.0
11-15 yrs	0.25 - 5.0	III <sup>rd</sup> trimester	0.4 - 6.0

Reference ranges - Interpretation of Diagnostic tests - (Jacques Wallach)

Checked By.

**Dr. NITIN AGARWAL**  
MBBS, MD  
Regn. No. DMC-R-1436

**DR. NITIN AGARWAL**  
MBBS,MD(PATHOLOGIST)

47, Harsh Vihar, Pitampura, Delhi-34 ☎ 011-4248 0101, 9599913051

✉ Email: oneplusul@gmail.com 🌐 www.oneplusul.in

Page 6 of 9

- Clinical correlation is essential for final diagnosis. • If test results are unsatisfactory please contact personally or on phone.
- This report is for perusal of doctors only. • All disputes are subject to Delhi jurisdiction only. • Not for medico legal case.
- All congenital anomalies in a foetus may not be diagnosed in routine obstetric ultrasound.



# OnePLUS Ultrasound Lab

— QUALITY FIRST... ALWAYS! —

**Dr. Nitin Agarwal**

Pathologist & Director  
MBBS, MD, FAGE  
Ex. Chief of Lab  
Dr. Lal Path labs.

**Dr. Pooja (Garg) Agarwal**

Radiologist & Director  
MBBS (MAMC) DMRD (MAMC)  
Imaging Expert In Fetal And Maternal Medicine,  
University of Barcelona, Spain  
Fetal Medicine Foundation (UK) Accreditation



NAME	:Mr. ANIL KUMAR GOYAL	Barcode No	:10171927
AGE/GENDER	:51 YRS/Male	SPECIMEN DATE	:11/May/2024 08:36AM
PATIENT ID	:135986	SPECIMEN RECEIVED	:11/May/2024 08:46AM
REFERRED BY	:Dr. MEDIWHEEL	REPORT DATE	:11/May/2024 03:27PM
CENTRE NAME	:ONEPLUS ULTRASOUND LAB	LAB NO.	:012405110004

Test Name	Result	Unit	Ref. Range
1. Primary hypothyroidism is accompanied by depressed serum T3 and T4 values and elevated serum TSH level.			
2. Primary hyperthyroidism is accompanied by elevated serum T3 and T4 levels along with depressed TSH values.			
3. Slightly elevated T3 levels may be found in pregnancy and estrogen therapy, while depressed levels may be encountered in severe illness, renal failure and during therapy with drugs like propranolol and propyl thiouracil.			
4. Although elevated TSH levels are nearly always indicative of primary hypothyroidism, and may be seen in secondary thyrotoxicosis			

Checked By.

Dr. NITIN AGARWAL  
MBBS, MD  
Regn. No. DMC-R-1436

DR. NITIN AGARWAL  
MBBS, MD (PATHOLOGIST)

47, Harsh Vihar, Pitampura, Delhi-34 ☎ 011-4248 0101, 9599913051

✉ Email: [oneplusul@gmail.com](mailto:oneplusul@gmail.com) 🌐 [www.oneplusul.in](http://www.oneplusul.in)

Page 7 of 9

- Clinical correlation is essential for final diagnosis. • If test results are unsatisfactory please contact personally or on phone.
- This report is for perusal of doctors only. • All disputes are subject to Delhi jurisdiction only. • Not for medico legal case.
- All congenital anomalies in a foetus may not be diagnosed in routine obstetric ultrasound.



NAME	:Mr. ANIL KUMAR GOYAL	Barcode No	:10171927
AGE/GENDER	:51 YRS/Male	SPECIMEN DATE	:11/May/2024 08:36AM
PATIENT ID	:135986	SPECIMEN RECEIVED	:11/May/2024 12:23PM
REFERRED BY	:Dr. MEDIWHEEL	REPORT DATE	:11/May/2024 03:27PM
CENTRE NAME	:ONEPLUS ULTRASOUND LAB	LAB NO.	:012405110004

Test Name	Result	Unit	Ref. Range
-----------	--------	------	------------

**CLINICAL PATHOLOGY**

**URINE ROUTINE (Strip/microscopy)**

Sample Type:Urine

**Physical examination**

Colour	PALE YELLOW	PALE YELLOW
Transparency	CLEAR	CLEAR
Sp.gravity BROMOTHYMOL BLUE	1.020	1.005-1.030
pH Double Indicators Test	6.00	5.0-8.0
Reaction	ACIDIC	ACIDIC

**Chemical examination**

Urine protein Protein Ionization	NIL	NIL
Urine sugar Oxidation Reaction	NIL	NIL
Bilirubin, urine	NEGATIVE	NEGATIVE
Urobilinogen P-Aminobenzoic Acid and Phenazopyridine Reaction	NORMAL	NORMAL
Ketones Acetoacetate and Dichlorobenzene Reaction	NEGATIVE	NEGATIVE

**Microscopic examination**

<b>Pus cells.</b> Microscopy	1-2	/HPF	0-2
<b>Epithelial cells</b> Microscopy	1-2	/HPF	NIL
<b>R.B.C.</b> Microscopy	NIL	/HPF	NIL
<b>Casts</b> Microscopy	NIL	/HPF	NIL
<b>Crystals</b> Microscopy	NIL	/HPF	NIL
<b>Bacteria</b> Microscopy	NIL	/HPF	NIL

Checked By.

Dr. NITIN AGARWAL  
MBBS, MD  
Regn. No. DMC-R-1436

  
DR. NITIN AGARWAL  
MBBS,MD(PATHOLOGIST)

47, Harsh Vihar, Pitampura, Delhi-34 ☎ 011-4248 0101, 9599913051

✉ Email: oneplusul@gmail.com 🌐 www.oneplusul.in



NAME	:Mr. ANIL KUMAR GOYAL	Barcode No	:10171927
AGE/GENDER	:51 YRS/Male	SPECIMEN DATE	:11/May/2024 08:36AM
PATIENT ID	:135986	SPECIMEN RECEIVED	:11/May/2024 12:23PM
REFERRED BY	:Dr. MEDIWHEEL	REPORT DATE	:11/May/2024 03:27PM
CENTRE NAME	:ONEPLUS ULTRASOUND LAB	LAB NO.	:012405110004

Test Name	Result	Unit	Ref. Range
Others.	NIL	NIL	NIL

**STOOL ROUTINE(MANUAL METHOD/MICROSCOPY)**

Sample Type:Stool

Physical examination

Colour	BROWNISH		
Consistency	SEMI LOOSE		Semi Formed
Blood	ABSENT		Absent
Mucus	ABSENT		Absent

Chemical examination, stool

pH Double Indicators Test	6.50		5.0-8.0
------------------------------	------	--	---------

Microscopic examination

Pus cells Microscopy	0-1	/HPF	
R.B.C. Microscopy	NIL	/HPF	NIL
Ova Microscopy	NIL		NIL
Cysts Microscopy	NIL		NIL
Bacteria Microscopy	PRESENT	/HPF	NIL
Others	NIL		

\*\*\* End Of Report \*\*\*

Checked By.

**Dr. NITIN AGARWAL**  
MBBS, MD  
Regn. No. DMC 6036



**DR. NITIN AGARWAL**  
MBBS,MD(PATHOLOGIST)

47, Harsh Vihar, Pitampura, Delhi-34 ☎ 011-4248 0101, 9599913051

✉ Email: [oneplusul@gmail.com](mailto:oneplusul@gmail.com) 🌐 [www.oneplusul.in](http://www.oneplusul.in)



**OnePLUS**  
Ultrasound Lab  
— QUALITY FIRST... ALWAYS! —

**Dr. Nitin Agarwal**

Pathologist & Director  
MBBS, MD, FAGE  
Ex. Chief of Lab  
Dr. Lal Path labs.

**Dr. Pooja (Garg) Agarwal**

Radiologist & Director  
MBBS (MAMC) DMRD (MAMC)  
Imaging Expert In Fetal And Maternal Medicine  
University of Barcelona, Spain  
Fetal Medicine Foundation (UK) Accreditation

<b>Name</b>	: Mr. ANIL KUMAR GOYAL	<b>Age/Sex</b>	: 51 YRS/Male
<b>Ref. By</b>	: Dr. MEDIWHEEL	<b>Lab No</b>	: 012405110004
<b>Date</b>	: 11-May-2024	<b>Patient ID</b>	: LSHHI135986

### ULTRASOUND EXAMINATION---WHOLE ABDOMEN

**Liver** is enlarged in size (15.9 cm) and normal in outline with altered echopattern. Diffuse increase in echogenicity of liver parenchyma is noted, suggestive of fatty infiltration (grade II). No abscess or mass lesion seen. Hepatic veins, portal vein, IVC and aorta are normal. Intrahepatic biliary radicles are not dilated. CBD is normal in caliber.

**Gall bladder** is well distended with anechoic lumen. Wall thickness is normal.

**Both kidneys** are normal in size, shape, position, outline and echopattern. Corticomedullary differentiation is maintained. No pelvicalyceal dilation or calculus or mass lesion is seen.

**Spleen** is normal in size and echotexture. No mass lesion seen.

**Pancreas** is normal in size, outline and echotexture.

**Urinary bladder** is normal in shape and position. No evidence of intravesical stone or mass seen.

**Prostate** is normal in size, shape and echopattern.

**Prostate measures** 4.3 x 3.0 x 2.9 cm. **Weight of prostate is 20 grams.**

No abnormal bowel wall thickening seen in right iliac fossa.

No free fluid seen anywhere in abdomen.

**IMPRESSION: Fatty infiltration of liver (grade II) with hepatomegaly.**



**DR. POOJA GARG**  
**RADIOLOGIST**  
**REG NO- DMC/R/03398**

**Dr. POOJA GARG**  
**M.B.B.S., D.M.R.D.**  
**Reg No DMC/R/03398**  
**Radiologist**

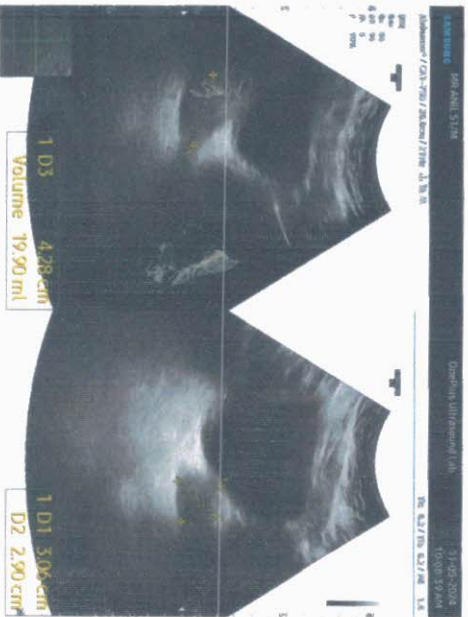
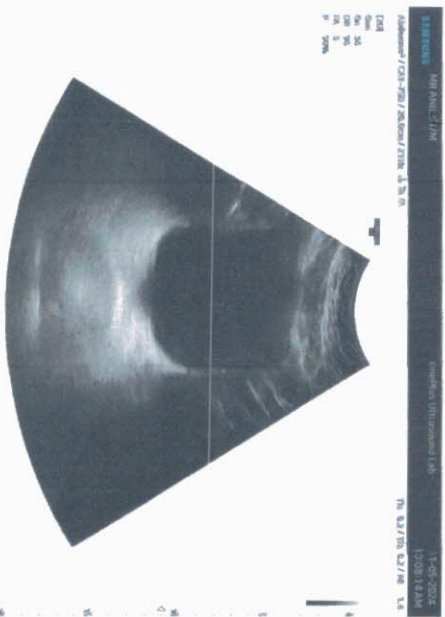
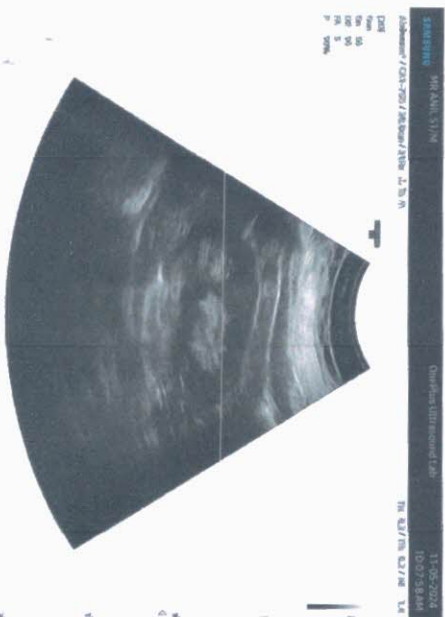
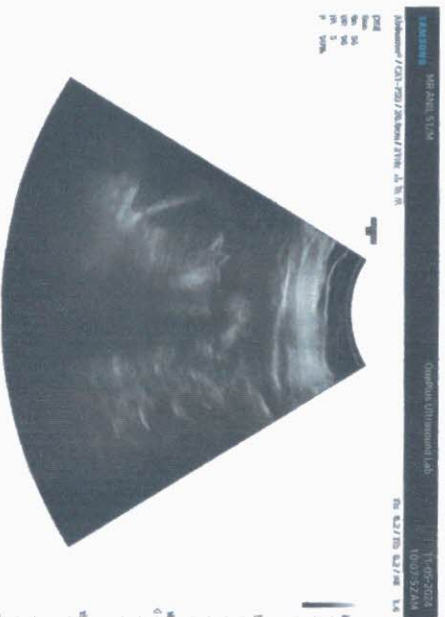
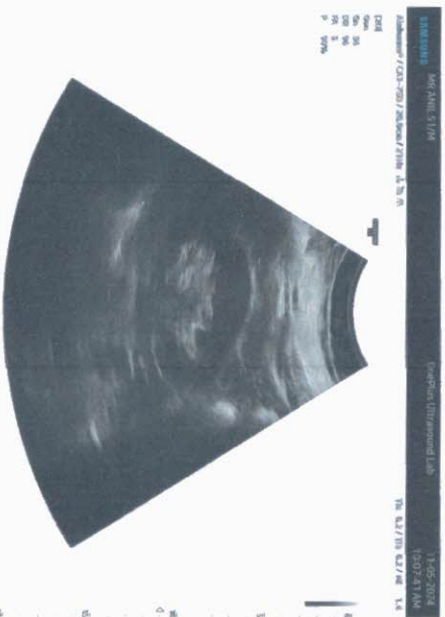
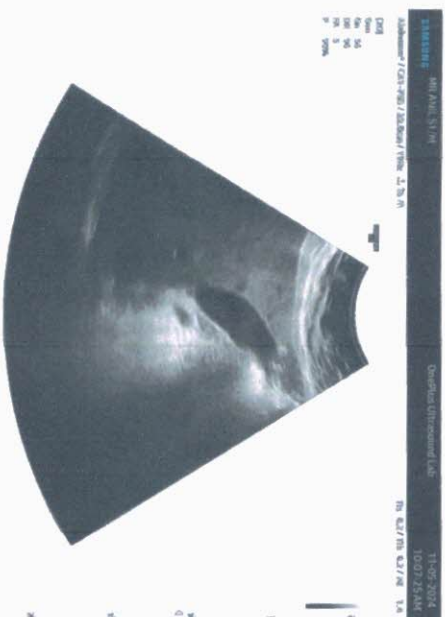
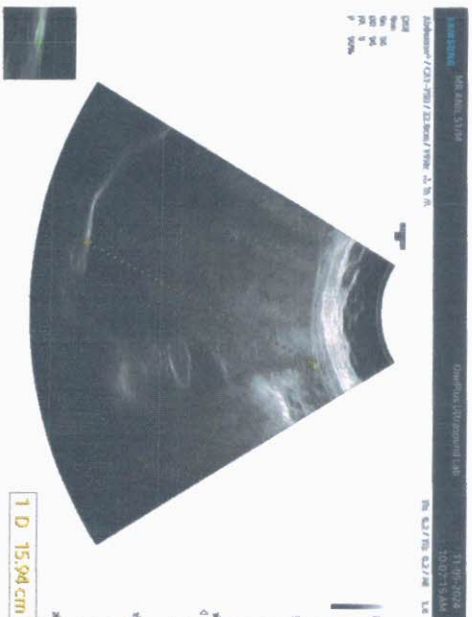
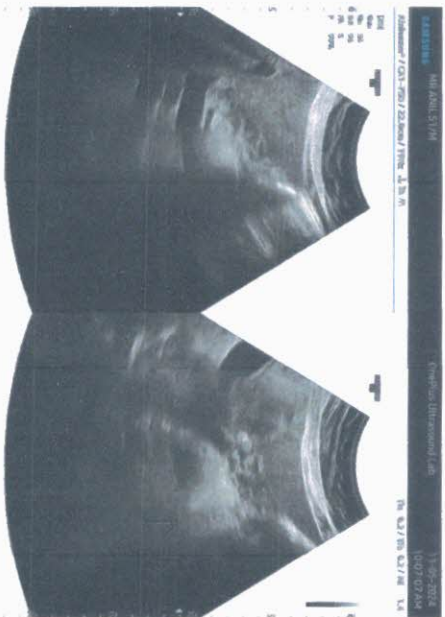
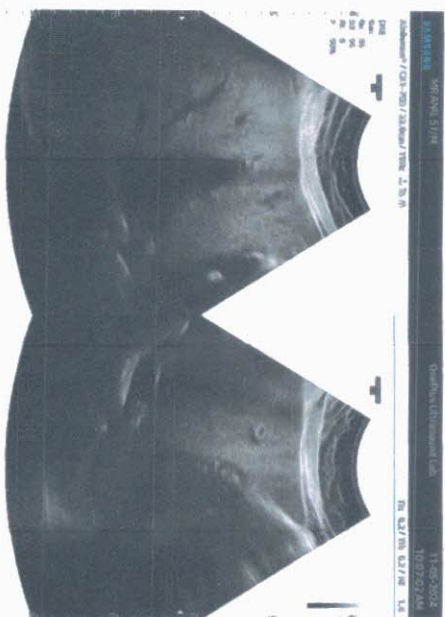
47, Harsh Vihar, Pitampura, Delhi-34 ☎ 011-4248 0101, 9599913051

✉ Email: [oneplusul@gmail.com](mailto:oneplusul@gmail.com) 🌐 [www.oneplusul.in](http://www.oneplusul.in)

- Clinical correlation is essential for final diagnosis. • If test results are unsatisfactory please contact personally or on phone.
- This report is for perusal of doctors only. • All disputes are subject to Delhi jurisdiction only. • Not for medico legal case.
- All congenital anomalies in a foetus may not be diagnosed in routine obstetric ultrasound.









**OnePLUS**  
Ultrasound Lab  
— QUALITY FIRST... ALWAYS! —

**Dr. Nitin Agarwal**

Pathologist & Director  
MBBS, MD, FAGE  
Ex. Chief of Lab  
Dr. Lal Path labs.

**Dr. Pooja (Garg) Agarwal**

Radiologist & Director  
MBBS (MAMC) DMRD (MAMC)  
Imaging Expert In Fetal And Maternal Medicine  
University of Barcelona, Spain  
Fetal Medicine Foundation (UK) Accreditation

Name	: Mr. ANIL KUMAR GOYAL	Age/Sex	: 51 YRS/Male
Ref. By	: Dr. MEDIWHEEL	Lab No	: 012405110004
Date	: 11-May-2024	Patient ID	: LSHHI135986

### X-ray-Chest PA view

Bony cage and soft tissues are normal.

Cardiothoracic ratio is normal.

Mediastinum is normal.


Both hila are normal.

Both costophrenic angles are clear.

Both domes of diaphragm are normal.

Lung fields are clear. No parenchymal lesion seen.

**IMPRESSION: Normal Study.**

  
**DR. POOJA GARG**  
RADIOLOGIST  
REG NO- DMC/R/03398

**Dr. POOJA GARG**  
M.B.B.S., D.M.R.D  
Reg No DMC/R/03398  
Radiologist

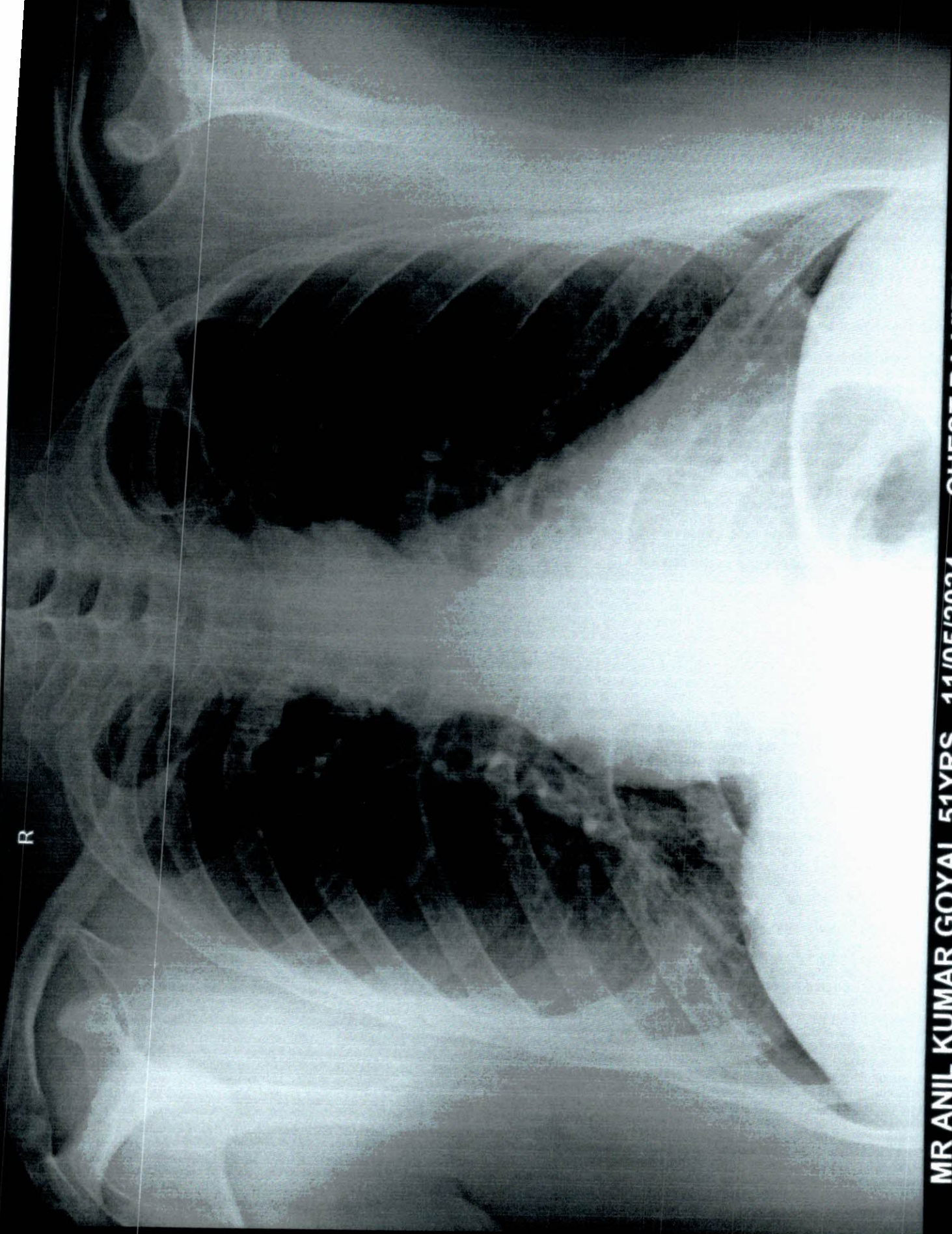
Type By : darshita

47, Harsh Vihar, Pitampura, Delhi-34 ☎ 011-4248 0101, 9599913051

✉ Email: [oneplusul@gmail.com](mailto:oneplusul@gmail.com) 🌐 [www.oneplusul.in](http://www.oneplusul.in)

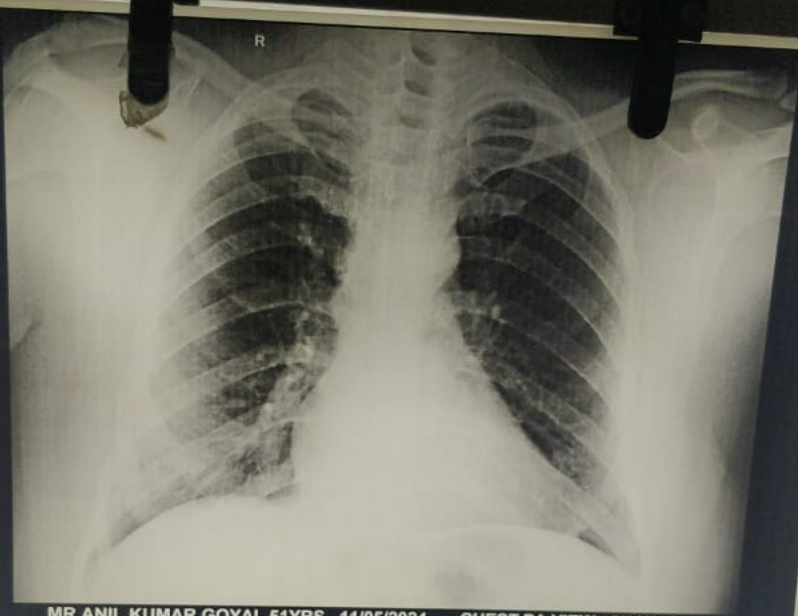
- Clinical correlation is essential for final diagnosis. • If test results are unsatisfactory please contact personally or on phone.
- This report is for perusal of doctors only. • All disputes are subject to Delhi jurisdiction only. • Not for medico legal case.
- All congenital anomalies in a foetus may not be diagnosed in routine obstetric ultrasound.

R



MR ANIL KUMAR GOYAL 51YRS 11/05/2024 CHEST PA VIEW 5/11/2024  
ONERI US III TRA COUN

R



MR ANIL KUMAR GOYAL 51YRS 11/05/2024 CHEST PA VIEW 5/11/2024  
ONEPLUS ULTRASOUND LAB, 47-HARSH VIHAR, PITAMPURA