



Medicover Hospitals

VENKOJIPALAM VISAKHAPATNAM - 530017
ANDHRA PRADESH - INDIA
PHONE NO : 0891-6829999

**Dr. RAKESH P
MD
GENERAL PHYSICIAN**

NAME : David Ralu Gmm AGE 44yrs 10m ✓

WT: 81 kg's
HT: 167 cms
BP: 129/82
PR 72.1

NO REMARK





Medicover Hospitals

VENKOJIPALAM VISKHAPATNAM -530017

ANDHRA PRADESH -INDIA

PHONO NO : 0891-6829999

OPHTHALMOLOGIST CONSULTATION

NAME: David Ratu Omma AGE: 44/med

DATE: 12/6/24

ARER +0.50 +0.50 X 169°
+0.25 +0.25 X 5°

H10 No,

SVCR 612 +0.50 +0.50 X 170° 66
66 +0.25 SPH

PGPR +0.50 +0.50 X 170°
+0.25 SPH
NV +1.25 SR 1

NV +1.50 SPH 1/2

Sp: hypermet

low power / m

Ar
Sur

(B/E) LUBREX eye
drop



Medicover Hospitals
VENKOJIPALAM VISAKHAPATNAM - 530017
ANDHRA PRADESH - INDIA



MEDICOVER
HOSPITALS

A UNIT OF SAHRUDAYA HEALTHCARE PVT LTD.

Lab Report

Patient Name : **Mr. DAVID RAJU OMMI** Age /Gender : **44 Y(s)/Male**
Bill No/ UMR No : **V4BC243377/V4U190932** Referred By : **Dr. CMO**
Received Dt : **12-Jun-24 08:16 am** Report Date : **12-Jun-24 09:10 am**
Lab No : **120000647638**

| <u>Parameter</u> | <u>Result Values</u> | <u>Biological Reference</u> |
|----------------------------------|----------------------|------------------------------------|
| CBC(COMPLETE BLOOD COUNT) | | |
| RBC | | |
| HAEMOGLOBIN | * 12.4 | 13.0 - 17.0 g/dl |
| R B C COUNT | * 4.0 | 4.5 - 5.5 10⁶/μL |
| PCV/HCT | * 36 | 40 - 50 % |
| MCV | 89 | 83 - 101 fl |
| MCH | 31 | 27 - 32 pg |
| MCHC | 34 | 31.5 - 34.5 g/dL |
| RDW(cv) | * 14.7 | 11.6 - 14.0 % |
| WBC | | |
| TC (TOTAL LEUCOCYTE COUNT) | 6000 | 4000 - 11000 cells/cumm |
| DIFFERENTIAL COUNT | | |
| NEUTROPHILS | 54 | 40 - 80 % |
| LYMPHOCYTES | 37 | 20 - 40 % |
| MONOCYTES | 05 | 02 - 10 % |
| EOSINOPHILS | 04 | 00 - 06 % |
| BASOPHILS | 00 | 00 - 01 % |
| PLATELET COUNT | | |
| PLATELET COUNT | 2.20 | 1.50 - 4.50 Lakhs/cumm |
| BLOOD GROUPING AND RH | | |
| BLOOD GROUP | " O " | |
| RH TYPE | POSITIVE | |
| ESR | 15 | 0 - 10 mm/1st hour |

*** End Of Report ***

Doctor Incharge

Dr.MUDUGANTI SRINIVAS
MBBS, MD
CONSULTANT PATHOLOGIST

Dr.SRUJANA
MBBS, MD PATHOLOGY
CONSULTANT PATHOLOGIST

Dr.MOHAMMAD SIMI IQBAL
M.B.B.S, M.D
CONSULTANT BIOCHEMIST

Medicover Unit - I
18-1-3, KGH Down, Maharani-peta,
Jagadamba Junction, Visakhapatnam,
Andhrapradesh - 530 002.
Ph: +91 96526 69351

Medicover Unit - III
Sry. No. 27, Plot No. 05, BRTS Road,
Health City, Arilova, Chinnagadili Mandal,
Visakhapatnam, Andhrapradesh - 530 040.
Ph: +91 0891-6677888

Medicover - MVP
1-1-83, Sector-6, Venkojipalem,
MVP Colony, Visakhapatnam,
Andhrapradesh-530017.
Ph: +91 8886655677



Lab Report

| | |
|-----------------------------------------------|-----------------------------------------|
| Patient Name : Mr. DAVID RAJU OMMI | Age /Gender : 44 Y(s)/Male |
| Bill No/ UMR No : V4BC243377/V4U190932 | Referred By : Dr. CMO |
| Received Dt : 12-Jun-24 08:16 am | Report Date : 12-Jun-24 10:13 am |
| Lab No : 120000647639 | |

Parameters

| | Result | Biological Reference Intervals |
|------------------------------------|---------------|---------------------------------------------------------------------------------------------------|
| LIPID PROFILE | | |
| TOTAL CHOLESTEROL | 188 | No risk : < 200 mg/dL Moderate risk : 200 - 239 High risk : > 240 |
| HDL CHOLESTEROL | 37 | <40 Low >60 High |
| LDL CHOLESTEROL | * 132 | Border line : 100 - 130 mg/dL High : > 130 mg/dL Desirable : < 100 mg/dL 100 - 130 mg/dL |
| VLDL | 18 | |
| SERUM TRYGLYCERIDES | 90 | Very High : > 500 mg/dL High : >= 200 - 499 mg/dL Border line High : >= 150 - 199 mg/dL |
| CHO/HDL RATIO | 5.08 | Normal : < 150 mg/dL Normal : < 4.0 Low risk : 4.0 - 6.0 High risk : > 6.0 |
| LDL/HDL RATIO | 3.57 | |
| FBS (FASTING BLOOD GLUCOSE) | | |
| FASTING BLOOD GLUCOSE | 98 | Normal : 70-99 mg/dL Impaired : 100-125 mg/dL Diabetic : >= 126 mg/dL |
| CREATININE | 1.0 | 0.9 - 1.3 mg/dL |
| GAMMA GT | | |
| GAMMA GLUTAMYL TRANSFERASE(GGT) | 67 | 10 - 71 U/L |
| LFT(LIVER FUNCTION TEST) | | |
| TOTAL BILIRUBIN | 0.5 | < 1.2 mg/dL |
| DIRECT BILIRUBIN | 0.2 | <= 0.20 mg/dL |
| INDIRECT BILIRUBIN | 0.3 | <= 1.0 mg/dL |
| SGPT (ALT) | 36 | <= 41 U/L |
| SGOT (AST) | 25 | <= 40 U/L |
| ALKALINE PHOSPHATASE (ALP) | 56 | 40 - 129 U/L |
| TOTAL PROTEINS | 6.2 | 1-2 years : 5.6-7.5 g/dL > 3 years : 6.0-8.0 g/dL Adults : 6.4-8.3 g/dL |



Lab Report

| | |
|-----------------------------------------------|-----------------------------------------|
| Patient Name : Mr. DAVID RAJU OMMI | Age /Gender : 44 Y(s)/Male |
| Bill No/ UMR No : V4BC243377/V4U190932 | Referred By : Dr. CMO |
| Received Dt : 12-Jun-24 08:16 am | Report Date : 12-Jun-24 10:13 am |
| Lab No : 120000647639 | |

Parameters

SERUM ALBUMIN

Result

3.9

Biological Reference In Method

NewBorn: 0-4 days : 2.8 - 4.4 g/dL

Children: 4 days - 14 years : 3.8 - 5.4 g/dL

14-18 years : 3.2

- 4.5 g/dL

Adults : 3.5- 5.2 g/dL

GLOBULINS

A/G RATIO

* 2.3

2.5 - 3.5 g/dL

BUN(BLOOD UREA NITROGEN)

1.7

1.2 - 2.5

BUN(BLOOD UREA NITROGEN)

10

7.0 - 21.0 mg/dL

12

T3,T4 AND TSH

T3

1.10

0.8 - 2.0 ng/mL

T4

6.66

5.1 - 14.1 ug/dL

TSH(THYROID STIMULATING HORMONE)

2.21

0.270 - 4.20 uIU/mL

PSA (PROSTATE SPECIFIC ANTIGEN).

PROSTATE SPECIFIC ANTIGEN TOTAL (TPSA)

0.509

0.21 - 6.77 ng/mL

HBA1C (GLYCOSYLATED HAEMOGLOBIN)

HBA1C

* 5.7

Non -Diabetic : <= 5.6 %

Pre Diabetic : 5.7 - 6.4 %

Diabetic : >= 6.5 % %

PLBS (POST LUNCH BLOOD GLUCOSE)

PLBS (POST LUNCH BLOOD GLUCOSE)

124

Normal : 70- 139 mg/dL

Impaired : 140 - 199 mg/dL

Diabetic : >= 200 mg/dL


*** End Of Report ***

Suggested Clinical Correlation * If necessary, Please discuss

Verified By : : MC0954

Test results related only to the Item tested.

No part of the report can be reproduced without written permission of the laboratory.



Dr. MOHAMMAD SIMI IQBAL, M.B.B.S, M.D

Dr.MUDUGANTI SRINIVAS
MBBS, MD
CONSULTANT PATHOLOGIST

Dr.SRUJANA
MBBS, MD PATHOLOGY
CONSULTANT PATHOLOGIST

Dr.MOHAMMAD SIMI IQBAL
M.B.B.S, M.D
CONSULTANT BIOCHEMIST



Medicover Hospitals
VENKOJIPALAM VISAKHAPATNAM - 530017
ANDHRA PRADESH - INDIA



Lab Report

| | | | |
|-----------------|------------------------|-------------|----------------------|
| Patient Name | : Mr. DAVID RAJU OMMI | Age /Gender | : 44 Y(s)/Male |
| Bill No/ UMR No | : V4BC243377/V4U190932 | Referred By | : Dr. CMO |
| Received Dt | : 12-Jun-24 08:16 am | Report Date | : 12-Jun-24 10:53 am |
| Lab No | : 240601725 | | |

| <u>Parameter</u> | <u>Result Values</u> | <u>Biological Reference</u> |
|--------------------------------|----------------------|-----------------------------|
| URINE ROUTINE | | |
| <u>CHEMICAL EXAMINATION</u> | | |
| ALBUMIN | NIL | Negative |
| SUGAR | NIL | Negative |
| BLOOD | NIL | Absent |
| <u>MICROSCOPIC EXAMINATION</u> | | |
| PUS CELLS | 2-4 | /HPF |
| RBC | NIL | /HPF |
| EPITHELIAL CELLS | 1-2 | /HPF |
| CRYSTALS | NIL | |
| CASTS | NIL | |
| OTHERS | NIL | |

*** End Of Report ***

Doctor Incharge

Dr.MUDUGANTI SRINIVAS
MBBS, MD
CONSULTANT PATHOLOGIST

Dr.SRUJANA
MBBS, MD PATHOLOGY
CONSULTANT PATHOLOGIST

Dr.MOHAMMAD SIMI IQBAL
M.B.B.S, M.D
CONSULTANT BIOCHEMIST

Medicover Unit - I
18-1-3, KGH Down, Maharani-peta,
Jagadamba Junction, Visakhapatnam,
Andhrapradesh - 530 002.
Ph: +91 96526 69351

Medicover Unit - III
Sry. No. 27, Plot No. 05, BRTS Road,
Health City, Arilova, Chinnagadili Mandal,
Visakhapatnam, Andhrapradesh - 530 040.
Page 1 of 4
Ph: +91 0891-6677888

Medicover - MVP
1-1-83, Sector-6, Venkojipalem,
MVP Colony, Visakhapatnam,
Andhrapradesh-530017.
Ph: +91 8886655677



Medicover Hospitals

VENKOJIPALAM VISAKHAPATNAM - 530017
ANDHRA PRADESH - INDIA



MEDICOVER HOSPITALS

A UNIT OF SAHRUDAYA HEALTHCARE PVT LTD.

DEPARTMENT OF RADIOLOGY

| | |
|-----------------------------------------------|-----------------------------------------|
| Patient Name : Mr. DAVID RAJU OMMI | Age / Gender : 44 Y(s)/Male |
| Bill No/ UMR No : V4BC243377/V4U190932 | Referred By : Dr. CMO |
| Received Dt : 12-Jun-24 08:03 am | Report Date : 12-Jun-24 10:24 am |

USG ABDOMEN (MALE)

LIVER

Measuring 13.4 cm. Normal in size with increased echotexture.
There is no evidence of IHBR/EHBR dilatation seen.
The portal, hepatic vessels are normal. No S.O.L. noted.

GALL BLADDER

Normal in volume and wall thickness.
Polyp of size 3 mm noted in the lumen of gallbladder.
Common bile duct appears normal.

PANCREAS

Head, Body & Tail are identified with normal echopattern & smooth outlines. The pancreatic duct system appears normal. The peri pancreatic fat planes are well preserved.

SPLEEN

Measuring 9.2 cm in cranio caudal directions with normal homogenous echotexture.

RIGHT KIDNEY

Measuring 8.4 cm. Normal in location, size with echopattern
Cortico Medullary differentiation is normal
No evidence of mass / calculi / hydroureteronephrosis seen.

LEFT KIDNEY

Measuring 9.6 cm. Normal in location, size, echopattern.
Cortico Medullary differentiation is normal
No evidence of mass / calculi / hydroureteronephrosis seen.
No evidence of suprarenal / retroperitoneal mass noted.

URINARY BLADDER

Normal in volume and wall thickness.
No intraluminal mass / calculi noted.

PROSTATE

Measuring 12 cc. Normal in size and echopattern.

No evidence of ascites/ pleural effusion seen.
No detectable bowel pathology seen.

IMPRESSION

* **Grade I fatty changes of liver.**

* Small gallbladder

Medicover Unit - I

18-1-3, KGH Down, Maharani-peta,
Jagadamba Junction, Visakhapatnam,
Andhrapradesh - 530 002.
Ph: +91 96526 69351

Medicover Unit - III

Sry. No. 27, Plot No. 05, BRTS Road,
Health City, Arilova, Chinagudim Mandal,
Visakhapatnam, Andhrapradesh - 530 040.
Ph: +91 0891-6677888

Medicover - MVP

1-1-83, Sector-6, Venkojipalem,
MVP Colony, Visakhapatnam,
Andhrapradesh-530017.
Ph: +91 8886655677



Medicover Hospitals

VENKOJIPALAM VISAKHAPATNAM - 530017
ANDHRA PRADESH - INDIA



MEDICOVER HOSPITALS

A UNIT OF SAHRUDAYA HEALTHCARE PVT LTD.

DEPARTMENT OF RADIOLOGY

| | |
|-----------------------------------------------|-----------------------------------------|
| Patient Name : Mr. DAVID RAJU OMMI | Age / Gender : 44 Y(s)/Male |
| Bill No/ UMR No : V4BC243377/V4U190932 | Referred By : Dr. CMO |
| Received Dt : 12-Jun-24 08:03 am | Report Date : 12-Jun-24 10:24 am |

* Small gallbladder polyp.

*** End Of Report ***

Dr. VENKATA SUMAN KUNA, MBBS , M.D,
PDCC(MSK)
CONSULTANT RADIOLOGIST

1. This report is not valid for medico-legal purpose.

2. In case of any discrepancy due to machine error or typing error, please get it rectified immediately.

Medicover Unit - I
18-1-3, KGH Down, Maharanipeta,
Jagadamba Junction, Visakhapatnam,
Andhrapradesh - 530 002.
Ph: +91 96526 69351

Medicover Unit - III
Sry. No. 27, Plot No. 05, BRTS Road,
Health City, Arilova, Ponnampeta Mandal,
Visakhapatnam, Andhrapradesh - 530 040.
Ph: +91 0891-6677888

Medicover - MVP
1-1-83, Sector-6, Venkojipalem,
MVP Colony, Visakhapatnam,
Andhrapradesh-530017.
Ph: +91 8886655677



Medicover Hospitals

VENKOJIPALAM VISAKHAPATNAM - 530017
ANDHRA PRADESH - INDIA



MEDICOVER HOSPITALS

A UNIT OF SAHRUDAYA HEALTHCARE PVT LTD.

DEPARTMENT OF RADIOLOGY

| | |
|-----------------------------------------------|-----------------------------------------|
| Patient Name : Mr. DAVID RAJU OMMI | Age /Gender : 44 Y(s)/Male |
| Bill No/ UMR No : V4BC243377/V4U190932 | Referred By : Dr. CMO |
| Received Dt : 12-Jun-24 08:03 am | Report Date : 12-Jun-24 11:27 am |

X-RAY CHEST PA VIEW

FINDINGS

The cardiac size & configuration appear normal.

The Aorta and pulmonary vasculature appear normal.

There is no evidence of mediastinal widening.

Both the lungs and CP angles are clear.

The soft tissues and the bones of the rib cage displayed no abnormality.

IMPRESSION

*** Normal study.**

*** End Of Report ***

Dr. VULAPU CHENNAKRISHNA RAO, .
MBBS, DNB
CONSULTANT RADIOLOGIST

Summary Report

PATIENT ID : 190932
PATIENT NAME : MR DAVID RAJU OMMI 44/M

Report time : 10:46 am
June 12, 2024 10:46 am

PROTOCOL : BRUCE
PATIENT HEIGHT : 167 Cm
PATIENT ADD. :
PATIENT WEIGHT : 81.00 Kg

Ref. By : DR RAKESH P
(MD)

OBJECT OF TEST :
RISK FACTOR :
ACTIVITY :
MEDICATION :
BRIEF HISTORY :
OTHER INVESTIGATION :
REASON FOR TERMINATION : ACHIVED THR
EXERCISE TOLERANCE :
EXERCISE INDUCED ARRHYTHMIA :
HAEMO RESPONSE :
CHRONO RESPONSE :
FINAL IMPRESSION : GOOD EXERCISE TOLERANCE
TEST NEGATIVE FOR STRESS INDUCED ISCHEMIA

DR ASHWIN KUMAR PANDA
MD(AIIMS DELHI) DM(NIMS HYD)

44 Years

DAVID RAJU OMMI
Male

12/06/2024 08:13:17

MEDCOVER HOSPITALS NYP VLAG

Rate 68 . SINUS RHYTHM.....normal P axis, V-rate 50- 99

WELLNESS

PR 160
QRSD 92
QT 400
QTc 426

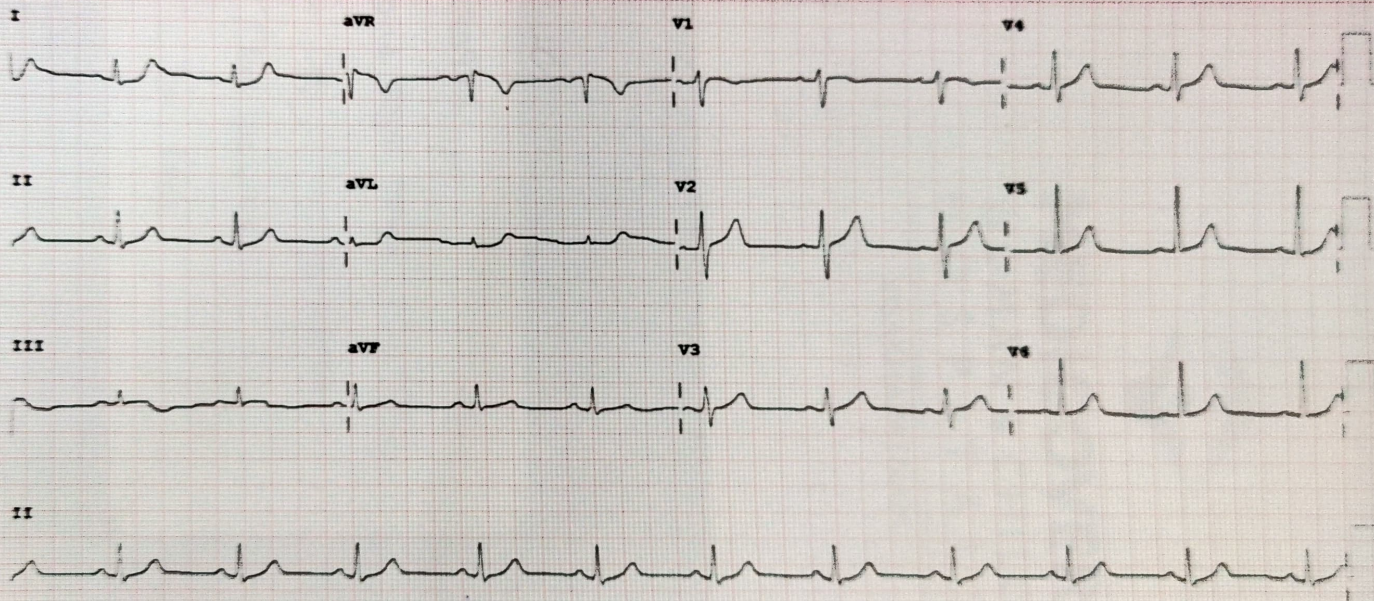
--AXIS--

P 66
QRS 59
T 44

- NORMAL ECG -

12 Lead: Standard Placement

Unconfirmed Diagnosis



Device:

Speed: 25 mm/sec

Limb: 10 mm/mV

Chest: 10.0 mm/mV

F 50- 0.50- 40 Hz W

PR090A CL