

MEDICAL EXAMINATION REPORT

Name J. Satya sailaja Gender M / F Date of Birth 5/4/1940

Position Selected For Identification marks A mole on the right eye

A. HISTORY:

1. Do you have, or are you being treated for, any of the following conditions? (please tick all that apply)?

- | | | |
|---|--|---|
| <input type="checkbox"/> Anxiety | <input type="checkbox"/> Cancer | <input type="checkbox"/> High Blood Pressure |
| <input type="checkbox"/> Arthritis | <input type="checkbox"/> Depression/ bipolar disorder | <input type="checkbox"/> High Cholesterol |
| <input type="checkbox"/> Asthama, Bronchitis, Emphysema | <input type="checkbox"/> Diabetes | <input type="checkbox"/> Migraine Headaches |
| <input type="checkbox"/> Back or spinal problems | <input type="checkbox"/> Heart Disease | <input type="checkbox"/> Sinusitis or Allergic Rhinitis (Hay Fever) |
| <input type="checkbox"/> Epilepsy | <input type="checkbox"/> Any other serious problem for which you are receiving medical attention | |

2. List the medications taken Regularly.

3. List allergies to any known medications or chemicals

4. Alcohol : Yes No Occasional

5. Smoking : Yes No Quit(more than 3 years)

6. Respiratory Function :

- a. Do you become unusually short of breath while walking fast or taking stair - case? Yes No
- b. Do you usually cough a lot first thing in morning? Yes No
- c. Have you vomited or coughed out blood? Yes No

7. Cardiovascular Function & Physical Activity :

- a. Exercise Type: (Select 1)
- No Activity
 - Very Light Activity (Seated At Desk, Standing)
 - Light Activity (Walking on level surface, house cleaning)
 - Moderate Activity (Brisk walking, dancing, weeding)
 - Vigorous Activity (Soccer, Running)
- b. Exercise Frequency: Regular (less than 3 days/ week) / Irregular (more than 3 days/ Week)
- c. Do you feel pain in chest when engaging in physical activity? Yes No

8. Hearing :

- a. Do you have history of hearing troubles? Yes No
- b. Do you experiences ringing in your ears? Yes No
- c. Do you experience discharge from your ears? Yes No
- d. Have you ever been diagnosed with industrial deafness? Yes No

9. Musculo - Skeletal History

- | | | | |
|-----------------------------------|--|------------------------------|--|
| a. Neck : | Have you ever injured or experienced pain? | Yes <input type="checkbox"/> | No <input checked="" type="checkbox"/> |
| b. Back : | If Yes ; approximate date (MM/YYYY) | | |
| c. Shoulder, Elbow, Wrists, Hands | Consulted a medical professional ? | Yes <input type="checkbox"/> | No <input checked="" type="checkbox"/> |
| d. Hips, Knees, Ankles, Legs | Resulted in time of work? | Yes <input type="checkbox"/> | No <input checked="" type="checkbox"/> |
| | Surgery Required ? | Yes <input type="checkbox"/> | No <input checked="" type="checkbox"/> |
| | Ongoing Problems ? | Yes <input type="checkbox"/> | No <input checked="" type="checkbox"/> |

10. Function History

- a. Do you have pain or discomfort when lifting or handling heavy objects? Yes No
- b. Do you have knee pain when squatting or kneeling? Yes No
- c. Do you have back pain when forwarding or twisting? Yes No
- d. Do you have pain or difficulty when lifting objects above your shoulder height? Yes No
- e. Do you have pain when doing any of the following for prolonged periods (Please circle appropriate response)
 - Walking : Yes No
 - Kneeling : Yes No
 - Squatting : Yes No
 - Climbing : Yes No
 - Sitting : Yes No
 - Standing : Yes No
 - Bending : Yes No
- f. Do you have pain when working with hand tools? Yes No
- g. Do you experience any difficulty operating machinery? Yes No
- h. Do you have difficulty operating computer instrument? Yes No

B. CLINICAL EXAMINATION :

a. Height b. Weight Blood Pressure mmhg

Chest measurements: a. Normal b. Expanded

Waist Circumference

Skin

Vision

Circulatory System

Gastro-intestinal System

Ear, Nose & Throat

Respiratory System

Nervous System

Genito- urinary System

Colour Vision

Discuss Particulars of Section B :-

C. REMARKS OF PATHOLOGICAL TESTS:

Chest X-ray	<input type="text" value="N"/>	ECG	<input type="text" value="N"/>
Complete Blood Count	<input type="text" value="N"/>	Urine routine	<input type="text" value="N"/>
Serum cholesterol	<input type="text" value="N"/>	Blood sugar	<input type="text" value="N"/>
Blood Group	<input type="text" value="N"/>	S.Creatinine	<input type="text" value="N"/>

D. CONCLUSION :

Any further investigations required

Any precautions suggested

E. FITNESS CERTIFICATION


Certified that the above named recruit does not appear to be suffering from any disease communicable or otherwise, constitutional weakness or bodily infirmity except yes

_____ . I do not consider this as disqualification for employment in the Company. S

Candidate is free from Contagious/Communicable disease

Date : 25/05/24

[Signature]
Signature of Medical Adviser



DR. DENTAL CONSULTATION
CONSULTANT DENTAL



MEDICOVER
HOSPITALS

KURNOOL

Organization Name : ARCOFEMI HEALTHCARE PVT LTD

Ref. Letter No. :

Name : Mrs. JANGAREDDI SATYA SAILAJA

Age : 52 Year(s) / Female

UMR No : KUU191467

Ref. Doctor :

Address : KURNOOL
KURNOOL, Andhra Pradesh

Visit Type : NORMAL

Phone No : 9440974004

Consult.No : KUOC352190

Date : 25-May-2024 9:41 am

Chief Complaints & H/O Present illness :

Past History

	Yes
HTN	
DM	
IHD	
Others	

Personal History

	Yes
Smoking	
Alcohol	

Investigations :

Provisional Diagnosis :

KUU191467

KUOC352190



A UNIT OF SAHRUDAYA HEALTHCARE (KURNOOL) PVT. LTD.

Sy. No. 419/B2, Opp. Old Edga, Near RTC Bus Stand, Kurnool | Ph : 040-6833 4455



Dr. OPHTHALMOLOGY CONSULTATION
CONSULTANT OPHTHALMOLOGIST

Organization Name : ARCOFEMI HEALTHCARE PVT LTD

ReF. Letter No. :

Name : Mrs. JANGAREDDI SATYA SAILAJA

Age : 52 Year(s) / Female

UMR No : KUU191467

Ref. Doctor :

Address : KURNOOL
KURNOOL, Andhra Pradesh

Visit Type : NORMAL

Phone No : 9440974004

Consult.No : KUOC352193

Date : 25-May-2024 9:41 am

Chief Complaints & H/O Present illness :

vr 6/9
6/9
Ns
CV - 21/21
- 21/21

l.c.c. (N)

os
os
nuclear
and
perineur
etc
etc

Past History

	Yes
HTN	
DM	
IHD	
Others	

Personal History

	Yes
Smoking	
Alcohol	

Investigations :

name study.

Ado
Kaldyggel 670
211d

Provisional Diagnosis :

Dr. D. SANTHOSHUMARI
MS, FCRS, FICO (UK)
Consultant Ophthalmologist
Phaco Cornea Refractive Surgeon
Reg. No: 61001
PRASANTH HOSPITAL, KURNOOL-2.

KUU191467



KUOC352193





Dr. PHYSICIAN CONSULTATION
CONSULTANT GENERAL PHYSICIAN



Organization Name : ARCOFEMI HEALTHCARE PVT LTD

Ref. Letter No. :

Name : Mrs. JANGAREDDI SATYA SAILAJA

Age : 52 Year(s) / Female

UMR No : KUU191467

Ref. Doctor :

Address : KURNOOL
KURNOOL, Andhra Pradesh

Visit Type : NORMAL

Phone No : 9440974004

Consult.No : KUOC352191

Date : 25-May-2024 9:41 am

Chief Complaints & H/O Present illness :

Past History

	Yes
HTN	
DM	
IHD	
Others	

Personal History

	Yes
Smoking	
Alcohol	

Investigations :

Provisional Diagnosis :

KUU191467

KUOC352191



A UNIT OF SAHRUDAYA HEALTHCARE (KURNOOL) PVT. LTD.

Sy. No. 419/B2, Opp. Old Edga, Near RTC Bus Stand, Kurnool | Ph : 040-6833 4455



Dr. GYNEACOLOGIST CONSULTATION
CONSULTANT GYNAECOLOGIST



MEDICOVER
HOSPITALS

KURNOOL

Organization Name : ARCOFEMI HEALTHCARE PVT LTD

ReF. Letter No. :

Name : Mrs. JANGAREDDI SATYA SAILAJA

Age : 52 Year(s) / Female

UMR No : KUU191467

Ref. Doctor :

Address : KURNOOL
KURNOOL, Andhra Pradesh

Visit Type : NORMAL

Phone No : 9440974004

Consult.No : KUOC352192

Date : 25-May-2024 9:41 am

Chief Complaints & H/O Present illness :

Past History

	Yes
HTN	
DM	
IHD	
Others	

Personal History

	Yes
Smoking	
Alcohol	

Investigations :

Provisional Diagnosis :

KUU191467

KUOC352192



A UNIT OF SAHRUDAYA HEALTHCARE (KURNOOL) PVT. LTD.

Sy. No. 419/B2, Opp. Old Edga, Near RTC Bus Stand, Kurnool | Ph : 040-6833 4455



DEPARTMENT OF HISTOPATHOLOGY

KURNOOL

Patient Name : Mrs. JANGAREDDI SATYA SAILAJA	Age /Sex : 52 Y(s)/Female
Bill Date : 25-May-2024 09:41 AM	UMR No : KUU191467
Received Date : 25-May-2024 9:53 AM	Bill No : KUB326808
Report Date : 25-May-2024 09:26 PM	Result No : RES511016
Ref By : DR.ANY CONSULTATION	Org.Name : ARCOFEMI HEALTHCARE PVT LTD
	Specimen : PAP

PAP SMEAR (FOR FEMALE)


MICROSCOPIC DESCRIPTION Cytosmear examined reveal superficial, intermediate squames, parabasal cells and tiny endocervical cell clusters. Background shows dense neutrophilic infiltrate.

Negative for intraepithelial lesion / malignancy.

IMPRESSION Atrophic inflammatory smear.

*** End Of Report ***

Verified By :



DR.K VASUNDHARA, MBBS, MD
CONSULTANT PATHOLOGIST



Department Of Laboratory



Patient Name : Mrs. JANGAREDDI SATYA SAILAJA	Age /Sex : 52 Y(s)/Female
Bill Date : 25-May-2024 09:41 AM	UMR No. : KUU191467
Report Date : 25-May-2024 9:53 AM	Bill No. : KUB326808
Received Date : 25-May-2024 01:00 PM	Result No : RES510905
Ref By : DR.ANY CONSULTATION	Org.Name : ARCOFEMI HEALTHCARE PVT LTD
	Specimen :

<u>Parameters</u>	<u>Result</u>	<u>Biological Reference</u>	<u>Method</u>
BUN / CREATININE RATIO			
BLOOD UREA NITROGEN (BUN)	13.2 mg/dL	7.0 - 21.0 mg/dL	Urease kinetic
PLBS (POST LUNCH BLOOD SUGAR WITH URINE SUGAR)			
POST PRANDIAL PLASMA / SERUM GLUCOSE(PLBS)	* 175 mg/dL	UPTO - 140 mg/dL	HEXOKINASE

*** End Of Report ***

Verified By:

DR DEVIANIB SREEATHA

ST



MEDICOVER HOSPITALS-KURNOOL

51/1-E2, 1-E3, 1-E4
Opp Old Edga, Near RTC Bus Stand,



MEDICOVER HOSPITALS

DEPARTMENT OF RADIOLOGY

KURNOOL

Patient Name	: Mrs. JANGAREDDI SATYA SAILAJA	Age /Sex	: 52 Y(s)/Female
Bill Date	: 25-May-2024 09:41 AM	UMR No.	: KUU191467
Received Date	: 25-May-2024 9:41 AM	Bill No.	: KUB326808
Report Date	: 25-May-2024 11:59 AM	Result No	: RES510835 / 0
Ref By	: DR.ANY CONSULTATION	Org.Name	: ARCOFEMI HEALTHCARE PVT LTD

USG BREAST

FINDINGS

A oval shaped hypoechoic well defined lesion measuring 9.8 x 4.5mm seen at 2'o clock position of right breast with approximately 1cm away from NAC - Likely Fibroadenoma / Intra mammary lymphnode.

A oval shaped hypoechoic well defined lesion measuring 7.5 x 5.2mm at 9'o clock position of left breast with approximately 3cm away from NAC - Likely Fibroadenoma / Intra mammary lymphnode.

Echogenic fibro glandular tissue seen in bilateral breasts - Likely Fibroadenosis.

Vascularity appears normal.

No e/o calcifications.

IMPRESSION

A oval shaped hypoechoic well defined lesion measuring 9.8 x 4.5mm seen at 2'o clock position of right breast with approximately 1cm away from NAC - Likely Fibroadenoma / Intra mammary lymphnode -- BI-RADS - III.

A oval shaped hypoechoic well defined lesion measuring 7.5 x 5.2mm at 9'o clock position of left breast with approximately 3cm away from NAC - Likely Fibroadenoma / Intra mammary lymphnode -- BI-RADS - III.

Echogenic fibro glandular tissue seen in bilateral breasts - Likely Fibroadenosis.

- Needs annual follow up.



MEDICOVER HOSPITALS-KURNOOL



51/1-E2, 1-E3, 1-E4
Opp Old Edga, Near RTC Bus Stand,

MEDICOVER HOSPITALS

KURNOOL

DEPARTMENT OF RADIOLOGY

Patient Name	: Mrs. JANGAREDDI SATYA SAILAJA	Age /Sex	: 52 Y(s)/Female
Bill Date	: 25-May-2024 09:41 AM	UMR No.	: KUU191467
Received Date	: 25-May-2024 9:41 AM	Bill No.	: KUB326808
Report Date	: 25-May-2024 11:46 AM	Result No	: RES510835 / 0
Ref By	: DR.ANY CONSULTATION	Org.Name	: ARCOFEMI HEALTHCARE PVT LTD

BI-RADS : Category

Definition

Likelihood of cancer

BI-RADS 0	Incomplete	N/A
BI-RADS 1	Negative	Essentially 0%
BI-RADS 2	Benign	Essentially 0%
BI-RADS 3	Probably benign	>0% , but <2%
BI-RADS 4	Suspicious	>2% , but < 95%
BI-RADS 5	Highly S/o Malignancy	> 95%
BI-RADS 6	Known biopsy-proven malignancy	N/A

Suggested clinical correlation.

*** End Of Report ***

DR.D SREENIVASULU, MBBS,MD
CONSULTANT RADIOLOGIST

Verified By :

Approved By :

Dispatched By :

Page 2 of 2



MEDICOVER HOSPITALS-KURNOOL

51/1-E2, 1-E3, 1-E4
Opp Old Eidga, Near RTC Bus Stand,



DEPARTMENT OF RADIOLOGY

Patient Name	: Mrs. JANGAREDDI SATYA SAILAJA	Age /Sex	: 52 Y(s)/Female
Bill Date	: 25-May-2024 09:41 AM	UMR No.	: KUU191467
Received Date	: 25-May-2024 9:41 AM	Bill No.	: KUB326808
Report Date	: 25-May-2024 11:37 AM	Result No	: RES510833 / 0
Ref By	: DR.ANY CONSULTATION	Org.Name	: ARCOFEMI HEALTHCARE PVT LTD

U/S ABDOMEN - PELVIS

FINDINGS

LIVER : Normal in size and increased in echotexture. No focal lesions seen. No Intra hepatic biliary ductal dilatation.

CBD & PV : Normal.

GALL BLADDER : Well distended. No gallstones. Gall Bladder wall thickness is normal

PANCREAS : Visualized head of pancreas appears normal in size with echotexture.
No focal lesions. Pancreatic duct normal. No Pancreatic Calcifications.

SPLEEN : Normal in size with normal echotexture. No focal lesions.

KIDNEYS : Right kidney normal in size and position. Cortico medullary differentiation is well made out. No e/o calculus / Hydronephrosis.

Left kidney normal in size and position. Cortico medullary differentiation is well made out. No e/o calculus / Hydronephrosis.

URINARY BLADDER : Well Distended.No vesical calculus. Bladder wall thickness is normal.

Uterus : Post hysterectomy status.

Ovaries : Both ovaries are normal in size with normal echotexture.

No focal lesions seen. Both adnexal regions normal.

IVC, Aortic and Para aortic areas normal.

No free fluid in the abdomen.

IMPRESSION

Grade - I fatty liver.

ADVISED: Clinical correlation and kindly discuss if necessary not for medico legal purpose

*** End Of Report ***

DR.C.A.SANTOSH VARMA
CONSULTANT RADIOLOGIST

Verified By :

Approved By :

Dispatched By :



MEDICOVER
HOSPITALS

DEPARTMENT OF HAEMATOLOGY

KURNOOL

Patient Name : Mrs. JANGAREDDI SATYA SAILAJA	Age /Sex : 52 Y(s)/Female
Bill Date : 25-May-2024 09:41 AM	UMR No : KUU191467
Received Date : 25-May-2024 9:52 AM	Bill No : KUB326808
Report Date : 25-May-2024 10:50 AM	Result No : RES510793
Ref By : DR.ANY CONSULTATION	Org.Name : ARCOFEMI HEALTHCARE PVT LTD
	Specimen : Blood

COMPLETE BLOOD COUNT

<u>Parameters</u>	<u>Result</u>	<u>Biological Reference Intervals</u>	<u>Method</u>
WBC	8,700	4000 - 11000 cells/cumm	Automated Cell Counter
RED BLOOD CELLS	4.68 mill/cumm.	3.9 - 5.0 milli/cumm	Automated Cell Counter
HAEMOGLOBIN	12.9 g/dl	11.5 - 16.0 g/dl	Electrical Impedance
PCV (PACKED CELL VOLUME)	41.9 %	37 - 52 %	Automated Cell Counter cyanmethemoglobin
MCV (MEAN CORPUSCULAR VOLUME)	89 fl	80.0 - 100.0 fl	Automated Cell Counter Calculated
MCH (Mean Corpuscular Hemoglobin)	27.6 pg	27.0 - 34.0 pg	Automated cell counter calculated
MCHC (Mean Corpuscular Hemoglobin Concentration)	* 30.9 g/dL	32.0 - 36.0 g/dL	Automated cell counter calculated
PLATELET COUNT	1.95 Lakhs/cumm.	1.4 - 4.0 Lakhs/cumm.	Automated Cell Counter
RDW-SD	* 12.4 fl	37.0 - 54.0 fl	Electrical Impedance
PDW	16.0 fl	9.0 - 17.0 fl	FULLY AUTOMATED HAEMATOLOGY ANALYSER
MPV	9.2 fl	9.0 - 13.0 fl	FULLY AUTOMATED HAEMATOLOGY ANALYSER
PCT	0.180 %	0.17 - 0.35 %	FULLY AUTOMATED HAEMATOLOGY ANALYSER
NEUTROPHILS	53.6 %	50.0 - 70.0 %	FULLY AUTOMATED HAEMATOLOGY ANALYSER
LYMPHOCYTES	* 40.7 %	20.0 - 40.0 %	Microscopy
MONOCYTES	3.2 %	1.0 - 10.0 %	Microscopy
EOSINOPHILS	2.0 %	1.0 - 6.0 %	Microscopy
BASOPHILS	0.5 %	0.0 - 1.0 %	Microscopy

*** End Of Report ***

Verified By:

DR.K VASUNDHARA, MBBS, MD
CONSULTANT PATHOLOGIST

A UNIT OF SAHRUDAYA HEALTHCARE (KURNOOL) PVT. LTD.

Sy. No. 419/B2, Opp. Old Edga, Near RTC Bus Stand, Kurnool | Ph : 040-6833 4455



MEDICOVER
HOSPITALS

DEPARTMENT OF BIOCHEMISTRY

KURNOOL

Patient Name : Mrs. JANGAREDDI SATYA SAILAJA	Age /Sex : 52 Y(s)/Female
Bill Date : 25-May-2024 09:41 AM	UMR No : KUU191467
Received Date : 25-May-2024 9:53 AM	Bill No : KUB326808
Report Date : 25-May-2024 11:44 AM	Result No : RES510825
Ref By : DR.ANY CONSULTATION	Org.Name : ARCOFEMI HEALTHCARE PVT LTD
	Specimen : SERUM

<u>Parameters</u>	<u>Result</u>	<u>Biological Reference Intervals</u>	<u>Method</u>
VITAMIN B12	383.3 pg/mL	Deficient : < 145 pg/mL Indeterminate : 145 - 180 pg/mL Normal : 180 - 914 pg/mL	ECLIA

*** End Of Report ***

Verified By:

DR.DEVANUR SREELATHA
CONSULTANT BIOCHEMIST

A UNIT OF SAHRUDAYA HEALTHCARE (KURNOOL) PVT. LTD.

Sy. No. 419/B2, Opp. Old Edga, Near RTC Bus Stand, Kurnool | Ph : 040-6833 4455



Department Of Laboratory



MEDICOVER HOSPITALS

KURNOOL

Patient Name : Mrs. JANGAREDDI SATYA SAILAJA	Age /Sex : 52 Y(s)/Female
Bill Date : 25-May-2024 09:41 AM	UMR No. : KUU191467
Report Date : 25-May-2024 9:53 AM	Bill No. : KUB326808
Received Date : 25-May-2024 11:44 AM	Result No : RES510820
Ref By : DR.ANY CONSULTATION	Org.Name : ARCOFEMI HEALTHCARE PVT LTD
	Specimen : CITRATED PLASMA

<u>Parameters</u>	<u>Result</u>	<u>Biological Reference</u>	<u>Method</u>
Erythrocyte Sedimentation Rate (ESR)	08 mm/Hour	0 - 20 mm/Hour	westergren's
BLOOD UREA NITROGEN (BUN)	12.5 mg/dL	7.0 - 21.0 mg/dL	Urease kinetic
GLYCOSYLATED HAEMOGLOBIN (HbA1c)	6.2 %	NORMAL : 4.0 - 6.0 % increased risk of diabetes : > 6.0 - 6.40 % indicate diabetes : > 6.5 - 7.0 %	Immunoturbidimetric
VITAMIN D3	33.8 ng/mL	Deficient : < 20 ng/mL Insufficient : 20 - 29 ng/mL Sufficient : 30 - 100 ng/mL Potential toxicity : > 100 ng/mL	Enzyme Linked Fluorescent Assay
LIPID PROFILE			
TOTAL CHOLESTEROL	* 217 mg/dl	0 - 200 mg/dl	Cholesterol esterase
SERUM TRYGLYCERIDES	151 mg/dL	Border line : 200 - 240 mg/dL Desirable : < 200 mg/dL High : > 400 mg/dL	Lipoprotein Lipase
HDL CHOLESTEROL	50 mg/dL	Desirable : >= 40 mg/dL	Direct measure-PEG
LDL CHOLESTEROL	137 mg/dL	Border line : 100 - 130 mg/dL Desirable : < 100 mg/dL High : > 130 mg/dL	Calculated
VLDL	30 mg/dL	0 - 40 mg/dL	Calculated
FBS (FASTING BLOOD GLUCOSE WITH URINE GLUCOSE)			
FASTING PLASMA /SERUM GLUCOSE (FBS)	94 mg/dL	70 - 110 mg/dL	Hexokinase
CREATININE	1.1 mg/dl	0.6 - 1.5 mg/dl	Kinetic jaffe reaction
LIVER FUNCTION TESTS (LFT)			
TOTAL BILIRUBIN	* 1.2 mg/dL	0.2 - 1.1 mg/dL	Diazotization
DIRECT (CONJUGATED) BILIRUBIN	* 0.4 mg/dL	0.0 - 0.25 mg/dL	Diazotization
SGOT (AST)	19 U/L	9 - 48 U/L	Uv kinetic with P5P
SGPT (ALT)	24 U/L	0.0 - 50.0 U/L	Uv kinetic with P5P
ALKALINE PHOSPHATASE (ALP)	72 U/L	37 - 110 U/L	p-NPP AMP Buffer
TOTAL SERUM PROTEINS	7.9 g/dL	6.4 - 8.2 g/dL	Biuret reaction
SERUM ALBUMIN	4.9 g/dL	3.5 - 5.2 g/dL	BCG Dye Method



Parameters

URIC ACID

TOTAL SERUM PROTEINS

Result

* 6.6 mg/dL

7.9 g/dL

Biological Reference

2.6 - 6.0 mg/dL

6.4 - 8.2 g/dL

Method

URICASE

Biuret reaction

*** End Of Report ***

Verified By:

DR DEVAJIB SREEATHA

A handwritten signature in black ink, appearing to read 'Devajib Sreeatha'.

ST



MEDICOVER
HOSPITALS

DEPARTMENT OF RADIOLOGY

KURNOOL

Patient Name	: Mrs. JANGAREDDI SATYA SAILAJA	Age /Sex	: 52 Y(s)/Female
Bill Date	: 25-May-2024 09:41 AM	UMR No.	: KUU191467
Received Date	: 25-May-2024 9:41 AM	Bill No.	: KUB326808
Report Date	: 25-May-2024 11:53 AM	Result No	: RES510846 / 0
Ref By	: DR.ANY CONSULTATION	Org.Name	: ARCOFEMI HEALTHCARE PVT LTD

X-RAY CHEST PA VIEW

FINDINGS

Cardiac shadow within normal limits.
Aorta normal.
Mediastinum normal.
Lung fields are clear.
Hilar and bronchovascular markings are normal bilaterally.
Both domes of diaphragm are regular.
Both costophrenic angles normal.
Bony thoracic cage and soft tissues of the chest wall normal.

IMPRESSION

No significant abnormality detected.

SUGGESTED CLINICAL CORRELATION.

*** End Of Report ***

DR.D SREENIVASULU, MBBS,MD
CONSULTANT RADIOLOGIST

Verified By :

Approved By :

Dispatched By :

A UNIT OF SAHRUDAYA HEALTHCARE (KURNOOL) PVT. LTD.

Sy. No. 419/B2, Opp. Old Edga, Near RTC Bus Stand, Kurnool | Ph : 040-6833 4455



Department Of Laboratory



Patient Name : Mrs. JANGAREDDI SATYA SAILAJA	Age /Sex : 52 Y(s)/Female
Bill Date : 25-May-2024 09:41 AM	UMR No. : KUU191467
Report Date : 25-May-2024 9:53 AM	Bill No. : KUB326808
Received Date : 25-May-2024 01:00 PM	Result No : RES510905
Ref By : DR.ANY CONSULTATION	Org.Name : ARCOFEMI HEALTHCARE PVT LTD
	Specimen :

<u>Parameters</u>	<u>Result</u>	<u>Biological Reference</u>	<u>Method</u>
BUN / CREATININE RATIO			
BLOOD UREA NITROGEN (BUN)	13.2 mg/dL	7.0 - 21.0 mg/dL	Urease kinetic
PLBS (POST LUNCH BLOOD SUGAR WITH URINE SUGAR)			
POST PRANDIAL PLASMA / SERUM GLUCOSE(PLBS)	* 175 mg/dL	UPTO - 140 mg/dL	HEXOKINASE

*** End Of Report ***

Verified By:

DR DEVAJIJI SREEATHA

ST



MEDICOVER HOSPITALS-KURNOOL

51/1-E2, 1-E3, 1-E4
Opp Old Eidga, Near RTC Bus Stand,



MEDICOVER HOSPITALS

DEPARTMENT OF CARDIOLOGY

KURNOOL

Name	: Mrs. JANGAREDDI SATYA SAILAJA	Age /Sex	: 52 Y(s)/Female
Bill Date	: 25-May-2024 09:41 AM	UMR No	: KUU191467
Received	: 25-May-2024 9:41 AM	Bill No	: KUB326808
Report Date	: 25-May-2024 10:26 AM	Result No	: RES510801
Ref By	: DR.ANY CONSULTATION	Org.Name	: ARCOFEMI HEALTHCARE PVT LTD

2D ECHOCARDIOGRAPHY/COLOR DOPPLER

MITRAL VALVE : NORMAL

AORTIC VALVE : NORMAL

TRICUSPID VALVE : NORMAL

PULMONARY VALVE : NORMAL

LEFT ATRIUM : 2.8 CMS

AORTA : 2.7 CMS

LEFT VENTRICLE : EDD : 4.6 CMS ESD : 2.8 CMS EF : 66 %

RIGHT VENTRICLE : NORMAL

RIGHT ATRIUM : NORMAL

PULMONARY ARTERY : NORMAL

IAS : INTACT

IVS : INTACT

PERICARDIUM : NORMAL

DOPPLER : AJV=1.1m/sec. PJV=1.0m/sec.

CONCLUSION : NO RWMA

NORMAL LV SYSTOLIC FUNCTION

NO MR, NO AR, NO TR, NO PAH

NO PE/NO LA, LV CLOTS

*** End Of Report ***

DR.CARDIOLOGY CONSULTATION
CONSULTANT CARDIOLOGIST

j, satya sailaja
Female

52 Years

Rate 75 . Sinus rhythm.....normal P axis, V-rate 50- 99

PR 171
QRSD 86
QT 417
QTc 466

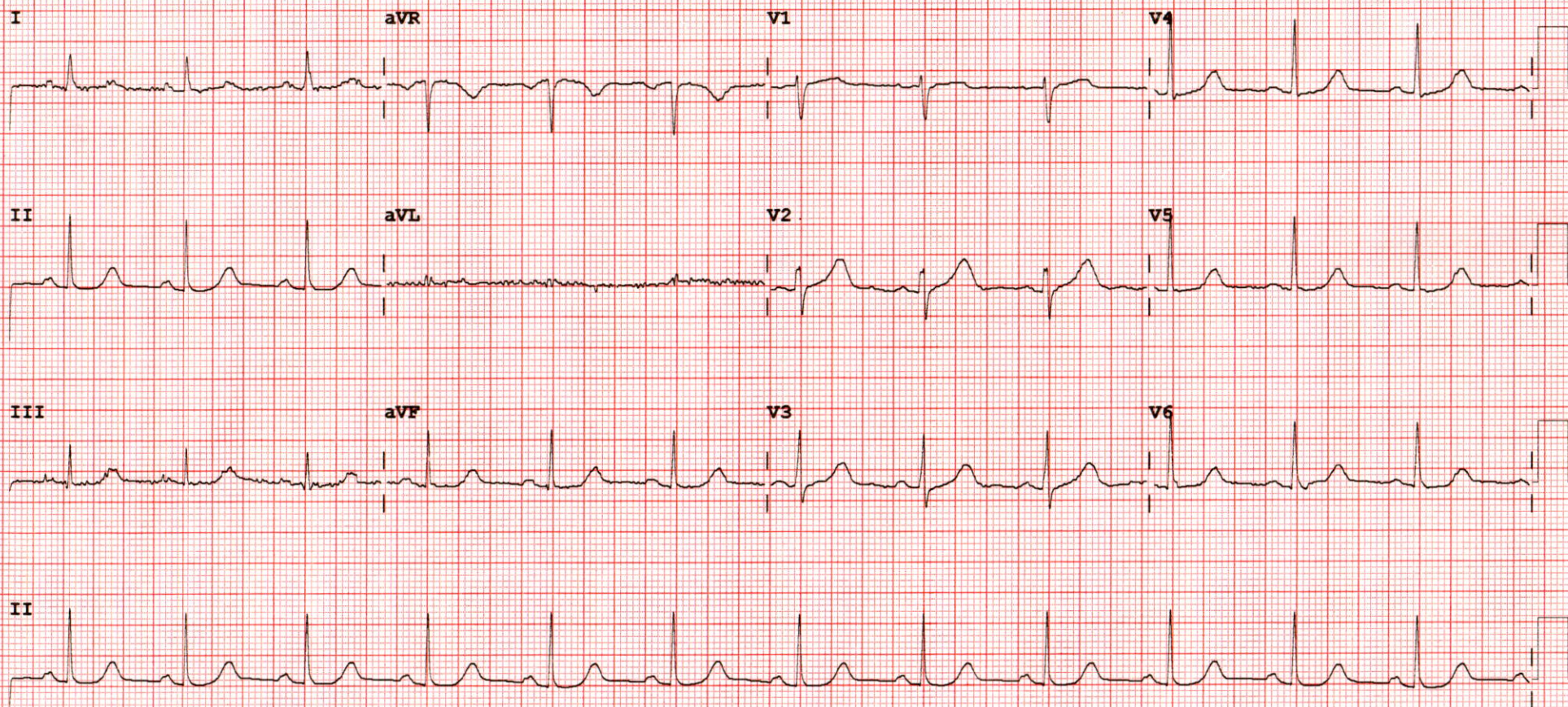
--AXIS--

P 73
QRS 47
T 63

- NORMAL ECG -

12 Lead; Standard Placement

Unconfirmed Diagnosis



Device: Speed: 25 mm/sec Limb: 10 mm/mV Chest: 10.0 mm/mV F 50~ 0.50- 40 Hz W 100B CL P?



SPRINT DIAGNOSTICS

Plot No. 8-2, Check Post, 293/A/1268, Rd Number 36,
near Jubilee Hills, Hyderabad, Telangana 500033, Jubilee Hills



LABORATORY REPORT : Biochemistry

Name	: Mrs. J SATYA SAILAJA	Age /Sex	: 052Y Y(s)/FEMALE
Sample Collected On	: 26-May-2024 04:17 PM	UMR No.	: 32405002736
Department Receiving	: 26-May-2024 05:27 PM	Bill No.	: MOPB240503681
Reported Date	: 26-May-2024 06:39 PM	Result No	: RJB240504798
Advised By	: Dr ANY CONSULTATION	Sample ID	: JBH240502975
Sample Type	: Serum		

GGT (GAMMA GLUTAMYL TRANSPEPTIDASE), SERUM

<u>Parameters</u>	<u>Result</u>	<u>BRI</u>	<u>Units</u>
GAMMA GLUTAMYL TRANSFERASE(GGT) <i>IFCC</i>	14.5	6-42	U/L


INTERPRETATION

Gamma glutamyltransferase is used in the diagnosis and monitoring of hepatobiliary diseases.
Gamma glutamyltransferase is also a sensitive screening test for occult alcoholism.
Elevated GGT activities are found in the serum of patients requiring long-term medication with phenobarbital and phenytoin.

*** End Of Report ***

Suggested Clinical Correlation * If neccessary, Please discuss

Verified By :
ID -15478


DR SWAPNIKA T.G
MD BIOCHEMISTRY
TSMC/72222