



Medicover Hospitals

VENKOJIPALAM VISAKHAPATNAM - 530017
ANDHRA PRADESH - INDIA
PHONE NO : 0891-6829999

**Dr. RAKESH P
MD
GENERAL PHYSICIAN**

NAME : Satish AGE 38y 1M

WT: 70 kg's

HT: 162 cm-s

BP: 120/80 mmHg

PR: 89/min



**MEDICOVER
HOSPITALS**

A UNIT OF SAHRUDAYA HEALTHCARE PVT LTD.

Medicover Hospitals

VENKOJIPALAM VISKHAPATNAM -530017

ANDHRA PRADESH -INDIA

PHONO NO : 0891-6829999

OPHTHALMOLOGIST CONSULTATION

NAME: V. ganesh AGE: 38M

DATE: 25/5/24

AR $\begin{matrix} R & -0.25-1.25 \times 76 \\ C & -1.00 \times 94 \end{matrix}$

SV $\begin{matrix} R & 6/9 +0.00 \times 80 \text{ @ } 6/6 \\ C & 6/9 -0.25 \times 100 \text{ @ } 6/6 \end{matrix}$

NOV-206

(L) KPI +

SS

0.4 = 1

I/O WNL

AT $\begin{matrix} L & 1/4 \\ R & 1/6 \end{matrix}$

PIA by



Medicover Hospitals
VENKOJIPALAM VISAKHAPATNAM - 530017
ANDHRA PRADESH - INDIA



Lab Report

Patient Name : Mr. SATISH VADDI	Age /Gender : 38 Y(s)/Male
Bill No/ UMR No : V4BC237652/V4U188055	Referred By : Dr. CMO
Received Dt : 25-May-24 08:59 am	Report Date : 25-May-24 10:07 am
Lab No : 120000635698	

<u>Parameter</u>	<u>Result Values</u>	<u>Biological Reference</u>
CBC(COMPLETE BLOOD COUNT)		
RBC		
HAEMOGLOBIN	13.0	13.0 - 17.0 g/dl
R B C COUNT	4.9	4.5 - 5.5 $10^6/\mu\text{L}$
PCV/HCT	* 38	40 - 50 %
MCV	* 77	83 - 101 fl
MCH	* 26	27 - 32 pg
MCHC	34	31.5 - 34.5 g/dL
RDW(cv)	* 15.7	11.6 - 14.0 %
WBC		
TC (TOTAL LEUCOCYTE COUNT)	4700	4000 - 11000 cells/cumm
DIFFERENTIAL COUNT		
NEUTROPHILS	55	40 - 80 %
LYMPHOCYTES	38	20 - 40 %
MONOCYTES	05	02 - 10 %
EOSINOPHILS	02	00 - 06 %
BASOPHILS	00	00 - 01 %
PLATELET COUNT		
PLATELET COUNT	2.04	1.50 - 4.50 Lakhs/cumm
ESR	10	0 - 10 mm/1st hour

*** End Of Report ***

Doctor Incharge

Dr.MUDUGANTI SRINIVAS
MBBS, MD
CONSULTANT PATHOLOGIST

Dr.SRUJANA
MBBS, MD PATHOLOGY
CONSULTANT PATHOLOGIST

Dr.MOHAMMAD SIMI IQBAL
M.B.B.S, M.D
CONSULTANT BIOCHEMIST

Medicover Unit - I

18-1-3, KGH Down, Maharanipecta,
Jagadamba Junction, Visakapatnam,
Andhrapradesh - 530 002.
Ph: +91 96526 69351

Medicover Unit - III

Sry. No. 27, Plot No. 05, BRTS Road,
Health City, Arilova, Chinnagadalu Mandal,
Visakhapatnam, Andhrapradesh - 530 040.
Ph: +91 08916677888

Medicover - MVP

1-1-83, Sector -6, Venkijipalem,
MVP Colony, Visakapatnam,
Andhrapradesh-530017.
Ph: +91 8886655677



Medicover Hospitals

VENKOJIPALAM VISAKHAPATNAM - 530017
ANDHRA PRADESH - INDIA



MEDICOVER HOSPITALS

A UNIT OF SAHRUDAYA HEALTHCARE PVT LTD.

Lab Report

Patient Name	: Mr. SATISH VADDI	Age /Gender	: 38 Y(s)/Male
Bill No/ UMR No	: V4BC237652/V4U188055	Referred By	: Dr. CMO
Received Dt	: 25-May-24 08:59 am	Report Date	: 25-May-24 11:48 am
Lab No	: 120000635699		

<u>Parameters</u>	<u>Result</u>	<u>Biological Reference Intervals</u>
LIPID PROFILE		
TOTAL CHOLESTEROL	164	No risk : < 200 mg/dL Moderate risk : 200 - 239 High risk : > 240
HDL CHOLESTEROL	27	<40 Low >60 High
LDL CHOLESTEROL	* 92	Border line : 100 - 130 mg/dL High : > 130 mg/dL Desirable : < 100 mg/dL 100 - 130 mg/dL
VLDL	45	
SERUM TRYGLYCERIDES	226	Very High : > 500 mg/dL High : >= 200 - 499 mg/dL Border line High : >= 150 - 199 mg/dL Normal : < 150 mg/dL
CHO/HDL RATIO	* 6.07	Normal : < 4.0 Low risk : 4.0 - 6.0 High risk : > 6.0
LDL/HDL RATIO	3.41	
FBS (FASTING BLOOD GLUCOSE)		
FASTING BLOOD GLUCOSE	87	Normal : 70-99 mg/dL Impaired : 100-125 mg/dL Diabetic : >= 126 mg/dL
CREATININE	* 0.8	0.9 - 1.3 mg/dL
LFT(LIVER FUNCTION TEST)		
TOTAL BILIRUBIN	0.5	< 1.2 mg/dL
DIRECT BILIRUBIN	0.1	<= 0.20 mg/dL
INDIRECT BILIRUBIN	0.4	<= 1.0 mg/dL
SGPT (ALT)	30	<= 41 U/L
SGOT (AST)	33	<= 40 U/L
ALKALINE PHOSPHATASE (ALP)	102	40 - 129 U/L
TOTAL PROTEINS	7.5	1-2 years : 5.6-7.5 g/dL > 3 years : 6.0-8.0 g/dL
SERUM ALBUMIN	4.7	Adults : 6.4-8.3 g/dL NewBorn: 0-4 days : 2.8 - 4.4 g/dL Children: 4 days - 14 years : 3.8 - 5.4 g/dL 14-18 years : 3.2 - 4.5 g/dL Adults : 3.5- 5.2 g/dL

Medicover Unit - I

18-1-3, KGH Down, MaharaniPeta,
Jagadamba Junction, Visakapatnam,
Andhrapradesh - 530 002.
Ph: +91 96526 69351

Medicover Unit - III

Sry. No. 27, Plot No. 05, BRTS Road,
Health City, Arilova, Chinnagadalu Mandal,
Visakhapatnam, Andhrapradesh - 530 040.
Ph: +91 08916677888

Medicover - MVP

1-1-83, Sector -6, Venkojipalem,
MVP Colony, Visakapatnam,
Andhrapradesh-530017.
Ph: +91 8886655677



Medicover Hospitals

VENKOJIPALAM VISAKHAPATNAM - 530017
ANDHRA PRADESH - INDIA



MEDICOVER HOSPITALS

A UNIT OF SAHRUDAYA HEALTHCARE PVT.LTD.

Lab Report

Patient Name	: Mr. SATISH VADDI	Age /Gender	: 38 Y(s)/Male
Bill No/ UMR No	: V4BC237652/V4U188055	Referred By	: Dr. CMO
Received Dt	: 25-May-24 08:59 am	Report Date	: 25-May-24 11:48 am
Lab No	: 120000635699		

Parameters	Result	Biological Reference In Method
GLOBULINS	2.8	2.5 - 3.5 g/dL
A/G RATIO	1.68	1.2 - 2.5
TOTAL PROTEIN		
TOTAL PROTEINS	7.5	1-2 years : 5.6-7.5 g/dL > 3 years : 6.0-8.0 g/dL Adults : 6.4-8.3 g/dL
HBA1C (GLYCOSYLATED HAEMOGLOBIN)		
HBA1C	5.6	Non -Diabetic : <= 5.6 % Pre Diabetic : 5.7 - 6.4 % Diabetic : >= 6.5 %
T3,T4 AND TSH		
T3	1.05	0.8 - 2.0 ng/mL
T4	5.92	5.1 - 14.1 ug/dL
TSH(THYROID STIMULATING HORMONE)	* 4.24	0.270 - 4.20 uIU/mL
PLBS (POST LUNCH BLOOD GLUCOSE)		
PLBS (POST LUNCH BLOOD GLUCOSE)	102	Normal : 70- 139 mg/dL Impaired : 140 - 199 mg/dL Diabetic : >= 200 mg/dL
GAMMA GT		
GAMMA GLUTAMYL TRANSFERASE(GGT)	55	10 - 71 U/L
BUN(BLOOD UREA NITROGEN)	9.6	7.0 - 21.0 mg/dL
BUN(BLOOD UREA NITROGEN)	10	

*** End Of Report ***

Suggested Clinical Correlation * If necessary, Please discuss

Verified By : : 25687

Test results related only to the item tested.

No part of the report can be reproduced without written permission of the laboratory.

Dr. MOHAMMEDI SIMI IQBAL M.B.B.S, M.D

Dr.MUDUGANTI SRINIVAS
MBBS, MD
CONSULTANT PATHOLOGIST

Dr.SRUJANA
MBBS, MD PATHOLOGY
CONSULTANT PATHOLOGIST

Dr.MOHAMMAD SIMI IQBAL
M.B.B.S, M.D
CONSULTANT BIOCHEMIST

Medicover Unit - I

18-1-3, KGH Down, Maharanipeta,
Jagadamba Junction, Visakapatnam,
Andhrapradesh - 530 002.
Ph: +91 96526 69351

Medicover Unit - III

Sry. No. 27, Plot No. 05, BRTS Road,
Health City, Arilova, Chinnagadalu Mandal,
Visakhapatnam, Andhrapradesh - 530 040.
Ph: +91 08916677888

Medicover - MVP

1-1-83, Sector -6, Venkojipalem,
MVP Colony, Visakapatnam,
Andhrapradesh-530017.
Ph: +91 8886655677



Medicover Hospitals

VENKOJIPALAM VISAKHAPATNAM - 530017
ANDHRA PRADESH - INDIA



MEDICOVER HOSPITALS

A UNIT OF SAHRUDAYA HEALTHCARE PVT LTD.

Lab Report

Patient Name	: Mr. SATISH VADDI	Age /Gender	: 38 Y(s)/Male
Bill No/ UMR No	: V4BC237652/V4U188055	Referred By	: Dr. CMO
Received Dt	: 25-May-24 08:59 am	Report Date	: 25-May-24 10:39 am
Lab No	: 240503687		

<u>Parameters</u>	<u>Result</u>	<u>Biological Reference Intervals</u>
CUE(COMPLETE URINE EXAMINATION)		
CHEMISTRY TEST		
UROBILINOGEN	NIL	Negative
BILIRUBIN	Negative	Negative
KETONE BODIES	Negative	Negative
BLOOD	Negative	Negative
PROTEIN	NIL	NIL
NITRITE	Negative	Negative
LEUCOCYTES	Negative	
GLUCOSE	NIL	NIL
SPECIFIC GRAVITY	1.010	1.005 - 1.030
PH	6.0	5.0 - 8.0
MICROSCOPY MORPHOLOGY		
RBC	NIL	0 - 3 /HPF
WBC (WHITE BLOOD CELL)	2-4	0 - 5 /HPF
SQEP (SQUAMOUS EPITHELIAL CELL)	1-2	0 - 5 /HPF
UNCC (PATHOLOGICAL CAST)	NIL	0 - 0 /HPF
UNCX (UNCLASSIFIED CRYSTALS)	NIL	0 - 5 /HPF

*** End Of Report ***

Doctor Incharge

Dr.MUDUGANTI SRINIVAS
MBBS, MD
CONSULTANT PATHOLOGIST

Dr.SRUJANA
MBBS, MD PATHOLOGY
CONSULTANT PATHOLOGIST

Dr.MOHAMMAD SIMI IQBAL
M.B.B.S, M.D
CONSULTANT BIOCHEMIST

Medicover Unit - I

18-1-3, KGH Down, Maharanipecta,
Jagadamba Junction, Visakapatnam,
Andhrapradesh - 530 002.
Ph: +91 96526 69351

Medicover Unit - III

Sry. No. 27, Plot No. 05, BRTS Road,
Health City, Arilova, Chinnagadalu Mandal,
Visakhapatnam, Andhrapradesh - 530 040.
Ph: +91 08916677888

Medicover - MVP

1-1-83, Sector -6, Venkojipalem,
MVP Colony, Visakapatnam,
Andhrapradesh-530017.
Ph: +91 8886655677



Medicover Hospitals

VENKOJIPALAM VISAKHAPATNAM - 530017
ANDHRA PRADESH - INDIA



DEPARTMENT OF RADIOLOGY

Patient Name : Mr. SATISH VADDI	Age / Gender : 38 Y(s)/Male
Bill No/ UMR No : V4BC237688/V4U188055	Referred By : Dr. CMO
Received Dt : 25-May-24 10:12 am	Report Date : 25-May-24 10:36 am

USG SCREENING (ABDOMEN)

FINDINGS

LIVER : Measures 13.7cm. Normal in size and increased echotexture. Smooth contours noted. Intrahepatic biliary tree and venous radicles are normal.

Portal vein and CBD : Normal in course and calibre.

- Small hypoechoic lesion of size 1.3 x 1.3cm noted in right lobe of the liver.

GALL BLADDER : Distended with a normal wall thickness . No calculi noted within.

PANCREAS : Head and body of pancreas are normal in size and echotexture. Rest obscured by bowel gas shadow.

SPLEEN : Measures - 9.6cm. Normal in size and echotexture.

KIDNEYS :

Right kidney measures - 10.2cm

Left kidney measures - 9.9cm

Both kidneys are normal in size, position and echogenecity. Cortical thickness and corticomedullary differentiation are normal. No hydronephrosis or calculi noted.

URINARY BLADDER : Partially distended . Wall thickness is normal.

PROSTATE : Normal in size and echotexture. No focal lesions.

No evidence of free fluid in abdomen.

No evidence of bowel pathology seen.

IMPRESSION

* **Grade I fatty changes of liver.**

* **Small hypoechoic lesion in right lobe of liver - Focal area of fat sparing / space occupying lesion.**

*** End Of Report ***

Dr. VENKATA SUMAN KUNA, MBBS , M.D,
PDCC(MSK)
CONSULTANT RADIOLOGIST

Medicover Unit - I

18-1-3, KGM Town, Manjanipeta,
Jagadamba Colony, Visakhapatnam,
Andhrapradesh - 530 002.
Ph: +91 96526 69351

Medicover Unit - III

Plot No. 27, Plot No. 05, BRTS Road,
Health City, Anirva, Chinmaganagar, Medical,
Visakhapatnam, Andhrapradesh - 530 040.
Ph: +91 08916677888

Medicover - MVP

1-1-83, Sector -6, Venkojipalem,
MVP Colony, Visakhapatnam,
Andhrapradesh-530017.
Ph: +91 8886655677

This report is not valid for medico-legal purpose
In case of any discrepancy due to machine error or typing error, please get it rectified immediately.



Medicover Hospitals

VENKOJIPALAM VISAKHAPATNAM - 530017
ANDHRA PRADESH - INDIA



MEDICOVER
HOSPITALS
A UNIT OF SAHRUDAYA HEALTHCARE PVT LTD

DEPARTMENT OF RADIOLOGY

Patient Name : Mr. SATISH VADDI	Age / Gender : 38 Y(s)/Male
Bill No/ UMR No : V4BC237652/V4U188055	Referred By : Dr. CMO
Received Dt : 25-May-24 08:46 am	Report Date : 25-May-24 11:41 am

X-RAY CHEST PA VIEW

FINDINGS

The cardiac size & configuration appear normal.

The Aorta and pulmonary vasculature appear normal.

There is no evidence of mediastinal widening.

Both the lungs and CP angles are clear.

The soft tissues and the bones of the rib cage displayed no abnormality.

IMPRESSION

* Normal study.

*** End Of Report ***

DR. VULAPU CHENNAKRISHNA RAO, .
MBBS, DNB
CONSULTANT RADIOLOGIST

Medicover Unit - I

#1, 1-83, Sector -6, Venkojipalem, Visakhapatnam, Andhra Pradesh - 530017.

Ph: +91 96526 69351

Medicover Unit - III

#27, Plot No. 05, BRTS Road, Visakhapatnam, Andhra Pradesh - 530040.

Ph: +91 08916677888

Medicover - MVP

#1, 1-83, Sector -6, Venkojipalem, Visakhapatnam, Andhra Pradesh - 530017.

Ph: +91 8886655677

This report is not valid for medico-legal purpose. In case of any discrepancy due to machine error or typing error, please get it rectified immediately.

38 Years

SATISH VADDI
Male

25/05/2024 08:41:55

MEDCOVER HOSPITALS MVP VZAG

WELLNESS

Rate 81 . SINUS RHYTHM.....normal P axis, V-rate 50- 99
 . BORDERLINE INTRAVENTRICULAR CONDUCTION DELAY.....QRSd >105ms

PR 148
 QRSD 106
 QT 376
 QTc 437

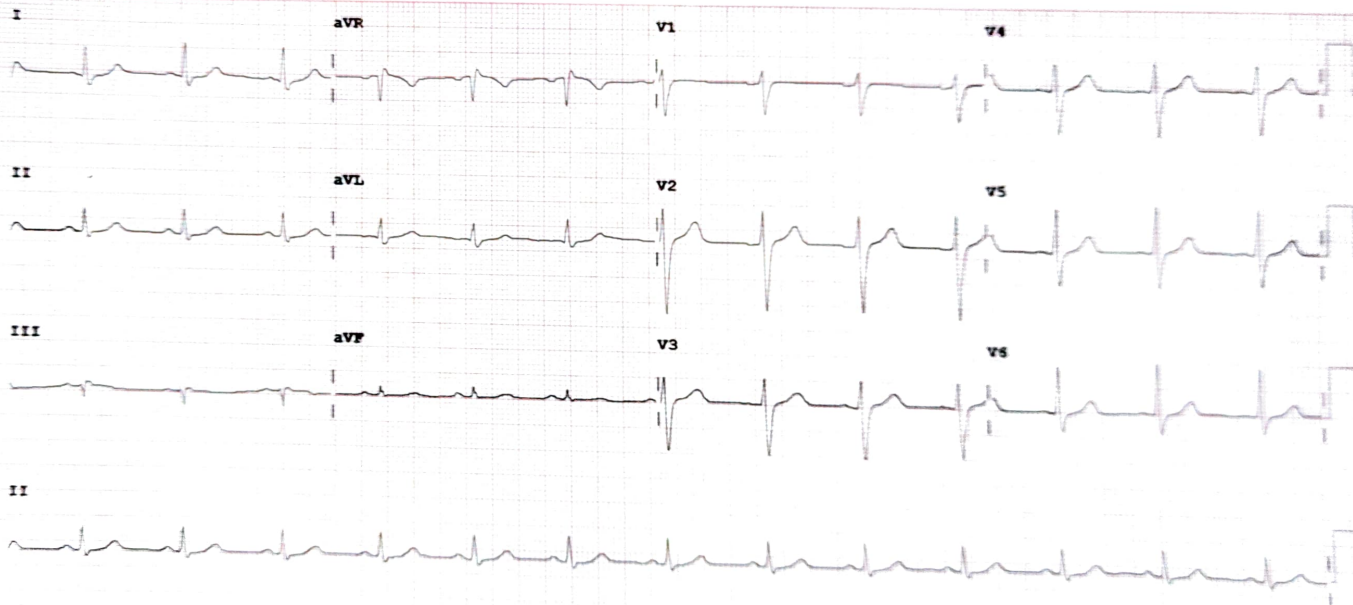
--AXIS--

P 64
 QRS 36
 T 24

- OTHERWISE NORMAL ECG -

12 Lead; Standard Placement

Unconfirmed Diagnosis



Device: Speed: 25 mm/sec Limb: 10 mm/mV Chest: 10.0 mm/mV

F 50- 0.50- 40 Hz W PH090A CL