

R

CHESTIA 11 05 2023 09 51 AM

VIKASIT KUMAR 11Y M R1212850



UHID	PT212850	LAB No.	XRY2312593
Name	Mr. VIKASH KUMAR	Regn. No.	GEN2405290
Age / Sex	41 Yrs / M	Receiving Dt/Time	11-May-2024 09:45
		Reporting Dt/Time	11-May-2024 04:34 PM



XRAY

CHEST (PA)

Both lung fields are normal.

Cp angles are clear.

Hila are normal...

Heart size appears within normal limits.

Soft tissue shadows and bony thorax are normal.

Advised....please correlate clinically.

***** END OF REPORT *****

DR. K.K. SINHA
M.B.B.S. D.M.R.D.
SENIOR CONSULTANT
Reg. No. 25437 (DMC)

DR. RAJESH MALHOTRA
MBBS, MD (RADIOLOGY)
CONSULTANT RADIOLOGY
Reg.No.DMC9299

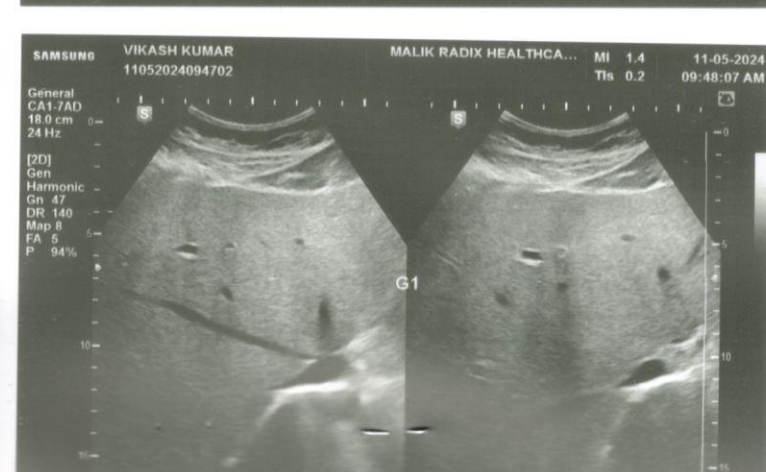
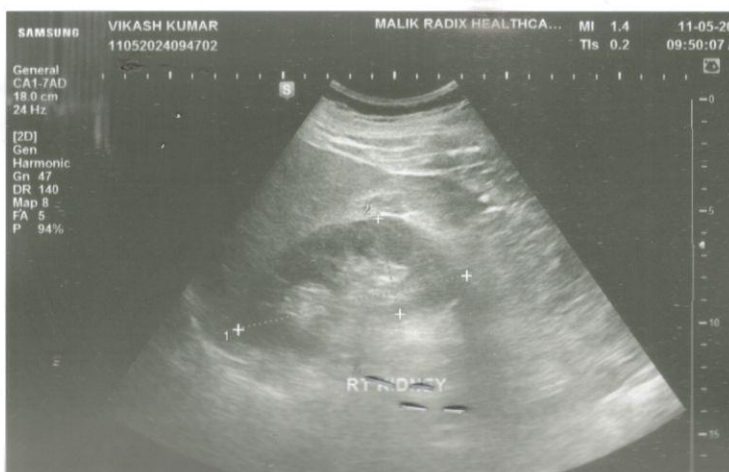
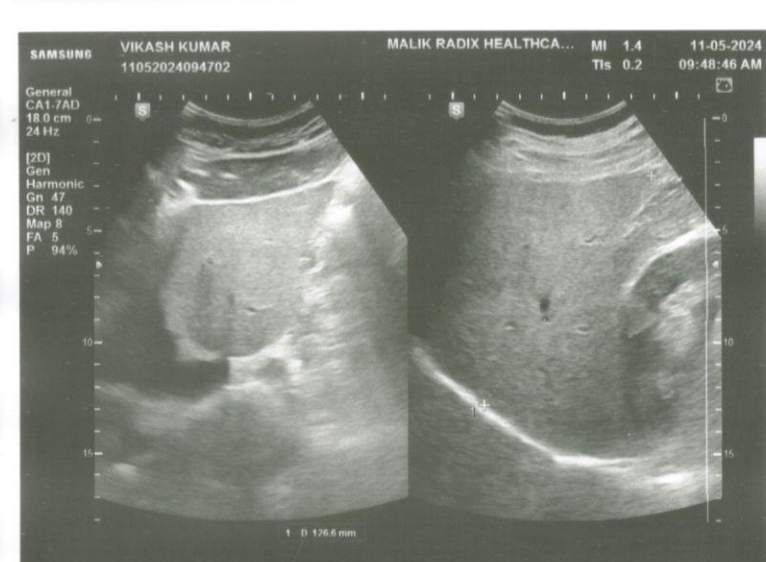
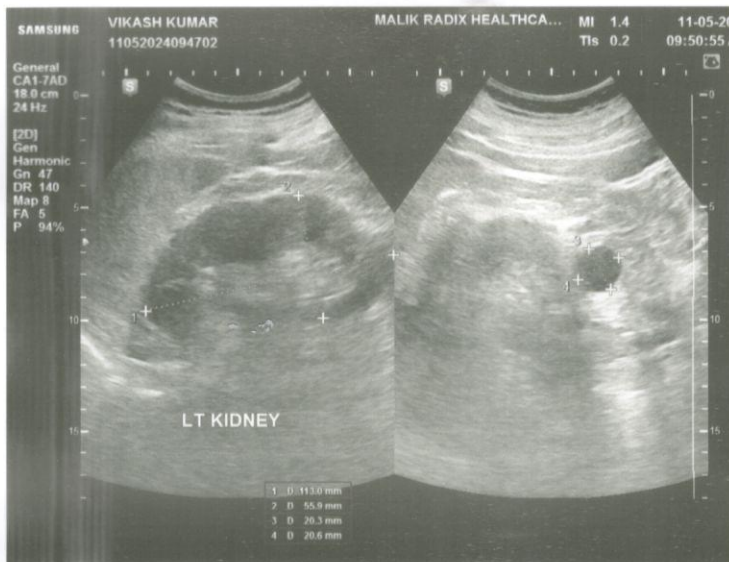
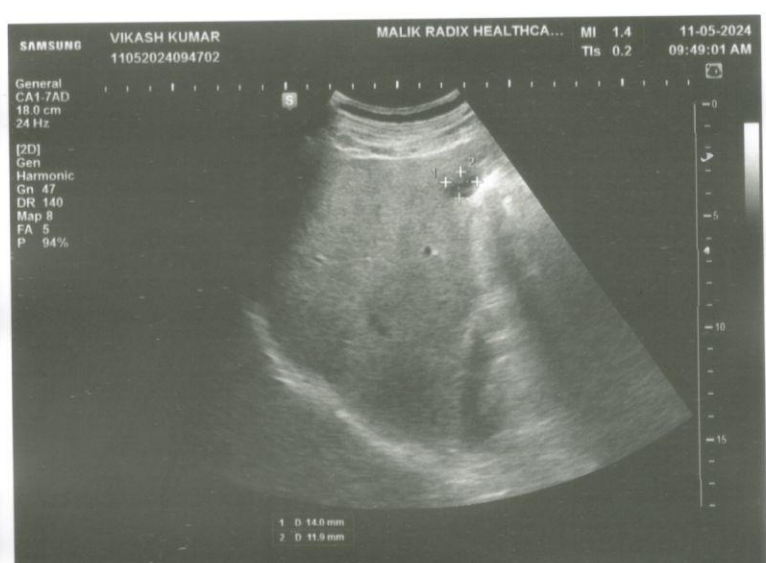
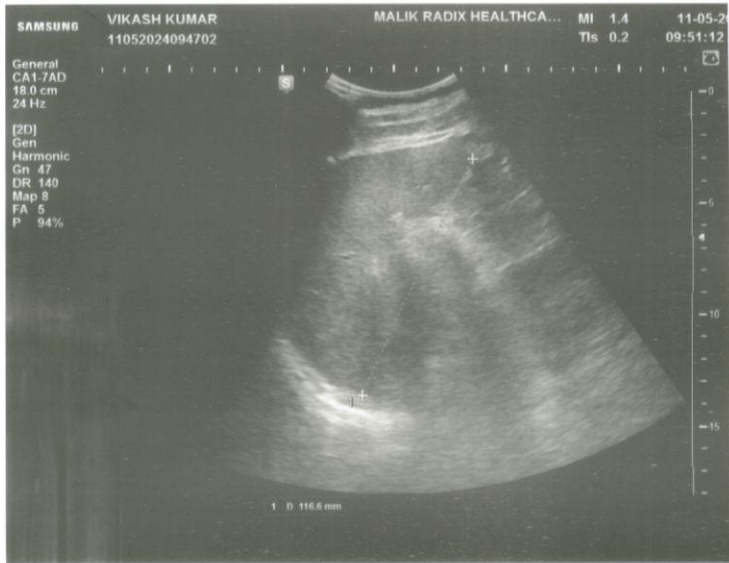
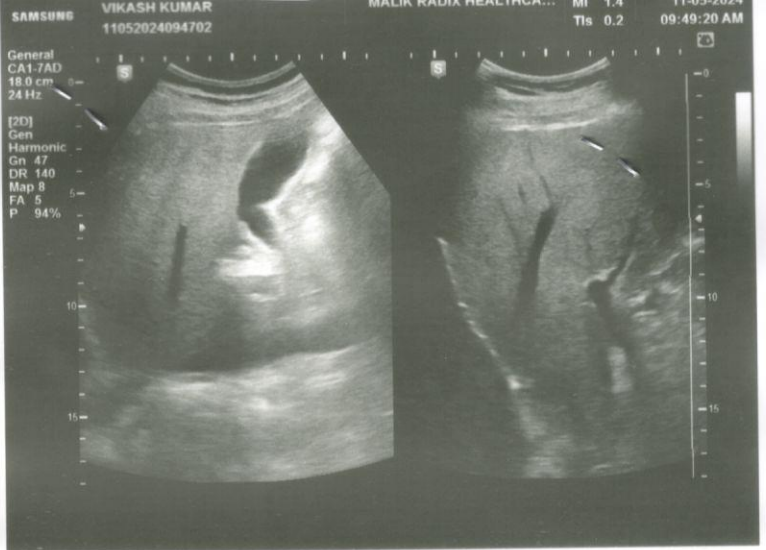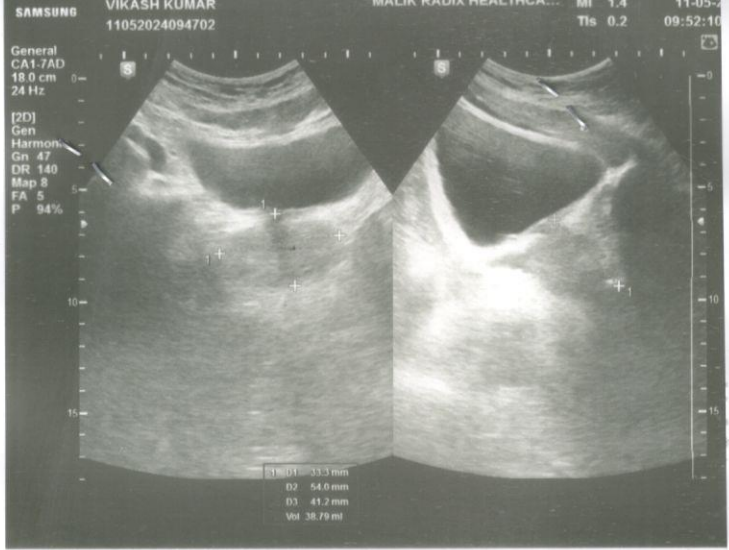
DR. T. K VOHRA
MD (RADIODIAGNOSIS)
SENIOR CONSULTANT
Reg. No. 3272 (DMC)

DR MUKESH KOSHAL
MBBS, MD (RADIOLOGY)
CONSULTANT RADIOLOGY
Reg.No.DMC10407

DR SHREYASH TIWARY
MBBS, MD (RADIOLOGY)
CONSULTANT RADIOLOGY
Reg.No.DMC85802

Facilities Available

- Multispeciality Hospital - 24 Hours Emergency - X-Ray/ ECG/ Ultrasound/ CT Scan - Dental - Fully Equipped Operation Theatre
- Fully Functional Lab - 24/7 Casualty/ ICU-Nursery 24/7 Pharmacy - Labour Room - All Speciality OPD - Laproscopic Surgery - ECHO - Plastic Surgery





NAME	MR. VIKASH KUMAR	AGE	41 YRS/M
REFD. BY.	HEALTH CHECK UP	DATE	11.05.24

Ultrasound Examination of Whole Abdomen & Pelvis:

Liver: Liver appears normal in size (12.6 cm) with normal outlines and shows increased parenchymal echotexture. **A simple cyst measuring – 14 x 1.9 mm seen in segment V.** IHBR & portal radicles are normal.

Gallbladder: Gallbladder is well distended. No evidence of cholecystitis or cholelithiasis seen. Common bile duct is normal in course & caliber.

Pancreas: Pancreas shows normal size, outlines & echotexture. No focal lesion is seen. MPD is not dilated.

Spleen: Spleen shows normal size (11.6 cm), outline & echotexture.

Kidneys: Kidneys show normal size, shape, position & echotexture. No calculus/ hydronephrosis or SOL is seen in kidneys. **A simple cyst measuring 2.0 x 2.0 mm noted at lower pole of left kidney.** Cortico-medullary differentiation and cortical thickness is normal on both sides.

Right kidney measures –10.4 x 4.4 cm

Left kidney measures –11.3 x 5.6 cm

Great abdominal vessels are normal.

No ascites seen.

No para-aortic lymph nodes seen.

Urinary bladder Urinary bladder is well distended. Walls and lumen appear normal.

Prostate is enlarged in size (38.7 cc) with normal outline and echotexture. No focal lesion is seen.

IMPRESSION:

Simple hepatic cyst

Grade I Fatty Liver

Left renal simple cortical cyst

Grade I Prostatomegaly

Dr Shreyash Tiwary MD (Rad- diag)



Regn. No. DMC 85802


RADIOLOGIST :

Facilities Available

5

41


 भारत सरकार
 Government of India
 


 Vikash Kumar
 DOB : 16/08/1982
 Male

Issue Date : 26/02/2012

6060 1987 9872

मेरा आधार, मेरी पहचान

Vikash Kumar


 भारतीय विशिष्ट पहचान प्राधिकरण
 Unique Identification Authority of India
 

Address: C/O RADHE SHYAM
 PRASAD, F 191B 3RD FLOOR,
 MANGAL BAZAR, LAXMI NAGAR,
 Laxmi Nagar (east Delhi), East Delhi,
 Delhi, 110092

Print Date : 08/12/2021

6060 1987 9872

 1947
  help@uidai.gov.in
 www.uidai.gov.in

MALIK RADIX HEALTH CARE PVT. LTD.
 C-217, C-218, Nirman Vihar,
 Delhi-110092
 Ph.: 011-49287456, 011-61381379
 Regd. No. 607

RADIX
HEALTH
care



Radix Healthcare

BMI, Eye, Dental.

Malik Radix Healthcare

C/217, C/218, Vikas Marg, Nirman Vihar, New Delhi-110092

A Unit of Malik Radix Healthcare

Toll Free - 1800-120-5457

Whatsapp No. - 9811550650

E-mail: info@radixhealthcare.org

Website: www.radixhealthcare.org



ANNUAL HEALTH CHECK UP

NAME: Mr. Vikash Kumar AGE/GENDER: 41 yrs / Male DATE 11/03/24

V/L 6/6 ~~6/6~~
6/6 ~~6/6~~

RCR { 14-
13-

9 HYPERARE (B2)

Color vis. normal

hnd: normal

Ref done for hb

Dr. Nidhi Gupta
MBBS, MS, DNB
Casualtant Ophthalmologist
Malik Radix Healthcare Pvt. Ltd.
DMC No. 121661

Facilities Available

- Multispeciality Hospital - 24 Hours Emergency - X-Ray/ ECG/ Ultrasound/ CT Scan - Dental- Fully Equipped Operation Theatre
- Fully Functional Lab - 24/7 Casualty/ ICU-Nursery 24/7 Pharmacy - Labour Room - All Speciality OPD - Laproscopic Surgery - ECHO - Plastic Surgery



CONSULTANTS ON PANEL

PAEDIATRICS

Dr Ravi Malik (MBBS, MD)
Dr Harit Prasad (MBBS, MD, Pdi)
Dr Ritu Jain (MBBS, MD)

GYNAECOLOGY

Dr Renu Malik (MBBS, MD)
Dr Meena Malhotra (MBBS, MD)
Dr Rajni (MBBS, MD)
Dr Manju Gupta (MBBS, MS)
Dr Vaishali Saini (MBBS, DGO)
Dr Rupam Arora (MBBS, MD)

DENTAL

Dr Shruti Malik (BDS, MDS)
Dr Annu Saini (BDS, MDS)
Dr Rachit Thakral (BDS, MDS)
Dr Mohit Mangla (BDS, MDS)
Dr Tarun Mittal (BDS, MDS)
Dr Geetika Sharma (BDS)
Dr Shilpa Verma (BDS)

CHILD GASTROENTEROLOGY

Dr S. K Mittal (MBBS, MD)

MEDICINE

Dr A S Talwar (MBBS, MD)
Dr Sunny Uppal (MBBS, MD)
Dr Surendra Rajpal (MBBS, MD)

RESPIRATORY MEDICINE /PULMONOLOGY

Dr Abhinav Bhanot (MBBS, DNB)

LAPAROSCOPY SURGERY

Dr Ajay Jain (MBBS, MS)
Dr Deepak Saran (MBBS, MS)
Dr Pradeep Saini (MBBS, MS)
Dr G. S Garg (MBBS, MS)

ORTHOPAEDICS

Dr Vikas Bhardwaj (MBBS, MS ORTHO, DNB)
Dr Prabhakar Aggarwal (MBBS, MS ORTHO)
Dr KB Tiwari (MBBS, MS ORTHO)
Dr Deepak Kumar Arora (MBBS, MS ORTHO)

EYE/OPTHALMOLOGY

Dr Nidhi Gupta (MBBS, MS, DNB, PGDM)
Dr Himanshu Singh Pundir (MBBS, MS)

ENT

Dr Sharad Kumar Singhi (MBBS, MS)
Dr Prateek Sharma (MBBS, MS)
Dr Ashok Singh (MBBS, MS)
Dr A K Lahiri (MBBS, MS)

RADIOLOGY(ULTRASOUND)

Dr K K Sinha (MBBS, DMRB)
Dr T K Vohra (MBBS, MD)
Dr Rajesh Malhotra (MBBS, MD)
Dr Ashish Tomar (MBBS, MD)

PATHOLOGY

Dr Reema Dahiya (MBBS, MD PATH)
Dr Meenu Aggarwal (MBBS, MD PATH)

ANAESTHESIA

Dr Rajesh Dhall (MBBS, MD)
Dr Rakesh Atrey (MBBS, MD)
Dr R K Arora (MBBS, MD)
Dr Swaraj Garg (MBBS, MD)

DERMATOLOGY

Dr Niharika Jha (MBBS, MD)

PLASTIC & COSMETIC SURGERY

Dr Ayush Jain (MBBS, MS, MCh)

PAEDIATRIC SURGERY

Dr Dharmendra Singh (MBBS, MS, M.Ch)
Dr Satish Aggarwal (MBBS, MS, M.Ch)

PAEDIATRIC NEPHROLOGY

Dr A S Vasudev (MD, Dip.in. Paed.)

NEPHROLOGY

Dr Javed (MBBS, MD, Nephro)

CARDIOLOGY

Dr Nishant Tyagi (MBBS, MD)

NEUROLOGY

Dr Amit Batra (MBBS, MD)

GASTROENTEROLOGY

Dr Deepak Lahoti (MBBS, MD)
Dr Naresh Aggarwal (MBBS, MD)
Dr Ashok Goyal (MBBS, MD)
Dr Ankur Singhal (MBBS, MD)

UROLOGY

Dr Nikhil Sharma (MBBS, Mch)
Dr Ankur Singhal (MBBS, MD)

PSYCHIATRY

Dr Mohit Sharma (MBBS, MD)

PHYSIOTHERAPY

Dr Kirti Dwivedi
Dr Ravi Kumar

NUTRITIONIST

Dr Deepika Kohli
Dr Sakshi Rana

CLINICAL PSYCHOLOGIST

Dr. Sarika Singh

Dr. Shruti Malik

BDS, MDS (Endodontics)

(+91-9899561092)

Name : Vikas

Age/Sex : 41y/M

Date : 11/05/2024

Timings : 10:00 am. to 2:00 pm.
6:00 pm. to 8:30 pm.

For Appointment

(011-45152510
+91-9999254639

CLINICAL EXAMINATION:- Regular check up.

1. TMJ:-

O/E → Stains +
calculus +

2. DENTAL STATUS:

wear facet $\frac{76}{67}$
 $\frac{67}{67}$

- a. Caries Teeth :
- b. Fracture Teeth :
- c. Root Stumps :
- d. Gingivitis :
- e. Periodontitis :
- f. Impacted Teeth :
- g. Malaligned Teeth :

Advised - Oral Prophylaxis,
* Mouth wash - Periogard *
3x/day
Mouth

3. ORAL LESIONS:-

4. DIAGNOSIS:-

5. TREATMENT PLANNING:

6. FOLLOW UP:-

Referral To Other Consultant: Yes/ No

If Yes, please mention the Name:

Doctor's Signature

Donny

Facilities Available :

- ★ MULTI-SPECIALITY HOSPITAL ★ MODULAR FULLY EQUIPPED OT ★ NURSERY ★ LAPROSCOPIC SURGERY
- ★ 24X7 EMERGENCY ★ OPG ★ DENTAL ★ 24X7 DIAGNOSTICS ★ LABOUR ROOM ★ ECHO ★ EEG ★ DIGITAL X-RAY ★ CT SCAN
- ★ ECG ★ ULTRASOUND ★ RICU/ICU ★ ALL SPECIALITY OPD ★ PLASTIC & COSMETIC SURGERY ★ DIALYSIS ★ PHARMACY

GE

MAC600 1.02

ID: 9884861340

1-May-2024 10:09:51

Vikash Kumar

ID: 9884861340

aVR

V1

V4

V1

I

aVL

V2

V5

V2

II

aVF

V3

V6

V3

III

aVF

V3

V6

V4

0.16-20Hz

25.0 mm/s

10.0 mm/mV

50Hz

82 bpm

MAC600 1.02

12SL™ v239

41years

Male

Vent. rate 82 bpm

QRS duration 80 ms

QT/QTc 364/425 ms

PR interval 132 ms

P duration 92 ms

RR interval 731 ms

P-R-T axes 39 20 11

Vikash Kumar

MAC600 1.02

12SL™ v239

± by 2.5s + 1 rhythm ld

Malik Radix HealthCare.

ELECTROCARDIOGRAM

Name: MR. VIKASH KUMAR

Age & Sex: 41 YR/MALE

Ref By: MEDIWHEEL

Date: 11/05/2024

ECG FINDINGS:

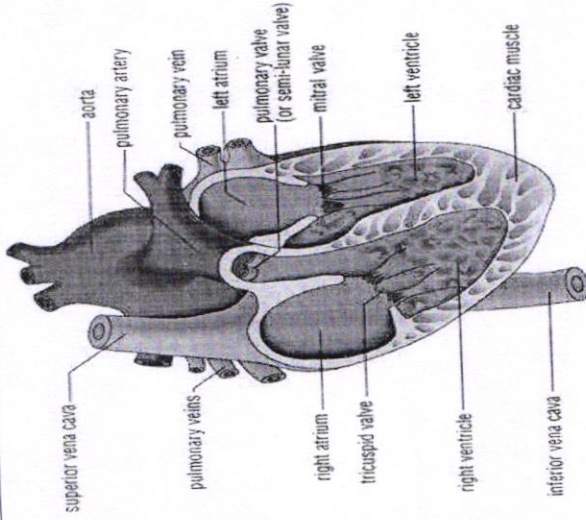
Rate 82 bpm Rhythm Sinus Mechanism Normal


Axis Normal P Wave Normal PR Interval 0.13/Sec

QRS Complex Normal QT Interval Normal Q Wave Normal

ST Segment Normal T Wave Normal

Conclusion Sinus Rhythm, Normal Axis, WNL.



Doctors Signature  **Dr. SHEIKH NAZIR AHMED**
M.D. "Physician"
PGDCC
DMC-46499




Echocardiogram Report

Patient Name	MR. VIKASH KUMAR
Date of Test	11/05/2024
Age	41 YRS/ MALE
Ref. by	MEDIWHEEL

Dimensions	Result	Normal Range
AO (ed)	2.8 cm	(2.1 -3.7cm)
LA (es)	3.2 cm	(2.1 -3.7cm)
RVID (ed)	2.5 cm	(1.1-3.0cm)
LVID (ed)	4.8 cm	(3.6 – 5.5 cm)
LVID (es)	3.3 cm	(2.3-3.9cm)
IVS (ed)	1.1 cm	(0.6 – 1-2 cm)
LVPW (ed)	1.1 cm	(0.6 – 1-2 cm)
EF	58 %	
FS	30 %	(28 % - 42 %)

Impression

- NO REGIONAL WALL MOTION ABNORMALITY SEEN.
- LVEF= 58 %
- NORMAL CHAMBER DIMENSIONS.
- STAGE I LV DIASTOLIC DYSFUNCTION.
- NORMAL COLOR FLOW.
- NO INTRA CARDIAC CLOT/MASS/ VEGETATION/PERICARDIAL EFFUSION SEEN.


Dr. Sheikh Nazir Ahmed
M.D. "Physician" PGDCC
(Consultant Non – Invasive Cardiologist)

Facilities Available

- Multispeciality Hospital - 24 Hours Emergency - X-Ray/ ECG/ Ultrasound/ CT Scan - Dental- Fully Equipped Operation Theatre
- Fully Functional Lab - 24/7 Casualty/ ICU-Nursery 24/7 Pharmacy - Labour Room - All Speciality OPD - Laproscopic Surgery -
ECHO - Plastic Surgery



LAB REPORT

Reg. Date	11/05/2024	Patient Id	2405110002	DOB.	16/08/1982
Name	MR. VIKASH KUMAR	Gender	M	Perm. ID	
Age	41 Yrs. 8 Mn. 26 Day	Panel	MEDIWHEEL	Reported	11/05/2024 17:30:15
Ref. By	MEDIWHEEL				

Test Name	Result	Units	Ref. Range
-----------	--------	-------	------------

ANNUAL PLUS ABOVE 50 M

HAEMATOLOGY

COMPLETE HAEMOGRAM

HAEMOGLOBIN (HB%)	15.0	gm/dl	13 - 18
TOTAL LEUCOCYTE COUNT (TLC)	7,100	/cumm	4000 - 11000
DIFFERENTIAL LEUCOCYTE COUNT (DLC)			
NEUTROPHIL	69	%	40 - 80
LYMPHOCYTE	22	%	28 - 55
MONOCYTE	07	%	02 - 10
EOSINOPHIL	02	%	01 - 06
BASOPHIL	00	%	0 - 0
ESR (WESTEGREN'S METHOD)	10	mm/1st hr.	0 - 10
R B C COUNT	4.72	Millions/cmm	4.247 - 5.4
P.C.V / HAEMATOCRIT	44.6	%	40 - 54
M C V	94.5	fl.	80 - 100
M C H	31.8	Picogram	27.0 - 31.0
M C H C	33.6	gm/dl	33 - 37
PLATELET COUNT	1.98	Lakh/cu mm	1.50 - 4.50

Urine Routine Examination

PHYSICAL EXAMINATION

QUANTITY	30	ml.	
COLOUR	Pale Yellow		Pale Yellow
TRANSPARENCY	Clear		
SPECIFIC GRAVITY	1.025		
PH	6.0		

Checked by : _____
Page 1 Contd...2

If test results are alarming or unexpected, patient is advised to contact the laboratory immediately for possible remedial action.

Facilities Available

- Multispeciality Hospital - 24 Hours Emergency - X-Ray/ ECG/ Ultrasound/ CT Scan - Dental- Fully Equipped Operation Theatre
- Fully Functional Lab - 24/7 Casualty/ ICU-Nursery 24/7 Pharmacy - Labour Room - All Speciality OPD - Laproscopic Surgery - ECHO - Plastic Surgery



LAB REPORT

Reg. Date	11/05/2024	Patient Id	2405110002	DOB.	16/08/1982
Name	MR. VIKASH KUMAR	Gender	M	Perm. ID	
Age	41 Yrs. 8 Mn. 26 Day	Panel	MEDIWHEEL	Reported	11/05/2024 17:30:15
Ref. By	MEDIWHEEL				

Test Name	Result	Units	Ref. Range
-----------	--------	-------	------------

CHEMICAL EXAMINATION

ALBUMIN	Nil		
SUGAR	Nil		

MICROSCOPIC EXAMINATION

PUS CELLS	1-2	/HPF	
RBC'S	Nil	/HPF	
CASTS	Nil		
CRYSTALS	NIL		
EPITHELIAL CELLS	1-2	/HPF	
BACTERIA	Nil		
OTHERS	Nil		

BLOOD GROUP ABO	" B "		
RH TYPING	Positive		

BLOOD SUGAR FASTING	92.45	mg/dl	70 - 100
BLOOD SUGAR PP	97.42	mg/dl	90 - 140

THYROID PROFILE

Free T3 ELFA	3.01	ng/ml	02 - 04
Free T4 ELFA	1.59	ug/dl	0.8 - 2.7
TSH Serum/ELFA	4.510	uIU/ml	0.25 - 5.50 uIU/ml

Interpretation

Clinical Use

- Diagnose Hypothyroidism and Hyperthyroidism

Checked by : _____
Page 2 Contd...3

If test results are alarming or unexpected, patient is advised to contact the laboratory immediately for possible remedial action.

Facilities Available

- Multispeciality Hospital - 24 Hours Emergency - X-Ray/ ECG/ Ultrasound/ CT Scan - Dental- Fully Equipped Operation Theatre
- Fully Functional Lab - 24/7 Casualty/ ICU-Nursery 24/7 Pharmacy - Labour Room - All Speciality OPD - Laproscopic Surgery - ECHO - Plastic Surgery



LAB REPORT

Reg. Date	11/05/2024	Patient Id	2405110002	DOB.	16/08/1982
Name	MR. VIKASH KUMAR	Gender	M	Perm. ID	
Age	41 Yrs. 8 Mn. 26 Day	Panel	MEDIWHEEL	Reported	11/05/2024 17:30:15
Ref. By	MEDIWHEEL				

Test Name	Result	Units	Ref. Range
-----------	--------	-------	------------

- Monitor T4 replacement or T4 suppressive Therapy
- Quantify TSH levels in the subnormal range

Increased Levels : Primary Hypothyroidism Subclinical Hypothyroidism, TSH dependent, Thyroid Hormone Resistance.

Decreased Levels : Grave's Disease, Autonomous Thyroid Hormone Secretion, TSH Deficiency

LIPID PROFILE

TOTAL CHOLESTEROL	185.70	mg/dL	130.0 - 200.0 (<200)
TRIGLYCERIDES	178.70	mg/dL	80.5 - 150.0 (<150)
H D L CHOLESTEROL DIRECT	45.35	mg/dL	35.0 - 60.0 (<40->59)
V L D L	35.7	mg/dL	4.0 - 30. (23-45)
L D L CHOLESTEROL	104.6	mg/dL	50.0 - 150.0 (50-150)
TOTAL CHOLESTEROL / HDL RATIO	4.1		3.3 - 5.1
LDL / HDL CHOLESTEROL RATIO	2.3		1.5 - 3.5
SERUM URIC ACID	5.57	mg/dl	3.4 - 7.0
BLOOD UREA NITROGEN (BUN)	13.20	mg/dl	6.0 - 21.0
SERUM CREATININE	1.30	mg/dl	0.7 - 1.4
BUN/CREAT RATIO	10.1	mg/dl	

LIVER FUNCTION TEST (LFT)

BILIRUBIN TOTAL	2.77	mg/dl	0.2 - 1.2
CONJUGATED (D. BILIRUBIN)	0.59	mg/dl	0.00 - 0.3
UNCONJUGATED (I.D.BILIRUBIN)	2.18	mg/dl	0.2 - 0.9

Checked by : _____
Page 3 Contd...4

If test results are alarming or unexpected, patient is advised to contact the laboratory immediately for possible remedial action.

Facilities Available

- Multispeciality Hospital - 24 Hours Emergency - X-Ray/ ECG/ Ultrasound/ CT Scan - Dental- Fully Equipped Operation Theatre
- Fully Functional Lab - 24/7 Casualty/ ICU-Nursery 24/7 Pharmacy - Labour Room - All Speciality OPD - Laproscopic Surgery - ECHO - Plastic Surgery



LAB REPORT

Reg. Date	11/05/2024	Patient Id	2405110002	DOB.	16/08/1982
Name	MR. VIKASH KUMAR	Gender	M	Perm. ID	
Age	41 Yrs. 8 Mn. 26 Day	Panel	MEDIWHEEL	Reported	11/05/2024 17:30:15
Ref. By	MEDIWHEEL				

Test Name	Result	Units	Ref. Range
SGOT / AST	26.40	IU/L	0 - 35
SGPT / ALT	18.6	IU/L	0 - 35
ALKALINE PHOSPHATASE	130.40	U/L	64 - 306
TOTAL PROTEIN	8.27	gm/dl	6.0 - 8.3
ALBUMIN	4.41	gm/dl	3.2 - 5.0
GLOBULIN	3.86	gm/dl	2.5 - 5.6
A/G RATIO	1.14		0.9 - 2.0
GAMMA GT	20.14	IU/L	0.0 - 45.0
TOTAL PSA Chemiluminescence	0.91	ng/ml	

INTERPRETATION :

Expected Values :

99%	:	of Healthy males	0.0-4.0 ng/ml
80%	:	of Benign prostatic hypertrophy	0.0-4.0 ng/ml
81%	:	of Prostatic Carcinomas	Above 4.0 ng/ml

PSA is reliable tumour marker for already diagnosed prostatic carcinomas. It is uniquely associated only with prostatic tissue, and therefore is specific for it. Baseline levels measured prior to therapeutic intervention and followed later by serial periodical measurements will predict the outcome of therapy. It also helps in early discovery of recurrences, relapses and metastases.

DR. REEMA DAHIYA

Dr. REEMA DAHIYA

M.B.B.S., MD (Path.)

M.D.C.S., MD (Gen.)

Page 4 of 4

Malik Radix Healthcare Pvt. Ltd.

DR. MEENU AGGARWAL
M.B.B.S., MD (Path.)

If test results are alarming or unexpected, patient is advised to contact the laboratory immediately for possible remedial action.

Facilities Available

- Multispeciality Hospital - 24 Hours Emergency - X-Ray/ ECG/ Ultrasound/ CT Scan - Dental- Fully Equipped Operation Theatre
- Fully Functional Lab - 24/7 Casualty/ ICU-Nursery 24/7 Pharmacy - Labour Room - All Speciality OPD - Laproscopic Surgery - ECHO - Plastic Surgery