



**MEDICOVER  
HOSPITALS**

A UNIT OF SAHRUDAYA HEALTHCARE PVT LTD

# Medicover Hospitals

VENKOJIPALAM VISAKHAPATNAM - 530017

ANDHRA PRADESH - INDIA

PHONE NO : 0891-6829999

**Dr. RAKESH P  
MD  
GENERAL PHYSICIAN**

NAME: Mr. Samir Saha AGE 47/4

WT: 74 kg's

HT:

BP: 120/80 mmHg

PR 94/min



**Medicover Hospitals**  
VENKOJIPALAM VISAKHAPATNAM - 530017  
ANDHRA PRADESH - INDIA



**Lab Report**

Patient Name : **Mr. KANCHARAPU SRINIVASULU** Age /Gender : **47 Y(s)/Male**  
 Bill No/ UMR No : **V4BC242011/V4U190273** Referred By : **Dr. CMO**  
 Received Dt : **08-Jun-24 09:07 am** Report Date : **08-Jun-24 10:43 am**  
 Lab No : **120000644883**

<u>Parameter</u>	<u>Result Values</u>	<u>Biological Reference</u>
<b>CBC(COMPLETE BLOOD COUNT)</b>		
<b>RBC</b>		
HAEMOGLOBIN	14.0	13.0 - 17.0 g/dl
R B C COUNT	4.8	4.5 - 5.5 10 <sup>6</sup> /μL
PCV/HCT	40	40 - 50 %
MCV	84	83 - 101 fl
MCH	29	27 - 32 pg
MCHC	+ 35	31.5 - 34.5 g/dL
RDW(cv)	13.0	11.6 - 14.0 %
<b>WBC</b>		
TC (TOTAL LEUCOCYTE COUNT)	6300	4000 - 11000 cells/cumm
<b>DIFFERENTIAL COUNT</b>		
NEUTROPHILS	55	40 - 80 %
LYMPHOCYTES	38	20 - 40 %
MONOCYTES	04	02 - 10 %
EOSINOPHILS	03	00 - 06 %
BASOPHILS	00	00 - 01 %
<b>PLATELET COUNT</b>		
PLATELET COUNT	2.43	1.50 - 4.50 Lakhs/cumm
ESR	08	0 - 10 mm/1st hour
<b>BLOOD GROUPING AND RH</b>		
BLOOD GROUP	" O "	
RH TYPE	POSITIVE	

\*\*\* End Of Report \*\*\*

**Doctor Incharge**

**Dr.MUDUGANTI SRINIVAS**  
MBBS, MD  
CONSULTANT PATHOLOGIST

**Dr.SRUJANA**  
MBBS, MD PATHOLOGY  
CONSULTANT PATHOLOGIST

**Dr.MOHAMMAD SIMI IQBAL**  
M.B.B.S, M.D  
CONSULTANT BIOCHEMIST

Medicover Unit - I  
# 18-1-3, KGH Down, MaharaniPeta,  
Jagadamba Junction, Visakhapatnam,  
Andhrapradesh - 530 002.  
Ph: +91 96526 69351

Medicover Unit - III  
Sry. No. 27, Plot No. 05, BRTS Road,  
Health City, Arliova, Chinnagadiil Mandal,  
Visakhapatnam, Andhrapradesh - 530 040.  
Ph: +91 0891-6677888

Medicover - MVP  
# 1-1-83, Sector-6, Venkojipalem,  
MVP Colony, Visakhapatnam,  
Andhrapradesh-530017.  
Ph: +91 8886655677



# Medicover Hospitals

VENKOJIPALAM VISAKHAPATNAM - 530017  
ANDHRA PRADESH - INDIA



# MEDICOVER HOSPITALS

A UNIT OF SAHRUDAYA HEALTHCARE PVT LTD

## Lab Report

Patient Name	: Mr. KANCHARAPU SRINIVASULU	Age /Gender	: 47 Y(s)/Male
Bill No/ UMR No	: V4BC242011/V4U190273	Referred By	: Dr. CMO
Received Dt	: 08-Jun-24 09:07 am	Report Date	: 08-Jun-24 10:34 am
Lab No	: 120000644884		

Parameters	Result	Biological Reference Intervals
<b>LIPID PROFILE</b>		
TOTAL CHOLESTEROL	230	No risk : < 200 mg/dL Moderate risk : 200 - 239 High risk : > 240
HDL CHOLESTEROL	36	<40 Low >60 High
LDL CHOLESTEROL	* 153	Border line : 100 - 130 mg/dL High : > 130 mg/dL Desirable : < 100 mg/dL 100 - 130 mg/dL
VLDL	41	
SERUM TRYGLYCERIDES	204	Very High : > 500 mg/dL High : >= 200 - 499 mg/dL Border line High : >= 150 - 199 mg/dL Normal : < 150 mg/dL Normal : < 4.0 Low risk : 4.0 - 6.0 High risk : > 6.0
CHO/HDL RATIO	* 6.39	
LDL/HDL RATIO	4.25	
<b>FBS (FASTING BLOOD GLUCOSE)</b>		
FASTING BLOOD GLUCOSE	103	Normal : 70-99 mg/dL Impaired : 100-125 mg/dL Diabetic : >= 126 mg/dL
CREATININE	1.0	0.9 - 1.3 mg/dL
<b>LFT(LIVER FUNCTION TEST)</b>		
TOTAL BILIRUBIN	1.0	< 1.2 mg/dL
DIRECT BILIRUBIN	* 0.3	<= 0.20 mg/dL
INDIRECT BILIRUBIN	0.7	<= 1.0 mg/dL
SGPT (ALT)	* 48	<= 41 U/L
SGOT (AST)	28	<= 40 U/L
ALKALINE PHOSPHATASE (ALP)	49	40 - 129 U/L
TOTAL PROTEINS	7.4	1-2 years : 5.6-7.5 g/dL > 3 years : 6.0-8.0 g/dL Adults : 6.4-8.3 g/dL NewBorn: 0-4 days : 2.8 - 4.4 g/dL Children: 4 days - 14 years : 3.8 - 5.4 g/dL 14-18 years : 3.2 - 4.5 g/dL Adults : 3.5- 5.2 g/dL
SERUM ALBUMIN	5.1	



**Lab Report**

Patient Name : **Mr. KANCHARAPU SRINIVASULU** Age /Gender : **47 Y(s)/Male**  
Bill No/ UMR No : **V4BC242011/V4U190273** Referred By : **Dr. CMO**  
Received Dt : **08-Jun-24 09:07 am** Report Date : **08-Jun-24 10:34 am**  
Lab No : **120000644884**

<b>Parameters</b>	<b>Result</b>	<b>Biological Reference In Method</b>
<b>GLOBULINS</b>	<b>2.3</b>	2.5 - 3.5 g/dL
<b>A/G RATIO</b>	<b>2.2</b>	1.2 - 2.5
<b>HBA1C (GLYCOSYLATED HAEMOGLOBIN)</b>		
<b>HBA1C</b>	<b>5.6</b>	Non -Diabetic : <= 5.6 % Pre Diabetic : 5.7 - 6.4 % Diabetic : >= 6.5 %
<b>T3,T4 AND TSH</b>		
<b>T3</b>	<b>1.04</b>	0.8 - 2.0 ng/mL
<b>T4</b>	<b>7.12</b>	5.1 - 14.1 ug/dL
<b>TSH (THYROID STIMULATING HORMONE)</b>	<b>3.40</b>	0.270 - 4.20 uIU/mL
<b>PSA (PROSTATE SPECIFIC ANTIGEN).</b>		
<b>PROSTATE SPECIFIC ANTIGEN TOTAL (TPSA)</b>	<b>0.460</b>	<b>0.21 - 6.77 ng/mL</b>
<b>GAMMA GT</b>		
<b>GAMMA GLUTAMYL TRANSFERASE (GGT)</b>	<b>46</b>	10 - 71 U/L
<b>BUN (BLOOD UREA NITROGEN)</b>	<b>10</b>	7.0 - 21.0 mg/dL
<b>BUN (BLOOD UREA NITROGEN)</b>	<b>09</b>	
<b>PLBS (POST LUNCH BLOOD GLUCOSE)</b>		
<b>PLBS (POST LUNCH BLOOD GLUCOSE)</b>	<b>158</b>	Normal : 70- 139 mg/dL Impaired : 140 - 199 mg/dL Diabetic : >= 200 mg/dL

\*\*\* End Of Report \*\*\*

Suggested Clinical Correlation \* If necessary, Please discuss

Verified By : : MC0954

Test results related only to the item tested.

No part of the report can be reproduced without written permission of the laboratory.

*Md. Simi Iqbal*

**Dr. MOHAMMAD SIMI IQBAL, M.B.B.S, M.D**

**Dr. MUDUGANTI SRINIVAS**  
MBBS, MD  
CONSULTANT PATHOLOGIST

**Dr. SRUJANA**  
MBBS, MD PATHOLOGY  
CONSULTANT PATHOLOGIST

**Dr. MOHAMMAD SIMI IQBAL**  
M.B.B.S, M.D  
CONSULTANT BIOCHEMIST



**Medicover Hospitals**  
 VENKOJIPALAM VISAKHAPATNAM - 530017  
 ANDHRA PRADESH - INDIA



**Lab Report**

Patient Name	: Mr. KANCHARAPU SRINIVASULU	Age /Gender	: 47 Y(s)/Male
Bill No/ UMR No	: V4BC242011/V4U190273	Referred By	: Dr. CMO
Received Dt	: 08-Jun-24 09:07 am	Report Date	: 08-Jun-24 11:39 am
Lab No	: 240601058		

<u>Parameter</u>	<u>Result Values</u>	<u>Biological Reference</u>
<b>URINE ROUTINE</b>		
<u>CHEMICAL EXAMINATION</u>		
ALBUMIN	NIL	Negative
SUGAR	NIL	Negative
BLOOD	NIL	Absent
<u>MICROSCOPIC EXAMINATION</u>		
PUS CELLS	2-4	/HPF
RBC	NIL	/HPF
EPITHELIAL CELLS	1-2	/HPF
CRYSTALS	NIL	
CASTS	NIL	
OTHERS	NIL	

\*\*\* End Of Report \*\*\*

**Doctor Incharge**

**Dr.MUDUGANTI SRINIVAS**  
 MBBS, MD  
 CONSULTANT PATHOLOGIST

**Dr.SRUJANA**  
 MBBS, MD PATHOLOGY  
 CONSULTANT PATHOLOGIST

**Dr.MOHAMMAD SIMI IQBAL**  
 M.B.B.S, M.D  
 CONSULTANT BIOCHEMIST

Medicover Unit - I  
 # 18-1-3, KGH Down, Maharanipeta,  
 Jagadamba Junction, Visakhapatnam,  
 Andhrapradesh - 530 002.  
 Ph: +91 96526 69351

Medicover Unit - III  
 Sry. No. 27, Plot No. 05, BRTS Road,  
 Health City, Arilova, Chinnagadilli Mandal,  
 Visakhapatnam, Andhrapradesh - 530 040.  
 Ph: +91 0891-6677888

Medicover - MVP  
 # 1-1-B3, Sector-6, Venkojipalem,  
 MVP Colony, Visakhapatnam,  
 Andhrapradesh-530017.  
 Ph: +91 8886655677



**Medicover Hospitals**  
VENKOJIPALAM VISAKHAPATNAM - 530017  
ANDHRA PRADESH - INDIA



**DEPARTMENT OF RADIOLOGY**

<b>Patient Name</b> : Mr. KANCHARAPU SRINIVASULU	<b>Age / Gender</b> : 47 Y(s)/Male
<b>Bill No/ UMR No</b> : V4BC242011/V4U190273	<b>Referred By</b> : Dr. CMO
<b>Received Dt</b> : 08-Jun-24 08:49 am	<b>Report Date</b> : 08-Jun-24 12:09 pm

**X-RAY CHEST PA VIEW**

**FINDINGS**

The cardiac size & configuration appear normal.  
The Aorta and pulmonary vasculature appear normal.  
There is no evidence of mediastinal widening.  
Both the lungs and CP angles are clear.  
The soft tissues and the bones of the rib cage displayed no abnormality.

**IMPRESSION**

- \* Normal study.
- Kindly correlate clinically.

\*\*\* End Of Report \*\*\*

**Dr. VULAPU CHENNAKRISHNA RAO, .**  
**MBBS, DNB**  
**CONSULTANT RADIOLOGIST**



## Medicover Hospitals

VENKOJIPALAM VISAKHAPATNAM - 530017  
ANDHRA PRADESH - INDIA



# MEDICOVER HOSPITALS

A UNIT OF SAHRUDAYA HEALTHCARE PVT LTD.

### DEPARTMENT OF RADIOLOGY

<b>Patient Name</b>	: Mr. KANCHARAPU SRINIVASULU	<b>Age / Gender</b>	: 47 Y(s)/Male
<b>Bill No/ UMR No</b>	: V4BC242011/V4U190273	<b>Referred By</b>	: Dr. CMO
<b>Received Dt</b>	: 08-Jun-24 08:49 am	<b>Report Date</b>	: 08-Jun-24 12:30 pm

### USG ABDOMEN (MALE)

#### LIVER

Measuring 15.7 cm. Enlarged in size with increased echotexture.  
There is no evidence of IHBR/EHBR dilatation seen.  
The portal, hepatic vessels are normal. No S.O.L. noted.

#### GALL BLADDER

Normal in volume and wall thickness.  
No evidence of intraluminal calculi/ masses seen.  
C.B.D appears normal with no intraluminal mass/ calculi.

#### PANCREAS

Head, Body & Tail are identified with normal echopattern & smooth outlines. The pancreatic duct system appears normal. The peri pancreatic fat planes are well preserved.

#### SPLEEN

Measuring 9.6 cm in cranio caudal directions with normal homogenous echotexture.

#### RIGHT KIDNEY

Measuring 9.6 x 4.5 cm. Normal in location, size with echopattern  
Cortico Medullary differentiation is normal  
No evidence of mass / calculi / hydroureteronephrosis seen.

#### LEFT KIDNEY

Measuring 9.9 x 5.3 cm. Normal in location, size, echopattern.  
Cortico Medullary differentiation is normal  
No evidence of mass / calculi / hydroureteronephrosis seen.  
No evidence of suprarenal / retroperitoneal mass noted.

#### URINARY BLADDER

Normal in volume and wall thickness.  
No intraluminal mass / calculi noted.

#### PROSTATE

Measuring 14 cc. Normal in size and echopattern.

No evidence of ascites/ pleural effusion seen.  
No detectable bowel pathology seen.

#### IMPRESSION

**\* Fatty hepatomegaly.**

\*\*\* End Of Report \*\*\*



# Medicover Hospitals

VENKOJIPALAM VISAKHAPATNAM - 530017  
ANDHRA PRADESH - INDIA



# MEDICOVER HOSPITALS

A UNIT OF SAHRUDAYA HEALTHCARE PVT LTD.

## DEPARTMENT OF RADIOLOGY

<b>Patient Name</b>	: Mr. KANCHARAPU SRINIVASULU	<b>Age /Gender</b>	: 47 Y(s)/Male
<b>Bill No/ UMR No</b>	: V4BC242011/V4U190273	<b>Referred By</b>	: Dr. CMO
<b>Received Dt</b>	: 08-Jun-24 08:49 am	<b>Report Date</b>	: 08-Jun-24 12:30 pm

**Dr. VULAPU CHENNAKRISHNA RAO, .**  
**MBBS, DNB**  
CONSULTANT RADIOLOGIST



PATIENT ID : 190273  
PATIENT NAME : MR KANCHARAPU SRINIVASULU 47/M

Summary Report

Report time :  
June 08, 2024 02:07 pm

PROTOCOL : BRUCE  
PATIENT HEIGHT : 175 Cm  
PATIENT WEIGHT : 74.00 Kg  
PATIENT ADD :  
OBJECT OF TEST : Routine check up  
RISK FACTOR :  
ACTIVITY :  
MEDICATION :  
BRIEF HISTORY :  
OTHER INVESTIGATION :  
REASON FOR TERMINATION : ACHIVED THR  
EXERCISE TOLERANCE :  
EXERCISE INDUCED ARRHYTHMIA :  
HAEMO RESPONSE :  
CHRONO RESPONSE :  
FINAL IMPRESSION : GOOD EXERCISE TOLERANCE  
TEST NEGATIVE FOR STRESS INDUCED ISCHEMIA

Ref. By : Not Applicable  
( Not Applicable )

DR ASHWIN KUMAR PANDA  
DNB(DELHI) DM(NIMS HYD)

K SRINIVASULU

Male

47 Years

WELLNESS

Rate 83 SINUS RHYTHM.....normal P axis, V-rate 50-99  
 . PROBABLE LEFT ATRIAL ABNORMALITY.....P >50ms, <-0.10mV V1  
 . BASELINE WANDER IN LEAD(S) V2

PR 160  
 QRSD 90  
 QT 344  
 QTc 405

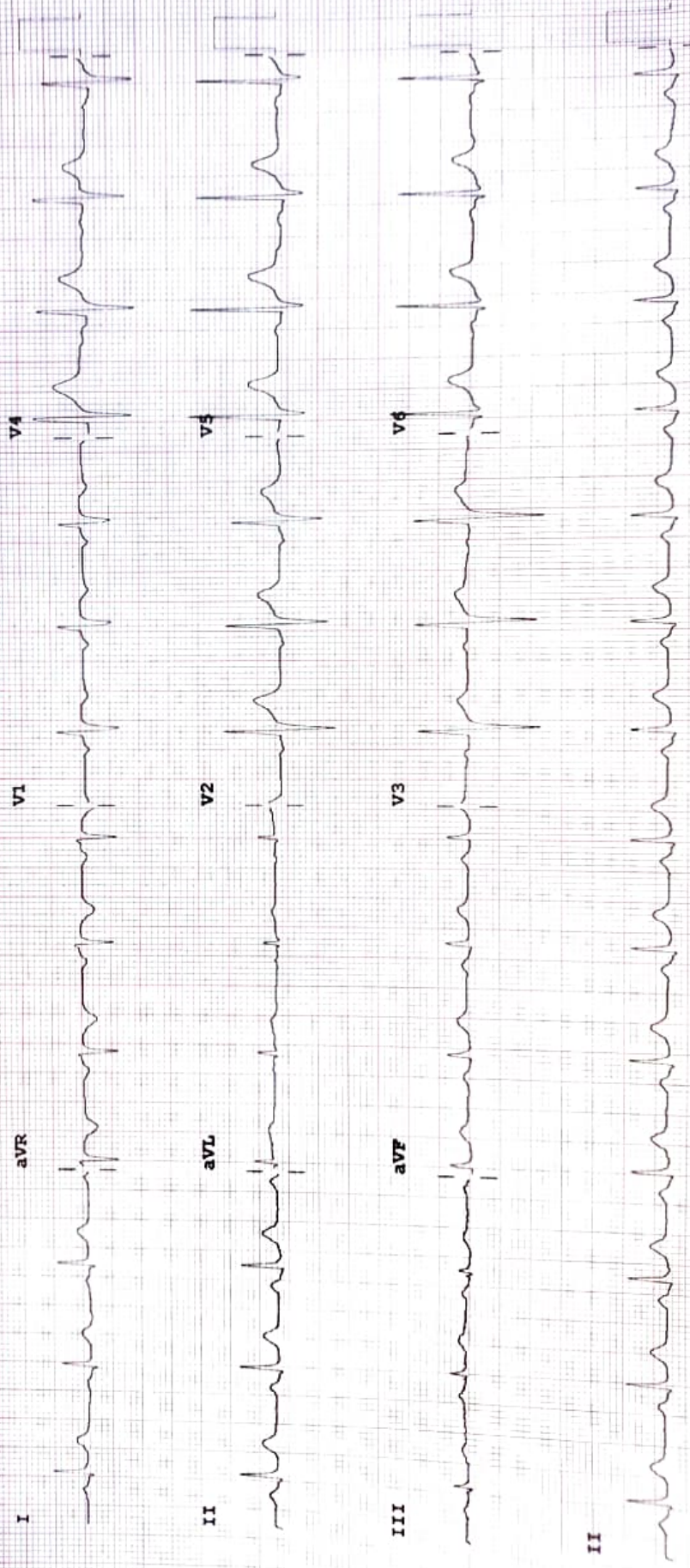
--AXIS--

P 67  
 QRS 46  
 T 43

12 Lead; Standard Placement

- BORDERLINE ECG -

Unconfirmed Diagnosis



Device: Speed: 25 mm/sec Limb: 10 mm/mV Chest: 10.0 mm/mV

F 50~ 0.50~ 40 Hz W

PH090A CL