



Dr. KUNTILLA AMULYA
MBBS,MD (GENERAL MEDICINE)
CONSULTANT GENERAL MEDICINE

Out Patient Department



MEDICOVER
HOSPITALS

A unit of Sahrudaya Health Care Srikakulam Pvt. Ltd.

UMR No : SKU90553	Name : Mr. ATMARAM SENAPATY
Consultation Date : 25-May-2024	Age/Gender : 40 Year(s) / Male
Valid Upto :	Sponsor : PHASORZ TECHNOLOGIES PRIVATE L
	Visit Type : NORMAL

for routine health check
 O/E - Pt certain
 and
 for surgery

Height	: cms
Weight	: 65 kgs
BMI	: kg/m2
Temp	: F
Pulse Rate	: 99 bpm
Resp. Rate	: bpm
BP	: 133/84 mm of Hg
Pain Score	:
Natritional Status	:

HA 3mmE
 Pasy Thyroid
 probe

- ① T. Thyroxine 50 (90)
- ② T. Nurocet 500 2007 (10)
- ③ T. Parony 0.1R 400 (10)
- ④ T. Ravel 100 mg (10)



ECHO CARDIOGRAPHIC REPORT



Name : Almaran Senapath

Age : 40

Sex : male

UMR No.: 90553

IP No.:

DATE : 23/5/24

ECHO NO.:

REF BY :

DONE BY :

DIAGNOSIS

MITRAL VALVE : |

AORTIC VALVE : |

PULMONARY VALVE : | (nl)

TRICUSPID VALVE : |

LEFT ATRIUM : 3.4cm

LEFT VENTRICLE : EDD: 6.4 EDV EF 64% IVS (D) 1.0cm
ESD: 2.9 ESV %FS PW (D) 1.0cm

RIGHT ATRIUM : |

RIGHT VENTRICLE : | (nl)

AORTA : 2.7cm

PULMONARY ARTERY : | (nl) AJV: 1.30ml/sec

I.A.S 103 : Intact PJV: 0.80ml/sec

SVC / IVC / CS : | RVSP: 30mmHg

PERICARDIUM : | (nl) new : 6.2A

DOBPLER STUDY : |

Normal sized cardiac chambers
 NO Rxms
 Normal w systolic function
 Trace MR
 Reduced w compliance
 NO Ps / NO clms / NO ov

CONCLUSIONS

SIGNATURE



SANKAR FOUNDATION EYE HOSPITAL AND INSTITUTE

Paidi Srinivasa Complex
Kushalapuram, Venkatapuram Village
Near Simhadwaram
Srikakulam-532410

Prescription

Patient ID	514656	Visit Date	25/May/2024
Patient Name	MR. ATMARAM. SENAPATY	Age/Sex	40 yrs / M
Payor Name	WALK IN	Contact No.	7440044707
Patient Address	AT-BADAPATSUNDARPUR, CUTTAK, ODISHA.		

Present Complaints

Routine Eye Check Up.

Vision	Distance Vision		Near Vision	
	Right Eye	Left Eye	Right Eye	Left Eye
Unaided	6/9	6/9	N6	N6
With Pinhole	6/6	6/6		
Best Correct	6/6	6/6		

Method (IOP)	IOP Time	IOP (RE)	IOP (LE)	Corrected IOP(RE)	Corrected IOP(LE)	CCT (RE)	CCT (LE)
NCT	01:16	11	10				

Examination Details

Adnexa :- normal in both eyes

Conjunctiva :- normal in both eyes

Cornea :- clear in right eye, CLEAR in left eye

Anterior Chamber :- ND in both eyes

Iris :- NCP in both eyes

Pupil :- NSRL in both eyes

Lens :- clear in both eyes

Fundus :- WNL in both eyes

Diagnosis

NORMAL

Plan of Care :

NORMAL

Next Review SOS.

Doctor's Signature

Dr B. Sumanjali

Rate 70 . Age not entered, assumed to be 50 years old for purpose of ECG interpretation
 PR 122 . Sinus rhythm.....normal P axis, V-rate 50- 99
 QRS 102 . ST elev, probable normal early repol pattern.....ST elevation, age<55
 QT 361
 QTc 390

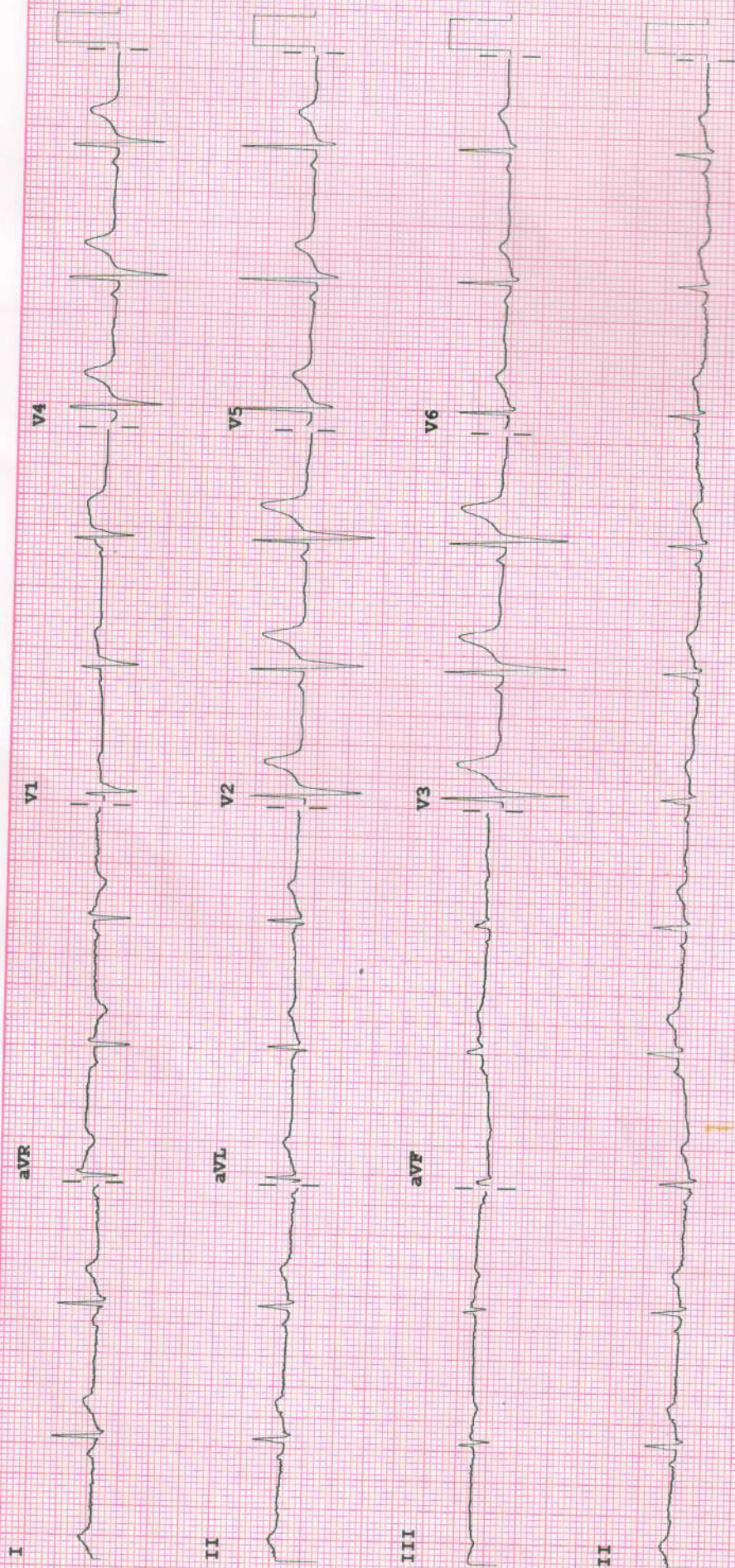
--AXIS--

P 4
 QRS 41
 T 8

12 Lead; Standard Placement

- NORMAL ECG -

Unconfirmed Diagnosis



Device:

Speed: 25 mm/sec Limb: 10 mm/mV Chest: 10.0 mm/mV

F 60~ 0.15-100 Hz

100B CL

P?



MEDICOVER HOSPITALS

Sy.No.73/3 to 16,Door No.16-13-166,167,
Opp.Prakruthi Aventures, New Bridge Road,

DEPARTMENT OF RADIOLOGY



MEDICOVER HOSPITALS

A unit of Sahrudaya Health Care Srikakulam Pvt. Ltd.

Patient Name	: Mr. ATMARAM SENAPATY	Age /Sex	: 40 Y(s)/Male
Bill Date	: 25-May-2024 09:26 AM	UMR No.	: SKU90553
Received Date	: 25-May-2024 9:26 AM	Bill No.	: SKB128749
Report Date	: 25-May-2024 12:22 PM	Result No	: RES300520 / 0
Ref By	: DR.KUNTILLA AMULYA MBBS,MD (GENERAL MEDICINE)	Org.Name	: PHASORZ TECHNOLOGIES PRIVATE

ULTRASOUND ABDOMEN WITH PELVIS

FINDINGS

Liver : Normal in size, shape and increased echotexture. Anechoic cyst measuring 10 x 10 mm noted in the segment V of right lobe of liver. No evidence of any intrahepatic biliary dilatation.

Gall Bladder is well distended. Wall thickness is normal. No evidence of any peri-gall bladder collections. No evidence of calculi or sludge. CBD and PV are normal.

Pancreas is normal in size, shape and echotexture. No evidence of focal lesion or calcification.

Spleen : Normal in size, shape and echotexture. No evidence of focal lesion or calcification.

Right kidney is located in the right iliac fossa. Normal in size (8.4 x 4.6 cm). Cortical echotexture is normal and corticomedullary differentiation is normal. No evidence of any pelvicalyceal dilatation. No calculi seen.

Left kidney : Normal in size (9.7 x 5.4 cm). Cortical echotexture is normal and corticomedullary differentiation is normal. No evidence of any pelvicalyceal dilatation. No calculi seen.

Urinary bladder is well distended. No calculi seen.

Prostate is normal in size. No evidence of focal lesions.

No evidence of any free fluid in peritoneal cavity and pelvis.

IMPRESSION

- * **Fatty liver grade I.**
- * **Simple hepatic cyst in the right lobe of liver.**
- * **Ectopic right kidney in the right iliac fossa.**

*** End Of Report ***

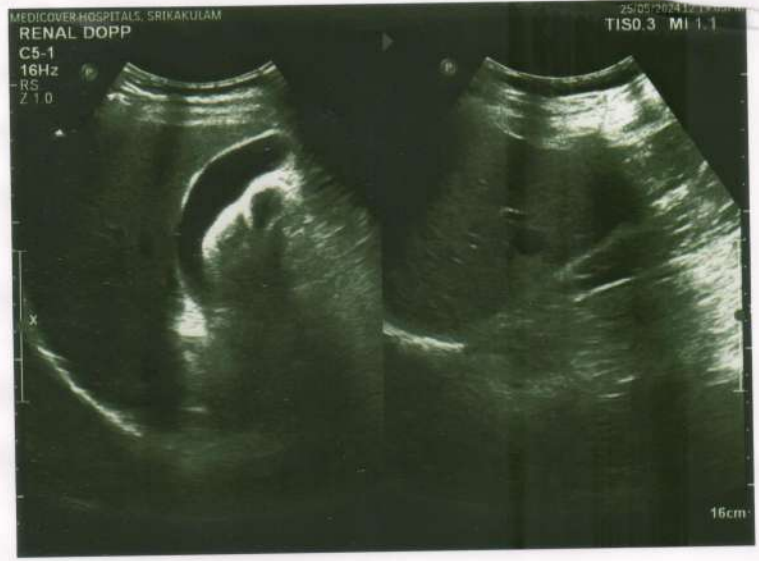DR.VENKATESH BASINA, MBBS MD DMRD
CONSULTANT RADIOLOGIST

The sonological diagnosis suggested here is not by appropriate means. Based on the ultrasound findings and their significance in the respective clinical context, wherever relevant, appropriate further

Verified By :

Approved By :

Dispatched By :





MEDICOVER HOSPITALS

Sy.No.73/3 to 16,Door No.16-13-166,167,
Opp.Prakruthi Aventures, New Bridge Road,

Department Of Laboratory



MEDICOVER HOSPITALS

A unit of Sahrudaya Health Care Srikakulam Pvt. Ltd.

Name : Mr. ATMARAM SENAPATY	Age /Sex : 40 Y(s)/Male
Bill Date : 25-May-2024 09:26 AM	UMR No. : SKU90553
Spl Rvs Dt : 25-05-2024 09:50:39	Bill No. : SKB128749
Rept. Dt : 25-May-2024 10:28 AM	Result No : RES300427
Ref By : Dr.KUNTILLA AMULYA MBBS,MD (GENERAL MEDICINE)	

Parameters	Result	Biological Reference Inte	Method
COMPLETE BLOOD COUNT			
HAEMOGLOBIN	: 16.2 g/dl	13.0 - 18.0 g/dl	Automated Cell Counter cyanmethemoglobin
PCV (PACKED CELL VOLUME)	: 48.2 %	40.0 - 50.0 %	Automated Cell Counter Calculated
WHITE BLOOD CELLS (WBC)	: 7800 Cells/cumm.	4000 - 11000 Cells/cumm.	Automated Cell Counter Electrical Impedance
RED BLOOD CELLS	: 5.59 million/ul	4.2 - 6.5 million/ul	Automated Cell Counter Electrical Impedance
PLATELET COUNT	: 3.3 Lakhs/cumm.	1.5 - 4.5 Lakhs/cumm.	Automated Cell Counter Electrical Impedance
MCV (MEAN CORPUSCULAR VOLUME)	: 86 fl	83 - 101 fl	Automated Cell Counter Calculated
MCH (Mean Corpuscular Hemoglobin)	: 28.9 pg	27 - 32 pg	Automated cell counter calculated
MCHC (Mean Corpuscular Hemoglobin Concentration)	: 33.5 %	31.0 - 34.0 %	Automated cell counter calculated
NEUTROPHILS	:* 41 %	45 - 75 %	Microscopy
LYMPHOCYTES	:* 50 %	20 - 45 %	Microscopy
MONOCYTES	: 06 %	1 - 10 %	Microscopy
EOSINOPHILS	: 03 %	1 - 6 %	Microscopy

BLOOD GROUPING RH TYPING

BLOOD GROUP : " O "

Rh TYPING : POSITIVE

COMPLETE URINE TEST

COLOUR	: PALE YELLOW	Pale yellow
PH	: 6.5	5.0 - 7.5
SP. GRAVITY	: 1.015	1.010 - 1.025
BILE SALTS	: NEGATIVE	Negative
BILE PIGMENTS	: NEGATIVE	Negative
KETONE BODIES	: NEGATIVE	Negative
BLOOD	: ABSENT	Absent
SUGAR	: NIL	Negative



MEDICOVER HOSPITALS

Sy.No.73/3 to 16,Door No.16-13-166,167,
Opp.Prakruthi Aventures, New Bridge Road,



MEDICOVER HOSPITALS

A unit of Sahrudaya Health Care Srikakulam Pvt. Ltd.

Parameters	Result	Biological Reference	Inte	Method
ALBUMIN	: 2+	Negative		
MICROSCOPIC EXAMINATION				
PUS CELLS	: * 20-25/HPF	1 - 2		
RBC	: 0-1/HPF	0.0 - 1.0		
EPITHELIAL CELLS	: * 3-5/HPF	0 - 4		
CASTS	: NIL	Absent		
CRYSTALS	: NIL	Absent		
BLOOD UREA NITROGEN (BUN)				
BLOOD UREA	: 17.5 mg/dL	15.0 - 45.0 mg/dL		Urease-GLDH(Enzymatic UV)
BLOOD UREA NITROGEN (BUN)	: 8.18 mg/dL	7.0 - 21.0 mg/dL		
LIPID PROFILE				
TOTAL CHOLESTEROL	: 205.0 mg/dL	Border line : 200 - 240 mg/dL Desirable : < 200 mg/dL High : > 240 mg/dL	CHOD-PAP	
SERUM TRYGLYCERIDES	: 309.0 mg/dL	Border line : 200 - 240 mg/dL Desirable : < 200 mg/dL High : > 400 mg/dL	Lipoprotein Lipase	
HDL CHOLESTEROL	: 36.4 mg/dL	Desirable : >= 40 mg/dL	Direct measure-PEG	
LDL CHOLESTEROL	: 106.8 mg/dL	Border line : 100 - 130 mg/dL Desirable : < 100 mg/dL High : > 130 mg/dL		
VLDL	: * 61.8 mg/dL	0 - 40 mg/dL		
NON HDL CHOLESTEROL	: * 168.6 mg/dl	< 130 mg/dl		
TOT CHOL/HDL RATIO	: * 5.63	Low Risk : 3.3 - 4.4 Average Risk : 4.5 - 7.1 Moderate Risk : 7.2 - 11.0		
LDL/HDL RATIO	: 2.93	< 3.0		
HDL/LDL RATIO	: 0.34	> 0.3		
COMMENTS	:			

FBS (FASTING BLOOD GLUCOSE)

FASTING BLOOD GLUCOSE	: 88 mg/dL	70 - 110 mg/dL	Hexokinase
CREATININE	: 0.94 mg/dl	0.4 - 1.4 mg/dl	Enzymatic
		0.4 - 1.4 mg/dl	

LIVER FUNCTION TESTS (LFT)

TOTAL BILIRUBIN	: 0.731 mg/dL	0.2 - 1.0 mg/dl	Diazotization
DIRECT (CONJUGATED) BILIRUBIN	: 0.222 mg/dL	0.0 - 0.25 mg/dL	Diazotization



MEDICOVER HOSPITALS

Sy.No.73/3 to 16,Door No.16-13-166,167,
Opp.Prakruthi Aventures, New Bridge Road,



MEDICOVER HOSPITALS

A unit of Sahrudaya Health Care Srikakulam Pvt. Ltd.

Parameters	Result	Method
INDIRECT BILLIRUBIN	: 0.51	
SGOT (AST)	: 30.7 U/L	9 - 48 U/L Uv kinetic with P5P
SGPT (ALT)	: * 54.6 U/L	0.0 - 50.0 U/L Uv kinetic with P5P
ALKALINE PHOSPHATASE (ALP)	: 124 U/L	40 - 129 U/L p-NPP AMP Buffer
TOTAL SERUM PROTEINS	: 8.09 g/dL	6.4 - 8.2 g/dL Biuret reaction
SERUM ALBUMIN	: * 5.23 g/dL	3.2 - 4.6 g/dL Bromocresol purple
GLOBULINS	: 2.86	
A/G RATIO	: 1.83	0.8 - 2.0
SERUM URIC ACID	: 6.9 mg/dL	3.5 - 7.2 mg/dL uricase

Thyroid Profile

TRI-IODO THYRONINE (T3)	: 1.42 ng/mL	0.51 - 1.65 ng/mL	Chemiluminescence
THYROXINE (T4)	: 8.09 ug/dL	4.5 - 12.5 ug/dL	Chemiluminescence
THYROID STIMULATING HORMONE (TSH)	: * 8.40 μ IU/mL	0.35 - 4.94 μ IU/mL	Chemiluminescence
PROSTATE SPECIFIC ANTIGEN (PSA)	: 0.36 ng/mL	0.21 - 6.77 ng/mL	Enzyme Linked Fluorescent assay

BUN / CREATININE RATIO

BLOOD UREA NITROGEN (BUN)	: 8.18 mg/dL	7.0 - 21.0 mg/dL	Urease kinetic
CREATININE	: 0.94 mg/dl	0.4 - 1.4 mg/dl	Enzymatic
BUN/CREATININE RATIO	: 8.7		CALCULATION

ESR	: * 20 mm/hour	0 - 9 mm/hour	WESTERGREN'S
-----	----------------	---------------	--------------



MEDICOVER HOSPITALS

Sy.No.73/3 to 16,Door No.16-13-166,167,
Opp.Prakruthi Aventures, New Bridge Road,



MEDICOVER HOSPITALS

A unit of Sahrudaya Health Care Srikakulam Pvt. Ltd.

HbA1c

: 5.3 %

indicate diabetes : > 6.5 %
NORMAL : 4.0 - 6.0 %
increased risk of diabetes:

Immunoturbidimetric
: > 6.0 %

*** End Of Report ***

Dr. KONAPALA SUDHEER, MBBS, DCP,DNB (
CONSULTANT PATHOLOGIST

* Suggested Correlate Clinically

Verified By : 16321

Approved By : FTC1028

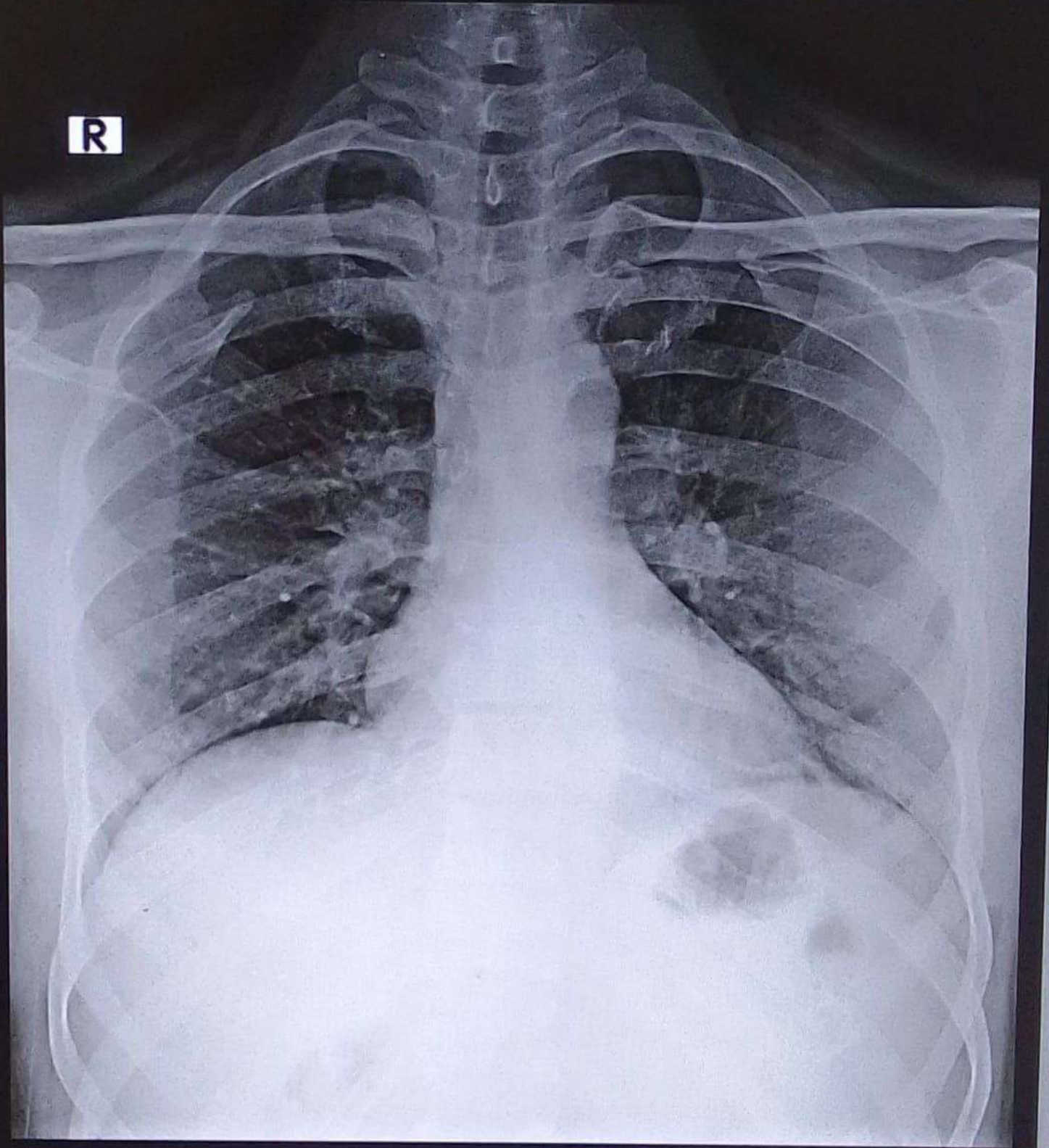
Dispatched By : 20833

Opp. Prakruthi Aventures, New Bridge Road, Srikakulam, Andhra Pradesh - 532005, India

Release Date : 25-05-2024 (5:06 PM)
For appointment :T: +91 40 6833 4455,
info@medicoverhospitals.in

www.medicoverhospitals.in

R



**ATMARAM SENAPATY 40Y SKU90553 CHEST PA 5/25/2024 DR K AMULYA
MEDICOVER HOSPITAL, SRIKAKULAM.**