



Dr. KUNTILLA AMULYA
 MBBS, MD (GENERAL MEDICINE)
 CONSULTANT GENERAL MEDICINE

Out Patient Department



MEDICOVER
 HOSPITALS

A unit of Sahrudaya Health Care Srikakulam Pvt. Ltd.

UMR No : SKU90556	Name : Mr. NAVIN ROSHAN XESS
Consultation Date : 25-May-2024	Age/Gender : 41 Year(s) / Male
Valid Upto :	Sponsor : PHASORZ TECHNOLOGIES PRIVATE L
	Visit Type : NORMAL

to medical Specialist Attn

O/E Patient
 and

July 2024

Height	:	cms
Weight	:	61 kgs
BMI	:	kg/m ²
Temp	:	F
Pulse Rate	:	94 bpm
Resp. Rate	:	bpm
BP	:	142/103 mm of Hg
Pain Score	:	
Nutritional Status	:	

RA 2 days ESR & CRP
Refer to cardiologist

- ① T. Rosavel 10mg on H₁
 (A. 00pm) ②
- ② T. Udiliv 300mg 30
 (10)



ECHO CARDIOGRAPHIC REPORT



Name : Navin roshan xen

Age : 41

Sex : male

UMR No.: 90556

IP No.:

DATE : 25/5/24

DIAGNOSIS

ECHO NO.:

REF BY:

DONE BY:

MITRAL VALVE : 10

AORTIC VALVE : calcified

PULMONARY VALVE : 10

TRICUSPID VALVE : 10

LEFT ATRIUM : 3.6cm

LEFT VENTRICLE : EDD: 4.5 EDV : 60+ IVS(D) 1.1 cm
ESD: 3.0 ESV : %FS PW(D) 1.1 cm

RIGHT ATRIUM : 10

RIGHT VENTRICLE : 10

AORTA : 2.8cm AV4 : 40/33 mm/4tr

PULMONARY ARTERY : 10 AVJ :

I.A.S 10 : intact PJV : 0.90m/sec

SVC / IVC / CS : 10 RVSP : 35 mm Hg

PERICARDIUM : 10

DOPPLER STUDY : 10

? Bicuspid valve
 calcified Aortic valve
 mild to moderate AS + mild AR
 NO L/RMA
 normal biventricular function
 NO PE / NO CLON / NO LVOT

CONCLUSIONS

SIGNATURE

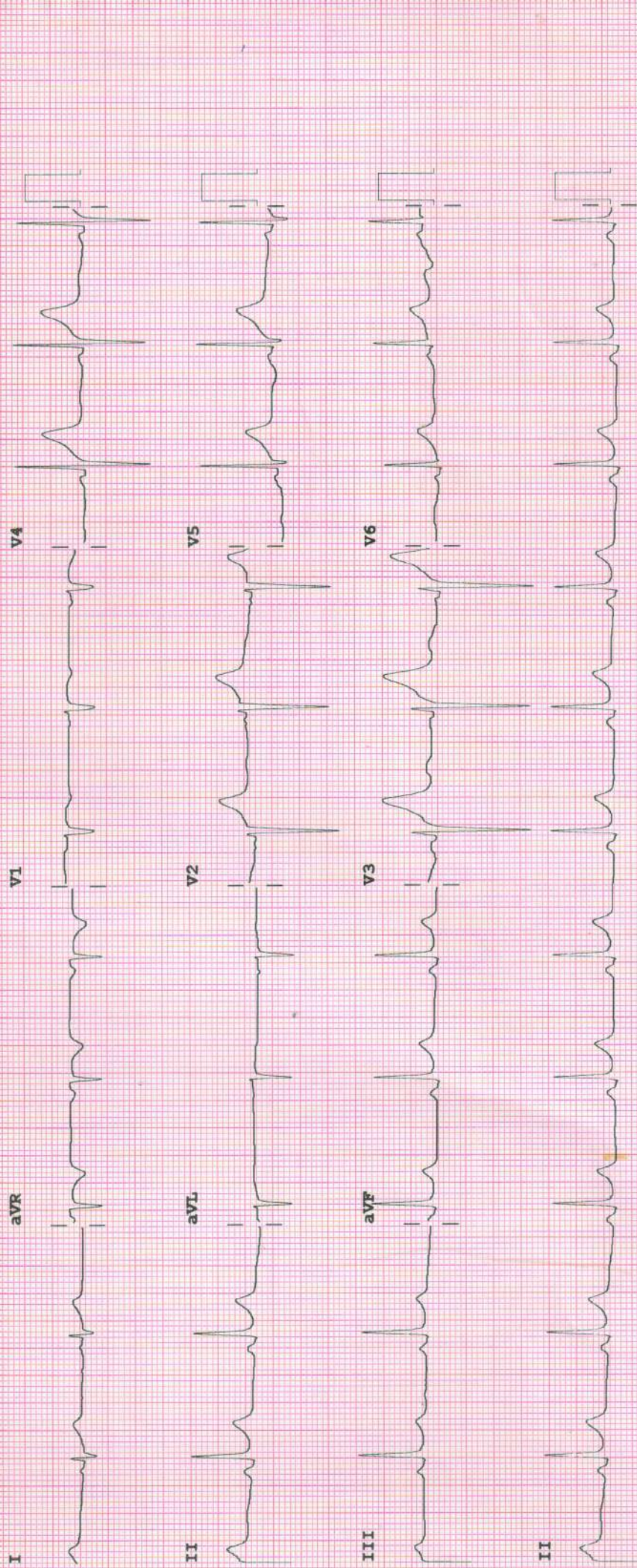
Rate 66 . Age not entered, assumed to be 50 years old for purpose of ECG interpretation
 PR 130 . Sinus rhythm.....normal P axis, V-rate 50- 99
 QRSD 86 . ST elevation suggests acute pericarditis.....ST >0.10mV, ant/lat/inf
 QT 370 . Baseline wander in lead(s) V1, V5, V6
 QTc 388 . Partial missing lead(s): V2

--AXIS--
 P 71
 QRS 89
 T 53

12 Lead; Standard Placement

- ABNORMAL ECG -

Unconfirmed Diagnosis



Device: Speed: 25 mm/sec Limb: 10 mm/mV Chest: 10.0 mm/mV F 60~ 0.15-100 Hz 100B CL P?



MEDICOVER HOSPITALS

Sy.No.73/3 to 16,Door No.16-13-166,167,
Opp.Prakruthi Aventures, New Bridge Road,

DEPARTMENT OF RADIOLOGY



Patient Name	: Mr. NAVIN ROSHAN XESS	Age /Sex	: 41 Y(s)/Male
Bill Date	: 25-May-2024 09:40 AM	UMR No.	: SKU90556
Received Date	: 25-May-2024 9:40 AM	Bill No.	: SKB128751
Report Date	: 25-May-2024 12:27 PM	Result No	: RES300526 / 0
Ref By	: DR.KUNTILLA AMULYA MBBS,MD (GENERAL MEDICINE)	Org.Name	: PHASORZ TECHNOLOGIES PRIVATE

ULTRASOUND ABDOMEN WITH PELVIS

FINDINGS

Liver : Normal in size, shape and increased echotexture. No evidence of any focal solid or cystic lesions. No evidence of any intrahepatic biliary dilatation.
Gall Bladder is well distended. Wall thickness is normal. No evidence of any peri-gall bladder collections. No evidence of calculi or sludge. CBD and PV are normal.
Pancreas is normal in size, shape and echotexture. No evidence of focal lesion or calcification.
Spleen : Normal in size, shape and echotexture. No evidence of focal lesion or calcification.
Right kidney : Normal in size. Cortical echotexture is normal and corticomedullary differentiation is normal. No evidence of any pelvicalyceal dilatation. No calculi seen.
Left kidney : Normal in size. Cortical echotexture is normal and corticomedullary differentiation is normal. No evidence of any pelvicalyceal dilatation. No calculi seen.
Urinary bladder is well distended. No calculi seen.
Prostate is enlarged in size. Measures 27 cc in volume. No evidence of focal lesions. No evidence of any free fluid in peritoneal cavity and pelvis.

IMPRESSION

- * Fatty liver grade I.
- * Grade I prostatomegaly.

*** End Of Report ***

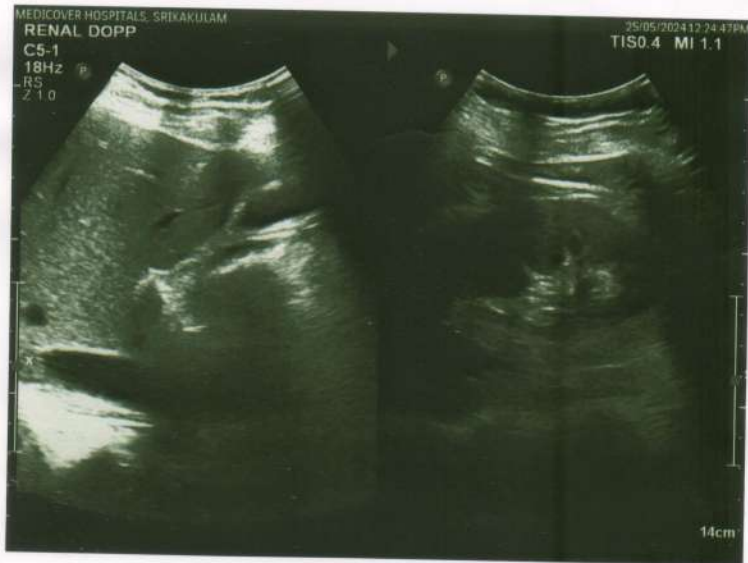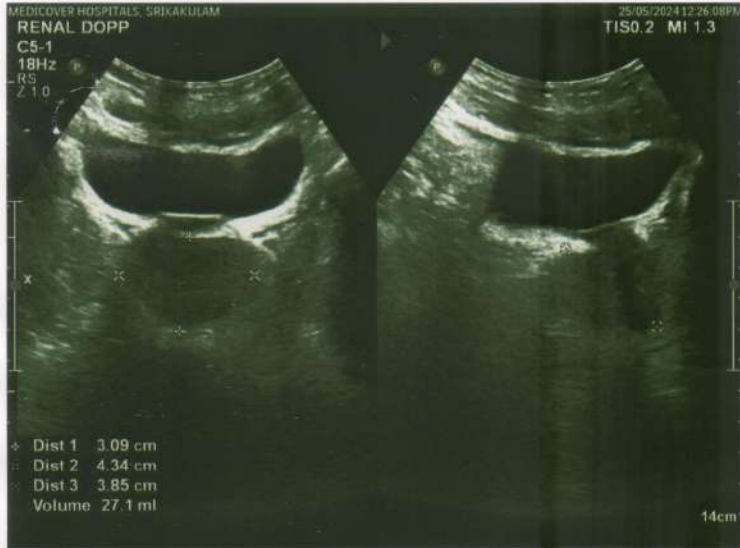
DR.VENKATESH BASINA, MBBS MD DMRD
CONSULTANT RADIOLOGIST

The sonological diagnosis suggested here is not by appropriate means. Based on the ultrasound findings and their significance in the respective clinical context, wherever relevant, appropriate furt

Verified By :

Approved By :

Dispatched By :





MEDICOVER HOSPITALS

Sy.No.73/3 to 16,Door No.16-13-166,167,
Opp.Prakruthi Aventures, New Bridge Road,

Department Of Laboratory



MEDICOVER HOSPITALS

A unit of Sahrudaya Health Care Srikakulam Pvt. Ltd.

Name : Mr. NAVIN ROSHAN XESS	Age /Sex : 41 Y(s)/Male
Bill Date : 25-May-2024 09:40 AM	UMR No. : SKU90556
Spl Rvs Dt : 25-05-2024 09:59:39	Bill No. : SKB128751
Rept. Dt : 25-May-2024 10:33 AM	Result No : RES300429
Ref By : Dr.KUNTILLA AMULYA MBBS,MD (GENERAL MEDICINE)	

Parameters	Result	Biological Reference	Inte Method
COMPLETE BLOOD COUNT			
HAEMOGLOBIN	: 13.4 g/dl	13.0 - 18.0 g/dl	Automated Cell Counter
PCV (PACKED CELL VOLUME)	: 43.6 %	40.0 - 50.0 %	cyanmethemoglobin Automated Cell Counter
WHITE BLOOD CELLS (WBC)	: 5800 Cells/cumm.	4000 - 11000 Cells/cumm.	Calculated
RED BLOOD CELLS	: 6.37 million/ul	4.2 - 6.5 million/ul	Automated Cell Counter
PLATELET COUNT	: * 1.08 Lakhs/cumm.	1.5 - 4.5 Lakhs/cumm.	Electrical Impedance
MCV (MEAN CORPUSCULAR VOLUME)	: * 68 fl	83 - 101 fl	Automated Cell Counter
MCH (Mean Corpuscular Hemoglobin)	: * 21.0 pg	27 - 32 pg	Electrical Impedance
MCHC (Mean Corpuscular Hemoglobin Concentration)	: * 30.7 %	31.0 - 34.0 %	Automated Cell Counter
NEUTROPHILS	: 67 %	45 - 75 %	Calculated
LYMPHOCYTES	: 25 %	20 - 45 %	Automated cell counter
MONOCYTES	: 06 %	1 - 10 %	calculated
EOSINOPHILS	: 02 %	1 - 6 %	Automated cell counter calculated Microscopy

BLOOD GROUPING RH TYPING

BLOOD GROUP : " O "

Rh TYPING : POSITIVE

Thyroid Profile

TRI-IODO THYRONINE (T3) : 1.48 ng/mL
0.51 - 1.65 ng/mL
Chemiluminescence

THYROXINE (T4) : 9.62 ug/dL
4.5 - 12.5 ug/dL
Chemiluminescence



MEDICOVER HOSPITALS

Sy.No.73/3 to 16,Door No.16-13-166,167,
Opp.Prakruthi Aventures, New Bridge Road,



MEDICOVER HOSPITALS

A unit of Sahrudaya Health Care Srikakulam Pvt. Ltd.

Parameters	Result	Biological Reference	Method
THYROID STIMULATING HORMONE (TSH)	: 1.82 μ IU/mL	0.35 - 4.94 μ IU/mL	Chemiluminescence
COMPLETE URINE TEST			
COLOUR	: PALE YELLOW	Pale yellow	
PH	: 6.0	5.0 - 7.5	
SP. GRAVITY	: 1.010	1.010 - 1.025	
BILE SALTS	: NEGATIVE	Negative	
BILE PIGMENTS	: NEGATIVE	Negative	
KETONE BODIES	: NEGATIVE	Negative	
BLOOD	: ABSENT	Absent	
SUGAR	: NIL	Negative	
ALBUMIN	: NIL	Negative	
MICROSCOPIC EXAMINATION			
PUS CELLS	: * 2-4/HPF	1 - 2	
RBC	: NIL	0.0 - 1.0	
EPITHELIAL CELLS	: 0-1/HPF	0 - 4	
CASTS	: NIL	Absent	
CRYSTALS	: NIL	Absent	
BLOOD UREA NITROGEN (BUN)			
BLOOD UREA	: 26.8 mg/dL	15.0 - 45.0 mg/dL	Urease-GLDH(Enzymatic UV)
BLOOD UREA NITROGEN (BUN)	: 12.52 mg/dL	7.0 - 21.0 mg/dL	
LIPID PROFILE			
TOTAL CHOLESTEROL	: 190.2 mg/dL	Border line : 200 - 240 mg/dL CHOD-PAP Desirable : < 200 mg/dL High : > 240 mg/dL	
SERUM TRYGLYCERIDES	: 84.0 mg/dL	Border line : 200 - 240 mg/dL Lipoprotein Lipase Desirable : < 200 mg/dL High : > 400 mg/dL	
HDL CHOLESTEROL	: 47.6 mg/dL	Desirable : \geq 40 mg/dL	Direct measure-PEG
LDL CHOLESTEROL	: 125.8 mg/dL	Border line : 100 - 130 mg/dL Desirable : < 100 mg/dL High : > 130 mg/dL	
VLDL	: 16.8 mg/dL	0 - 40 mg/dL	
NON HDL CHOLESTEROL	: * 142.6 mg/dl	< 130 mg/dl	
TOT CHOL/HDL RATIO	: 4	Low Risk : 3.3 - 4.4 Average Risk : 4.5 - 7.1 Moderate Risk : 7.2 - 11.0	
LDL/HDL RATIO	: 2.64	< 3.0	
HDL/LDL RATIO	: 0.38	> 0.3	
FBS (FASTING BLOOD GLUCOSE)			
FASTING BLOOD GLUCOSE	: 79 mg/dL	70 - 110 mg/dL	Hexokinase
CREATININE	: 0.79 mg/dl	0.4 - 1.4 mg/dl	Enzymatic
		0.4 - 1.4 mg/dl	



MEDICOVER HOSPITALS

Sy.No.73/3 to 16,Door No.16-13-166,167,
Opp.Prakruthi Aventures, New Bridge Road,



MEDICOVER HOSPITALS

A unit of Sahrudaya Health Care Srikakulam Pvt. Ltd.

Parameters	Result		Method
LIVER FUNCTION TESTS (LFT)			
TOTAL BILIRUBIN	:* 1.691 mg/dL	0.2 - 1.0 mg/dl	Diazotization
DIRECT (CONJUGATED) BILIRUBIN	:* 0.407 mg/dL	0.0 - 0.25 mg/dL	Diazotization
INDIRECT BILLIRUBIN	: 1.28		
SGOT (AST)	: 27.4 U/L	9 - 48 U/L	Uv kinetic with P5P
SGPT (ALT)	: 27.7 U/L	0.0 - 50.0 U/L	Uv kinetic with P5P
ALKALINE PHOSPHATASE (ALP)	: 77 U/L	40 - 129 U/L	p-NPP AMP Buffer
TOTAL SERUM PROTEINS	:* 8.31 g/dL	6.4 - 8.2 g/dL	Biuret reaction
SERUM ALBUMIN	:* 5.01 g/dL	3.2 - 4.6 g/dL	Bromocresol purple
GLOBULINS	: 3.3		
A/G RATIO	: 1.52	0.8 - 2.0	
SERUM URIC ACID	: 4.8 mg/dL	3.5 - 7.2 mg/dL	uricase
BUN / CREATININE RATIO			
BLOOD UREA NITROGEN (BUN)	: 12.52 mg/dL	7.0 - 21.0 mg/dL	Urease kinetic
CREATININE	: 0.79 mg/dl	0.4 - 1.4 mg/dl	Enzymatic
BUN/CREATININE RATIO	: 15.85		CALCULATION
PROSTATE SPECIFIC ANTIGEN (PSA)	: 1.59 ng/mL	0.21 - 6.77 ng/mL	Enzyme Linked Fluorescent assay
ESR	:* 30 mm/hour	0 - 9 mm/hour	WESTERGREN'S
HbA1c	: 5.0 %	indicate diabetes : > 6.5 % NORMAL : 4.0 - 6.0 % increased risk of diabetes:	Immunoturbidimetric : > 6.0 %

*** End Of Report ***

Dr. KONAPALA SUDHEER, MBBS, DCP,DNB (CONSULTANT PATHOLOGIST)

* Suggested Correlate Clinically

Verified By : 15227

Approved By : FTC1028

Dispatched By : 20833

Opp.Prakruthi Aventures, New Bridge Road, Srikakulam, Andhra Pradesh - 532005, India

For appointment :T: +91 40 6833 4455,
info@medicoverhospitals.in

www.medicoverhospitals.in



MEDICOVER HOSPITALS

Sy.No.73/3 to 16,Door No.16-13-166,167,
Opp.Prakruthi Aventures, New Bridge Road,

DEPARTMENT OF BIOCHEMISTRY



MEDICOVER HOSPITALS

A unit of Sahrudaya Health Care Srikakulam Pvt. Ltd.

Name	: Mr. NAVIN ROSHAN XESS	Age /Sex	: 41 Y(s)/Male
Bill Date	: 25-May-2024 09:40 AM	UMR No.	: SKU90556
Rept. Dt	: 25-May-2024 02:21 PM	Bill No.	: SKB128751
Ref By	: Dr.KUNTILLA AMULYA MBBS,MD (GENERAL MEDIC	Result No	: RES300578 / 240501119
Sample Type	: Blood		

POST PRANDIAL PLASMA / SERUM GLUCOSE

Parameters

Result

POST PRANDIAL PLASMA / SERUM G : * 71 mg/dL
Hexokinase

*** End Of Report ***

Consultant Pathologist

* Suggested Correlate Clinically

Verified By : 16321

Approved By :

Dispatched By :

Opp.Prakruthi Aventures, New Bridge Road, Srikakulam, Andhra Pradesh - 532005, India

For appointment :T: +91 40 6833 4455,
info@medicoverhospitals.in

www.medicoverhospitals.in



SANKAR FOUNDATION EYE HOSPITAL AND INSTITUTE

Paidi Srinivasa Complex
Kushalapuram, Venkatapuram Village
Near Simhadwaram
Srikakulam-532410

Prescription

Patient ID	514651	Visit Date	25/May/2024
Patient Name	MR. NAVIN ROSHAN. XESS	Age/Sex	41 yrs / M
Payor Name	WALK IN	Contact No.	9045641846
Patient Address	B -1315 /SECTOR 2,DGURWA, RANCHI,		

Present Complaints

Routine Eye Check Up.

Vision	Distance Vision		Near Vision	
	Right Eye	Left Eye	Right Eye	Left Eye
Unaided	6/6	6/9P		
With Pinhole		6/6		
Best Correct		6/6		

Method (IOP)	IOP Time	IOP (RE)	IOP (LE)	Corrected IOP(RE)	Corrected IOP(LE)	CCT (RE)	CCT (LE)
NCT	01:05	18	18				

Examination Details

Adnexa :- normal in both eyes

Conjunctiva :- normal in both eyes

Cornea :- clear in right eye, CLEAR in left eye

Anterior Chamber :- ND in both eyes

Iris :- NCP in both eyes

Pupil :- NSRL in both eyes

Lens :- clear in both eyes

Fundus :- WNL in both eyes

Diagnosis

NORMAL

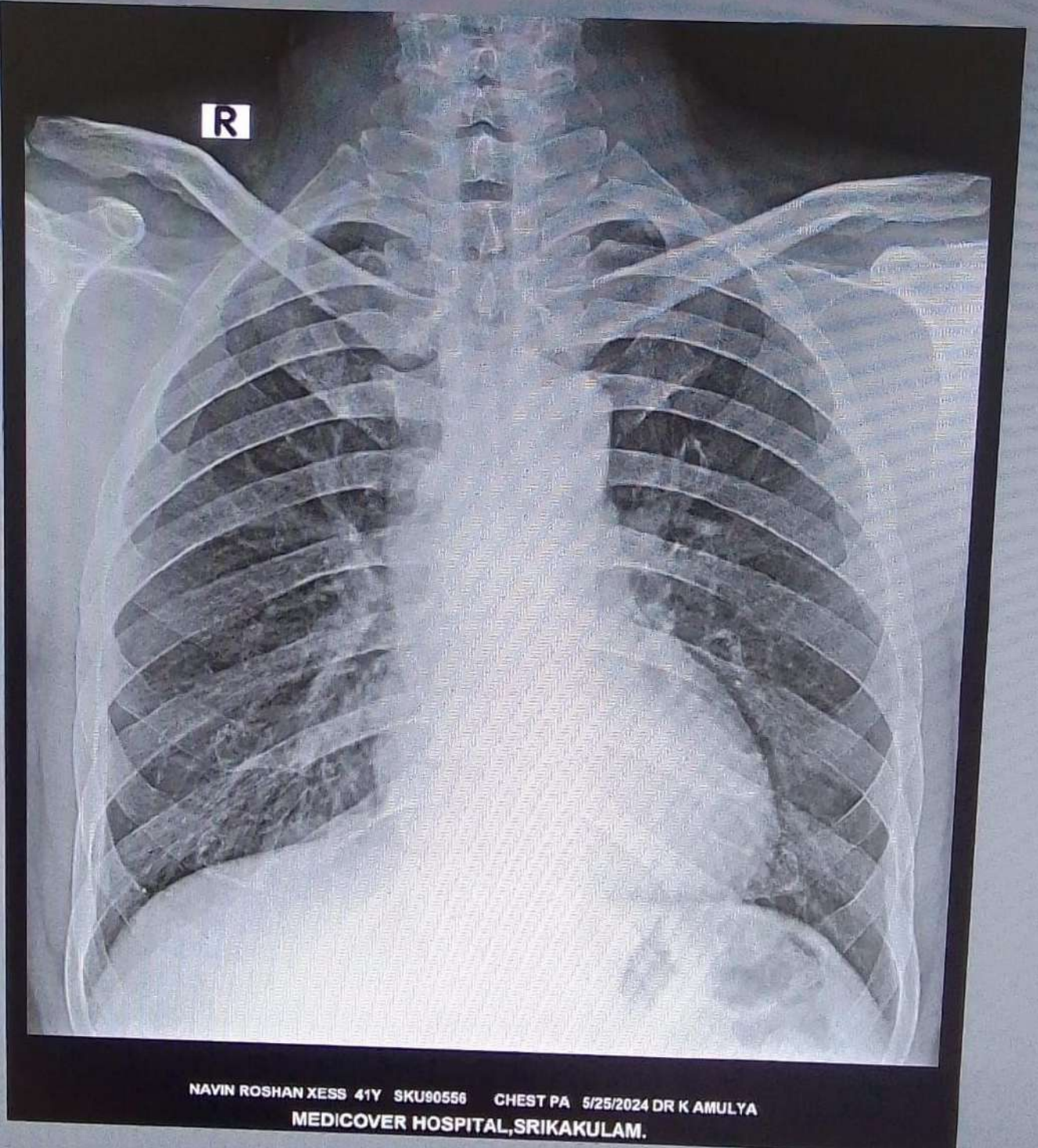
Plan of Care :

NORMAL

Next Review SOS.

Doctor's Signature

Dr B. Sumanjali



NAVIN ROSHAN XESS 41Y SKU90556 CHEST PA 5/25/2024 DR K AMULYA
MEDICOVER HOSPITAL, SRIKAKULAM.