



**MEDICOVER  
HOSPITALS**

A UNIT OF SAHRUDAYA HEALTHCARE PVT LTD.

# Medicover Hospitals

VENKOJIPALAM VISAKHAPATNAM - 530017

ANDHRA PRADESH - INDIA

PHONE NO : 0891-6829999

**Dr. RAKESH P  
MD  
GENERAL PHYSICIAN**

NAME: K. Venkata Rama Krishna AGE 55 Y

WT: 99 kg  
HT: 180 cm  
BP: 130/80 mmHg  
PR: 77 /min

No Remarks

Adv  
TMT

**Medicover Unit - I**  
# 18-1-3, KGH Down, Maharanipeta,  
Jagadamba Junction, Visakhapatnam  
Andhrapradesh - 530 002.  
Ph: +91 96526 69351

**Medicover Unit - III**  
Sry. No.27, Plot No.05, BRTS Road,  
Health City, Arilova, Chinnagadhili Mandal,  
Visakhapatnam, Andhrapradesh - 530 040.  
Ph: +91 9994 42222

**Medicover - MVP**  
# 1-1-83, Sector-6, Venkojipalem,  
MVP Colony, Visakhapatnam



**MEDICOVER  
HOSPITALS**

A UNIT OF SAHRUDAYA HEALTHCARE PVT LTD.

# Medicover Hospitals

VENKOJIPALAM VISKHAPATNAM -530017

ANDHRA PRADESH -INDIA

PHONO NO : 0891-6829999

## OPHTHALMOLOGIST CONSULTATION

NAME: N. Venkata Rama Krishna AGE: 55 male

DATE: 55/male

N/A R 6/9  
L 6/9      2 glasses R 6/6  
L 6/6

H/O H/TN

Under medication

dilali (30E) NU 2 glasses NU 6 (30E)

Dr. Preksham

AN

Kedam

su

L

mu 0.5m  
0.3m



### Lab Report

Patient Name	: Mr. K VENKATA RAMA KRISHNA	Age /Gender	: 55 Y(s)/Male
Bill No/ UMR No	: V4BC242026/V4U190279	Referred By	: Dr. CMO
Received Dt	: 08-Jun-24 09:30 am	Report Date	: 08-Jun-24 10:43 am
Lab No	: 120000644922		

<u>Parameter</u>	<u>Result Values</u>	<u>Biological Reference</u>
<b>CBC(COMPLETE BLOOD COUNT)</b>		
<b>RBC</b>		
HAEMOGLOBIN	14.6	13.0 - 17.0 g/dl
R B C COUNT	4.6	4.5 - 5.5 10 <sup>6</sup> /μL
PCV/HCT	42	40 - 50 %
MCV	92	83 - 101 fl
MCH	32	27 - 32 pg
MCHC	* 35	31.5 - 34.5 g/dL
RDW(cv)	* 14.8	11.6 - 14.0 %
<b>WBC</b>		
TC (TOTAL LEUCOCYTE COUNT)	6600	4000 - 11000 cells/cumm
<b>DIFFERENTIAL COUNT</b>		
NEUTROPHILS	55	40 - 80 %
LYMPHOCYTES	38	20 - 40 %
MONOCYTES	04	02 - 10 %
EOSINOPHILS	03	00 - 06 %
BASOPHILS	00	00 - 01 %
<b>PLATELET COUNT</b>		
PLATELET COUNT	2.44	1.50 - 4.50 Lakhs/cumm
ESR	08	0 - 10 mm/1st hour
<b>BLOOD GROUPING AND RH</b>		
BLOOD GROUP	" O "	
RH TYPE	POSITIVE	
*** End Of Report ***		

### Doctor Incharge

**Dr.MUDUGANTI SRINIVAS**  
MBBS, MD  
CONSULTANT PATHOLOGIST

**Dr.SRUJANA**  
MBBS, MD PATHOLOGY  
CONSULTANT PATHOLOGIST

**Dr.MOHAMMAD SIMI IQBAL**  
M.B.B.S, M.D  
CONSULTANT BIOCHEMIST



# Medicover Hospitals

VENKOJIPALAM VISAKHAPATNAM - 530017  
ANDHRA PRADESH - INDIA

# MEDICOVER HOSPITALS

A UNIT OF SAHRUDAYA HEALTHCARE PVT LTD.

## Lab Report

Patient Name	: Mr. K VENKATA RAMA KRISHNA	Age /Gender	: 55 Y(s)/Male
Bill No/ UMR No	: V4BC242026/V4U190279	Referred By	: Dr. CMO
Received Dt	: 08-Jun-24 09:30 am	Report Date	: 08-Jun-24 10:46 am
Lab No	: 120000644923		

Parameters	Result	Biological Reference In Method
SERUM ALBUMIN	4.6	NewBorn: 0-4 days : 2.8 - 4.4 g/dL Children: 4 days - 14 years : 3.8 - 5.4 g/dL 14-18 years : 3.2 - 4.5 g/dL Adults : 3.5- 5.2 g/dL
GLOBULINS A/G RATIO	* 2.0 2.3	2.5 - 3.5 g/dL 1.2 - 2.5
<b>T3,T4 AND TSH</b>		
T3	1.44	0.8 - 2.0 ng/mL
T4	8.78	5.1 - 14.1 ug/dL
TSH(THYROID STIMULATING HORMONE)	* 4.27	0.270 - 4.20 uIU/mL
<b>PSA (PROSTATE SPECIFIC ANTIGEN).</b>		
PROSTATE SPECIFIC ANTIGEN TOTAL (TPSA)	1.89	0.21 - 6.77 ng/mL
BUN(BLOOD UREA NITROGEN)	11.4	7.0 - 21.0 mg/dL
<b>GAMMA GT</b>		
GAMMA GLUTAMYL TRANSFERASE(GGT)	42	10 - 71 U/L
BUN(BLOOD UREA NITROGEN)	08	

\*\*\* End Of Report \*\*\*

Suggested Clinical Correlation \* If necessary, Please discuss

Verified By : : MC0954

Test results related only to the item tested.

No part of the report can be reproduced without written permission of the laboratory.

*Md. Simi Iqbal*

Dr. MOHAMMAD SIMI IQBAL M.B.B.S, M.D

Dr.MUDUGANTI SRINIVAS  
MBBS, MD  
CONSULTANT PATHOLOGIST

Dr.SRUJANA  
MBBS, MD PATHOLOGY  
CONSULTANT PATHOLOGIST

Dr.MOHAMMAD SIMI IQBAL  
M.B.B.S, M.D  
CONSULTANT BIOCHEMIST

### Medicover Unit - I

# 18-1-3, KGH Down, Maharanipeta,  
Jagadamba Junction, Visakhapatnam,  
Andhrapradesh - 530 002.  
Ph: +91 96526 69351

### Medicover Unit - III

Sry. No. 27, Plot No. 05, BRTS Road,  
Health City, Arilova, Chinnagadili Mandal,  
Visakhapatnam, Andhrapradesh - 530 040.  
Ph: +91 0891-6677888

### Medicover - MVP

# 1-1-83, Sector-6, Venkojipalem,  
MVP Colony, Visakhapatnam,  
Andhrapradesh-530017.  
Ph: +91 8886655677



**Lab Report**

Patient Name	: Mr. K VENKATA RAMA KRISHNA	Age /Gender	: 55 Y(s)/Male
Bill No/ UMR No	: V4BC242026/V4U190279	Referred By	: Dr. CMO
Received Dt	: 08-Jun-24 09:30 am	Report Date	: 08-Jun-24 11:04 am
Lab No	: 120000644920		

<u>Parameters</u>	<u>Result</u>	<u>Biological Reference Intervals</u>
<b>HBA1C (GLYCOSYLATED HAEMOGLOBIN)</b>		
HBA1C	5.5	Non -Diabetic : <= 5.6 % Pre Diabetic : 5.7 - 6.4 % Diabetic : >= 6.5 % %
<b>LIPID PROFILE</b>		
TOTAL CHOLESTEROL	165	No risk : < 200 mg/dL Moderate risk : 200 - 239 High risk : > 240
HDL CHOLESTEROL	25	<40 Low >60 High
LDL CHOLESTEROL	111	Border line : 100 - 130 mg/dL High : > 130 mg/dL Desirable : < 100 mg/dL 100 - 130 mg/dL
VLDL	29	
SERUM TRYGLYCERIDES	143	Very High : > 500 mg/dL High : >= 200 - 499 mg/dL Border line High : >= 150 - 199 mg/dL
<b>CHO/HDL RATIO</b>	* 6.6	Normal : < 150 mg/dL Normal : < 4.0 Low risk : 4.0 - 6.0 High risk : > 6.0
LDL/HDL RATIO	4.44	
<b>FBS (FASTING BLOOD GLUCOSE)</b>		
FASTING BLOOD GLUCOSE	99	Normal : 70-99 mg/dL Impaired : 100-125 mg/dL Diabetic : >= 126 mg/dL
CREATININE	0.9	0.9 - 1.3 mg/dL
<b>LFT(LIVER FUNCTION TEST)</b>		
TOTAL BILIRUBIN	0.4	< 1.2 mg/dL
DIRECT BILIRUBIN	0.2	<= 0.20 mg/dL
INDIRECT BILIRUBIN	0.2	<= 1.0 mg/dL
SGPT (ALT)	35	<= 41 U/L
SGOT (AST)	22	<= 40 U/L
ALKALINE PHOSPHATASE (ALP)	77	40 - 129 U/L
TOTAL PROTEINS	6.6	1-2 years : 5.6-7.5 g/dL > 3 years : 6.0-8.0 g/dL Adults : 6.4-8.3 g/dL



**Lab Report**

Patient Name	: Mr. K VENKATA RAMA KRISHNA	Age /Gender	: 55 Y(s)/Male
Bill No/ UMR No	: V4BC242026/V4U190279	Referred By	: Dr. CMO
Received Dt	: 08-Jun-24 09:30 am	Report Date	: 08-Jun-24 11:39 am
Lab No	: 240601071		

<u>Parameter</u>	<u>Result Values</u>	<u>Biological Reference</u>
<b>URINE ROUTINE</b>		
<u>CHEMICAL EXAMINATION</u>		
ALBUMIN	NIL	Negative
SUGAR	NIL	Negative
BLOOD	NIL	Absent
<u>MICROSCOPIC EXAMINATION</u>		
PUS CELLS	2-4	/HPF
RBC	NIL	/HPF
EPITHELIAL CELLS	1-2	/HPF
CRYSTALS	NIL	
CASTS	NIL	
OTHERS	NIL	

\*\*\* End Of Report \*\*\*

**Doctor Incharge**

**Dr.MUDUGANTI SRINIVAS**  
MBBS, MD  
CONSULTANT PATHOLOGIST

**Dr.SRUJANA**  
MBBS, MD PATHOLOGY  
CONSULTANT PATHOLOGIST

**Dr.MOHAMMAD SIMI IQBAL**  
M.B.B.S, M.D  
CONSULTANT BIOCHEMIST



# Medicover Hospitals

VENKOJIPALAM VISAKHAPATNAM - 530017  
ANDHRA PRADESH - INDIA



# MEDICOVER HOSPITALS

A UNIT OF SAHRUDAYA HEALTHCARE PVT LTD.

## DEPARTMENT OF RADIOLOGY

<b>Patient Name</b> : Mr. K VENKATA RAMA KRISHNA	<b>Age / Gender</b> : 55 Y(s)/Male
<b>Bill No/ UMR No</b> : V4BC242026/V4U190279	<b>Referred By</b> : Dr. CMO
<b>Received Dt</b> : 08-Jun-24 09:11 am	<b>Report Date</b> : 08-Jun-24 12:01 pm

### USG ABDOMEN (MALE)

#### LIVER

Measuring 14.3 cm. Normal in size with increased echotexture.  
There is no evidence of IHBR/EHBR dilatation seen.  
The portal, hepatic vessels are normal. No S.O.L. noted.

#### GALL BLADDER

Normal in volume and wall thickness.  
No evidence of intraluminal calculi/ masses seen.  
C.B.D appears normal with no intraluminal mass/ calculi.

#### PANCREAS

Head, Body & Tail are identified with normal echopattern & smooth outlines. The pancreatic duct system appears normal. The peri pancreatic fat planes are well preserved.

#### SPLEEN

Measuring 10.5 cm in cranio caudal directions with normal homogenous echotexture.

#### RIGHT KIDNEY

Measuring 13.1 x 6.5 cm. Normal in location, size with echopattern  
Cortico Medullary differentiation is normal  
No evidence of mass / calculi / hydroureteronephrosis seen.

#### LEFT KIDNEY

Left crossed fused ectopic kidney measuring 9.8 x 5.6 cm in size.  
Cortico Medullary differentiation is normal  
No evidence of mass / calculi / hydroureteronephrosis seen.  
No evidence of suprarenal / retroperitoneal mass noted.

#### URINARY BLADDER

Normal in volume and wall thickness.  
No intraluminal mass / calculi noted.

#### PROSTATE

Measuring 36 cc. Enlarged in size.

No evidence of ascites/ pleural effusion seen.  
No detectable bowel pathology seen.

#### IMPRESSION

\* Fatty liver.

\* Left crossed fused ectopic kidney.

#### Medicover Unit - I

# 18-1-3, KGH Down, Maharaniapeta,  
Jagadamba Junction, Visakapatnam,  
Andhrapradesh - 530 002.  
Ph: +91 96526 69351

#### Medicover Unit - III

Sry. No. 27, Plot No. 05, BRTS Road,  
Health City, Arilova, Chinnagadalu Mandal,  
Visakhapatnam, Andhrapradesh - 530 040.  
Ph: +91 08916677888

#### Medicover - MVP

# 1-1-83, Sector -6, Venkojipalem,  
MVP Colony, Visakapatnam,  
Andhrapradesh-530017.  
Ph: +91 8886655677



## Medicover Hospitals

VENKOJIPALAM VISAKHAPATNAM - 530017  
ANDHRA PRADESH - INDIA



# MEDICOVER HOSPITALS

A UNIT OF SAHRUDAYA HEALTHCARE PVT LTD.

### DEPARTMENT OF RADIOLOGY

<b>Patient Name</b> : Mr. K VENKATA RAMA KRISHNA	<b>Age / Gender</b> : 55 Y(s)/Male
<b>Bill No/ UMR No</b> : V4BC242026/V4U190279	<b>Referred By</b> : Dr. CMO
<b>Received Dt</b> : 08-Jun-24 09:11 am	<b>Report Date</b> : 08-Jun-24 11:20 am

\* Left crossed fused ectopic kidney.

\* Grade I prostatomegaly.

\*\*\* End Of Report \*\*\*

**Dr. VULAPU CHENNAKRISHNA RAO, .**  
MBBS, DNB  
CONSULTANT RADIOLOGIST





## Medicover Hospitals

VENKOJIPALAM VISAKHAPATNAM - 530017  
ANDHRA PRADESH - INDIA



# MEDICOVER HOSPITALS

A UNIT OF SAHRUDAYA HEALTHCARE PVT LTD.

### DEPARTMENT OF RADIOLOGY

<b>Patient Name</b> : Mr. K VENKATA RAMA KRISHNA	<b>Age / Gender</b> : 55 Y(s)/Male
<b>Bill No/ UMR No</b> : V4BC242026/V4U190279	<b>Referred By</b> : Dr. CMO
<b>Received Dt</b> : 08-Jun-24 09:11 am	<b>Report Date</b> : 08-Jun-24 12:07 pm

### X-RAY CHEST PA VIEW

#### FINDINGS

The cardiac size & configuration appear normal.

The Aorta and pulmonary vasculature appear normal.

There is no evidence of mediastinal widening.

Both the lungs and CP angles are clear.

The soft tissues and the bones of the rib cage displayed no abnormality.

#### IMPRESSION

\* Normal study.

- Kindly correlate clinically.

\*\*\* End Of Report \*\*\*

**Dr. VULAPU CHENNAKRISHNA RAO, .**  
MBBS, DNB  
CONSULTANT RADIOLOGIST



**DEPARTMENT OF CARDIOLOGY**

<b>Patient Name</b> : Mr. K VENKATA RAMA KRISHNA	<b>Age /Gender</b> : 55 Y(s)/Male
<b>Bill No/ UMR No</b> : V4BC242026/V4U190279	<b>Referred By</b> : Dr. CMO
<b>Received Dt</b> : 08-Jun-24 09:11 am	<b>Report Date</b> : 08-Jun-2024 11:34 am
<b>Lab No</b> : 0	

**2D ECHO WITH COLOUR DOPPLER**

**MEASUREMENTS**

LVID(D)	4.7CM
LVID(s)	2.6CM
LVEF	60%
IVS (d)	1.3CM
PWD (d)	1.2CM

**VALVES**

MITRAL VALVE	NORMAL
AORTIC VALVE	NORMAL
TRICUSPID VALVE	NORMAL
PULMONARY VALVE	NORMAL

**CHAMBER**

RIGHT ATRIUM	NORMAL
RIGHT VENTRICLE	NORMAL
LEFT ATRIUM	3.1 Cms
LEFT VENTRICLE	NORMAL
RWMA	NO RWMA
SYSTOLIC FUNCTION	NORMAL
DIASTOLIC DYSFUNCTION	NIL
CLOT	NO

**SEPTAE**

INTER ATRIAL SEPTUM	INTACT
INTER VENTRICULAR SEPTUM	INTACT

**GREAT ARTERY AND OTHERS**

AORTA	2.7 Cms
-------	---------



**Medicover Hospitals**  
VENKOJIPALAM VISAKHAPATNAM - 530017  
ANDHRA PRADESH - INDIA



**MEDICOVER  
HOSPITALS**

A UNIT OF SAHRUDAYA HEALTHCARE PVT LTD.

**DEPARTMENT OF CARDIOLOGY**

<b>Patient Name</b> : Mr. K VENKATA RAMA KRISHNA	<b>Age /Gender</b> : 55 Y(s)/Male
<b>Bill No/ UMR No</b> : V4BC242026/V4U190279	<b>Referred By</b> : Dr. CMO
<b>Received Dt</b> : 08-Jun-24 09:11 am	<b>Report Date</b> : 08-Jun-2024 11:34 am
<b>Lab No</b> : 0	

**PULMONARY ARTERY** NORMAL  
**PERICARDIUM** NORMAL  
**IVC/SVC/CS** NORMAL  
**DOPPLER STUDY**  
**MITRAL FLOW** E < A  
**AORTIC FLOW** 1.5 M/sec  
**PULMONARY FLOW** 0.9 M/sec  
**COLOUR DOPPLER**  
**MR** NO  
**AR** NO  
**TR** MILD TR  
**PR** NO  
**FINAL IMPRESSION**  
 --  
 NO RWMA  
 NORMAL LV FUNCTION  
 NO MR/AR  
 MILD TR, NO PAH  
 MILD CONCENTRIC LVH  
 NO PERICARDIAL EFFUSION  
 NO LV CLOTS  
 \*\*\* End Of Report \*\*\*

Technician

**Dr. ASHWIN KUMAR PANDA,**  
MBBS, DNB, Senior Medical Officer, Cardiology

Page 2 of 2

**Dr. ARCHANA BEHRA**  
MD., DNB(CARDIOLOGY)  
CONSULTANT CARDIOLOGIST

**Dr. BODEPUDI SRIKANTH**  
MD DM  
CONSULTANT CARDIOLOGIST

**Dr. K P RANGANAYAKULU**  
MD., DM.  
CONSULTANT INTERVENTIONAL C

**Dr. S. SRIKARA SAMIR NANDAN**  
MD., DM.

**Dr. RAVIKUMAR GURUGUBELLI**  
MD, DM

**Dr. A. SURESH**  
MBBS, MD(GM), DM-CARDIOLOGY,

CONSULTANT INTERVENTIONAL C  
Medicover Unit - I  
# 18-1-3, KGH Down, Maharani-peta,  
Jagadamba Junction, Visakhapatnam  
Andhrapradesh - 530 002.  
Ph: +91 96526 69351

CONSULTANT CARDIOLOGIST  
Medicover Unit - III  
Sry. No.27, Plot No.05, BRTS Road,  
Health City, Arilova, Chinnagadhili Mandal,  
Visakhapatnam, Andhrapradesh - 530 040.  
Ph: +91 0891 6677888

SENIOR CONSULTANT  
Medicover - MVP  
# 1-1-83, Sector-6, Venkojipalem,  
MVP Colony, Visakhapatnam,  
Andhrapradesh-530017.  
Ph: +91 8886655677

55 Years

Male

WELLNESS

Rate 70 . SINUS RHYTHM.....normal P axis, V-rate 50- 99  
: BORDERLINE LOW VOLTAGE IN FRONTAL LEADS.....all frontal leads <0.6mV

PR 140  
QRSD 74  
QT 396  
QTc 428

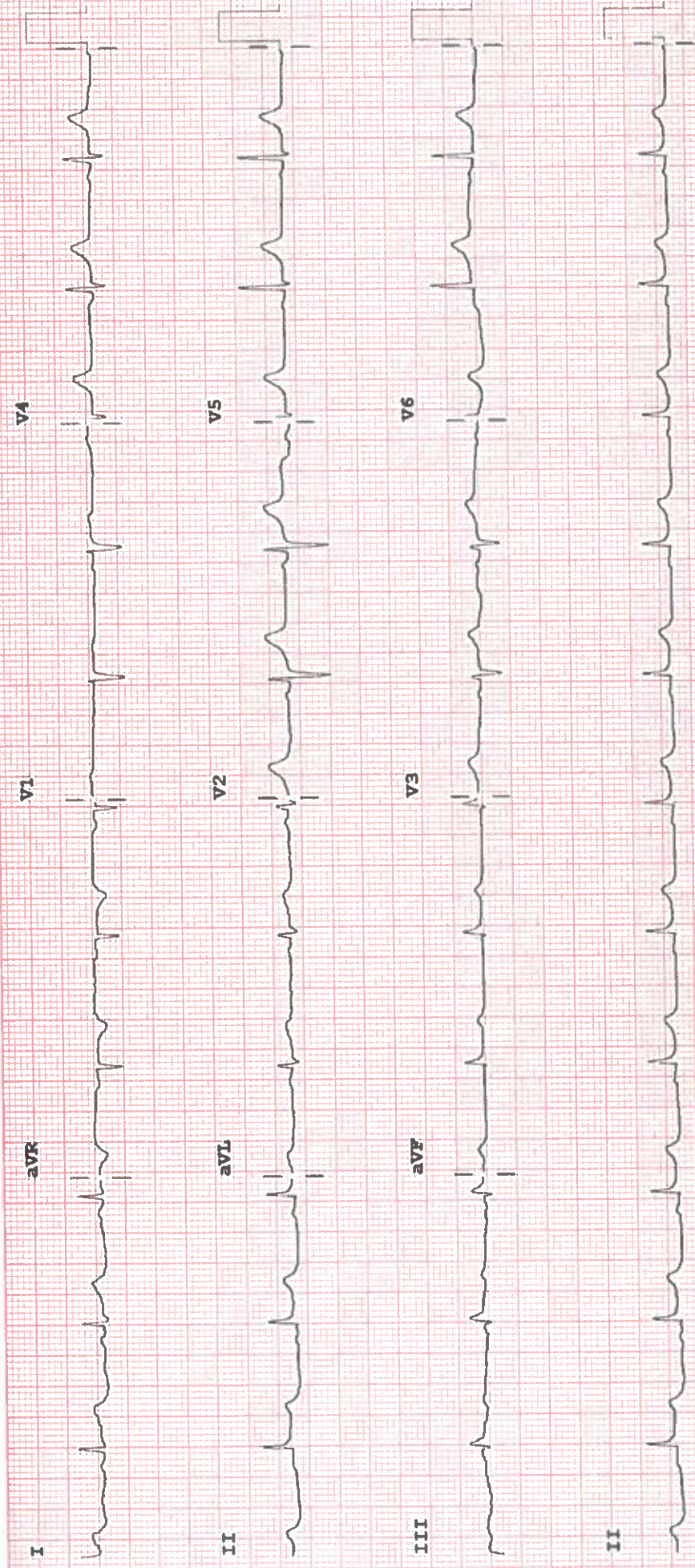
--AXIS--

P -19  
QRS 47  
T 26

12 Lead; Standard Placement

- OTHERWISE NORMAL ECG -

Unconfirmed Diagnosis



F 50~0.50- 40 Hz W

Speed: 25 mm/sec Limb: 10 mm/mV Chest: 10.0 mm/mV

PH090A CL

Device: