

**DR. NETRAVALKAR'S
ASHWINI PATHOLOGY LABORATORY**

(For all investigations in Histopathology, Cytopathology, Haematology, Clinical Pathology, Microbiology & Hormonal Chemistry)

Consultant Pathologist **Dr. Prasad Netravalkar** MBBS, MD (Path) BOM

(HOME COLLECTION FACILITY AVAILABLE)

Panaji : 1st, Floor, Rizvi Sadan, Above Saroj Emporium, Near Inox Theatre, Opp. Municipal Market, Panaji.
Ph.: 2229142, 8407912840, 8390242524

E-mail : ashwinilabpanaji@gmail.com, drprasadnetravalkar@gmail.com

Mapusa : F8, Ramchandra Chambers, 1st Floor, Mapusa Clinic Road, Mapusa - Bardez, Goa. Ph.: 2252320

Pt.No. : 61 080624

Pt.Name : Mr. Shirodkar Chanda Dharma

Age : 42 Yrs. Sex : M

Ref. By : -

Date : 08-06-2024

		Normal Range
Fasting Blood Sugar	: 93.0 mg/dl	70 - 110 mg/dl
2 Hrs. Blood Sugar	: 111.0 mg/dl	110 -140 mg/dl

GLYCOSYLATED HAEMOGLOBIN IN BLOOD (HPLC METHOD)

HbA1C : 5.40 %

Mean Blood Glucose : 107 mg %

INTERPRETATION:

HbA1c %

NORMAL

Below 6.5 %

GOOD DIABETIC CONTROL

6.5 % - 7.5 %

FAIR CONTROL


7.5 % - 8.0 %

UNSATISFACTORY CONTROL

8.0 % - 10.0 %

POOR CONTROL

Above 10.0 %



Dr. Prasad Netravalkar
MBBS, MD (Bom)
GMC Reg. No. 1294

We Care

All Diagnostic facilities under one roof in Panaji centre - Lab, ultrasound, X ray, ECG, TMT, ECHO

**DR. NETRAVALKAR'S
ASHWINI PATHOLOGY LABORATORY**

(For all investigations in Histopathology, Cytopathology, Haematology, Clinical Pathology, Microbiology & Hormonal Chemistry)

Consultant Pathologist **Dr. Prasad Netravalkar** MBBS MD (Path) BOM

(HOME COLLECTION FACILITY AVAILABLE)

Panaji : 1st, Floor, Rizvi Sadan, Above Saroj Emporium, Near Inox Theatre, Opp. Municipal Market, Panaji.

Ph.: 2229142, 8407912840, 8390242524

E-mail : ashwinilabpanaji@gmail.com, drprasadnetravalkar@gmail.com

Mapusa : F8, Ramchandra Chambers, 1st Floor, Mapusa Clinic Road, Mapusa - Bardez, Goa. Ph. 2252320

Pt.No. : 61 080624

Pt.Name : Mr. Shirodkar Chanda Dharma

Age : 42 Yrs. Sex : M



Ref. By : -

Date : 08-06-2024

Normal Range

LIPID PROFILE

Total Cholesterol	: 171.0 mg/dl	130 - 220 mg/dl
S. Triglycerides	: 81.0 mg/dl	35 - 170 mg/dl
HDL Cholesterol	: 37.0 mg/dl	> 35 mg/dl
LDL Cholesterol	: 118 mg/dl	< 130 mg/dl
VLDL Cholesterol	: 16 mg/dl	Upto 35 mg/dl
TC/HDLC Ratio	: 4.6	< 4.5
LDLC/HDLC Ratio	: 3.2	2.5 - 3.5



Dr. Prasad Netravalkar
MBBS, MD (Bom)
GMC Reg. No. 1294

We Care

All Diagnostic facilities under one roof in Panaji centre - Lab, ultrasound, X ray, ECG, TMT, ECHO

DR. NETRAVALKAR'S ASHWINI PATHOLOGY LABORATORY

(For all investigations in Histopathology, Cytopathology, Haematology, Clinical Pathology, Microbiology & Hormonal Chemistry)

Consultant Pathologist **Dr. Prasad Netravalkar** MBBS MD (Path) BOM

(HOME COLLECTION FACILITY AVAILABLE)

Panaji : 1st, Floor, Rizvi Sadan, Above Saroj Emporium, Near Inox Theatre, Opp. Municipal Market, Panaji.

Ph.: 2229142, 8407912840, 8390242524

E-mail : ashwinilabpanaji@gmail.com, drprasadnetravalkar@gmail.com

Mapusa : F8, Ramchandra Chambers, 1st Floor, Mapusa Clinic Road, Mapusa - Bardez, Goa Ph - 2252320

Pt.No. : 61 080624

Pt.Name : Mr. Shirodkar Chanda Dharma

Age : 42 Yrs. Sex : M

Ref. By : -

Date : 08-06-2024

Normal Range

LIVER FUNCTION TEST

S. Bilirubin (Total)	: 1.40	mg/dl	0 - 1 mg/dl
S. Bilirubin (Direct)	: 0.45	mg/dl	0 - 0.25 mg/dl
S. Bilirubin (Indirect)	: 0.95	mg/dl	0 - 0.75 mg/dl
S.G.O.T	: 22.0	U/L	0 - 42 U/L
S.G.P.T	: 18.0	U/L	0 - 42 U/L
S. Alkaline Phosphatase	: 59.0	IU/L	15 - 112 IU/L
GGTP	: 21.0	U/L	11-43 U/L
Total Proteins	: 6.50	g/dl	6.0 - 10.0 g/dl
S. Albumin	: 4.10	gm%	3.2 - 5.5 gm%
S. Globulin	: 2.4	g/dl	2.3 - 3.5 g/dl
A/G Ratio	: 1.7 : 1		



Dr. Prasad Netravalkar
MBBS, MD (Bom)
GMC Reg No. 1294

We Care

All Diagnostic facilities under one roof in Panaji centre - Lab, ultrasound, X ray, ECG, TMT, EPT

DR. NETRAVALKAR'S ASHWINI PATHOLOGY LABORATORY

(For all investigations in Histopathology, Cytopathology, Haematology, Clinical Pathology, Microbiology & Hormonal Chemistry)

Consultant Pathologist **Dr. Prasad Netravalkar** MBBS, MD (Path) BOM

(HOME COLLECTION FACILITY AVAILABLE)

Panaji : 1st, Floor, Rizvi Sadan, Above Saroj Emporium, Near Inox Theatre, Opp. Municipal Market, Panaji.
Ph.: 2229142, 8407912840, 8390242524

E-mail : ashwinilabpanaji@gmail.com, drprasadnetravalkar@gmail.com

Mapusa : F8, Ramchandra Chambers, 1st Floor, Mapusa Clinic Road, Mapusa - Bardez, Goa Ph - 2252320

Pt.No. : 61 080624

Pt.Name : Mr. Shirodkar Chanda Dharma

Age : 42 Yrs. Sex : M

Ref. By : -

Date : 08-06-2024

Normal Range

COMPLETE HEMOGRAM

Haemoglobin	: 14.6	g/dl	13.5 - 18 g/dl
W.B.C Count	: 6600	cells/ cu-mm	4000 - 11000 cells/ cu-mm
R.B.C Count	: 4.94	millions / cu-mm	4.5 - 6.5 millions / cu-mm
MCV	: 83.5	fl	80 - 96 fl
MCH	: 29.4	Pg	27 - 33 Pg
MCHC	: 35.2	%	32 - 37 %
PCV	: 41.3	%	40 - 54 %
Platelet Count	: 1.83	lakhs /cu mm	1.5 - 4.5 lakhs /cu mm
E.S.R (Westergren)	: 13	mm/hr	0 - 20 mm/hr

DIFFERENTIAL COUNT

Stab Cells	: 03	%	1-5 %
Neutrophils	: 39	%	40 - 60 %
Lymphocytes	: 44	%	20 - 45 %
Eosinophils	: 08	%	1 - 6 %
Monocytes	: 06	%	0 - 10 %
Basophils	: 00	%	0 - 1 %
Abnormal Cells	: Nil		

SMEAR EXAMINATION

RBC Morphology	: Normocytic , Normochromic
W.B.C Morphology	: Within Normal Limits
Platelets on Smear	: Adequate
Parasites	: Absent

Blood Group : 'O' Rh Positive



Dr. Prasad Netravalkar
MBBS, MD (Bom)
GMC Reg. No. 1294

We Care

All Diagnostic facilities under one roof in Panaji centre - Lab, ultrasound, X ray, ECG, TMT, ECHO

**DR. NETRAVALKAR'S
ASHWINI PATHOLOGY LABORATORY**

(For all investigations in Histopathology, Cytopathology, Haematology, Clinical Pathology, Microbiology & Hormonal Chemistry)

Consultant Pathologist **Dr. Prasad Netravalkar** MBBS MD (Path) BOM

(HOME COLLECTION FACILITY AVAILABLE)

Panaji : 1st, Floor, Rizvi Sadan, Above Saroj Emporium, Near Inox Theatre, Opp. Municipal Market, Panaji.
Ph.: 2229142, 8407912840, 8390242524

E-mail : ashwinilabpanaji@gmail.com, drprasadnetravalkar@gmail.com

Mapusa : FS, Ramchandra Chambers, 1st Floor, Mapusa Clinic Road, Mapusa - Bardez, Goa Ph - 2252320

Pt.No. : 61 080624

Pt.Name : Mr. Shirodkar Chanda Dharma

Age : 42 Yrs. Sex : M

Ref. By : -

Date : 08-06-2024

BIOCHEMISTRY REPORTS

Fasting Urine Glucose : Absent

2 Hrs. Urine Glucose : Absent


Pathologist

Dr. Prasad Netravalkar
MBBS, MD (Bom)
GMC Reg No. 1294

We Care

All Diagnostic facilities under one roof in Panaji centre - Lab, ultrasound, X ray, ECG, TMT, ECHO

DR. NETRAVALKAR'S
ASHWINI PATHOLOGY LABORATORY

(For all investigations in Histopathology, Cytopathology, Haematology, Clinical Pathology, Microbiology & Hormonal Chemistry)

Consultant Pathologist **Dr. Prasad Netravalkar** MBBS, MD (Path) DDM

(HOME COLLECTION FACILITY AVAILABLE)

Panaji : 1st, Floor, Rizvi Sadan, Above Saroj Emporium, Near Inox Theatre, Opp. Municipal Market, Panaji
Ph.: 2229142, 8407912840, 8390242524

E-mail : ashwinilabpanaji@gmail.com, drprasadnetravalkar@gmail.com

Mapusa : F8, Ramchandra Chambers, 1st Floor, Mapusa Clinic Road, Mapusa - Bardez, Goa. Ph. 2252120

Pt.No. : 61 080624

Pt.Name : Mr. Shirodkar Chanda Dharma

Age : 42 Yrs. Sex : M

Ref. By : -

Date : 08-06-2024

EXAMINATION OF URINE

PHYSICAL EXAMINATION


Quantity : 20 ml
Colour : Pale Yellow
Appearance : Slightly Hazy
pH : 6.5
Specific Gravity : 1.010

CHEMICAL EXAMINATION

Proteins : Absent
Glucose : Absent
Ketone Bodies : Absent
Bile Salts : Absent
Bile Pigments : Absent
Occult Blood : Negative
Urobilinogen : Normal

MICROSCOPIC EXAMINATION [As per hpf]

Epithelial Cells : 2 - 3 /hpf
Pus Cells : 10 - 12 /hpf
Red Blood Cells : Absent
Casts : Absent
Crystals : Absent



Dr. Prasad Netravalkar
MBBS, MD (Path)
GMC Reg. No. 1294

We Care

All Diagnostic facilities under one roof in Panaji centre - Lab, ultrasound, X ray, ECG, TMT, ECHO

DR. NETRAVALKAR'S ASHWINI PATHOLOGY LABORATORY

(For all investigations in Histopathology, Cytopathology, Haematology, Clinical Pathology, Microbiology & Hormonal Chemistry)

Consultant Pathologist **Dr. Prasad Netravalkar** MBBS, MD (Path) BOM

(HOME COLLECTION FACILITY AVAILABLE)

Panaji : 1st, Floor, Rizvi Sadan, Above Saroj Emporium, Near Inox Theatre, Opp. Municipal Market, Panaji.
Ph.: 2229142, 8407912840, 8390242524

E-mail : ashwinilabpanaji@gmail.com, drprasadnetravalkar@gmail.com

Mapusa : F8, Ramchandra Chambers, 1st Floor, Mapusa Clinic Road, Mapusa - Bardez, Goa Ph 2252320

Patient Name : MR. SHIRODKAR CHANDA DHARMA

Referral : SELF

Age / Gender : 42 / Male

Reporting Time : Jun 08, 2024, 02:08 p.m.

Patient ID : 32975

Sample ID :



Source : DIRECT

Test Description	Value(s)	Reference Range	Unit
Thyroid Profile			
T3 (Total) Method : Serum ECL	1.57	1.30 - 3.10	nmol/l
T4 (Total)* Method : Serum ECL	96.29	66.0 - 181.0	nmol/l
TSH(Ultrasensitive)* Method : Serum ECL	3.35	0.270 - 4.20	uIU/ml

END OF REPORT

Pathologist

Dr. Prasad Netravalkar

MBBS, MD (Path)
GMC Reg. No. 1294

We Care

All Diagnostic facilities under one roof in Panaji centre - Lab, ultrasound, X ray, ECG, TMT, ECHO

DR. NETRAVALKAR'S ASHWINI PATHOLOGY LABORATORY

(For all investigations in Histopathology, Cytopathology, Haematology, Clinical Pathology, Microbiology & Hormonal Chemistry)

Consultant Pathologist **Dr. Prasad Netravalkar** MBBS, MD (Path) BOM

(HOME COLLECTION FACILITY AVAILABLE)

Panaji : 1st, Floor, Rizvi Sadan, Above Saroj Emporium, Near Inox Theatre, Opp. Municipal Market, Panaji.
Ph.: 2229142, 8407912840, 8390242524

E-mail : ashwinilabpanaji@gmail.com, drprasadnetravalkar@gmail.com

Mapusa : F8, Ramchandra Chambers, 1st Floor, Mapusa Clinic Road, Mapusa - Bardez, Goa Ph. 2252320

Patient Name : MR. SHIRODKAR CHANDA DHARMA

Age / Gender : 42 / Male

Patient ID : 32975

Source : DIRECT

Referral : SELF

Reporting Time : Jun 08, 2024, 02:08 p.m.

Sample ID :



Test Description	Value(s)	Reference Range	Unit
------------------	----------	-----------------	------

PSA (Prostate Specific Antigen)-Total



PSA- Prostate Specific Antigen*	2.21	0 - 4	ng/mL
---------------------------------	------	-------	-------

INTERPRETATION :

Prostate-specific antigen (PSA) is a glycoprotein that is produced by the prostate gland, the lining of the urethra, and the bulbourethral gland. PSA exists in serum mainly in two forms, complexed to alpha-1-anti-chymotrypsin (PSA-ACT complex) and unbound (free PSA). Increases in prostatic glandular size and tissue damage caused by benign prostatic hypertrophy, prostatitis, or prostate cancer may increase circulating PSA levels. Transient increase in PSA can also be seen following per rectal digital or sonological examinations.

Note: Patients on Biotin supplement may have interference in some immunoassays. With individuals taking high dose Biotin (more than 5 mg per day) supplements, at least 8-hour wait time before blood draw is recommended.

END OF REPORT



Dr. Prasad Netravalkar
MBBS, MD (Path) BOM
GMC Reg No. 1294

We Care

All Diagnostic facilities under one roof in Panaji centre - Lab, ultrasound, X ray, ECG, TMT, ECHO

INDIAN UNION DRIVING LICENCE
GOA STATE
FORM 7

Number: 45/28 2006 400000
 Name: KISHOR D. KISHOR D.
 State of: GOA
 Address: 91 NO 42 SHIRDI
 KARNATA P O PANAJI
 PANAJI GOA

Issued on: 20.06.2006
 Valid till: 20.06.2012

Vehicle Class	14	14	14	14	14
Date of issue	20.06.2006	20.06.2006			

Motorist's Signature: 

Motorist's Photo: 

Motorist's Address: 

Motorist's Date of Birth: 

Motorist's Sex: 

Motorist's Blood Group: 

Motorist's Height: 

Motorist's Weight: 

Motorist's Eye Color: 

Motorist's Eye Sight: 

Motorist's Medical Condition: 

Motorist's Physical Condition: 

Motorist's Psychological Condition: 

Motorist's Social Condition: 

Motorist's Moral Condition: 

Motorist's Character: 

Motorist's Personality: 

Motorist's Intelligence: 

Motorist's Education: 

Motorist's Occupation: 

Motorist's Social Status: 

Motorist's Family Status: 

Motorist's Marital Status: 

Motorist's Divorce Status: 

Motorist's Widower Status: 

Motorist's Single Status: 

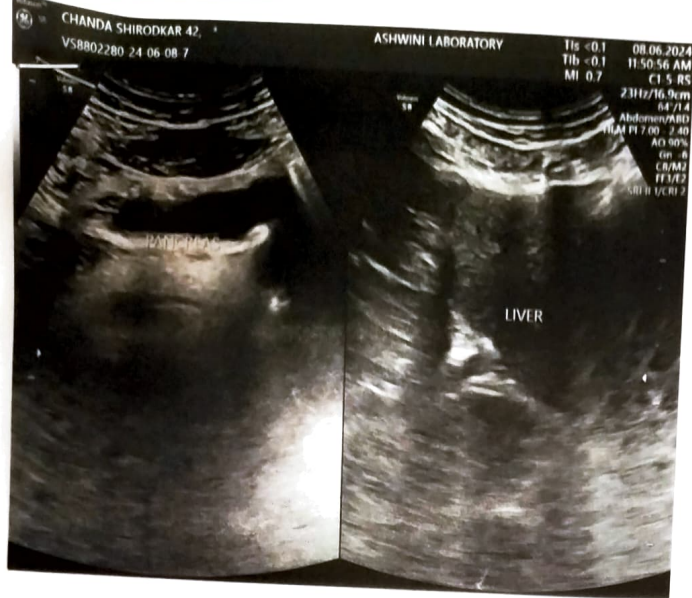
Motorist's Married Status: 

Handwritten signature

Large handwritten flourish



Handwritten signature



Dr. Ashadevi Netravalkar

MBBS., MD, AFIH

Consultant Radiologist & Sonologist

1 Market, Next to Vaidya Hospital, Panaji - Goa.
shanetravalkar@gmail.com

DATE: 08/06/2024

SEX: M

ULTRASONOGRAPHY OF ABDOMEN AND PELVIS

LIVER – It shows mild increased echotexture but normal size. No mass or focal lesions is seen.

Biliary and portal radicals appear normal. Length of right lobe of liver is 12.6cm. PV-9mm.

PANCREAS— It shows normal echotexture and size. No focal lesions are seen.

GALL BLADDER---It is moderately distended. No calculi are seen. GB wall thickness is 4mm.

Pericholecystic space appears normal. CBD is 3mm.

SPLEEN----- It shows normal echotexture and size. Length of spleen is 9.6cm.

BOTH KIDNEYS show normal echotexture and size. Corticomedullary junction appears normal.

No hydronephrosis or calculus is seen in both the kidneys. Perirenal space is normal.

Right kidney--measures 10cm x 5.2cms .

Left kidney—measures 10.3cms x 4.9cms.

Urinary Bladder is well distended . No calculus or mass is seen .Wall thickness is 3mm .Both

VUJs are normal.

FV-282ml. PVR is 56ml .

Prostate measures 4.6cms x 4.4cm x 3cms Weight is 33gms.

No calcification or mass is seen.

No free fluid is seen in pelvis. Plenty of bowel gases are seen.

Impression : Mild fatty liver.

Prostatomegaly with PVR.

With regards,

DR .ASHADEVI NETRAVALKAR, MD
RADIOLOGIST

201,202,203, Rizvi Sadan, 2nd Floor, Near Municipal Market, Next to Vaidya Hospital, Panaji - Goa.
Tel.: 0832 2238122 | Email : drashanetravalkar@gmail.com

NAME: MRS. CHANDA SHIRODKAR
AGE: 42/YRS
REF BY: DR.SELF

DATE: 10/10/2023
SEX:M

X-RAY CHEST--- PA VIEW

Lung fields are clear.

Both costophrenic angles are clear.


Borderline cardiomegaly is seen .

Both domes of diaphragm are normal.

Rib cage is normal.

IMPRESSION : Borderline cardiomegaly.To correlate with echocardiography.

With regards,



DR.ASHADEVI NETRAVALKAR,MD
RADIOLOGIST

PLEASE PRINT NAME AND SIGNATURE
DATE: 10/10/2023
TIME: 10:30 AM

201,202,203, Rizvi Sadan, 2nd Floor, Near Municipal Market, Next to Vaidya Hospital, Panaji - Goa
Tel: 0832 2238122 | Email: drashanetravalkar@gmail.com

Cardiology Report

Page 1/2

ASHWINI LABORATORY

Date of Exam 08.06.2024

Patient / Exam Information

Patient ID	VS8802280-24-06-08-7	Height
Name	CHANDA SHIRODKAR 42	Weight
DOB, Age		BSA
Sex	M	HR

Perf. Phys
Comment

Ref Phys
Indication

Sonographer

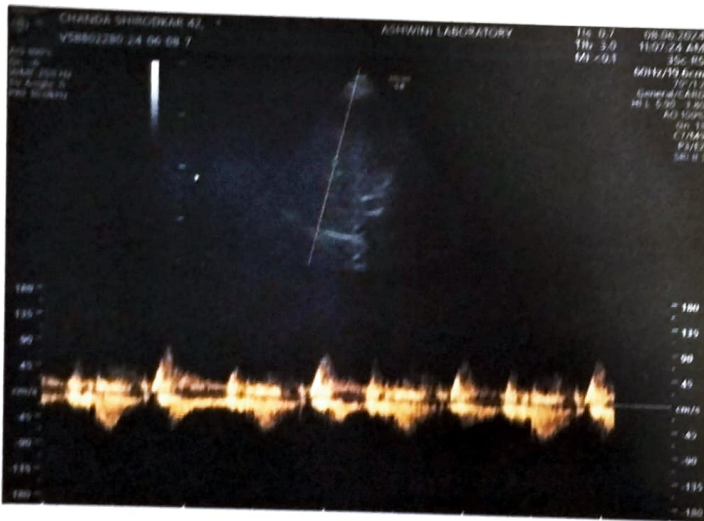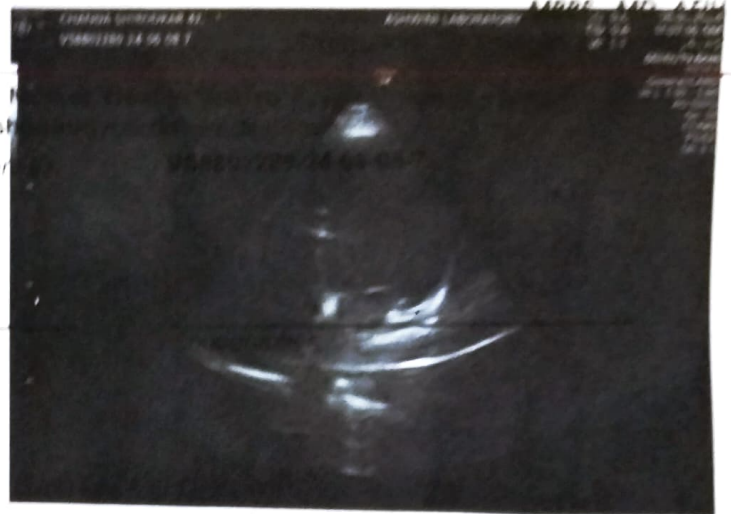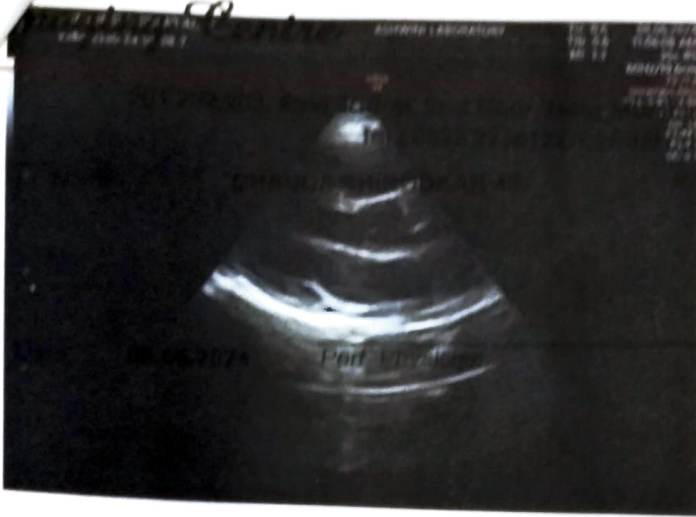M-Mode Measurements	Value	Sonographer						Moth
		m1	m2	m3	m4	m5	m6	
AVILA								avg.
Ao Root Diam.	2.65 cm		2.65					avg.
LA Diam.	3.14 cm		3.14					
Left Ventricle								avg.
IVSd	0.90 cm		0.90					avg.
LVDd	4.49 cm		4.49					avg.
LVPWd	0.90 cm		0.90					avg.
IVSs	1.45 cm		1.45					avg.
LVDs	2.99 cm		2.99					avg.
LVPWs	1.30 cm		1.30					
EDV (Teich)	91.964 ml		91.964					
EDV (Cubed)	90.519 ml		90.519					
ESV (Teich)	34.715 ml		34.715					
ESV (Cubed)	26.731 ml		26.731					
SV (Teich)	57.249 ml		57.249					
SV (Cube)	63.788 ml		63.788					
EF (Teich)	62.25 %		62.25					
EF (Cube)	70.47 %		70.47					
Fract. Short	33.41 %		33.41					
LV Mass	151.07 g		151.07					

Comment

NORMAL CARDIAC CHAMBERS DIMENSIONS. NORMAL BI VENTRICLE SYSTOLIC FUNCTION. NO REGIONAL WALL MOTION ABNORMALITIES. VALVES ARE NORMAL. AORTIC ROOT IS NORMAL. PERICARDIUM IS NORMAL.

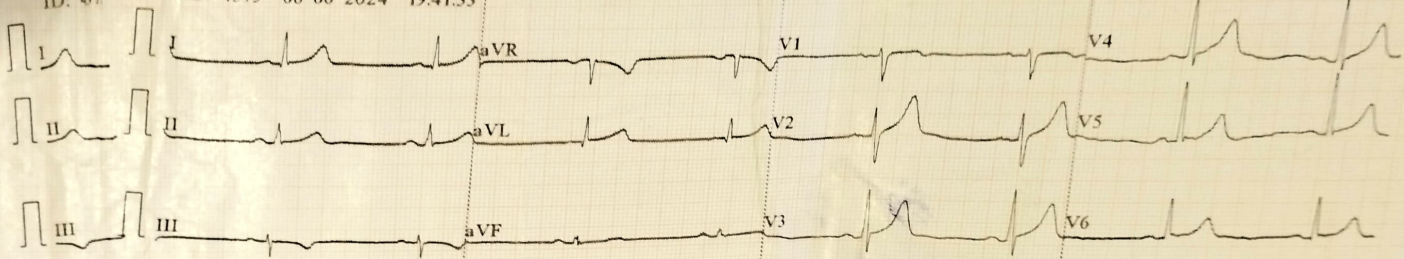
Ashadevi

1/2
08.06.2024 11:09:41 AM



ID: 457

ID: 4579 08-06-2024 19:41:33




0.5-100 0.5-100Hz 25mm/s 10mm/mV ♥47 V1.0 SEMIP V1.7

ID: 4579

Male / mmHg
42 Years cm kg

Dr. Netravalkar

HR	:	48	bpm
P	:	119	ms
PR	:	168	ms
QRS	:	79	ms
QT/QTc	:	439/396	ms
PQRST	:	60/20/14	°
RV5/SVI	:	1.329/0.560	mV



ECG shows sinus bradycardia

8/6/24

DR. SIGN.

**DR. NETRAVALKAR'S
ASHWINI PATHOLOGY LABORATORY**

(For all investigations in Histopathology, Cytopathology, Haematology, Clinical Pathology, Microbiology & Hormonal Chemistry)

Consultant Pathologist **Dr. Prasad Netravalkar** MBBS, MD (Path) BOM

(HOME COLLECTION FACILITY AVAILABLE)

Panaji : 1st, Floor, Rizvi Sadan, Above Saroj Emporium, Near Inox Theatre, Opp. Municipal Market, Panaji.
Ph.: 2229142, 8407912840, 8390242524

E-mail : ashwinilabpanaji@gmail.com, drprasadnetravalkar@gmail.com

Mapusa : F8, Ramchandra Chambers, 1st Floor, Mapusa Clinic Road, Mapusa - Bardez, Goa. Ph.: 2252320

Pt.No. : 61 080624

Pt.Name : Mr. Shirodkar Chanda Dharma

Age : 42 Yrs. Sex : M

Ref. By : -

Date : 08-06-2024

		Normal Range
Fasting Blood Sugar	: 93.0 mg/dl	70 - 110 mg/dl
2 Hrs. Blood Sugar	: 111.0 mg/dl	110 -140 mg/dl

GLYCOSYLATED HAEMOGLOBIN IN BLOOD (HPLC METHOD)

HbA1C : 5.40 %

Mean Blood Glucose : 107 mg %

INTERPRETATION:

HbA1c %

NORMAL

Below 6.5 %

GOOD DIABETIC CONTROL

6.5 % - 7.5 %

FAIR CONTROL



7.5 % - 8.0 %

UNSATISFACTORY CONTROL

8.0 % - 10.0 %

POOR CONTROL

Above 10.0 %



Dr. Prasad Netravalkar
MBBS, MD (Bom)
GMC Reg. No. 1294

We Care

All Diagnostic facilities under one roof in Panaji centre - Lab, ultrasound, X ray, ECG, TMT, ECHO

**DR. NETRAVALKAR'S
ASHWINI PATHOLOGY LABORATORY**

(For all investigations in Histopathology, Cytopathology, Haematology, Clinical Pathology, Microbiology & Hormonal Chemistry)

Consultant Pathologist **Dr. Prasad Netravalkar** MBBS MD (Path) BOM

(HOME COLLECTION FACILITY AVAILABLE)

Panaji : 1st, Floor, Rizvi Sadan, Above Saroj Emporium, Near Inox Theatre, Opp. Municipal Market, Panaji.

Ph.: 2229142, 8407912840, 8390242524

E-mail : ashwinilabpanaji@gmail.com, drprasadnetravalkar@gmail.com

Mapusa : F8, Ramchandra Chambers, 1st Floor, Mapusa Clinic Road, Mapusa - Bardez, Goa. Ph. 2252320

Pt.No. : 61 080624

Pt.Name : Mr. Shirodkar Chanda Dharma

Age : 42 Yrs. Sex : M



Ref. By : -

Date : 08-06-2024

Normal Range

LIPID PROFILE

Total Cholesterol	: 171.0 mg/dl	130 - 220 mg/dl
S. Triglycerides	: 81.0 mg/dl	35 - 170 mg/dl
HDL Cholesterol	: 37.0 mg/dl	> 35 mg/dl
LDL Cholesterol	: 118 mg/dl	< 130 mg/dl
VLDL Cholesterol	: 16 mg/dl	Upto 35 mg/dl
TC/HDLC Ratio	: 4.6	< 4.5
LDLC/HDLC Ratio	: 3.2	2.5 - 3.5



Dr. Prasad Netravalkar
MBBS, MD (Bom)
GMC Reg. No. 1294

We Care

All Diagnostic facilities under one roof in Panaji centre - Lab, ultrasound, X ray, ECG, TMT, ECHO

DR. NETRAVALKAR'S ASHWINI PATHOLOGY LABORATORY

(For all investigations in Histopathology, Cytopathology, Haematology, Clinical Pathology, Microbiology & Hormonal Chemistry)

Consultant Pathologist **Dr. Prasad Netravalkar** MBBS MD (Path) BOM

(HOME COLLECTION FACILITY AVAILABLE)

Panaji : 1st, Floor, Rizvi Sadan, Above Saroj Emporium, Near Inox Theatre, Opp. Municipal Market, Panaji.

Ph.: 2229142, 8407912840, 8390242524

E-mail : ashwinilabpanaji@gmail.com, drprasadnetravalkar@gmail.com

Mapusa : F8, Ramchandra Chambers, 1st Floor, Mapusa Clinic Road, Mapusa - Bardez, Goa Ph - 2252320

Pt.No. : 61 080624

Pt.Name : Mr. Shirodkar Chanda Dharma

Age : 42 Yrs. Sex : M

Ref. By : -

Date : 08-06-2024

Normal Range

LIVER FUNCTION TEST

S. Bilirubin (Total)	: 1.40	mg/dl	0 - 1 mg/dl
S. Bilirubin (Direct)	: 0.45	mg/dl	0 - 0.25 mg/dl
S. Bilirubin (Indirect)	: 0.95	mg/dl	0 - 0.75 mg/dl
S.G.O.T	: 22.0	U/L	0 - 42 U/L
S.G.P.T	: 18.0	U/L	0 - 42 U/L
S. Alkaline Phosphatase	: 59.0	IU/L	15 - 112 IU/L
GGTP	: 21.0	U/L	11-43 U/L
Total Proteins	: 6.50	g/dl	6.0 - 10.0 g/dl
S. Albumin	: 4.10	gm%	3.2 - 5.5 gm%
S. Globulin	: 2.4	g/dl	2.3 - 3.5 g/dl
A/G Ratio	: 1.7 : 1		



Dr. Prasad Netravalkar
MBBS, MD (Bom)
GMC Reg No. 1294

We Care

All Diagnostic facilities under one roof in Panaji centre - Lab, ultrasound, X ray, ECG, TMT, EPT

DR. NETRAVALKAR'S ASHWINI PATHOLOGY LABORATORY

(For all investigations in Histopathology, Cytopathology, Haematology, Clinical Pathology, Microbiology & Hormonal Chemistry)

Consultant Pathologist **Dr. Prasad Netravalkar** MBBS, MD (Path) BOM

(HOME COLLECTION FACILITY AVAILABLE)

Panaji : 1st, Floor, Rizvi Sadan, Above Saroj Emporium, Near Inox Theatre, Opp. Municipal Market, Panaji.

Ph.: 2229142, 8407912840, 8390242524

E-mail : ashwinilabpanaji@gmail.com, drprasadnetravalkar@gmail.com

Mapusa : F8, Ramchandra Chambers, 1st Floor, Mapusa Clinic Road, Mapusa - Bardez, Goa. Ph - 2252320

Pt.No. : 61 080624

Pt.Name : Mr. Shirodkar Chanda Dharma

Age : 42 Yrs. Sex : M

Ref. By : -

Date : 08-06-2024

Normal Range

COMPLETE HEMOGRAM

Haemoglobin	: 14.6	g/dl	13.5 - 18 g/dl
W.B.C Count	: 6600	cells/ cu-mm	4000 - 11000 cells/ cu-mm
R.B.C Count	: 4.94	millions / cu-mm	4.5 - 6.5 millions / cu-mm
MCV	: 83.5	fl	80 - 96 fl
MCH	: 29.4	Pg	27 - 33 Pg
MCHC	: 35.2	%	32 - 37 %
PCV	: 41.3	%	40 - 54 %
Platelet Count	: 1.83	lakhs /cu mm	1.5 - 4.5 lakhs /cu mm
E.S.R (Westergren)	: 13	mm/hr	0 - 20 mm/hr

DIFFERENTIAL COUNT

Stab Cells	: 03	%	1-5 %
Neutrophils	: 39	%	40 - 60 %
Lymphocytes	: 44	%	20 - 45 %
Eosinophils	: 08	%	1 - 6 %
Monocytes	: 06	%	0 - 10 %
Basophils	: 00	%	0 - 1 %
Abnormal Cells	: Nil		

SMEAR EXAMINATION

RBC Morphology	: Normocytic , Normochromic
W.B.C Morphology	: Within Normal Limits
Platelets on Smear	: Adequate
Parasites	: Absent
Blood Group	: 'O' Rh Positive



Dr. Prasad Netravalkar
MBBS, MD (Bom)
GMC Reg. No. 1294

We Care

All Diagnostic facilities under one roof in Panaji centre - Lab, ultrasound, X ray, ECG, TMT, ECHO

**DR. NETRAVALKAR'S
ASHWINI PATHOLOGY LABORATORY**

(For all investigations in Histopathology, Cytopathology, Haematology, Clinical Pathology, Microbiology & Hormonal Chemistry)

Consultant Pathologist **Dr. Prasad Netravalkar** MBBS MD (Path) BOM

(HOME COLLECTION FACILITY AVAILABLE)

Panaji : 1st, Floor, Rizvi Sadan, Above Saroj Emporium, Near Inox Theatre, Opp. Municipal Market, Panaji.
Ph.: 2229142, 8407912840, 8390242524

E-mail : ashwinilabpanaji@gmail.com, drprasadnetravalkar@gmail.com

Mapusa : FS, Ramchandra Chambers, 1st Floor, Mapusa Clinic Road, Mapusa - Bardez, Goa Ph - 2252320

Pt.No. : 61 080624

Pt.Name : Mr. Shirodkar Chanda Dharma

Age : 42 Yrs. Sex : M

Ref. By : -

Date : 08-06-2024

BIOCHEMISTRY REPORTS

Fasting Urine Glucose : Absent

2 Hrs. Urine Glucose : Absent


Pathologist

Dr. Prasad Netravalkar
MBBS, MD (Bom)
GMC Reg No. 1294

We Care

All Diagnostic facilities under one roof in Panaji centre - Lab, ultrasound, X ray, ECG, TMT, ECHO

DR. NETRAVALKAR'S
ASHWINI PATHOLOGY LABORATORY

(For all investigations in Histopathology, Cytopathology, Haematology, Clinical Pathology, Microbiology & Hormonal Chemistry)

Consultant Pathologist **Dr. Prasad Netravalkar** MBBS, MD (Path) DDM

(HOME COLLECTION FACILITY AVAILABLE)

Panaji : 1st, Floor, Rizvi Sadan, Above Saroj Emporium, Near Inox Theatre, Opp. Municipal Market, Panaji
Ph.: 2229142, 8407912840, 8390242524

E-mail : ashwinilabpanaji@gmail.com, drprasadnetravalkar@gmail.com

Mapusa : F8, Ramchandra Chambers, 1st Floor, Mapusa Clinic Road, Mapusa - Bardez, Goa. Ph. 2252120

Pt.No. : 61 080624

Pt.Name : Mr. Shirodkar Chanda Dharma

Age : 42 Yrs. Sex : M

Ref. By : -

Date : 08-06-2024

EXAMINATION OF URINE

PHYSICAL EXAMINATION


Quantity : 20 ml
Colour : Pale Yellow
Appearance : Slightly Hazy
pH : 6.5
Specific Gravity : 1.010

CHEMICAL EXAMINATION

Proteins : Absent
Glucose : Absent
Ketone Bodies : Absent
Bile Salts : Absent
Bile Pigments : Absent
Occult Blood : Negative
Urobilinogen : Normal

MICROSCOPIC EXAMINATION [As per hpf]

Epithelial Cells : 2 - 3 /hpf
Pus Cells : 10 - 12 /hpf
Red Blood Cells : Absent
Casts : Absent
Crystals : Absent



Dr. Prasad Netravalkar
MBBS, MD (Path)
GMC Reg. No. 1294

We Care

All Diagnostic facilities under one roof in Panaji centre - Lab, ultrasound, X ray, ECG, TMT, ECHO

DR. NETRAVALKAR'S ASHWINI PATHOLOGY LABORATORY

(For all investigations in Histopathology, Cytopathology, Haematology, Clinical Pathology, Microbiology & Hormonal Chemistry)

Consultant Pathologist **Dr. Prasad Netravalkar** MBBS, MD (Path) BOM

(HOME COLLECTION FACILITY AVAILABLE)

Panaji : 1st, Floor, Rizvi Sadan, Above Saroj Emporium, Near Inox Theatre, Opp. Municipal Market, Panaji.
Ph.: 2229142, 8407912840, 8390242524

E-mail : ashwinilabpanaji@gmail.com, drprasadnetravalkar@gmail.com

Mapusa : F8, Ramchandra Chambers, 1st Floor, Mapusa Clinic Road, Mapusa - Bardez, Goa Ph 2252320

Patient Name : MR. SHIRODKAR CHANDA DHARMA

Referral : SELF

Age / Gender : 42 / Male

Reporting Time : Jun 08, 2024, 02:08 p.m.

Patient ID : 32975

Sample ID :



Source : DIRECT

Test Description	Value(s)	Reference Range	Unit
Thyroid Profile			
T3 (Total) Method : Serum ECL	1.57	1.30 - 3.10	nmol/l
T4 (Total)* Method : Serum ECL	96.29	66.0 - 181.0	nmol/l
TSH(Ultrasensitive)* Method : Serum ECL	3.35	0.270 - 4.20	uIU/ml

END OF REPORT

Pathologist

Dr. Prasad Netravalkar

MBBS, MD (Path)
GMC Reg. No. 1294

We Care

All Diagnostic facilities under one roof in Panaji centre - Lab, ultrasound, X ray, ECG, TMT, ECHO

DR. NETRAVALKAR'S ASHWINI PATHOLOGY LABORATORY

(For all investigations in Histopathology, Cytopathology, Haematology, Clinical Pathology, Microbiology & Hormonal Chemistry)

Consultant Pathologist **Dr. Prasad Netravalkar** MBBS, MD (Path) BOM

(HOME COLLECTION FACILITY AVAILABLE)

Panaji : 1st, Floor, Rizvi Sadan, Above Saroj Emporium, Near Inox Theatre, Opp. Municipal Market, Panaji.
Ph.: 2229142, 8407912840, 8390242524

E-mail : ashwinilabpanaji@gmail.com, drprasadnetravalkar@gmail.com

Mapusa : F8, Ramchandra Chambers, 1st Floor, Mapusa Clinic Road, Mapusa - Bardez, Goa Ph. 2252320

Patient Name : MR. SHIRODKAR CHANDA DHARMA

Age / Gender : 42 / Male

Patient ID : 32975

Source : DIRECT

Referral : SELF

Reporting Time : Jun 08, 2024, 02:08 p.m.

Sample ID :



Test Description	Value(s)	Reference Range	Unit
------------------	----------	-----------------	------

PSA (Prostate Specific Antigen)-Total



PSA- Prostate Specific Antigen*	2.21	0 - 4	ng/mL
---------------------------------	------	-------	-------

INTERPRETATION :

Prostate-specific antigen (PSA) is a glycoprotein that is produced by the prostate gland, the lining of the urethra, and the bulbourethral gland. PSA exists in serum mainly in two forms, complexed to alpha-1-anti-chymotrypsin (PSA-ACT complex) and unbound (free PSA). Increases in prostatic glandular size and tissue damage caused by benign prostatic hypertrophy, prostatitis, or prostate cancer may increase circulating PSA levels. Transient increase in PSA can also be seen following per rectal digital or sonological examinations.

Note: Patients on Biotin supplement may have interference in some immunoassays. With individuals taking high dose Biotin (more than 5 mg per day) supplements, at least 8-hour wait time before blood draw is recommended.

END OF REPORT



Dr. Prasad Netravalkar
MBBS, MD (BOM)
GMC Reg No 1294

We Care

All Diagnostic facilities under one roof in Panaji centre - Lab, ultrasound, X ray, ECG, TMT, ECHO

INDIAN UNION DRIVING LICENCE
GOA STATE
FORM 7

Number: 14/07/2006-4000000
Name: KISHOR D. KISHOR D.
State of: GOA
Address: 91 NO 42 SHIRDI
City/Town: KARMALI, P. O. KARMALI
District: TORNALE, GOA

Issued on: 20/06/2006
Valid till: 20/06/2012

Vehicle Class: 14-17
Date of issue: 20/06/2006

Min of Transport
Min of Highways

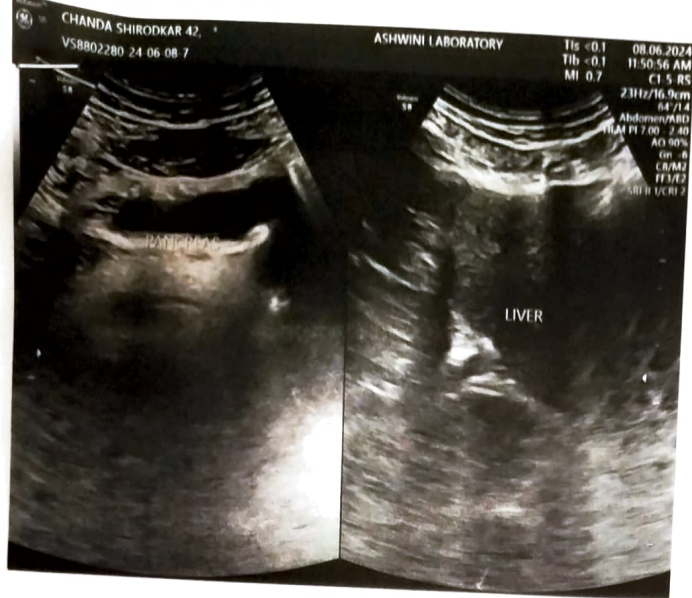



Handwritten signature

Large handwritten mark



Handwritten signature



Dr. Ashadevi Netravalkar

MBBS., MD, AFIH

Consultant Radiologist & Sonologist

1 Market, Next to Vaidya Hospital, Panaji - Goa.
shanetravalkar@gmail.com

DATE: 08/06/2024

SEX: M

ULTRASONOGRAPHY OF ABDOMEN AND PELVIS

LIVER – It shows mild increased echotexture but normal size. No mass or focal lesions is seen.

Biliary and portal radicals appear normal. Length of right lobe of liver is 12.6cm. PV-9mm.

PANCREAS— It shows normal echotexture and size. No focal lesions are seen.

GALL BLADDER---It is moderately distended. No calculi are seen. GB wall thickness is 4mm.

Pericholecystic space appears normal. CBD is 3mm.

SPLEEN----- It shows normal echotexture and size. Length of spleen is 9.6cm.

BOTH KIDNEYS show normal echotexture and size. Corticomedullary junction appears normal.

No hydronephrosis or calculus is seen in both the kidneys. Perirenal space is normal.

Right kidney--measures 10cm x 5.2cms .

Left kidney—measures 10.3cms x 4.9cms.

Urinary Bladder is well distended . No calculus or mass is seen .Wall thickness is 3mm .Both

VUJs are normal.

FV-282ml. PVR is 56ml .

Prostate measures 4.6cms x 4.4cm x 3cms Weight is 33gms.

No calcification or mass is seen.

No free fluid is seen in pelvis. Plenty of bowel gases are seen.

Impression : Mild fatty liver.

Prostatomegaly with PVR.

With regards,

DR .ASHADEVI NETRAVALKAR, MD
RADIOLOGIST

201,202,203, Rizvi Sadan, 2nd Floor, Near Municipal Market, Next to Vaidya Hospital, Panaji - Goa.
Tel.: 0832 2238122 | Email : drashanetravalkar@gmail.com

NAME: MRS. CHANDA SHIRODKAR
AGE: 42/YRS
REF BY: DR.SELF

DATE: 10/10/2023
SEX:M

X-RAY CHEST--- PA VIEW

Lung fields are clear.

Both costophrenic angles are clear.


Borderline cardiomegaly is seen .

Both domes of diaphragm are normal.

Rib cage is normal.

IMPRESSION : Borderline cardiomegaly.To correlate with echocardiography.

With regards,



DR.ASHADEVI NETRAVALKAR,MD
RADIOLOGIST

PLACED IN THE FILE
ON 10/10/2023
BY: [Signature]

201, 202, 203, Rizvi Sadan, 2nd Floor, Near Municipal Market, Next to Vaidya Hospital, Panaji - Goa
Tel: 0832 2238122 | Email: drashanetravalkar@gmail.com

Cardiology Report

Page 1/2

ASHWINI LABORATORY

Date of Exam 08.06.2024

Patient / Exam Information

Patient ID	VS8802280-24-06-08-7	Height
Name	CHANDA SHIRODKAR 42	Weight
DOB, Age		BSA
Sex	M	HR

Perf. Phys
Comment

Ref Phys
Indication

Sonographer

M-Mode Measurements	Value	Sonographer						Moth
		m1	m2	m3	m4	m5	m6	
AVILA								avg.
Ao Root Diam.	2.65 cm		2.65					avg.
LA Diam.	3.14 cm		3.14					
Left Ventricle								avg.
IVSd	0.90 cm		0.90					avg.
LVDd	4.49 cm		4.49					avg.
LVPWd	0.90 cm		0.90					avg.
IVSs	1.45 cm		1.45					avg.
LVDs	2.99 cm		2.99					avg.
LVPWs	1.30 cm		1.30					
EDV (Teich)	91.964 ml		91.964					
EDV (Cubed)	90.519 ml		90.519					
ESV (Teich)	34.715 ml		34.715					
ESV (Cubed)	26.731 ml		26.731					
SV (Teich)	57.249 ml		57.249					
SV (Cube)	63.788 ml		63.788					
EF (Teich)	62.25 %		62.25					
EF (Cube)	70.47 %		70.47					
Fract. Short	33.41 %		33.41					
LV Mass	151.07 g		151.07					

Comment

NORMAL CARDIAC CHAMBERS DIMENSIONS. NORMAL BI VENTRICLE SYSTOLIC FUNCTION. NO REGIONAL WALL MOTION ABNORMALITIES. VALVES ARE NORMAL. AORTIC ROOT IS NORMAL. PERICARDIUM IS NORMAL.

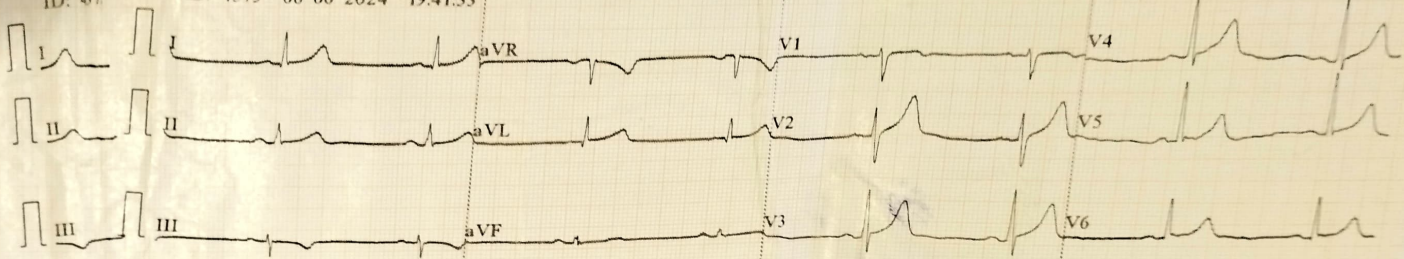
Ashadevi

1/2
08.06.2024 11:09:41 AM



ID: 457

ID: 4579 08-06-2024 19:41:33




0.5-100 0.5-100Hz 25mm/s 10mm/mV ♥47 V1.0 SEMIP V1.7

ID: 4579

Male / mmHg
42 Years cm kg

Dr. Netravalkar

HR	:	48	bpm
P	:	119	ms
PR	:	168	ms
QRS	:	79	ms
QT/QTc	:	439/396	ms
PQRST	:	60/20/14	°
RV5/SV1	:	1.329/0.560	mV



ECG shows sinus bradycardia

8/6/24

DR. SIGN.