


MER- MEDICAL EXAMINATION REPORT

Date of Examination	10/05/2024		
NAME	MRS. SHWETA KOTHARI		
AGE	38	Gender	female
HEIGHT(cm)	142 CM	WEIGHT (kg)	49 kg
B.P.	120/80		
ECG	Normal		
X Ray	Normal		
Vision Checkup	Normal		
Present Ailments	-		
Details of Past ailments (If Any)	-		
Comments / Advice : She / He is Physically Fit	Fit		
<p>BMI = 24.3 kg/m² (Normal)</p>			

Panel Medical Examiner
 Triveni Diagnostic & Research Centre
 Agrawal Plaza, B-7, H.I.G Main Road,
 INDORE



 Signature with Stamp of Medical Examiner
Dr. Mukesh Dubey
 (MBBS DCP)
 Registration No.-10632


 भारत सरकार
GOVERNMENT OF INDIA

 श्वेता जैन
Shweta Jain
जन्म वर्ष / Year of Birth : 1986
महिला / Female





6667 9651 5564


आधार — आम आदमी का अधिकार


 भारतीय विशिष्ट पहचान प्राधिकरण
UNIQUE IDENTIFICATION AUTHORITY OF INDIA

पता: D/O हेमन्त जैन, भारत माता मंदिर के पास, बी/एम ८० मुखलिया, इंदौर, विजय नगर, मध्य प्रदेश, 452010
Address: D/O Hemant Jain, Bharat mata mandir ke pass, B/M 80 sukhlia, Indore, Vijay Nagar, Madhya Pradesh, 452010

 1947
1800 180 1947

 help@uidai.gov.in

 www.uidai.gov.in

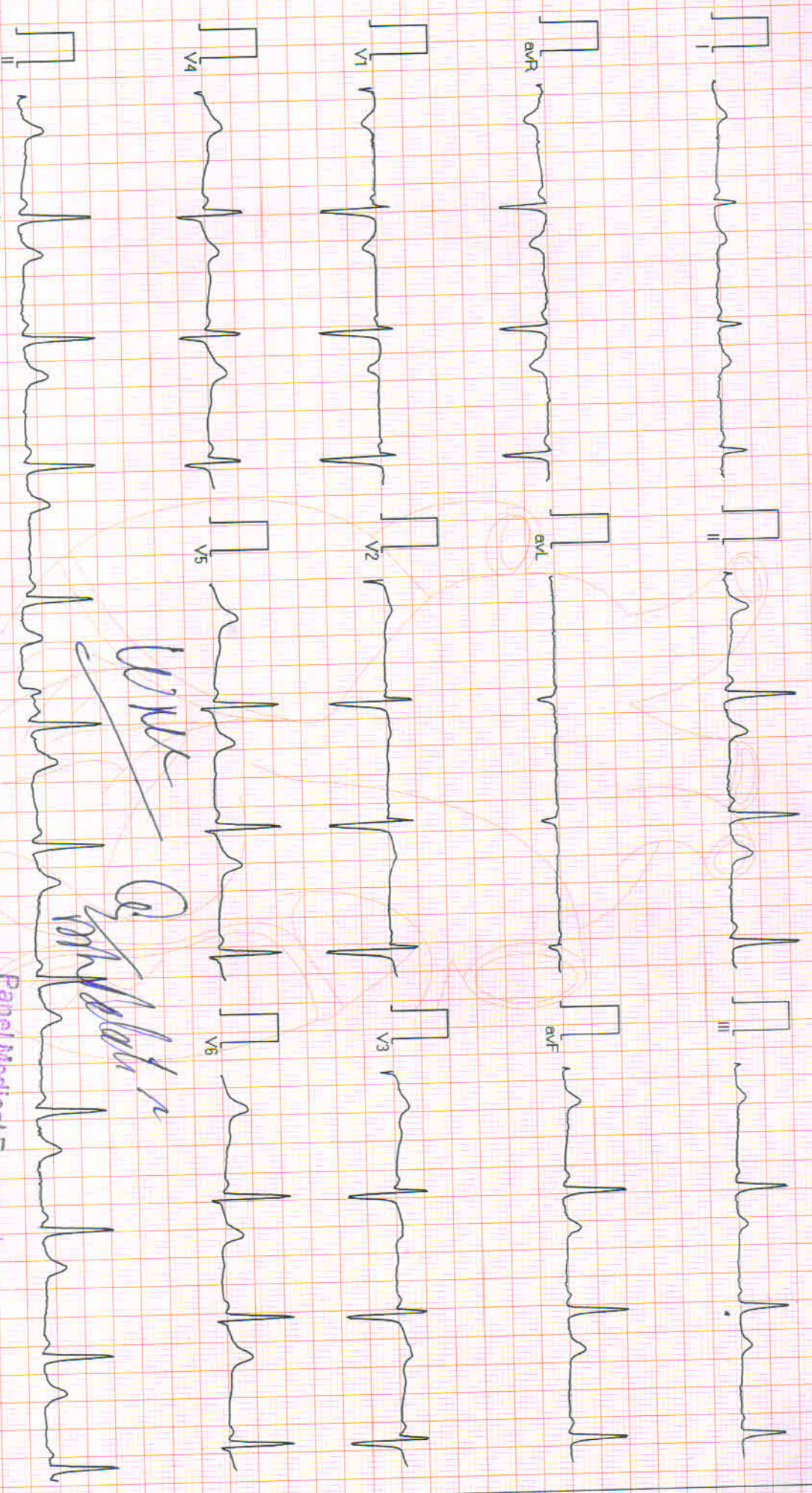
 P.O. Box No.1947,
Bengaluru-560 001

Panel Medical Examiner
Triveni Diagnostic & Research Centre
Agrawal Plaza, B-7, H.I.G. Main Road,
INDORE



TRIVENI DIAGNOSTIC AND RESEARCH CENTER INDORE

626 / MRS. SWETA KOTHARI / 38 Yrs / F / Non Smoker
Heart Rate : 67 bpm / Tested On : 10-Jun-24 09:56:00 / HF 0.05 Hz - LF 20 Hz / Notch 50 Hz / Sn 1.00 Cm/mV / Sw 25 mm/s
/ Refd By: ..

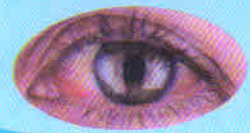

Vent Rate : 67 bpm
PR Interval : 106 ms
QRS Duration: 84 ms
QT/QTc Int : 392/404 ms
P-QRS-T axis: 52.00 • 71.00 • 61.00

Panel Medical Examiner

Triveni Diagnostic & Research Centre
Agrawal Plaza, B-7, H.I.G Main Road,

INDORE
Reported By:



डॉ. मनोज भटनागर

एम.एस.

नेत्र रोग विशेषज्ञ एवं सर्जन

C6 Jivex

Reg. No. 5453

Rx

Shweta Kothari

विशेषज्ञ

- ◆ इन्ट्राऑक्यूलर लेंस इम्प्लांट
- ◆ फेको विधि द्वारा बगैर टांके का मोतियाबिंद ऑपरेशन
- ◆ कॉन्टैक्ट लेंस विशेषज्ञ
- ◆ लेसिक लेजर (चश्मा उतारने की विधि)

3822

दिनांक 10-6-24

Vision 8/5
6/6

Near Vision N/A

Colour Vision Normal

Ext Exam N/A

Fundus (RE) N/A

समय : दोप 12 से 2 एवं शाम 6 से 9 एवं रविवार एपॉईमेन्ट द्वारा

क्लिनिक : ई-4, एच,आई.जी. कॉलोनी, एच,आई.जी. मेन रोड (क्रिश्चियन ऐमिनेन्ट स्कूल एवं एल.आई.जी चौराहे के बीच), इन्दौर (म.प्र.)

मो. : 94250-73027

Dr. Bhatnagar's Multispeciality Dental Clinic

Dr. Nikita Bhatnagar

B.D.S., M.D.S. (Gold Medalist)

Reg. No. A-3503

Mob. : 96699-37000

Clinic: E-4, HIG Colony, HIG Main Road
Indore-452011 (M.P.)

डॉ. निकिता भटनागर

बी.डी.एस., एम.डी.एस., (गोल्ड मेडलिस्ट)

रजि. नं. ए-3503

मो. : 96699-37000

क्लीनिक: ई-4, एच.आई.जी. काश्लोनी, एच.आई.जी. मेनरोड
इन्दौर-452011 (म.प्र.)

Ms. Shweta Kothari

Date 10/08/2024

Steline gum paint (for massaging
on gums for 2-3 min then rinse with water)

Residue-M gel (for local
applicⁿ on gums)

Denti-91 on/w.

Hydent pro - toothpaste

Lubriasm Saline gargles

Sab Mennicare plus (14)

[—————] x 7 days

Nikita

COSMETIC DENTISTRY

- Smile designing
- Teeth whitening & bleaching
- Tooth jewellery
- Composite & ceramic veneers
- Invisalign / Orthodontic braces
- Tooth colored fillings

GENERAL DENTISTRY

- Instant Dental X-rays
- Root Canal Treatment
- Gum treatment
- Atraumatic Extractions
- Wisdom tooth treatment
- Crown and bridges

PREVENTIVE DENTISTRY

- Teeth cleaning & polishing
- Fluoride application
- Treatment for Precancerous
- Conditions & lesions
- Tobacco chewing habit cessation

GERIATRIC DENTISTRY

- Dental Implants
- Dentures
- Oro-facial pain
- TMJ Disorders
- Snoring while sleeping

0/e -
C # Missing 4 / 4
S #

Adv: Complete oral prophylaxis.

1
Nikita



Triveni Diagnostic Centre

Reg. No. : 90643

Visit ID : 000095229

Patient Name : MRS. SHWETA KOTHARI

Age / Sex : 38 YEARS / FEMALE

Order Date : 11/06/24 07:33PM

Ref. By : Dr. ARCOFEMI HEALTHCARE LIMITED

Report Date : 11/06/24 07:35PM

X-RAY X-RAY CHEST PA

Trachea is central.

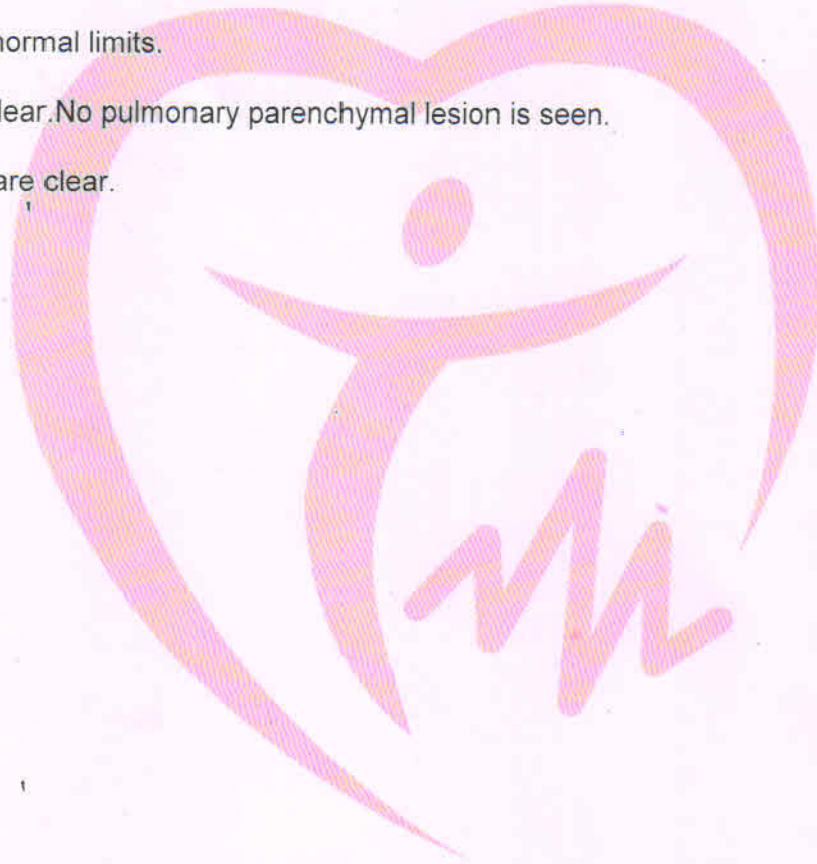
Bony rib cage and soft tissue wall of the thorax are normal.

Cardiac size is within normal limits.

Both lungs fields are clear.No pulmonary parenchymal lesion is seen.

Costo-phrenic angles are clear.

Kindly correlate.



DR. MUKESH DUBEY
(MBBS, DCP)

DR. VIJAY BHURIYA
MBBS DMRD

DR. AMIT SHANKHWAR
M.D. RADIO DIAGNOSIS

DR. P.S. TRIPATHI
M.D. (RADIO DIAGNOSIS)

DR. SANJAY YADAV
CONSULTANT MICROBIOLOGIST

Note: This report is not valid for medico legal purpose.
Address : Agrawal Plaza, B-7, HIG Main Road, Indore Ph. : 0731-4289992-3
Website : www.trivenidiagnostic.com email : trivenidiagnostic@yahoo.co.in

Page 1 of 1



Triveni Diagnostic Centre

Reg No. : 90643 VISITID : 0000095229
PATIENT NAME : MRS. SHWETA KOTHARI SPEC. NO : 1905422009
AGE/SEX : 38 YEARS/FEMALE SAMP. DATE : 10/06/2024 13:08:00
REF. BY : Dr. ARCOFEMI HEALTHCARE LIMITED RESULT DATE : 11/06/2024 19:28:57

HEMATOLOGY

CBC (COMPLETE BLOOD COUNT)

NAME OF TEST	RESULT VALUE	REFERENCE RANGE	UNIT
HAEMOGLOBIN	11.3	12.5 - 16	gm/dl
TOTAL RBC COUNT	4.9	4 - 6.5	mill/cummm
HAEMATOCRIT (PCV)	37.1	35.9 - 44.6	%
MEAN CORPUS VOL(MCV)	75.71	80 - 96	f l
MEAN CORPUS HB (MCH)	23.06	27.5 - 33.2	picograms
MEAN CORPUS HB CONC (MCHC)	30.46	33.4 - 35.5	%
RDW	14.9	11.5 - 15.5	%
PDW	11.3	-	f l
MPV	10.1	-	f l
PCT	0.35	-	%
P-LCR	23.7	-	%
TOTAL WBC	6300	4000 - 11000	/cumm
PLATELET COUNT	3.47	1.5 - 4.0	Lacs/cumm
DIFFERENTIAL COUNT			
NEUTROPHILS	69	40 - 70	%
LYMPHOCYTES	24	20 - 40	%
MONOCYTES	02	1 - 8	%
EOSINOPHILS	05	0 - 6	%
BASOPHILS	00	0 - 1	%
ABSOLUTE NEUTROPHILS	4.22	2 - 7	X1000/cumm
ABSOLUTE LYMPHOCYTES	1.57	1 - 3	X1000/cumm
ABSOLUTE MONOCYTE	0.10	0.2 - 1	X1000/cumm
ABSOLUTE EOSINOPHIL	0.42	0.02 - 0.5	X1000/cumm
ABSOLUTE BASOPHIL	00	0.02 - 0.1	X1000/cumm
ESR	12	0 - 20	mm at end of 1
MP (MALARIA PARASITE)			

METHOD:- By five part automated analyzer (sysmex XS1000 i) Japan

DR. MUKESH DUBEY
(MBBS, DCP) (DIRECTOR)

DR. VIJAY BHURIYA
MBBS DMRD

DR. YOGESH PAWDE
M. D. (CONS. PATHOLOGIST)

DR. P.S. TRIPATHI
M.D. (RADIO DIAGNOSIS)

DR. SANJAY YADAV
CON. MICROBIOLOGIST

Report Checked By:

Address : Agrawal Plaza, B-7, HIG Main Road, Indore Ph. : 0731-4289992-3
Website : www.trivenidiagnostic.com email : trivenidiagnostic@yahoo.co.in

Page 1 of 1



Triveni Diagnostic Centre

Reg No. : 90643 VISITID : 0000095229
PATIENT NAME : MRS. SHWETA KOTHARI SPEC. NO : 1905422004
AGE/SEX : 38 YEARS/FEMALE SAMP. DATE : 10/06/2024 13:08:00
REF. BY : Dr. ARCOFEMI HEALTHCARE LIMITED RESULT DATE : 11/06/2024 19:29:19

NAME OF TEST	RESULT VALUE		REFERENCE RANGE	UNIT
	IN RANGE	OUT RANGE		
LFT (LIVER FUNCTION TEST)				
TOTAL BILIRUBIN	0.87		0.2 - 1.3	mg/dL
DIRECT BILIRUBIN	0.55		0.2 - 0.65	mg / dl
INDIRECT BILIRUBIN	0.32		0.2 - 0.8	mg / dl
SGOT(AST)	27		0 - 40	U / L
SGPT(ALT)	31		0 - 40	U / L
ALKALINE PHOSPHATASE	101		37 - 143	U / L
PROTEINS	7.10		6 - 8.3	g / dl
ALBUMIN	4.23		3.5 - 5	gm/dl
GLOBULIN	2.87		1.9 - 3.5	g / dl
A.G.RATIO	1.47		0.5 - 2	mg / dl
PT (PROTHROMBIN TIME)		14	-	seconds
CONTROL		14	-	seconds
(INR) INTERNATIONALNARMLISED RATIO		1.0	-	.

REMARKS :

METHOD: BY COBAS INTEGRA 400 PLUS.

DR. MUKESH DUBEY
(MBBS, DCP) (DIRECTOR)

DR. VIJAY BHURIYA
MBBS DMRD

DR. YOGESH PAWDE
M. D. (CONS. PATHOLOGIST)

DR. P.S. TRIPATHI
M.D. (RADIO DIAGNOSIS)

DR. SANJAY YADAV
CON. MICROBIOLOGIST

Report Checked By :

Address : Agrawal Plaza, B-7, HIG Main Road, Indore Ph. : 0731-4289992-3
Website : www.trivenidiagnostic.com email : trivenidiagnostic@yahoo.co.in



Triveni Diagnostic Centre

Reg No. : 90643 VISITID : 0000095229
PATIENT NAME : MRS. SHWETA KOTHARI SPEC. NO : 1905422004
AGE/SEX : 38 YEARS/FEMALE SAMP. DATE : 10/06/2024 13:08:00
REF. BY : Dr. ARCOFEMI HEALTHCARE LIMITED RESULT DATE : 11/06/2024 19:29:46

BIO-CHEMISTRY

NAME OF TEST	RESULT VALUE	REFERENCE RANGE	UNIT
LIPID PROFILE			
CHOLESTEROL	151	0 - 200	mg / dl
TRIGLYCERIDES	127	50 - 190	mg / dl
HDL(HIGH DENSITY LIPIDS)	41	35 - 65	mg / dl
LDL	84.6	50 - 190	mg / dl
VLDL (VERY LOW DENSITY LIPIDS)	25.4	15 - 30	mg / dl
Cholestról : HDL	3.68*	3.5 - 5.5	
LDL : HDL	2.06	0 - 3.5	mg / dl

RESULT REMARKS : Test done by -"Roche COBAS- ENTEGRA 400 PLUS "fully bichemistry analyser .

RENAL PROFILE

UREA	21	10 - 40	mg / dl
CREATININE	0.79	0.6 - 1.2	mg / dl
SERUM SODIUM	140.2	135 - 155	mmol/L
SERUM POTASIUM	4.12	3.5 - 5.5	mmol/L

RESULT REMARKS :

DR. MUKESH DUBEY
(MBBS. DCP) (DIRECTOR)

DR. VIJAY BHURIYA
MBBS DMRD

DR. YOGESH PAWDE
M. D. (CONS. PATHOLOGIST)

DR. P.S. TRIPATHI
M.D.(RADIO DIAGNOSIS)

DR. SANJAY YADAV
CON. MICROBIOLOGIST

Report Checked By :

Address : Agrawal Plaza, B-7, HIG Main Road, Indore Ph. : 0731-4289992-3
Website : www.trivenidiagnostic.com email : trivenidiagnostic@yahoo.co.in

Page 1 of 1



Triveni Diagnostic Centre

Reg No. : 90643 VISITID : 0000095229
PATIENT NAME : MRS. SHWETA KOTHARI SPEC. NO : 1905422007
AGE/SEX : 38 YEARS/FEMALE SAMP. DATE : 10/06/2024 13:08:00
REF. BY : Dr. ARCOFEMI HEALTHCARE LIMITED RESULT DATE : 11/06/2024 19:31:12

DEPARTMENT OF PATHOLOGY

NAME OF TEST **RESULT VALUE** **REFERENCE RANGE** **UNIT**

BLOOD GROUP

BLOOD GROUP

"B"

RH FACTOR

Positive

RESULT REMARKS :

GAMA GT

GGT (GAMMA GLUTAMYL TRANSFERASE) 22

5 - 36

U / L

RESULT REMARKS :

PERIPHERAL SMEAR EXAMINATION

PERIPHERAL SMEAR

RESULT REMARKS : Rbcs show They are normocytic normochromic.

Wbcs are normal in number and morphology.

Platelets are adequate on smear and normal in morphology.

No hemoparasite is seen.

DR. MUKESH DUBEY
(MBBS, DCP) (DIRECTOR)

DR. VIJAY BHURIYA
MBBS DMRD

DR. YOGESH PAWDE
M. D. (CONS. PATHOLOGIST)

DR. P.S. TRIPATHI
M.D.(RADIO DIAGNOSIS)

DR. SANJAY YADAV
CON. MICROBIOLOGIST

Report Checked By :

Page 1 of 1

Address : Agrawal Plaza, B-7, HIG Main Road, Indore Ph. : 0731-4289992-3
Website : www.trivenidiagnostic.com email : trivenidiagnostic@yahoo.co.in



Triveni Diagnostic Centre

Reg No. : 90643 VISITID : 0000095229
PATIENT NAME : MRS. SHWETA KOTHARI SPEC. NO : 1905422004
AGE/SEX : 38 YEARS/FEMALE SAMP. DATE : 10/06/2024 13:08:00
REF. BY : Dr. ARCOFEMI HEALTHCARE LIMITED RESULT DATE : 11/06/2024 19:31:31

DEPARTMENT OF PATHOLOGY

NAME OF TEST	RESULT VALUE	REFERENCE RANGE	UNIT
--------------	--------------	-----------------	------

FBS

FBS	105	70 - 110	mg / dl
-----	-----	----------	---------

RESULT REMARKS : Test done by -"Roche COBAS- ENTEGRA 400 PLUS "fully bichemistry analyser .

HBA1 C (GLYCOSYLATED HEAMOGLOBIN)

HBA1 C (GLYCOSYLATED HEAMOGLOBIN)	5.5	Normal: 4-6 Good cntrol:6.1-7.0 Fair control :7.0-8.2 Unsatisfactory control: 8.0-10.2 Poor control: Above 10.0	%
-----------------------------------	-----	--	---

MEAN PLASMA GLUCOSE (MPG)	111	Exelent Control:90-120 Good Control:121-150 Avrege Control:151-180 Action Suggested:181-210 Panic value :>211	mg/dL
---------------------------	-----	---	-------

RESULT REMARKS : Test done by -"Roche COBAS- ENTEGRA 400 PLUS "fully bichemistry analyser .

METHOD BY: Turbidimetric inhibition immunoassay(TINIA)

Average blood glucose value is calculated from HBA1C value and indicates average blood sugar level over past three months.

DR. MUKESH DUBEY
(MBBS. DCP) (DIRECTOR)

DR. VIJAY BHURIYA
MBBS DMRD

DR. YOGESH PAWDE
M. D. (CONS. PATHOLOGIST)

DR. P.S.TRIPATHI
M.D.(RADIO DIAGNOSIS)

DR. SANJAY YADAV
CON. MICROBIOLOGIST

Report Checked By :

Page 1 of 1



Triveni Diagnostic Centre

Reg No. : 90643 VISITID : O000095229
PATIENT NAME : MRS. SHWETA KOTHARI SPEC. NO : 1905422004
AGE/SEX : 38 YEARS/FEMALE SAMP. DATE : 10/06/2024 13:08:00
REF. BY : Dr. ARCOFEMI HEALTHCARE LIMITED RESULT DATE : 11/06/2024 19:32:07

IMMUNO ASSAY

T3, T4 TSH

NAME OF TEST	RESULT VALUE	REFERENCE RANGE	UNIT
T3 (TRIIODOTHYRONINE)	1.04	Adults:- 0.60-1.58 Children:- 0-3 days:- 0.96- 2.92 1-11 months 0.81-2.81 1-5 years 0.83-2.52 6-10 years 0.92-2.19 11-15years 0.83-2.15	ng/ml
T4 (THYROXINE)	10.5	Adults:- 5.01-11.0 Children:- 0-3 days 11.80-22.60 4-30 days not Established 1-2 weeks 9.80-16.60 1-4 months 7.20-14.40 4-12 months 7.80-16.50	ug/dl
TSH (THYROID STIMULATING HORMONE)	0.44	Adults:- 0.38-4.31 Children:- 0-3 days:- 1.0-39.0 4-30 days:- 0.43-16.1 2-12 months:- 0.62-8.05 2-6 years:- 0.54-4.53 7-11 years:- 0.66-4.14 12-19 years:- 0.53-3.59	uIU/ml

Method: By AIA-360 (TOSOH) fully automated electro chemiluminescence immunoassay

INTERPRETATION: Suppressed TSH values are seen in hyperthyroid patients with the exception of hyperthyroidism caused by a TSH producing pituitary tumors. In addition TSH is suppressed in individuals treated with the exogenous thyroid hormones.

Elevated TSH values are seen in primary hypothyroidism with the exception of hypothyroidisms caused by pituitary disorders.

Note: Total T3 and T4 values may also be altered in other conditions due to changes in serum proteins or binding sites pregnancy, drugs (Androgens, Estrogens, O C pills, Phenyntion) nephrosis etc. In such cases free T3 and T4 give corrected values.

DR. MUKESH DUBEY
(MBBS, DCP) (DIRECTOR)

DR. VIJAY BHURIYA
MBBS DMRD

DR. YOGESH PAWDE
M. D. (CONS. PATHOLOGIST)

DR. P.S. TRIPATHI
M.D. (RADIO DIAGNOSIS)

DR. SANJAY YADAV
CON. MICROBIOLOGIST

Report Checked By:

Address : Agrawal Plaza, B-7, HIG Main Road, Indore Ph. : 0731-4289992-3
Website : www.trivenidiagnostic.com email : trivenidiagnostic@yahoo.co.in

Page 1 of 1



Triveni Diagnostic Centre

Reg. No. : 90643 Visit ID : 0000095229
Patient Name : MRS. SHWETA KOTHARI
Age / Sex : 38 YEARS / FEMALE Order Date : 10/06/24 12:54PM
Ref. By : Dr. ARCOFEMI HEALTHCARE LIMITED Report Date : 10/06/24 01:33PM

SONOGRAPHY

USG WHOLE ABDOMEN(FEMALE)

Liver is normal in size 11.7cm with smooth contour and homogenous echotexture. Intra hepatic biliary radicals are not dilated. Portal & splenic veins are normal in caliber.

Gall bladder is normal in size with thin walls & lumen is free from calculi/polyp. CHD & CBD are not dilated.

Pancreas is normal shaped with homogenous echotexture.

Spleen is normal in size 8.3cm and echotexture.

Kidneys are normal in size (Rt 8.9 X 3.6 Lt.9.5 X 4.5 cms), contour, position and show normal cortical echogenicity & CMJ. No evidence of calculus or calcification on either sides. Pelvicalyceal systems & ureters are undilated.

No abdominal/ pelvic lymphadenopathy is seen.

Urinary bladder is adequately filled with anechoic contents.

Mucosa is smooth and wall thickness measures normal.

Uterus is normal in size & retroverted.

Approx 12.9 mm size well defined heterogeneously hypoechoic soft tissue lesion seen in the anterior wall of uterus S/O fibroid.

Endometrial echo is central. Cervix appears to be normal.

Uterus Size 7.7 x 4.0 x 4.9 cm.

Endometrium is 9.4mm.

Ovaries are normal.

IMPRESSION: -Anterior uterine wall fibroid.

Kindly corrlate.

DR. MUKESH DUBEY
(MBBS, DCP)

DR. VEJAY BHURIYA
MBBS DMRD

DR. AMIT SHANKHWAR
M.D. RADIO DIAGNOSIS

DR. P.S. TRIPATHI
M.D. (RADIO DIAGONOSIS)

DR. SANJAY YADAV
CONSULTANT MICROBIOLOGIST

Address : Agrowal Plaza, B-7, High Main Road, Indore Ph. : 0731-4289992-3
Website : www.trivenidiagnostic.com email : trivenidiagnostic@yahoo.co.in