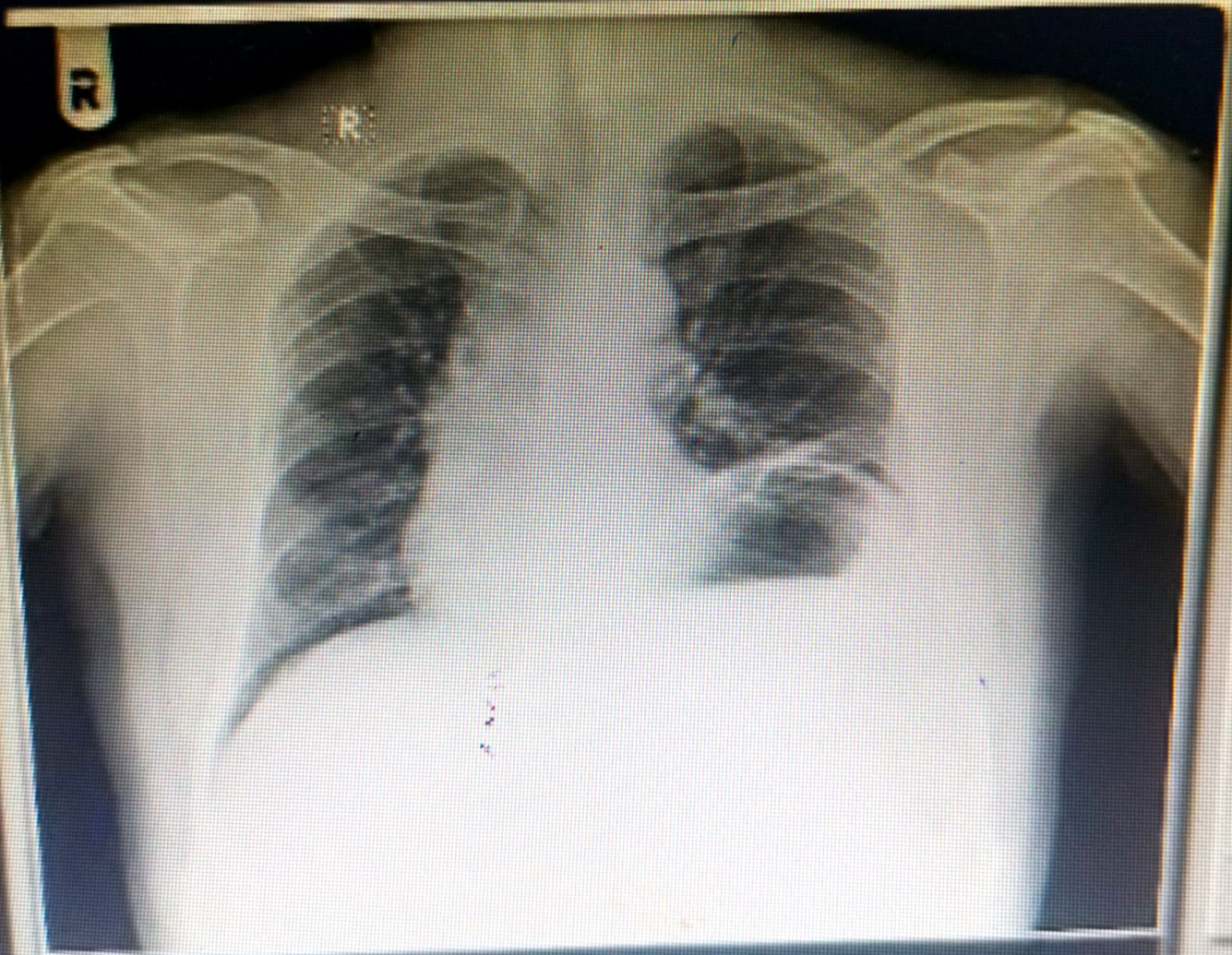


22062407

RAJUBHAI SARDARE 55YRS



MA










[Blank button]

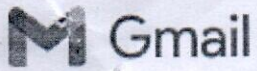
GA

GS

S

[Smiley face icon]





vidhi diagnostics <vidhidiagnostics@gmail.com>

Health Check up Booking Request(35E7092)

1 message

Mediwheel <wellness@mediwheel.in>
 To: vidhidiagnostics@gmail.com
 Cc: customercare@mediwheel.in

20 June 2024 at 13:41



Mediwheel
 ...Your wellness partner

011-41195959

Dear VIDHI DIAGNOSTICS

We have received a booking request with the following details. Provide your confirmation by clicking on the Yes button.

You confirm this booking? Yes No

Name : RAJUBHAI UTTAMRAO SARDARE
Contact Details : 9586470678
Hospital Package Name : Mediwheel Full Body Health Checkup Male Above 40
Location : L-86 Swatantra - Senani Nagar , Opp- Akhbarnagar Bus Terminals, New Wadaj , Ahmedabad -13
Appointment Date : 22-06-2024

Member Information

Booked Member Name	Age	Gender
RAJUBHAI UTTAMRAO SARDARE	56 year	Male

Tests included in this Package

- Urine Analysis
- Blood Group
- Stool Test
- CBC
- HbA1c
- Lipid Profile
- Kidney Profile
- Liver Profile
- Blood Glucose (Post Prandial)
- Prostate Specific Antigen (PSA Male)
- Thyroid Profile
- Urine Sugar Fasting
- Urine Sugar PP
- ESR
- Blood Glucose (Fasting)
- TMT OR 2D ECHO (Any 1) Chosen By Candidate
- Chest X-ray
- ECG
- USG Whole Abdomen
- Eye Check-up consultation
- Dental Consultation
- General Physician Consultation

Dr. Dinesh S. Modh

M.D., D.M.R.E. (Radiodiagnosis)
Consultant Radiologist & Sonologist
Ex. Junior Lecturer, B.J. Medical College, Civil Hospital, A'bad.

VIDHI
DIAGNOSTICS



DATE:	22/06/2024	
NAME:	Rajubhai Uttamrao Sardane	
AGE:	55 yr.	
MEDICAL EXAMINATION:-		
HEIGHT:	168 cm.	WEIGHT: 59 kg
BP:	124/78 mmHg	PULSE: 98 per min.
SPO2:	98	TEMPERATURE: normal
RS:	normal	CVS: normal
ASYMTOMATIC		
HISTORY:	H/O BP since 9 years, take medicine lipidip (1-0-0)	
EYE CHECK-UP:-	RIGHT	LEFT
DISTANCE:	6/6	6/6
NEAR:	N/6	N/6
COLOR VISION:	normal	normal
DENTAL CHECK-UP:	oral hygiene normal. H/O no cavity and caries seen.	
ADV: HE/SHE IS MEDICALLY FIT	He is medically fit	

Dr. Vidhi D. Modh

Reg. No. : 874540

Vidhi Diagnostics
L-86, Swatantra-Senani Nagar,
Nr. Akhbarnagar Bus Terminals
Nr. Akhbarnagar Circle,
New Wadaj, Ahmedabad-13.

ISO 9001:2015 Certified Diagnostics Center
Vidhi Imaging Center

L-86, Swatantra Senani Nagar, Opp. Indian Oil Petrol Pump, Akhbarnagar Circle, Nava Wadaj, Ahmedabad - 380 013.

Phone : (Radiology) 079-2762 1406 | M. 98799 29406, 98250 09406 | Time (Radiology) : Mon. to Sat. 9 am to 2 pm, 5 to 9 pm, Sunday 9 am to 12 Noon
E-mail : vidhidiagnostics@gmail.com, Website : www.vidhidiagnostics.com

Multislice CT Scan | CBCT-Dental Scan | Live 3D-4D Sonography | Colour Doppler | Echo Cardiography | Interventional Radiology | Maxillofacial Radiology | Fetal Medicine
Digital X-Ray | Digital Mammography | Digital OPG/TMJ | ECG/TMT/PFT/EEG/EMG | Audiometry | Pathology Laboratory | Health Check Up Plans | Pre Employment Check Up

CT SCAN & CBCT FACILITY NOW AVAILABLE

Dr. Dinesh S. Modh

M.D., D.M.R.E. (Radiodiagnosis), C.I.H

Consultant Radiologist & Sonologist

Ex. Junior Lecturer, B.J. Medical College, Civil Hospital, A'bad.

VIDHI
DIAGNOSTICS



Patient's name : RAJUBHAI U SARDARE
Reg. ID : R-3287-23
Referred by : Dr. MEDIWHEEL

Age/Sex : 55 Years/Male
Accession : 29998
Date : 22/06/2024

USG ABDOMEN

LIVER:- Liver appears normal in size & echo texture. No evidence of focal lesion is seen. IHBR appear normal. Portal vein and CBD appear normal. No e/o calculus is seen in bile duct.

GALL BLADDER:- Gall bladder is distended & appears normal. No evidence of calculus or cholecystitis is seen.

SPLEEN:- Spleen appears normal in size & shows normal echo texture. No evidence of diffuse or focal lesion is seen.

PANCREAS:- Pancreas appears normal size and echo pattern. No e/o diffuse or focal lesion is seen. Main pancreatic duct appears normal.

KIDNEY:- Both Kidneys appear normal in size & echo texture.

- No e/o calculus or hydronephrosis/ hydroureter is seen on both sides.

Cortico-medullary differentiation is maintained on both sides.

Both suprarenal regions appear normal.

No evidence of pre & para aortic lymphadenopathy is seen.

Both suprarenal regions appear normal.

No evidence of pre & para aortic lymphadenopathy is seen.

RIF & BOWEL LOOPS (By high frequency probe):- Normal.

No evidence of dilated or thickened bowel loops is seen.

No evidence of free fluid is seen in abdomen.

Urinary bladder:- appears normal. No e/o calculus or mass lesion is seen in bladder.

Prostate appears normal size and echopattern.

Thanks for reference.

Dr. Dinesh S. Modh

MD DMRE (Radiodiagnosis)

DR DINESH S. MODH

M.D. DMRE(RADIODIAGNOSIS)

ISO 9001:2015 Certified Diagnostics Center

Vidhi Diagnostics

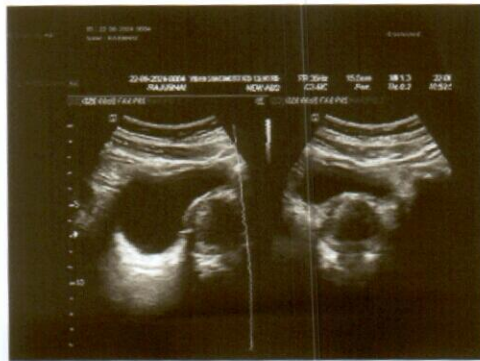
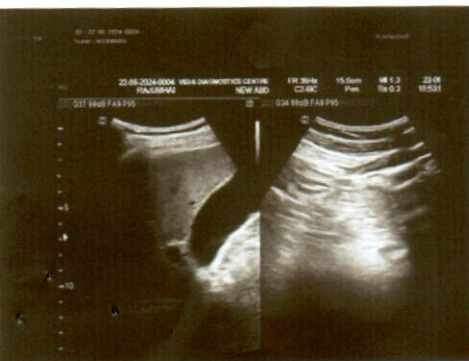
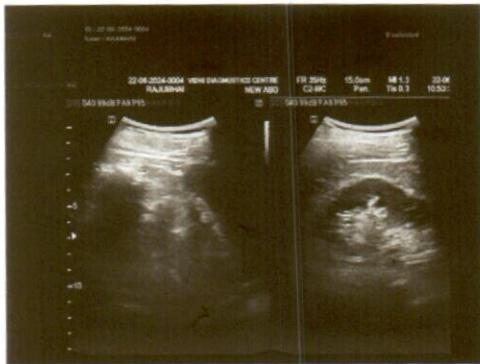
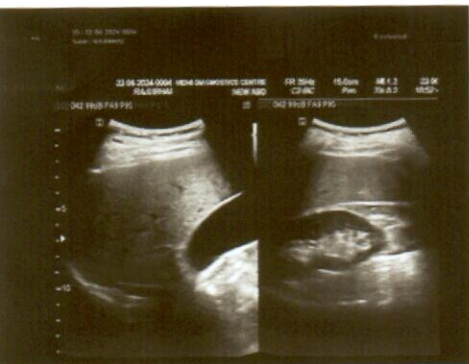L-86, Swatantra Senani Nagar, Opp. Indian Oil Petrol Pump, Near Akhbarnagar Circle, Nava Vadaj, Ahmedabad - 380 013.

Phone : (Radiology) 079-2762 1406 | M. 98799 29406, 98250 09406 | Time (Radiology) : Mon. to Sat. 9 am to 2 pm, 5 to 9pm, Sunday 9am to 12 Noon

E-mail : vidhidiagnostics@gmail.com, Website : www.vidhidiagnostics.com

Multislice CT Scan | CBCT-Dental Scan | Live 3D-4D Sonography | Colour Doppler | Echo Cardiography | Interventional Radiology | Maxillofacial Radiology | Fetal Medicine | Digital X-Ray | Digital Mammography | Digital OPG/TMJ | ECG / TMT / PFT / EEG / EMG | Audiometry | Pathology Laboratory | Health Check Up Plans | Pre Employment Check Up | Occupational Health Center

CT SCAN & CBCT FACILITY NOW AVAILABLE



Dr. Dinesh S. Modh

M.D., D.M.R.E. (Radiodiagnosis), C.I.H

Consultant Radiologist & Sonologist

Ex. Junior Lecturer, B.J. Medical College, Civil Hospital, A'bad.

VIDHI[®]
DIAGNOSTICS



Patient's name : RAJUBHAI U SARDARE
Reg. ID : R-3287-23
Referred by : Dr. MEDIWHEEL

Age/Sex : 55 Years/Male
Accession : 29998
Date : 22/06/2024

2D- ECHO REPORT

FINAL CONCLUSION:

LV IS NORMAL SIZE. GOOD LV SYSTOLIC FUNCTION NO RWMA.

LVEF - 60%. MILD CONCENTRIC LVH.

NORMAL LV COMPLIANCE.

LA IS NORMAL SIZE. NO LA CLOT.

RV IS NORMAL SIZE. GOOD RV SYSTOLIC FUNCTION.

RA IS NORMAL SIZE.

MITRAL VALVE IS NORMAL. NO MS. MILD MR (15%). NO MVP.

AORTIC VALVE IS NORMAL. NO AS. NO AR.

TRICUSPID VALVE IS NORMAL. MILD TR. RVSP-28mmHg. NO PAH.

NO CLOT, NO VEGETATION, NO PERICARDIAL EFFUSION.

DIMENSIONS:

AORTA	2.6 C.M
LEFT ATRIUM	2.7 C.M
LVDD	4.8 C.M.
IVSD	1.1 C.M
PWD	1.1 C.M
LVDS	2.6 C.M.

COLOUR DOPPLER FINDING:

STRUCTURE	VELOCITY m/sec
	Max
PULMONARY VALVE	0.7
MITRAL VALVE	E : 0.7 A: 0.4
AORTIC VALVE	1.0

Dr. Avinash Bhaskar

MBBS, D Cardio

Reg. No. : G-45946

DR AVINASH BHASKAR

CLINICAL CARDIOLOGIST

9924836431

ISO 9001:2015 Certified Diagnostics Center

Vidhi Diagnostics

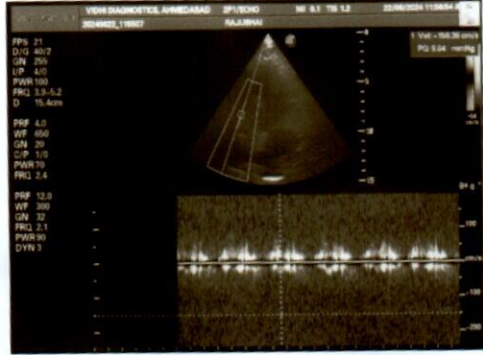
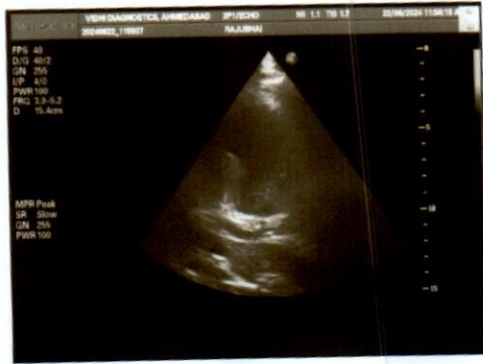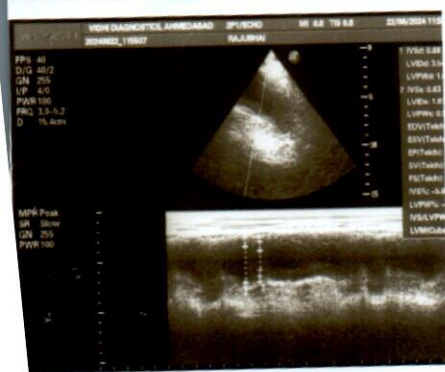
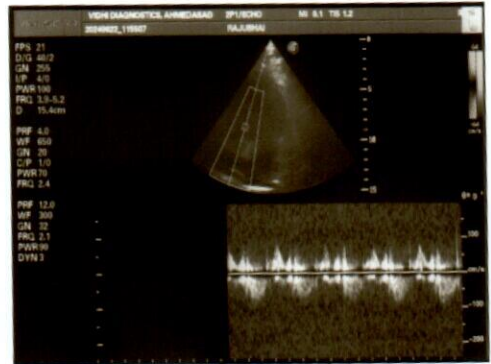
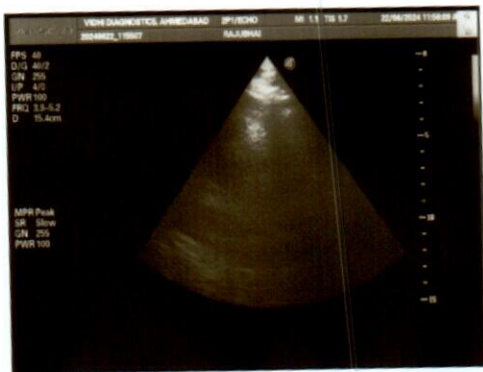
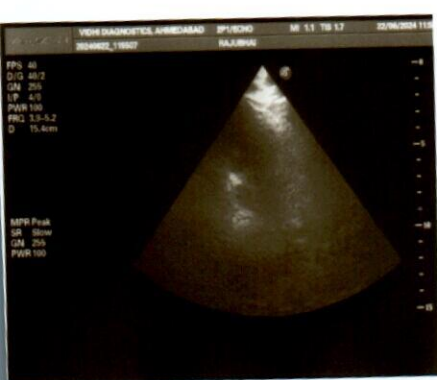
L-86, Swatantra Senani Nagar, Opp. Indian Oil Petrol Pump, Near Akhbarnagar Circle, **Nava Vadaj**, Ahmedabad - 380 013.

Phone : (Radiology) 079-2762 1406 | M. 98799 29406, 98250 09406 | **Time (Radiology)** : Mon. to Sat. 9 am to 2 pm, 5 to 9pm, Sunday 9am to 12 Noon

E-mail : vidhidiagnostics@gmail.com, **Website** : www.vidhidiagnostics.com

Multislice CT Scan | CBCT-Dental Scan | Live 3D-4D Sonography | Colour Doppler | Echo Cardiography | Interventional Radiology | Maxillofacial Radiology | Fetal Medicine | Digital X-Ray | Digital Mammography | Digital OPG/TMJ | ECG / TMT / PFT / EEG / EMG | Audiometry | Pathology Laboratory | Health Check Up Plans | Pre Employment Check Up | Occupational Health Center

CT SCAN & CBCT FACILITY NOW AVAILABLE



Dr. Dinesh S. Modh

M.D., D.M.R.E. (Radiodiagnosis), C.I.H

Consultant Radiologist & Sonologist

Ex. Junior Lecturer, B.J. Medical College, Civil Hospital, A'bad.

VIDHI[®]
DIAGNOSTICS



Patient's name : RAJUBHAI U SARDARE
Reg. ID : R-3287-23
Referred by : Dr. MEDIWHEEL

Age/Sex : 55 Years/Male
Accession : 29998
Date : 22/06/2024

X-RAY CHEST (PA VIEW)

Elevated left dome of diaphragm is seen.

Both lung fields appear normal.

No e/o consolidation or cavitations is seen.

Both costo-phrenic angles appear clear.

Cardiac size is with in normal limits.

Right dome of diaphragm appear normal.

Bony thoracic cage appears normal.

Thanks for reference.

Dr. Dinesh S. Modh

MD DMRE (Radiodiagnosis)
G-29825

DR DINESH S. MODH

M.D. DMRE(RADIODIAGNOSIS)

ISO 9001:2015 Certified Diagnostics Center

Vidhi Diagnostics

L-86, Swatantra Senani Nagar, Opp. Indian Oil Petrol Pump, Near Akhbarnagar Circle, **Nava Vadaj**, Ahmedabad - 380 013.

Phone : (Radiology) 079-2762 1406 | M. 98799 29406, 98250 09406 | **Time (Radiology)** : Mon. to Sat. 9 am to 2 pm, 5 to 9pm, Sunday 9am to 12 Noon

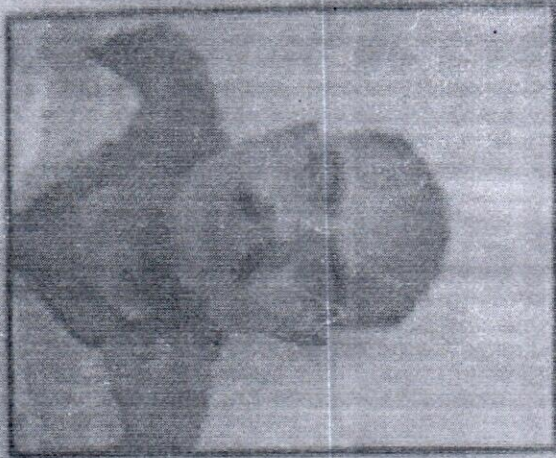E-mail : vidhidiagnostics@gmail.com, **Website** : www.vidhidiagnostics.com

Multislice CT Scan | CBCT-Dental Scan | Live 3D-4D Sonography | Colour Doppler | Echo Cardiography | Interventional Radiology | Maxillofacial Radiology | Fetal Medicine | Digital X-Ray | Digital Mammography | Digital OPG/TMJ | ECG / TMT / PFT / EEG / EMG | Audiometry | Pathology Laboratory | Health Check Up Plans | Pre Employment Check Up | Occupational Health Center

CT SCAN & CBCT FACILITY NOW AVAILABLE



भारत सरकार



राजुभाय उत्तमराव सारदे

Rajubhai Uttamrao Sardare

जन्म तारीख / DOB: 13/05/1968


पुंर / MALE

8052 6905 1272

भारत सरकार, भारत सरकार

R. V. Sardare

Rajushai



Vidhi Diagnostics
L-86, Swatantra-Senani Nagar,
Nr. Akhbarnagar Bus Terminals
Nr. Akhbarnagar Circle,
New Wadaj, Ahmedabad-13.

ID: 14330

Name: rajubhai sardare

Age: 56yrs

Sex: Male

Hospital:

Dr. Avinash Bhaskar

Department: ~~Cardio~~

Reg. No: ~~CA5946~~

HR : 79 bpm

PR : 148 ms

QRS : 94 ms

QT/QTc : 364/416 ms

P/QRS/T : 49/5/143 deg.

RV5/SV1 : 1.182/1.475 mv

RV5+SV1 : 2.657 mv

<< Analysis Result >>

** borderline ECG **

Sinus rhythm

Non-specific T wave abnormality

Vidhi Diagnostics

1-86, Svatantra-Senani Nagar,

Nr. Akharnagar Bus Terminals

Nr. Akharnagar Circle,

Nowpada, Ahmedabad-13.

Need to be confirmed by doctor. Doctor Name:

