



TAURUS HOSPITAL

(A Unit of Taurus Medicare Pvt. Ltd.)

208. Safipur 1st Ramadevi G. T. Road, Kanpur-208 007



Phone
0512 -2400779
0512 -2400774
0512 -2400737
8601955058

Pathology Report

Lab. No. : 1330	Date : 2024-11-02 12:11:54
Patient Name : Mrs. PREETI SINGH	Guardian Name :
Age/Sex : 33 Years/Female	Address : KANPUR,
Reffered By : SELF	
0	

Test Name	Observed Values	Unit	Normal Values
-----------	-----------------	------	---------------

Blood Chemistry

KFT			
CRET	0.71	mg/dl	0.60 - 1.20 mg/dl
UREA	40.02	mg/dl	15.00 - 45.00 mg/dl
BUN	18.18	mg/dl	5.00 - 25.00 mg/dl
UAC	5.72	mg/dl	2.50 - 7.50 mg/dl

Haematology

HbA1C	5.6	g/dl	< 5.6 % Normal 5.7-6.4% Pre-Diabetes >6.5 % Diabetes 6.5-7.0% Good control 7.0-8.0% Poor control >8.0% Bad control
-------	-----	------	---

CBC (Complete Blood Counts)

HB	8.20	mg/dl	10.10 - 15.50 mg/dl
TLC	7400	/CU MM	4000-11000
DLC		%	
NEUTROPHILL	66	%	40.0-80.0
LYMPHOCYTE	30	%	20.0-40.0
MONOCYTE	02	%	2.0-10.0
EOSINOPHILL	02	%	1.0-6.0
BASOPHILL		%	2.00 - 2.00 %
RBC	3.70	U/L	4.7-7.1
PCV	28.2	%	36.0-46.0
MCV	76.2	FL	83.0-101.0
MCH	22.2	%	11-20
MCHC	29.1	g/dl	31.5-34.5
PLatelet count	3.02	lakh/cum	1.50-4.0
RDW-CV	17.0	%	11.6-14.0

Dr. Vishakha Pal
MBBS,DCP(PATH)



TAURUS HOSPITAL

(A Unit of Taurus Medicare Pvt. Ltd.)

208. Safipur 1st Ramadevi G. T. Road, Kanpur-208 007



Phone
0512 -2400779
0512 -2400774
0512 -2400737
8601955058

Pathology Report

Lab. No. : 1330	Date : 2024-11-02 12:11:54 I
Patient Name : Mrs. PREETI SINGH	Guardian Name :
Age/Sex : 33 Years/Female	Address : KANPUR,
Referred By : SELF	
0	

Test Name	Observed Values	Unit	Normal Values
Biochemistry			
Lipid Profile (With Direct - HDL & L)			
Cholestrol	161.22	mg/dl	0.00 - 200.00 mg/dl
triglycerides	46.59	mg/dl	0.00 - 150.00 mg/dl
HDL	69.31	mg/dl	35.00 - 80.00 mg/dl
LDL	88.72	mg/dl	0.00 - 130.00 mg/dl
VLDL	28.29	mg/dl	2.00-30.00
Cholesterol/HDL Ratio	2.32	.	<4.00
LDL/HDL cholesterol Ratio	1.28	.	<3.50
HDL/LDL Cholestrol Ratio	0.78	.	<3.50

Blood Chemistry

L.F.T.

BILI TOTAL	0.79	mg/dl	0-2.0 mg/dl
BILI DIRECT	0.19	mg/dl	0-0.20 mg/dl
BILI (IND)	0.60	mg/dl	0.20-0.60mg/dl
SGPT(ALT)	30.49	IU/L	up- 34 U/L
SGOT	27.69	IU/L	up-31 IU/L
ALP(ALKALINE PHOSPHATASE)	65.49	IU/L	54-369 IU/L
TOTAL PROTEIN	6.71	g/dl	6.4-8.3 g/dl
ALBUMIN(ALB)	3.67	g/dl	3.5-4.6 g/dl

Dr. Vishakha Pal
MBBS,DCP(PATH)

Affiliated with CGHS/CAPF/TPA



TAURUS HOSPITAL

(A Unit of Taurus Medicare Pvt. Ltd.)

208. Safipur 1st Ramadevi G. T. Road, Kanpur-208 007



Phone
0512 -2400779
0512 -2400774
0512 -2400737
8601955058

Pathology Report

Lab. No. : 1330	Date : 2024-11-02 12:11:54 I
Patient Name : Mrs. PREETI SINGH	Guardian Name :
Age/Sex : 33 Years/Female	Address : KANPUR,
Referred By : SELF	
0	

Test Name	Observed Values	Unit	Normal Values
Biochemistry			
BLOOD SF	76.02	mg/dl	70-100
Haematology			
ESR-Wintrobe (Erythrocyte Sediment)	28	mm/hr.	
Hormones & Related Test			
T3, T4 (Total) & TSH 3rd Generation			
T3	2.19	.	1.30-3.10nmol/L
T4	135.72	.	66.00-181.00nmol/L
TSH	4.31	.	0.45-4.50MIU/L

Dr. Vishakha Pal
MBBS,DCP(PATH)

Affiliated with CGHS/CAPF/TPA



TAURUS HOSPITAL

(A Unit of Taurus Medicare Pvt. Ltd.)

208. Safipur 1st Ramadevi G. T. Road, Kanpur-208 007



Phone

0512 -2400779

0512 -2400774

0512 -2400737

8601955058

Pathology Report

Lab. No. : 1330	Date : 2024-11-02 12:11:54 I
Patient Name : Mrs. PREETI SINGH	Guardian Name :
Age/Sex : 33 Years/Female	Address : KANPUR,
Referred By : SELF	
0	

Test Name	Observed Values	Unit	Normal Values
-----------	-----------------	------	---------------

Clinical

URINE R/M

Colour	STRAW	.	
Appearance	CLEAR	.	
Specific Gravity	1.010	.	1.005-1.030
Ph	6.0	.	4.5-8.0
Protien	Nil	.	Nil
Glucose	Nil	.	Nil
Pus Cells	2-3	/hpf	0-5
Epithelial Cells	1-2	/hpf	0-5
RBC	Nil	/hpf	Nil
Casts	Not Seen	.	Not Seen
Crystals	Not Seen	.	Not Seen

Dr. Vishakha Pal
MBBS,DCP(PATH)

ECG report

ID : 20241102102713
Name : mrs preeti singh
Gender: F
Age : 33 Years
Dept :
Bed No:

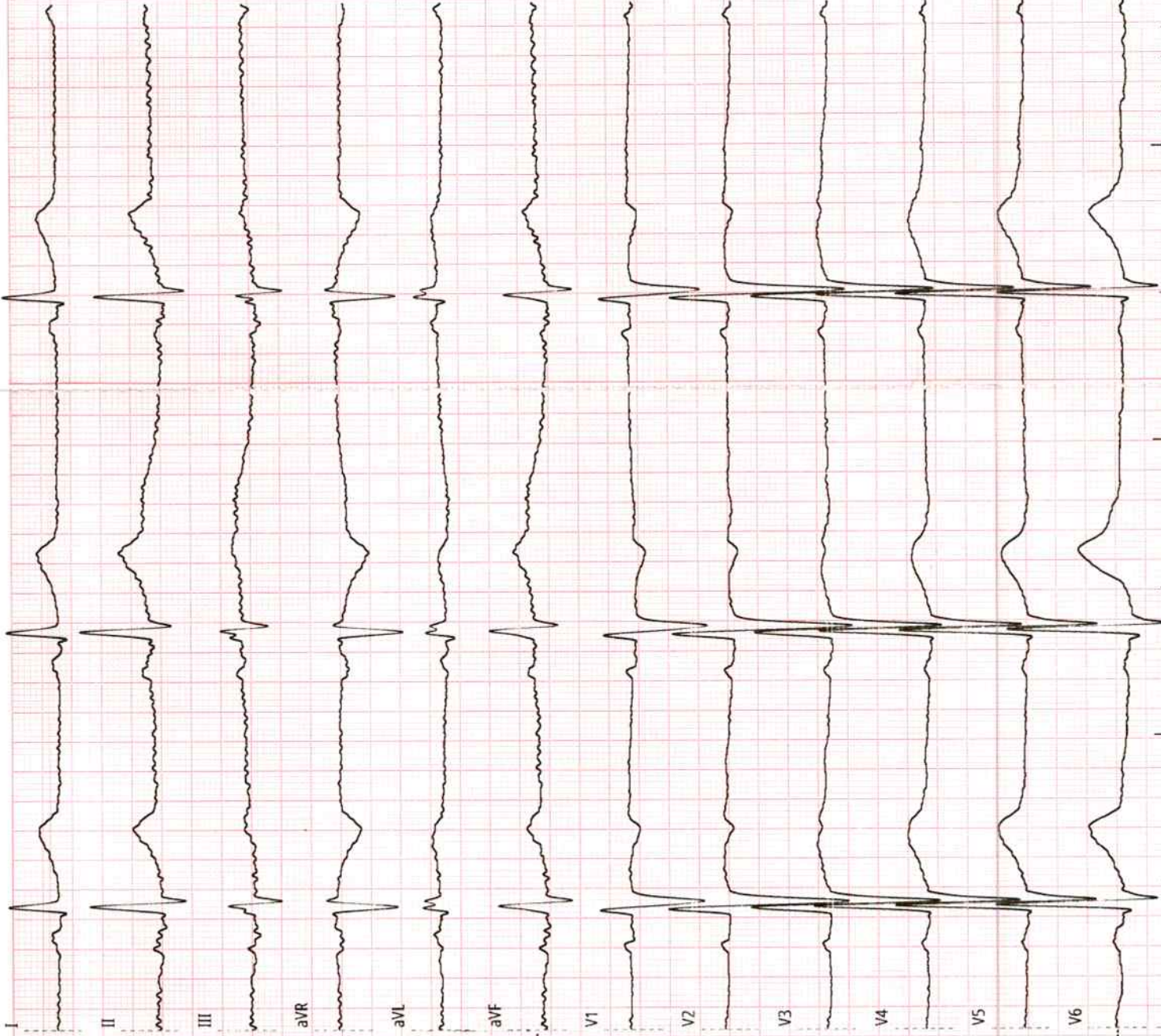
HR : 57 bpm
PR : 128 ms
QRS : 84 ms
QT/QTc : 394/389 ms
P/QRS/T : 21/24/50°
RV5/SV1 : 1.075/0.569 mv
RV5+SV1 : 1.644 mv

<<Interpretations >>

Sinus bradycardia with sinus arrhythmia
— Interpretation made without knowing
patient's gender/age —
Normal ECG except for rate



Confirm and sign: _____
Examination time: 2024-11-02 10:27:13



0.3Hz - 35Hz - AC 50Hz 50mm/s 20mm/mv 1.0.25 Simultaneous



RAJNI HOSPITAL

A Unit of Shrimati Rajani Dwivedi Charitable Society
1518/5, Daheli Sujapur, By Pass Road, Kanpur-208013
(Near Koyla Nagar Police Chowki)
GST NO:- 09AARTS9188A1ZR



Helpline No.:
+91 -8004991414
+91 -8004991515
+91 -8004991616
+91 -8933048215

Web : www.rajnihospitalin
Email : rajnihospitalknp@gmail.com

Patient Name : Mrs. PREETI SINGH
Referred by : Dr. SELF
Investigation : USG Whole Abdomen

Age : 33years/F
Date : 02/11/2024

Liver:

- Liver is normal in size (129mm) and echogenicity. No focal or diffuse lesion seen. Hepatic veins appear normal. No dilation of intrahepatic biliary ducts is seen.

Gall bladder:

- Gall bladder is normal in size and show echo free lumen. Wall thickness is within normal limit. No calculus is seen in GB.

Portal vein:

- Normal in size (mm) and shows normal appearance.

C.B.D.:

- Normal in size (mm) and shows normal caliber.

Pancreas:

- Pancreas is normal in size. No calcification or mass lesion seen.

Spleen:

- Spleen is normal in size. Splenic vein appears normal. No mass lesion or calcification seen.

Right kidney:

- Normal in size (92x40mm) seen in respective renal areas.
- Cortico - medullary differentiation appears to be normal.
- No calculus or mass lesion seen. No hydronephrosis is seen.



RAJNI HOSPITAL



A Unit of Shrimati Rajani Dwivedi Charitable Society
1518/5, Daheli Sujapur, By Pass Road, Kanpur-208013
(Near Koyla Nagar Police Chowki)
GST NO:- 09AARTS9188A1ZR



Helpline No.:
+91 -8004991414
+91 -8004991515
+91 -8004991616
+91 -8933048215
Web : www.rajnihospitalin.com
Email : rajnihospitalknp@gmail.com

Left kidney:

- Normal in size (102x33mm) seen in respective renal areas.
- Cortico - medullary differentiation appears to be normal.
- No calculus or mass lesion seen. No hydronephrosis is seen.

Ureter:

- Both ureters are normal.

Urinary bladder:

- Normal in size & shape, Wall thickness is normal limit.
- No calculus or mass lesion seen.

Uterus:

- Anteverted with normal in size (81x49x33mm) and morphology. Endometrial cavity is within normal limit. Cervix shows normal sonography. No focal mass lesion noted.

Ovaries/ Adnexa:

- Both ovaries are normal.
- Right ovary measure (mm), Left ovary measure (mm).

Peritoneum/Retroperitoneum:

- Dilated bowel loops with gas shadow seen in whole abdomen.
- No free fluid seen with cul-de-sac. No lymphadenopathy is seen.

Impression:

➤ **DILATED BOWEL LOOPS WITH GAS**

ADV: Please correlate clinically.

SONOLOGIST



Affiliated with CGHS / CAPF
TOURUS HOSPITAL

(A Unit of Taurus Medicare Pvt. Ltd.)

208, Safipur 1st Ramadevi, G. T. Road, Kanpur-208 007

Ph.: 0512-2400779, 2400774, 2400737, 8601955058 • E-mail: tourushospital@gmail.com



MRS. PREETI SINGH

331F

2DEMO

Normal size LAIV, RAIRV

NO RWMA

NO MR/TR IAR

NO MR IAS

NO PE / Apical clot

IUC - 14mm

collapsing 50%

LVEF - 60%





Affiliated with CGHS / CAPF
TOURUS HOSPITAL

(A Unit of Taurus Medicare Pvt. Ltd.)

208, Safipur 1st Ramadevi, G. T. Road, Kanpur-208 007

Ph.: 0512-2400779, 2400774, 2400737, 8601955058 • E-mail: tourushospital@gmail.com



Patient Name	PREETI SINGH	Patient ID	021124-2
Age/D.O.B	33 YRS	Gender	F
Ref Doctor	SELF	Date	2 Nov 24

XRAY RADIOGRAPH CHEST - PA

Observations

- Domes of Diaphragm:- Are smooth.
Pulmonary vasculature:- Appears normal.
Bones and soft tissue shadows:- Appear normal.
Cardia:- Is normal in size.
Visualised lung fields:- Appear normal.
Hilar Shadows:- Are within normal limits.
Both Costophrenic Recesses:- Are clear.

Impression

Essentially normal study.

Reported By,

Mr. Farid Khan

Dr. Farid Khan

MBBS, MD

Consultant Radiologist

MPMC - 23324