

DAKSH HOSPITAL

396 - 397, Gandhi Nagar, Scheme No. 8, ALWAR -301001

Ref. No.

Date.....

MEDICAL EXAMINATION REPORT

Mediwheel (BOB)

Name: Mr Brijendra Kumar Gupta Age: 36 yrs Sex: Male Date: 14/04/2023

General Physical Examination

Height	: 172 cm.	Weight	: 107 kg
Pulse	: 83/mt	BP	: 120/85 mm/hg
Temp.	: 97.6 °F	Respiration	: 93 %
BMI	: 36.2		

Systemic Exam:-

clear

Dental Check up :-

NORMAL

Eye check-up :-

NORMAL

Skin Check up:-

NORMAL

ENT Check up:-

NORMAL

Gynae Check up:-

N/A

Impression:-

Fatty liver

Recommendation:-

life style Modification

डॉ० मकेश गुप्ता
Dr. Mukesh Kumar Gupta
फिजिशियन MD Genie Medicine
Reg. No. 54287/6262
रजि. नं. 54287/6262

Results

Run Date 14/04/2023 10:19:25 AM

Operator DAKSH

Last Name

Sample ID 3

First Name MR BRIJENDRA KUMAR

Department

Gender Male Age

Physician DR. MUKESH GUPTA M.D

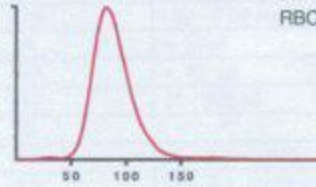
Patient ID AUTO_PID13049

Type Man

Date of birth

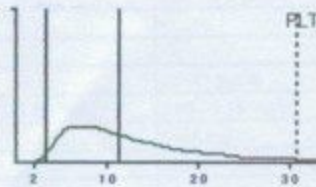
Sample comments

				Range
RBC	5.19	*	10 ⁶ /μL	3.80 - 5.50
HGB	14.8		g/dL	13.0 - 17.0
HCT	48.5	*	%	39.0 - 52.0
MCV	93.4	*	μm ³	76.0 - 100.0
MCH	28.4		pg	26.0 - 34.0
MCHC	30.4	L	g/dL	32.0 - 35.0
RDW-CV	18.8	H	%	11.0 - 16.0
RDW-SD	64.6	H	μm ³	37.0 - 49.0

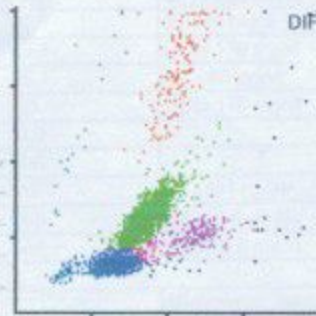


Susp. Pathologies
Anisocytosis

				Range
PLT	188		10 ³ /μL	150 - 450
PCT	0.22		%	0.15 - 0.40
MPV	11.8	h	μm ³	8.0 - 11.0
PDW	24.7	h	μm ³	11.0 - 22.0
P-LCC	86		10 ³ /μL	44 - 140
P-LCR	45.7		%	18.0 - 50.0



				Range		
WBC	5.36		10 ³ /μL	3.50 - 10.00		
	#					
NEU	2.32		1.60 - 7.00	43.5	40.0 - 75.0	
LYM	2.63		1.00 - 3.00	49.4	h	20.0 - 45.0
MON	0.08	l	0.20 - 0.80	1.4	l	2.0 - 10.0
EOS	0.21		0.00 - 0.50	4.0		1.0 - 6.0
BAS	0.09		0.00 - 0.15	1.7	h	0.0 - 1.0
LIC	0.03		0.00 - 0.10	0.6		0.0 - 1.0



डॉ० मुकेश गुप्ता
M.D. F.C.C.S.

किडनीरियन एवं मधुमेह रोग विशेषज्ञ

दक्ष हॉस्पिटल, अलवर
रजि. नं. 542111/62

14/04/2023 10:20:39 AM

Doctor

Printed by : DAKSH

S/N107YOXH04

TECHNOLOGIST

All investigation have their own limitations regarding the sensitivity & specificity of individual assay procedures, isolated laboratory investigations never confirm the final diagnosis of the disease. They only help in arriving at a diagnosis in conjunction with clinical presentation and other related investigations. Report is not valid for medico-legal purpose subject to ALWAR jurisdiction only.

Date :-14/04/2023

Name :- MR. BRIJENDRA KUMAR

Age & Sex :- - 36Yrs/ male

Refd. :- Dr Mukesh Gupta M.D.

	TEST NAME	RESULT	REFERENCE RANGE
	ESR	17	00 -20 mm/hrs
	Blood Group & Rh Factor	O * POSITIVE	
	HbA1C	4.6	4 - 5.6%
	Blood Sugar (F)	80.1	< 70 - 100 mg/dl
	Blood Sugar (PP)	101.2	< 140 mg/dl
	Urine Sugar (F)	NIL	-
	Urine Sugar (PP)	NIL	-
LIVER	S.Bilirubin Total	0.80	0.30 - 1.20 mg/dl
	S.Bilirubin Direct	0.20	0.10 - 0.30 mg/dl
	S.Bilirubin Indirect	0.60	0.30 - 0.90 mg/dl
	S.G.O.T.	94	> 37u/l
	S.G.P.T.	107	> 40 u/l
	S.Aik. Phosp.	197	80 - 306 u/l
	G.G.T.	22	5 -40 u/l
	Total Protein	6.5	6.5 - 8.5 gm/dl
	Albumin	3.5	3.8 - 5.4 gm/dl
	Globulin	3.0	2.3 - 3.5 gm/dl
	A/G Ratio	1.1	-
AST/ALT Ratio	0.8	-	
KIDNEY	Blood Urea	35.2	15 -45 mg/dl
	S.Creatinine	1.3	0.60 - 1.30 mg/dl
	BUN	15.0	6 -24 mg/dl
	S.Uric Acid	5.1	M 3.1 - 7.0, F 2.5 - 5.6 mg/dl
	BUN/Creatinine Ratio	11.5	-
LIPID PROFILE	Total Cholesterol	155.1	Up to 200 mg/dl
	S.HDL	42.1	30 - 70 mg/dl
	S.LDL	88.1	Up to 170 mg/dl
	S.VLDL	25.1	5.0 - 40 mg/dl
	S. Triglycerides	125.1	Up to 170 mg/dl
	LDL/HDL Ratio	2.0	-
	Total Cholesterol/ HDL Ratio	3.6	-
THYROID	T3	116.7	40 - 181 ng/dL
	T4	8.5	4.6- 10.5 µg /dL
	TSH	2.4	0.30 - 5.0 mIU/L

URINE EXAMINATION

Microscopic Examination :

General/Chemical Examination:	Colour	Pale Yellow	RBC	Absent
	Reaction	Acidic	WBC	0 - 1
	Specific Gravity	QNS	Epithelial Cells	0- 1
	Appearance	Clear	Cast	Absent
	Albumin	Nil	Crystal	Absent
	Sugar	Nil	Spermatozoa	Absent
			Amorphous Sediments	Absent
			Other	Absent

X-RAY CHEST

NORMAL STUDY

STOOL EXAMINATION

Microscopic Examination :

General/ Chemical Examination:	Colour	-	RBC	-
	Consistency	-	WBC	-
	PH	-	Ova & Parasites	-
	Reducing Substances	-		

Doctor

डॉ० मुकेश गुप्ता
M.D. F.C.C.S.
फिजिशियन एवं मधुमेह रोग विशेषज्ञ

TECHNOLOGIST

All investigation have their own limitations regarding the sensitivity & specificity of individual assay procedures, isolated laboratory investigations never confirm the final diagnosis of the disease. They only help in arriving at a diagnosis in conjunction with clinical presentation and other related investigations. Report is not valid for medico-legal purpose subject to ALWAR jurisdiction only.



दक्ष हॉस्पिटल

396, गाँधी नगर स्कीम नं.8, अलवर (राज०) ☎ 0144-2703340

Sonography / 2D Echo Cardiography / Doppler Report

2D/ ECHO REPORT

Name: - Mr Bijendra

Age: - 36 Yrs

Date: - 14-Apr-23

Reg. No.:- Alw/2009/04

BOB health checkup

PROCEDURES:

M-MODE/2D/DOPPLER/COLOR/CONTRAST B.A.S. M²

MEASUREMENT:		DOPPLER:	
AOD	24	NORMAL (20- 37mm)	NORMAL (cm/sec.)
LA	24	(19- 40mm)	MV 0.6 (0.8- 1.3) MR No
AVO	18	(12- 25mm)	AV 1.2 (1.2- 1.8) AR No
RVDd.	17	(03- 09mm)	TV 0.6 (0.3- 0.8) TR No
LVDd	52	(37- 56mm)	PV 0.8 (0.7- 1.1) PR No
LVDs	33	(22- 40mm)	MITRAL VALVE-
IVS d	7.8	(06- 12mm)	AML Normal
IVS s	13.6		PML Normal
PWd	5.8	(05- 10mm)	AORTIC VALVE Normal
LV FUNCTION		TV & PV are normal.	
M- E- S Separation		<0.9cm	
Minor		24.42%	
LV Ejection Fraction	65%	65 +/- 12%	

LV WALL MOTION: NO RWMA
ALL CARDIAC CHAMBERS ARE NORMAL
ALL VALVES ARE NORMAL
NO CLOT, VEGETATION, PERICARDIAL EFFUSION

FINAL DIAGNOSIS: NORMAL STUDY

Adv: - Follow up/ review at higher center for confirmation

Note:- Please Correlate clinically. Due to technical limitations as well as inaccuracies inherent in the laboratory and statistical analysis of biological process. Diagnostic accuracy of ECHO is up to 95% only.
Report is not valid for medico-legal purpose.


Dr. Mukesh Kumar Gupta
Physician & Echocardiologist
RM 5423/16262



भ्रूण लिंग परीक्षण की शिकायत
104 टोल फ्री सेवा पर भी की
जा सकती है।
भ्रूण लिंग परीक्षण की शिकायत 104 टोल फ्री सेवा पर भी की जा सकती है।



दक्ष हॉस्पिटल

396, गाँधी नगर स्कीम नं.8, अलवर (राज०) ☎ 0144-2703340

Sonography / 2D Echo Cardiography / Doppler Report

Name: MR. BIJENDRA /M/36 YRS

Date: 14-Apr-23

BCB HEALTH CHECK UP

U.S.G. OF ABDOMEN & PELVIS

LIVER

Liver is **16.6 cm vertically** with normal echo-texture (**Grade II fatty liver**). Intra hepatic biliary radicals are not dilated.

No evidence of focal or diffuse lesion.

GALL BLADDER

Gall bladder is normal dilated. Lumen clear. Wall thickness normal. CBD normal

PANCREAS

Pancreas is normal in size, shape & echo-texture.

SPLEEN

Normal in size with normal shape & echo- texture.

BOTH KIDNEY

Both kidneys are normal in size shape and echo- texture.

PROSTATE is normal shape, size & echo texture.


URINARY BLADDER is normal shape, size & echo texture..

Grade II fatty liver

Advice- X Ray KUB / URINE EXAM

Please correlate clinically. USG accuracy is 95 % due to technical limitations as well as inaccuracies inherent in the laboratory and statistical analysis biological process.

This report is not valid for medico-legal cases.


Dr. Mukesh Kumar Gupta
Physician & Sonologist
RM 5423/16262



"भ्रूण लिंग परीक्षण की शिकायत
104 टोल फ्री सेवा पर भी की
जा सकती है"

भ्रूण लिंग परीक्षण की शिकायत 104 टोल फ्री सेवा पर भी की जा सकती है।

ID: 606

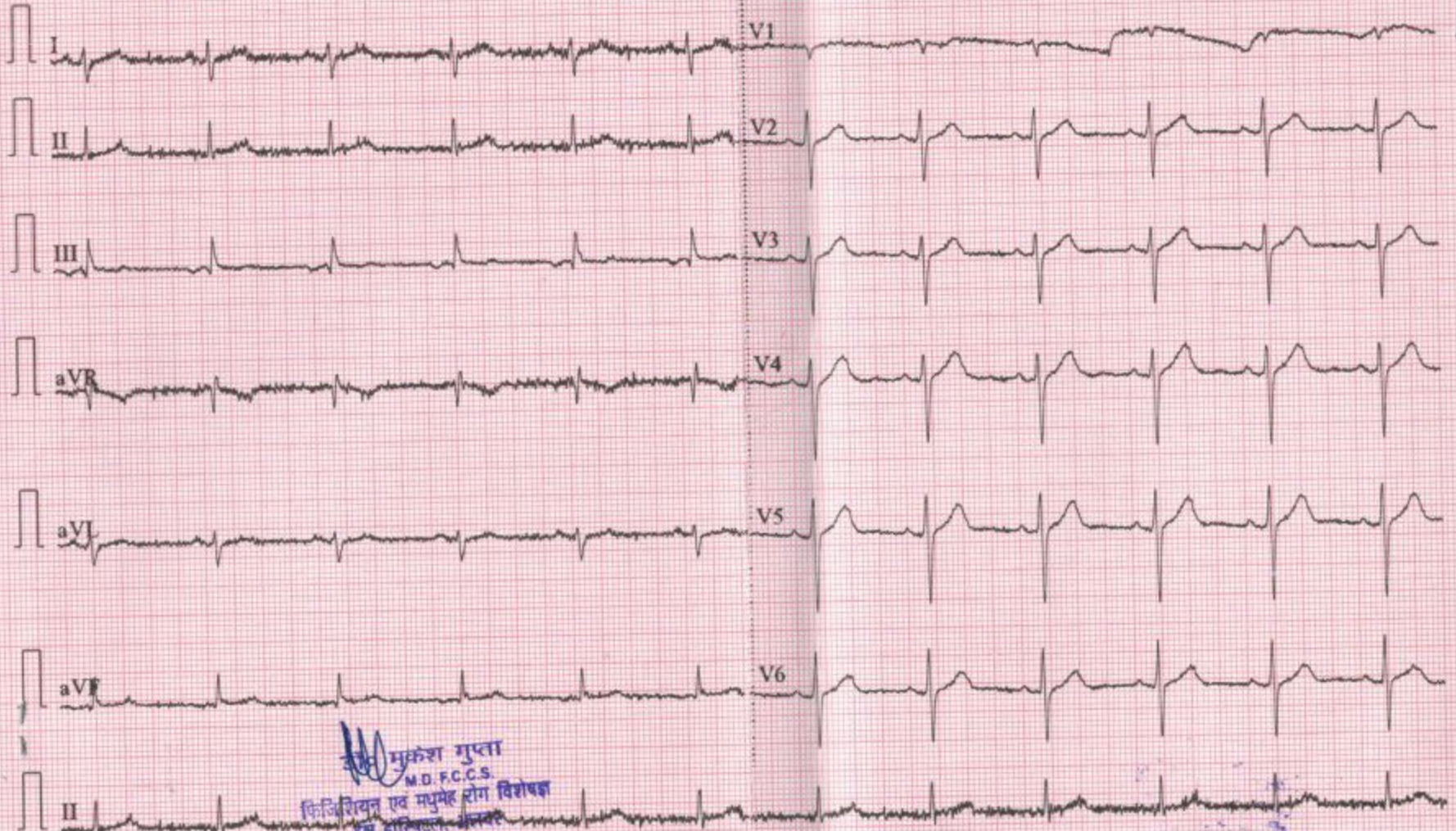
14-04-2023 13:32:53

Female Years
Req. No. :

HR : 70 bpm
 P : 90 ms
 PR : 146 ms
 QRS : 94 ms
 QT/QTcBz : 368/397 ms
 P/QRS/T : -27/95/33 °
 RV5/SV1 : 0.709/0.153 mV

Diagnosis Information:
 Possible ectopic atrial rhythm
 Rightward axis
 Borderline ECG

Report Confirmed by:



मकेश गुप्ता
 M.D. F.C.C.S.
 फिजिशियन एवं मधुमेह रोग विशेषज्ञ
 दक्ष हॉस्पिटल, अलवर
 रजि. नं. 5423/16262

T00421304 MR BIJENDAR REFD BY DR MUKESH GUPTA MD CHEST 14.04.2023

R

