

भारत सरकार
Government of India

भारत वर्मा
Bhawna Verma

माता : मातली वर्मा
 Mother : Malli Verma
 जन्म तिथि / DOB : 03/05/1991
 महिला / Female

4530 3631 8516

आधार - आम आदमी का अधिकार

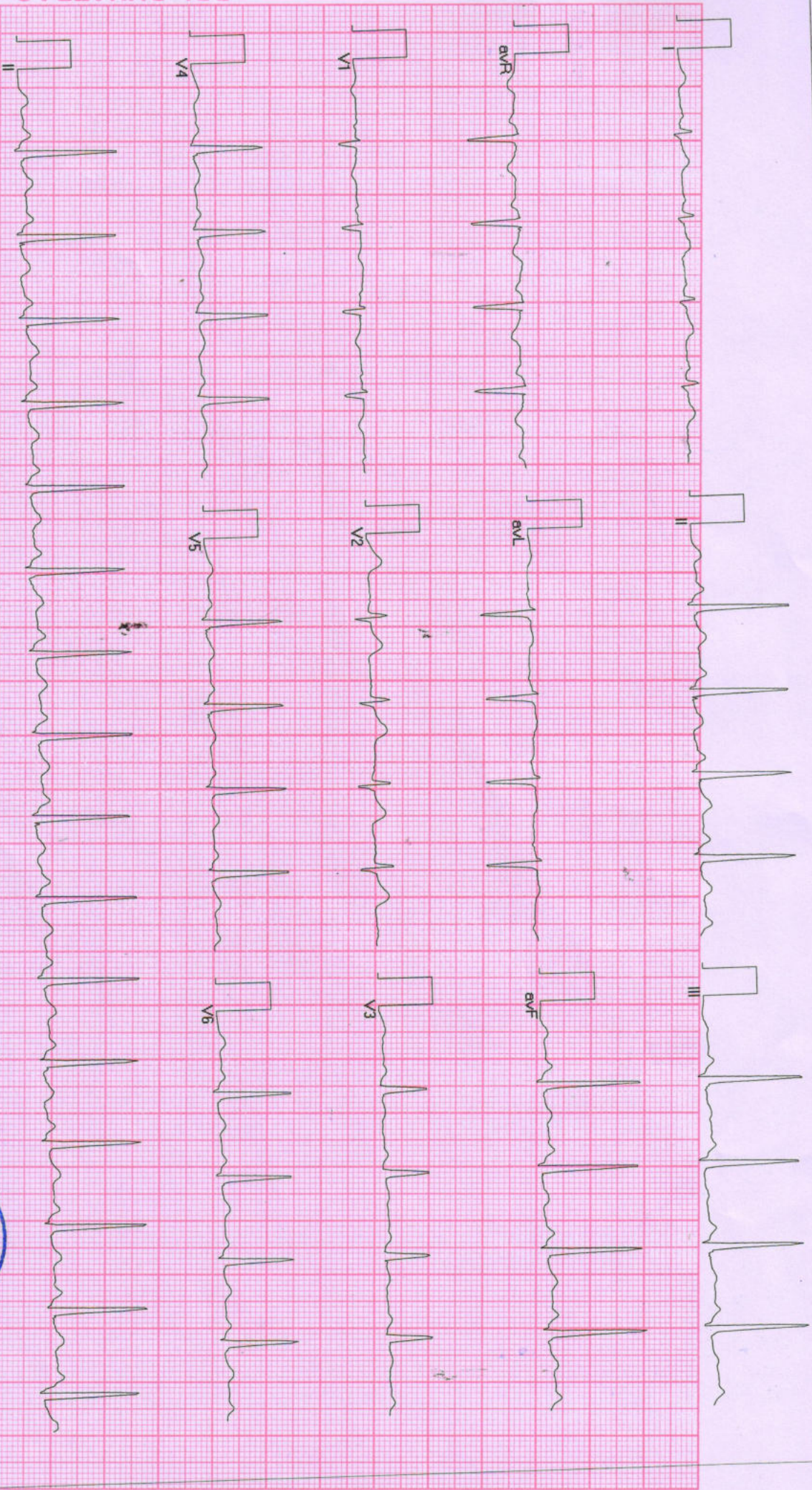
Handwritten signature



Dr. B. M. Agarwal
MBBS, DCP
Consultant Pathologist

Allengers Global Healthcare Pvt Ltd.
122 / MRS. BHAWNA VERMA / 31 Yrs / F / 153Cms. / 53Kgs.
Heart Rate : 98 bpm / Tested On : 08-Jun-22 15:33:11 / HF 0.05 Hz - LF 100 Hz / Notch 50 Hz / Sn 1.00 Cm/mV / Sw 25 mm/s
/ Refd By : BOB

ECG



BPL-DYNATRAC

Handwritten signature



Allengers ECG (Pisces)(PIS213180317)



दिवकर डायग्नोस्टिक सेंटर

E-7/636, पंजाब नेशनल बैंक के पास, मैन रोड, अरेरा कॉलोनी भोपाल (म.प्र.)


फोन: 0755-2465288, 0755-3520545 मो: 9826340190

Pt.Name :-	Mrs. Bhawna Verma
Age :-	31y/F
Refd. By :-	Mediwheel
Lab.pNo.:-	03
Date :-	03/06/2022

EXAMINATION OF BLOOD

TEST	RESULT	NORMAL VALUE
Haemoglobin	11.8mgs%	Female 12-16gms%, Male 14-18gms%
Red Cell count	4.7	4.5-5.6 million /cumm
Platelite Count	2.06	1.5-5.6 Lac/cumm
Leucocytes per.cu.mm	6900/cumm	5000-11000/cumm
Neutrophils	59%	50-70%
Lymphocytes	31%	20-40%
Eosinophils	06%	0-7%
Monocytes	04%	2-8%
PCV	38.2	37-47
MCV	77.5	76-96
MCH	29.1	27-32
MCHC	31.6	31-35
ESR	11	Male 0-9, Female 0-20mm/FHR
Blood Group	"B" POSITIVE	By Slide Method
S.Bilirubin(Total)	0.72	0.2-1.0mg/dl
Direct	0.30	0.0-0.25mg/dl
Indirect	0.42	
SGOT	21.7	5-35U/L
SGPT	26.0	8-40U/L
Alk Phosphatase	8.9	3-13 KA units
S. Protein(Total)	7.0	6.0-8.0mg%
Albumin	4.0	3.7-5.3mg%
Globulin	3.0	1.5 to 3.5 mg%
AG Ratio	1.23	1.-2.0
Blood Urea Nitrogen (BUN)	11.7	7-20 mg/dl
S.Creatine	0.71	0.5-1.4mg/dl
Uric Acid	5.8	4.8 to 7.5 mg/dl
Calcium	8.3	8.5-10.5 gm/dl
GGTP	29.2	5-35 UL/dl
Fasting Blood Sugar	85.5	up to 150mg/dl
Total Serum Cholesterol	161.9	100-250 mg%
Serum Triglyceride	127.3	Up to 160 mg%
Serum Cholesterol HDL	41.6	Up to 65 mg%
Serum Cholesterol LDL	94.8	Up to 125 mg%
VLDL	25.4	Up to 30 mg%
TC/HDL Ratio	3.20	Bellow 5
Glycosylated Hemoglobin HBA1c	5.3	Below - 6.0 % -Non Diabetic control 6-7 % -Excellent control Above- 8 % -Poor control

All test have technical limitation. Collaborative clinic pathological interpretation is mandatory. In case of disparity test may be repeated immediately. Typographical mistakes should be get correct instantly. This report is not valid for medico legal purpose



Pathologist
Dr. B. M. Agarwal
MBBS, DCP
Consultant Pathologist



दिवाकर डायग्नोस्टिक सेंटर

E-7/636, पंजाब नेशनल बैंक के पास, मैन रोड, अरेरा कॉलोनी भोपाल (म.प्र.)


फोन: 0755-2465288, 0755-3520545 मो: 9826340190

Pt.Name :-	Mrs. Bhawna Verma
Age :-	31y/F
Refd. By :-	Mediwheel
Lab.pNo.:-	03
Date :-	03/06/2022

URINE ANALYSIS

<u>A. PHYSICALEXAMINATION</u>		<u>C. MICROSCOPIEXAMINATION</u>	
1. Colour	Yellow	Pus Cells	3-4/HPF
2. Appearance	Clear	R.B.C.	Nil
3. Specific Gravity	Q.N.S.	Epithelial Cell	1-2/HPF
<u>B. CHEMICAL EXAMINATION</u>		Cast	Nil
1.Reaction	Acidic	Crystals(Cal.Oxa)	Nil
2.Albumin	Absent	Bacteria	Nil
3.Sugar	Nil	Amorphous	Nil
4.Bile Salts	Absent	T. Vaginitis	Nil

URINE COTININE	Negative	By Card method
----------------	----------	----------------



B
Dr. B. M. Agarwal
MBBS, DCP
Consultant Pathologist

All test have technical limitation. Collaborative clinic pathological interpretation is mandatory. In case of disparity test may be repeated immediately. Typographic mistakes should be get correct instantly. This report is not valid for medico legal purpose



द्विवाकर डायग्नोस्टिक सेंटर

E-7/636, पंजाब नेशनल बैंक के पास, मैन रोड, अरेरा कॉलोनी भोपाल (म.प्र.)

फोन: 0755-2465288, 0755-3520545 मो: 9826340190

Pt.Name :-	Mrs. Bhawna Verma
Age :-	31y/F
Refd. By :-	Mediwheel
Lab.pNo.:-	03
Date :-	03/06/2022
Skigram	X Ray Chest PA View
Radiologist	Dr. B.M.Agarwal MD (Radiology)

REPORT

Tricia Central

Thoracic cage normal

Both Lungs Field Clear.

Both hilers normal

Cardiac border normal


Both cp angles clear

Both domes and diaphragm normal

IMPRESSION

-NO CARDIO PULMONARY PATHOLOGY
-COORELATE WITH CLINICAL FINDINGS.




Dr. B. M. Agarwal
MD, Radiology
Consultant Radiologist
Radiologist



दिवाकर डायग्नोस्टिक सेंटर

E-7/636, पंजाब नेशनल बैंक के पास, मैन रोड, अरेरा कॉलोनी भोपाल (म.प्र.)

फोन: 0755-2465288, 0755-3520545 मो: 9826340190

Pt.Name :-	Mrs. Bhawna Verma
Age :-	31y/F
Refd. By :-	Mediwheel
Lab.pNo.:-	03
Date :-	03/06/2022


EXAMINATION OF BLOOD


Thyroid profile

<u>TEST</u>	<u>RESULT</u>	<u>NORMAL VALUE</u>
T3 - TOTAL	101.6	82-213 ng/dL
T4 - TOTAL	7.88	6.09-12.23 ug/dL
THYROID STIMULATING HORMONE (TSH)	2.10	0.45-4.25 ul/mL

Interpretation:

TSH Levels will be elevated in primary hypothyroidism, TSH levels will be low in Hyperthyroidism there is decreased production of thyroid hormones by the thyroid hence the person may experience symptoms such as weight gain, constipation, cold intolerance and fatigue. Iodine deficiency and Hashimoto thyroiditis is the most common cause of hypothyroidism It makes Thyroid stimulating hormone. If TSH levels are abnormally high it could mean you have an underactive thyroid or hypothyroidism.




Dr. B. M. Agarwal
MBBS, DCP
Consultant Pathologist

All test have technical limitation. Collaborative clinic pathological interpretation is mandatory. In case of disparity test may be repeated immediately. Typographical mistakes should be get correct instantly. This report is not valid for medico legal purpose



डॉ. सविता क्लिनिक

34, भूतल, मोहिनी अदिति आर्केड, शाहपुरा मस्जिद के पास
भरत नगर रोड, ई-7/194, अरेरा कॉलोनी, भोपाल - 462038

Mob. : 8989649694, 9516333619

Clinic Registration : CL/5392/Jun/2017

PNDT Registration : MPPCPNDT/BPL/2017/206



Name : Mrs. Bhawna Age 31/F YRS./F

R/B Health check up No. Date

WHOLE ABDOMES ULTRASOUND REPORT

Indication:

Liver appears normal in size and shape with normal outline. Normal/
increased parenchymal echogenicity is noted. No E/O focal lesion/ IHBR
dilatation is seen. Hepatic veins and portal veins appear normal.

No E/O subdiaphragmatic Collection.

Gall Bladder is physiologically well distended. No. E/O echogenic foci in GB
lumen. GB wall is normal / thickened. No E/O pericholecystic collection.
Common duct reveals normal course and caliber.

Pancreas appear normal in size, shape and echo texture with smooth
contour. No peripancreatic pathology seen. (Not seen due to gases)

Spleen is normal in size and echo texture.

IVC and aorta appear to be normal.

No evidence of lymphadenopathy is noted.

No evidence of free fluid is noted.

Right Kidney is normal in size. size, shape and position. Corticomedullary
differentiation (CMD) is well maintained. Normal cortical thickness is
noted. No E/O hydronephrosis or calculus is noted.

PTO

Dr. P. Savita, MD

MBBS, MD (O&G) Reg. No. 9971

स्त्री रोग विशेषज्ञ

Dr. Jayant Yadav, MD

MBBS, MD (Radiologist) Reg. No. 4166

रेडियोलॉजिस्ट

Left Kidney is normal in size, shape and position. CMD is well maintained. Normal cortical thickness is noted. No E/O hydronephrosis or calculus is noted.

Urinary Bladder is well distended (physiological). its contents are echo free. No E/O bladder wall thickening is noted. ~~Post-void residue is insignificant.~~

Prostate is normal in size. Shape and echo texture with smooth outline. No E/O focal lesion is noted.

Uterus is ante/~~retro~~ verted and normal in size, shape and echotexture with smooth outline. No E/O focal lesion is noted. Endometrial echo appear normal. Cervical and vaginal shadows appear normal.

Right Ovary appears ~~enlarged~~ / Normal in size, shape and echo texture.

Left Ovary appears ~~enlarged~~ / Normal in size, shape and echo texture.

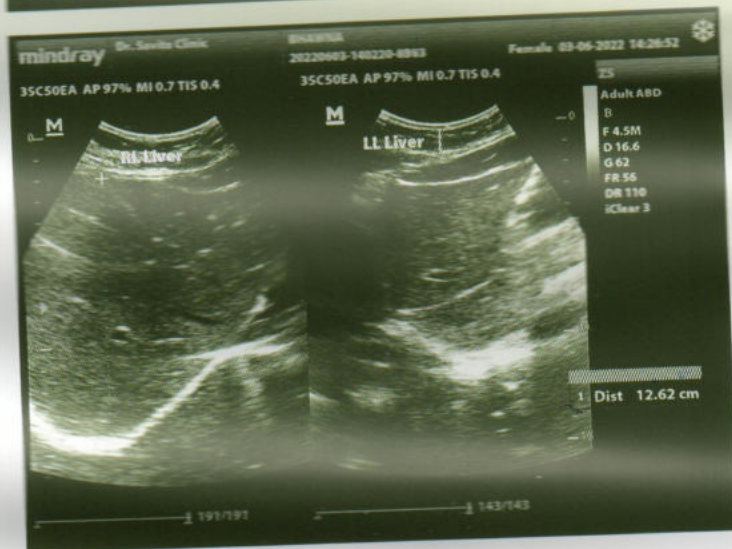
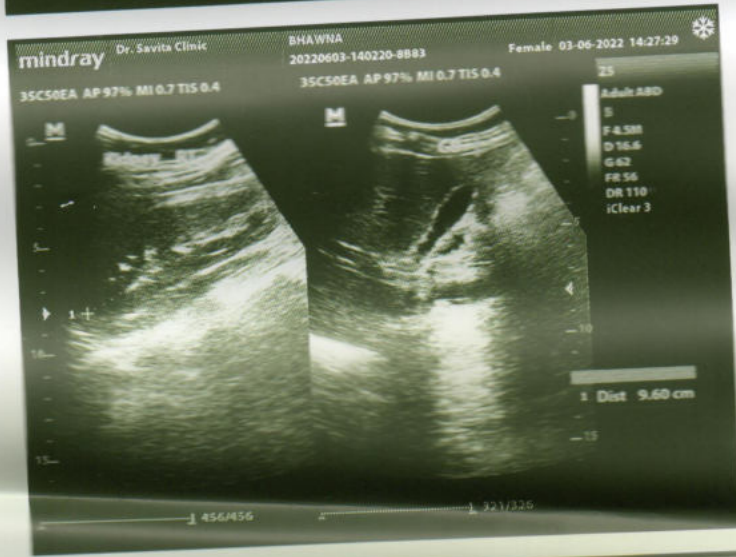
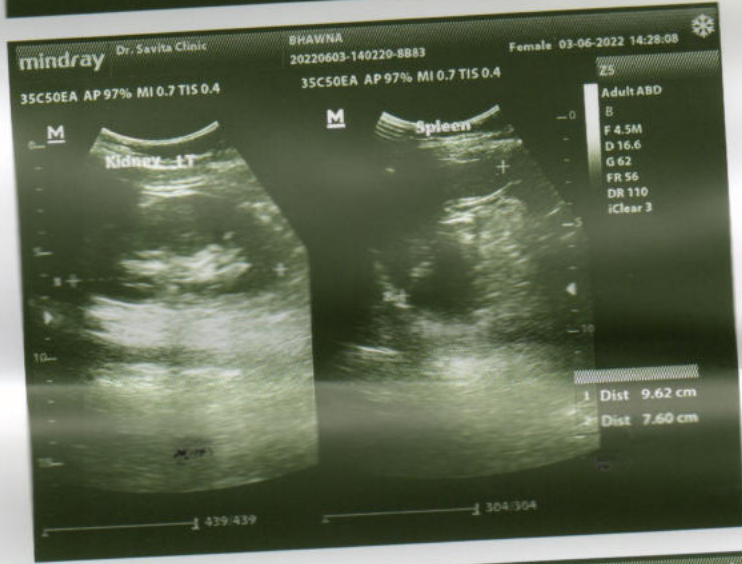
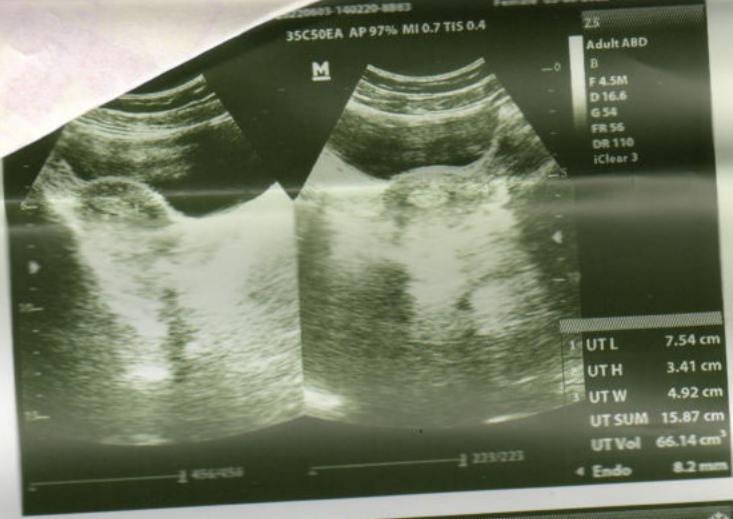
Impression : Normal study.

Advised clinical Correlation.

Jayant

Dr. P. Savita, MD
MBBS, MD (O&G) Reg. No. 9971
स्त्री रोग विशेषज्ञ

Dr. Jayant Yadav, MD
MBBS, MD (Radiologist) Reg. No. 4166
रेडियोलॉजिस्ट



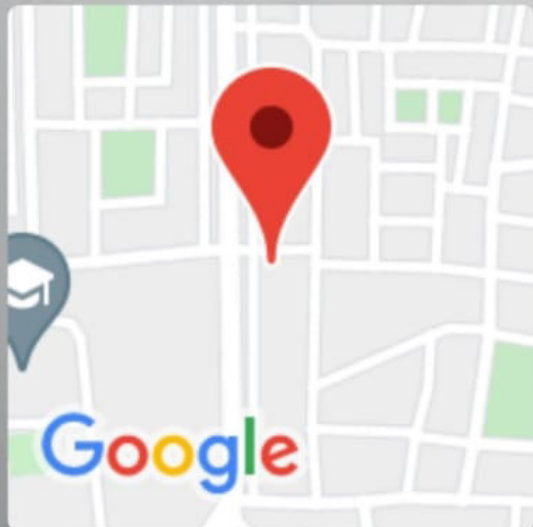


Diwakar Diagnostic Centre

पेथोलोजी | टी.एँम.टी. | एक्स-रे | ई.सी.जी. | एको कार्डियो ग्राफी | सोनोग्राफी



GPS Map Camera



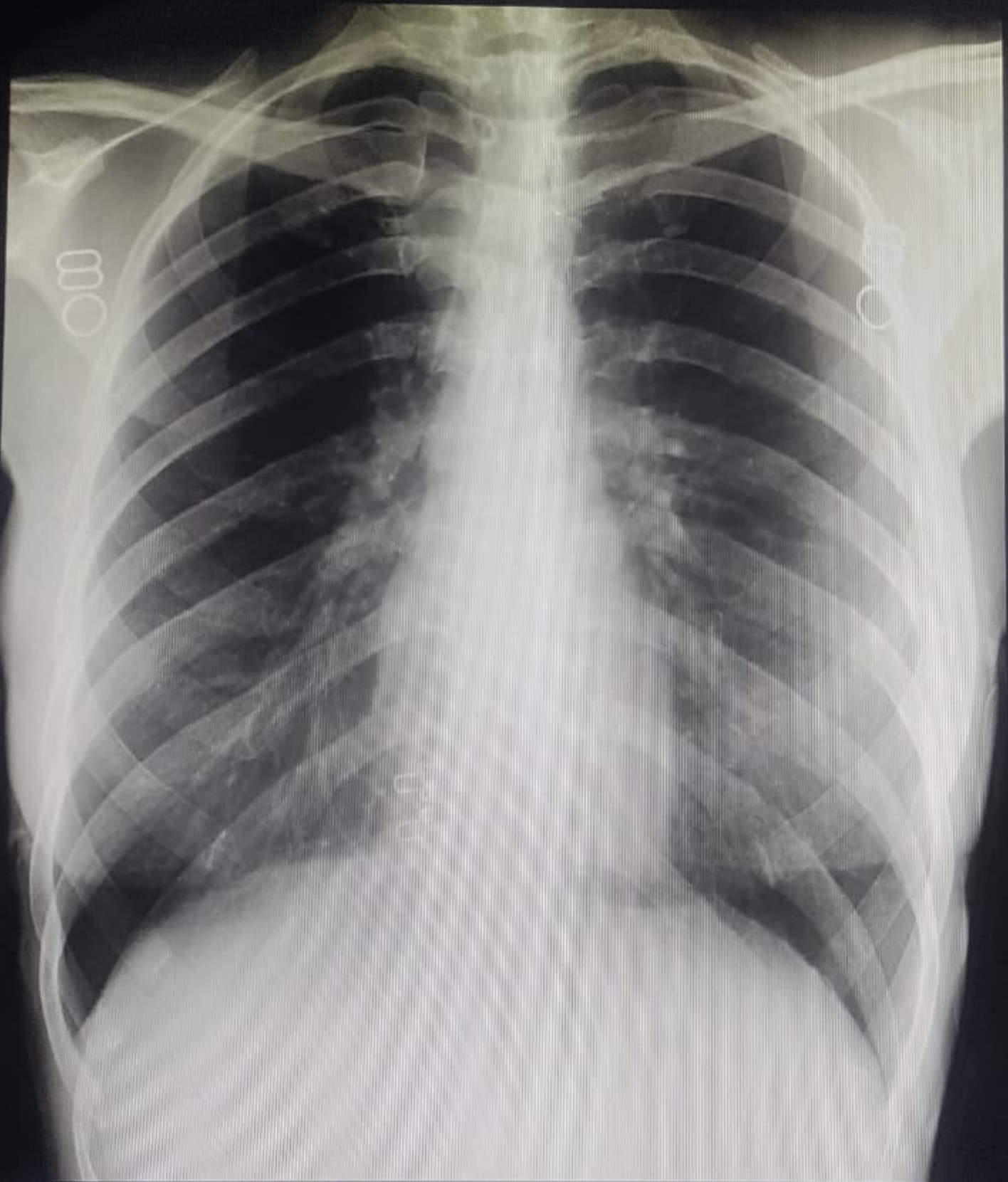
Bhopal, Madhya Pradesh, India

636, Champion School Rd, E-7, Arera Colony, Bhopal, Madhya Pradesh 462016, India

Lat 23.205828°

Long 77.431619°

03/06/22 12:52 PM



**MRS BHAVNA VERMA 31Y 1108 CHEST,FRN P->A 03-JUN-22
DIWAKAR DIAGNOSTIC CENTRE , ARERA COLONY ,BHOPAL**