

# Siddhivinayak HOSPITAL

S-1, Vedant Complex, Vartak Nagar, Thane (W)-400606, Tel.: 2588 3531/7151

## Corporate Health Centre

Reg. No. AP  
Date: 04.04.2024

Blood  Urine  Stool  Vaccine  ECG  2D Echo  TMT  X-Ray  PFT  Audio  USG  OPT  Dr.

Employee's Name : Tarannum Pathan

With ~~Glass~~ / Without Glasses

Blood Group : \_\_\_\_\_

Age/Sex : 27 / F

Contact No. : 9146449168

	Rt.	Lt.
NEAR	N16	N16
DISTANT	616	616
COLOUR VISION	Normal	

### PHYSIOLOGIC PARAMETERS :

Ht. (Cms.) 161 Wt. (Kgs.) 48 BMI

### COMPLAINTS : (Specify if any)

No fresh complaints.

### GENERAL EXAMINATION

Pulse (Min) : 70/min BP (mm Hg) : 110/70 mmHg  
R.R. (Min) : 18/cpm Temp. Afebrile  
Pallor : NAD Icterus : NAD  
Clubbing : NAD

### ENT EXAMINATION (Specify if Abnormal)

Ear \_\_\_\_\_ Nose \_\_\_\_\_ Tongue (N)  
Teeth \_\_\_\_\_ Tonsils \_\_\_\_\_ Gums \_\_\_\_\_

PAST HISTORY : H/O - operated for septoplasty & DNS in childhood.

M/O - RTA 4-5 yrs. No any # history.

FAMILY HISTORY : Mother - HTN. } expired.  
father - HTN. }

SURGICAL HISTORY : for DNS - septoplasty (for nose know)

### SYSTEMIC EXAMINATION

LOCOMOTOR SYSTEM NAD  
RESPIRATORY SYSTEM AEBE clear  
CARDIOVASCULAR SYSTEM S, S2 ⊕  
CENTRAL NERVOUS SYSTEM cons, oriented  
ABDOMEN soft  
GENITAL SYSTEM NAD  
MUSCULOSKELETAL SYSTEM NAD

### PERSONAL HISTORY (Addiction if any)

Chronic / Frequent / Occasional : No  
Smoker / Tobacco Chewer / Alcoholic : No.

PFT MEANS PRED % PRED

SVC  
FVC  
FEV1 / FVC  
Remark

Audiometry 500 1000 2000 Frequency in Hz 4000 6000 8000

Right Ear  
Left Ear  
Remark

[Signature]  
DOCTOR SIGNATURE

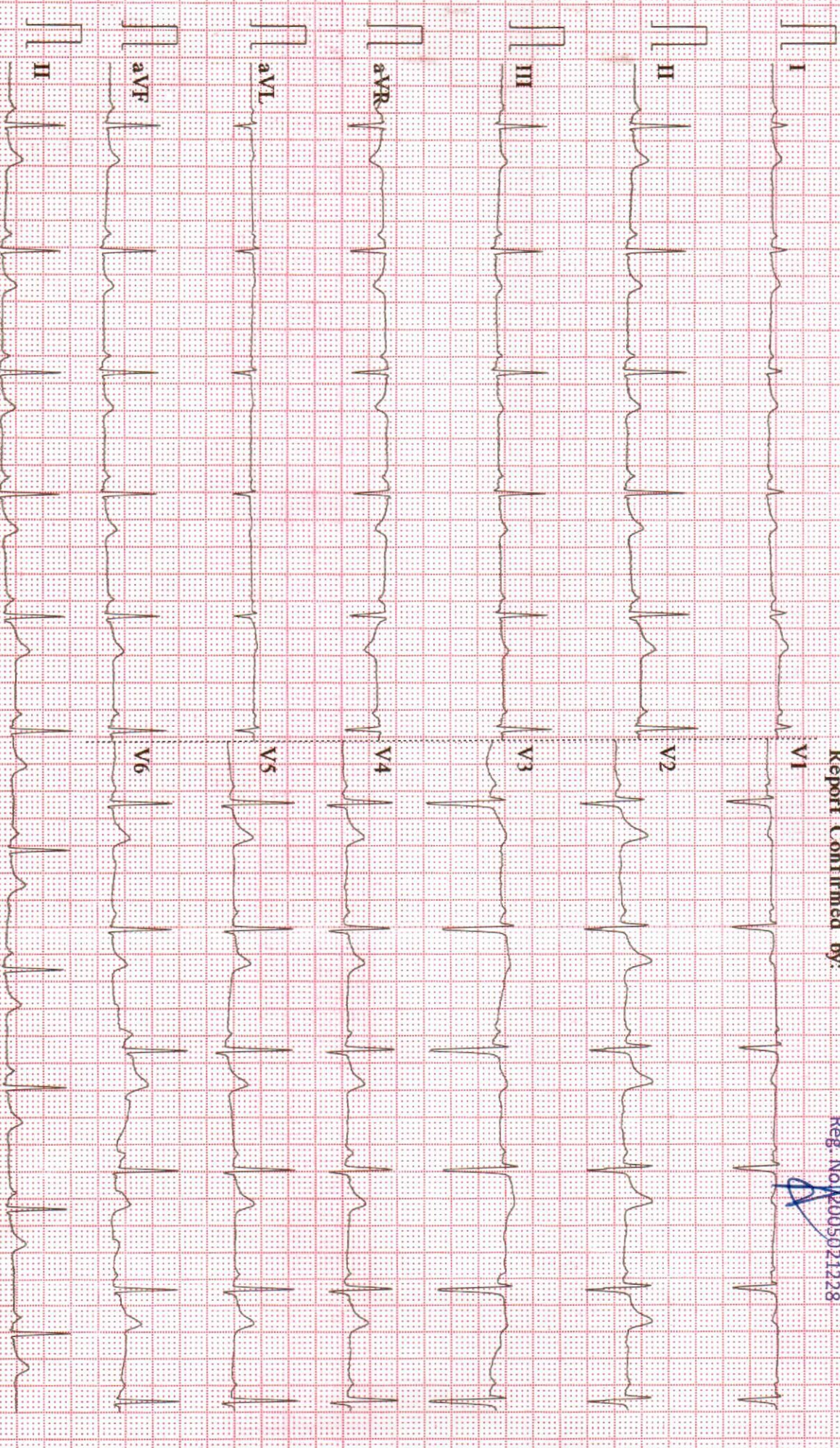
**DR. VISHAL DALVI**  
MBBS, MD (Medicine)  
Consultant Physician  
Reg. No. 2011/09/3121

ID-1267  
 Female  
 Req. No. :  
 Years : 27-11F  
 BP - 110/70 mmHg  
 SpO2 - 99%  
 PR - 94/m

04-04-2024 09:51:14 AM  
 HR : 67 bpm  
 P : 88 ms  
 PR : 133 ms  
 QRS : 77 ms  
 QT/QTcBz : 377/398 ms  
 P/QRST : 61/78/58  
 RV5/SV1 : 1.14/0.698 mV

Diagnosis Information:  
 Sinus Rhythm ✓  
 \*\*\*Normal ECG\*\*\*  
 NSR  
 No significant ST-T wave changes -  
 No immediate intervention needed.

Report Confirmed by:  
 Dr. Anant Ramkishanrao Munde  
 MBBS, DNB, DM (Cardiology)  
 Reg. No. 2005021228



0.15-45Hz AG50 25mm/s 10mm/mV 2\*5.0s+1r V2.21 SEMIP V1.92 Siddhivinayak Hospital



Name - Ms. TARANNUM PATHAN	Age - 27 Y/F
Ref by Dr.- Siddhivinayak Hospital	Date - 04 /04/2024

### X- Ray chest (PA VIEW)

No obvious active parenchymal lesion seen in both lungs.

Cardiac and aortic shadows appear normal

No evidence of pleural of effusion is seen.

Both domes of diaphragm appear normal.

No obvious bony lesion is seen.

#### IMPRESSION:

- No significant abnormality seen.

Adv.: Clinical and lab correlation.

**DR. AMOL BENDRE**

MBBS; DMRE

CONSULTANT RADIOLOGIST

Note: The above report represents interpretation of various radiographic / sonographic shadows, and hence has its own limitations. This report has to be co-related clinic-pathologically by the referring / physician and it does NOT represent the sole diagnosis.

**DR. AMOL BENDRE**  
MBBS DMRE  
Reg. No. 2015/08/4412

