



# ABI SCANS & LABS

A unit of Aarthi Scans and Labs

NAME	MR. MURALIDHARAN S	PATIENT ID	89223
ACCESSION NO	92964	AGE/GENDER	37Y/MALE
REFERRED BY	MEDIWHEEL	DATE	25.03.2022

## ECHOCARDIOGRAPHIC EVALUATION

MEASUREMENTS: ACOUSTIC WINDOW: OPTIMAL

### 2D/ M MODE PARAMETERS:

Parameters	Patient Values	Normal Adult Value
LA	3.18	(2.0 - 4.0 cm)
AO	2.95	(2.0 - 4.0 cm)
LVIDD	5.02	(3.5 - 5.5 cm)
LVIDS	3.34	(2.5 - 4.3 cm)
IVSd	0.98	(0.6 - 1.2 cm)
LVPWd	1.0	(0.6 - 1.2 cm)
EF	63	(50% - 70%)

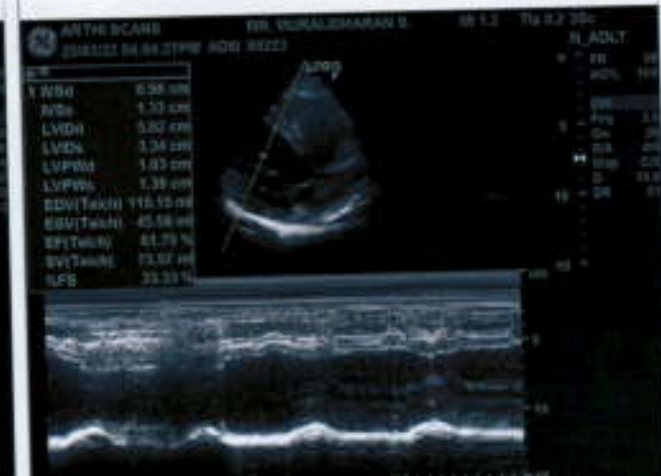
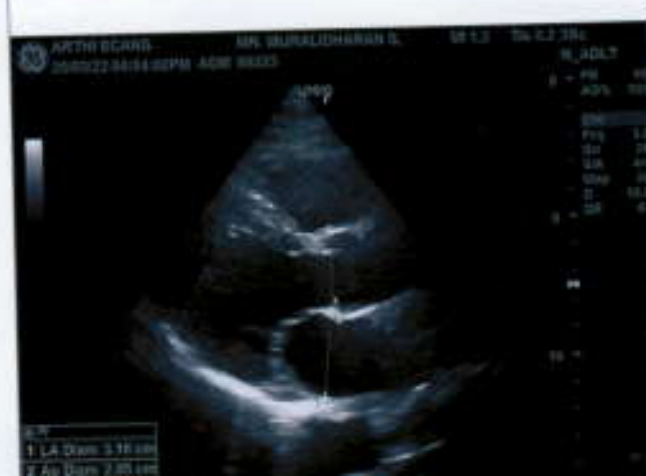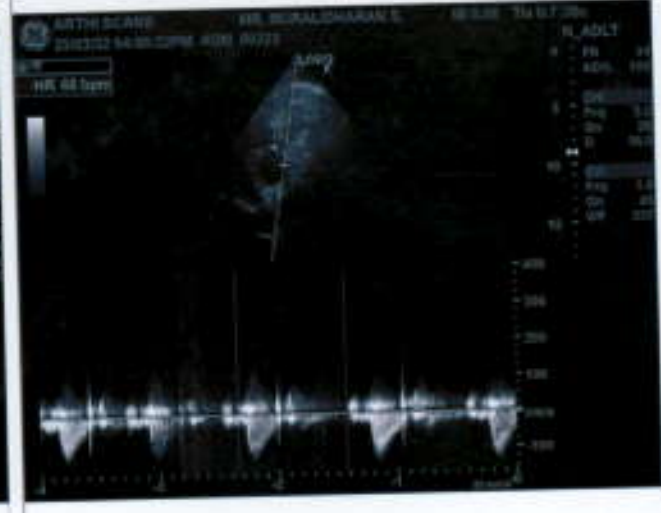
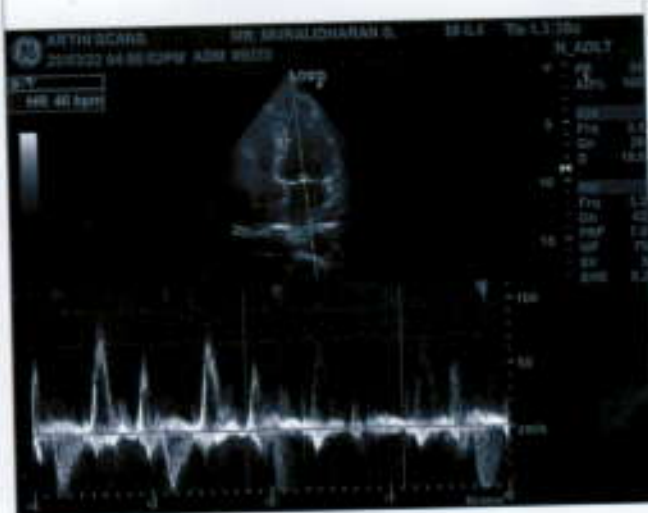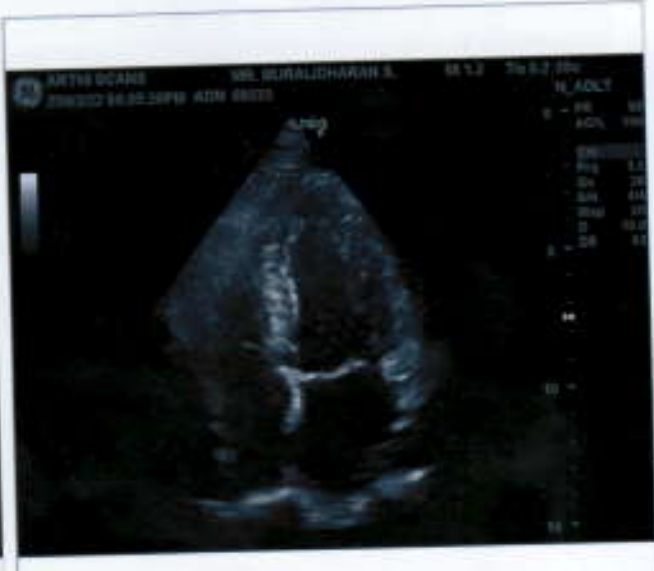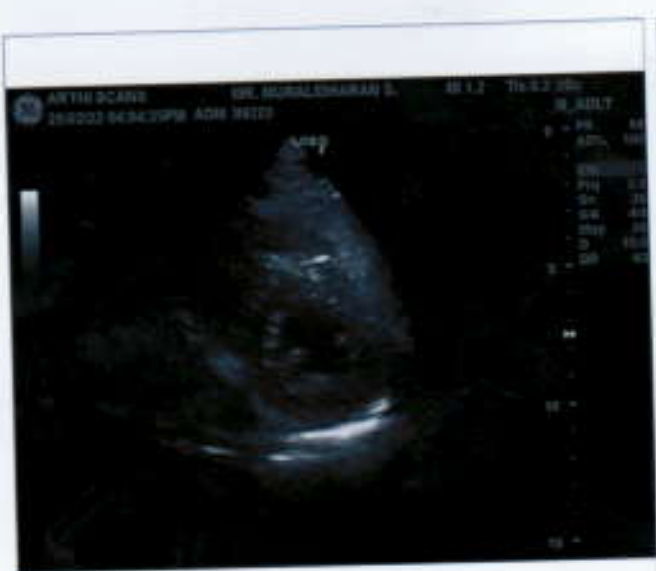### IMPRESSION:

- ✚ No regional wall motion abnormality at rest.
- ✚ Normal valves and chambers.
- ✚ No pulmonary hypertension.
- ✚ No pericardial effusion.
- ✚ Normal LV systolic function.

Dr. KARTHIK C.S.MD.,PGD(CARDIOLOGY,UKR)  
CONSULTANT CARDIOLOGIST.

# ABI SCANS & LABS

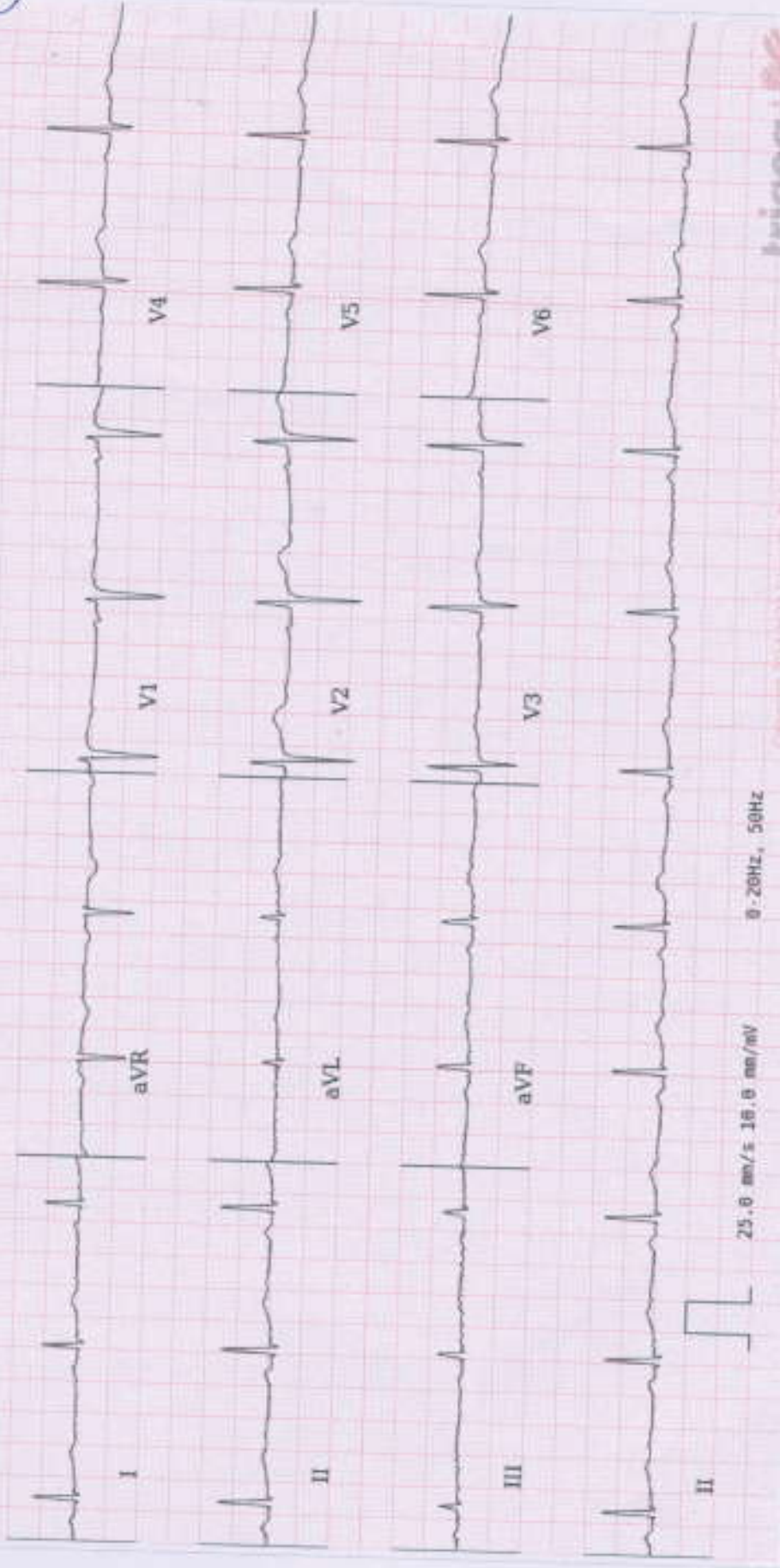
MR. MURALIDHARAN S 37Y/M 89223 25-Mar-2022 02:44:37 PM Physician Name



Age / Gender: 37/Male  
Patient ID: 0000089223  
Patient Name: MR. MURALIDHARAN S

Date and Time: 25th Mar 22 10:40 AM

BP-120/70 mmHg.



tricog

AP: 63bpm VR: 63bpm QRS0: 76ms QT: 412ms QTc: 421ms PRI: 162ms P-R-T: 43° 46° 42°  
25.0 mm/s 16.0 mm/mV 0.20Hz, 50Hz

Within Normal Limits: Sinus Rhythm, Normal Axis. Please correlate clinically.



This report is based on ECG done and should only be used as an adjunct to clinical history, symptoms and results of other invasive and non-invasive tests and must be interpreted by a qualified physician.



# ABI SCANS & LABS

A unit of Aarthi Scans and Labs

NAME	MR. MURALIDHARAN S	PATIENT ID	89223
ACCESSION NO	92964	AGE/GENDER	37Y/MALE
REFERRED BY	MEDIWHEEL	DATE	25 -MARC-2022

## VISION TEST

### VISUAL ACUITY (VA)

If The Acuity Can Be Measures, Complete This Box Using Snellen acuities or snellen equivalents or NLP,LP,HM, or distance at which the patient sees the 20/100 letter.

### WITH BEST CORRECTION

DISTANCE VISION	
Right	11/11
Left	10/11
Both	11/11

NEAR VISION	
Right	N6
Left	N6
Both	N6

COLOUR VISION	
BOTH	Normal



# ABI SCANS & LABS

A unit of Aarthi Scans and Labs

Patient Name	MR.MURALIDHARAN S 37Y	Age	37Yr
Patient ID	92964	Sex	Male
Referral Dr	MEDIWHEEL	Study Date	25 Mar 2022

## X-RAY - CHEST PA VIEW

### OBSERVATION:

The trachea is central.  
The mediastinal and cardiac silhouette are normal.  
Cardiothoracic ratio is normal.  
Cardiophrenic and costophrenic angles are normal.  
Both hila are normal.  
Lung zones are clear.  
Bones of the thoracic cage are normal.  
Soft tissues of the chest wall are normal.

### IMPRESSION:

No significant abnormality seen.

Dr. Abinaya., MD., (RD)  
Consultant Radiologist



# ABI SCANS & LABS

A unit of Aarthi Scans and Labs

Name	MR. MURALIDHARAN S	Patient ID	89223
Accession No	92964	Age/Gender	37Y / Male
Referred By	MEDIWHEEL	Date	25-Mar-2022

## USG REPORT - ABDOMEN AND PELVIS

### LIVER:

Liver is normal in size (measures ~ 12.9 cm) and shows increased echotexture.

No focal liver lesion. No intra hepatic biliary radical dilatation seen.

### GALL BLADDER:

Is adequately distended. No calculus or cholecystitis seen.

### PANCREAS:

Appears normal in size and shows uniform echo texture. The pancreatic duct is normal. No calcifications are seen.

### SPLEEN:

Appears normal in size and it shows uniform echo texture. It measures ~ 9.9 cm in long axis.

### RIGHT KIDNEY:

Right kidney measures ~ 10.6 x 4.7 cm.

The shape, size and contour of the right kidney appear normal.

Cortico medullary differentiation is within normal. No evidence of pelvicalyceal dilatation.

No calculi seen.

### LEFT KIDNEY:

Left kidney measures ~ 10.9 x 4.4 cm.

The shape, size and contour of the left kidney appear normal.

Cortico medullary differentiation is within normal. No evidence of pelvicalyceal dilatation.

No calculi seen.



# ABI SCANS & LABS

A unit of Aarthi Scans and Labs

Name	MR. MURALIDHARAN S	Patient ID	89223
Accession No	92964	Age/Gender	37Y / Male
Referred By	MEDIWHEEL	Date	25-Mar-2022

## USG REPORT - ABDOMEN AND PELVIS

### URINARY BLADDER:

Is normal contour. No intra luminal echoes are seen.

### PROSTATE:

Prostate appears normal, Measures ~ 3.1 x 2.2 x 3.2 cms (Vol - 12 cc).

### RIGHT ILIAC FOSSA:

No focal fluid collections seen.

No evidence of hernia seen in anterior abdominal wall.

### IMPRESSION:

❖ Grade I fatty liver.

- Suggested clinical correlation.

  
Dr. Lokesh Babu, MDRD.,  
Radiologist

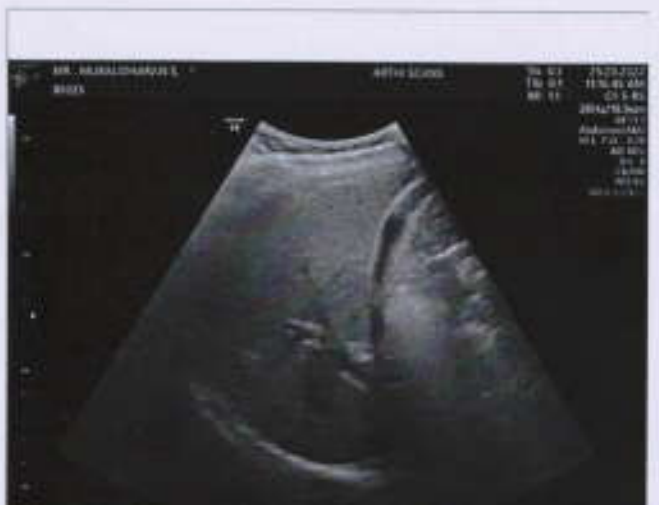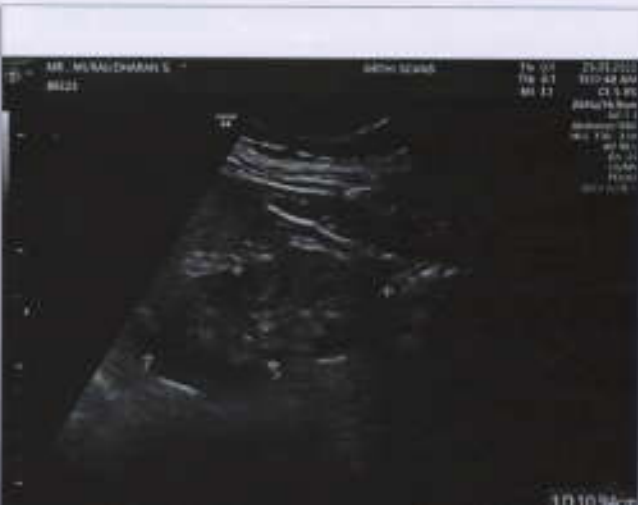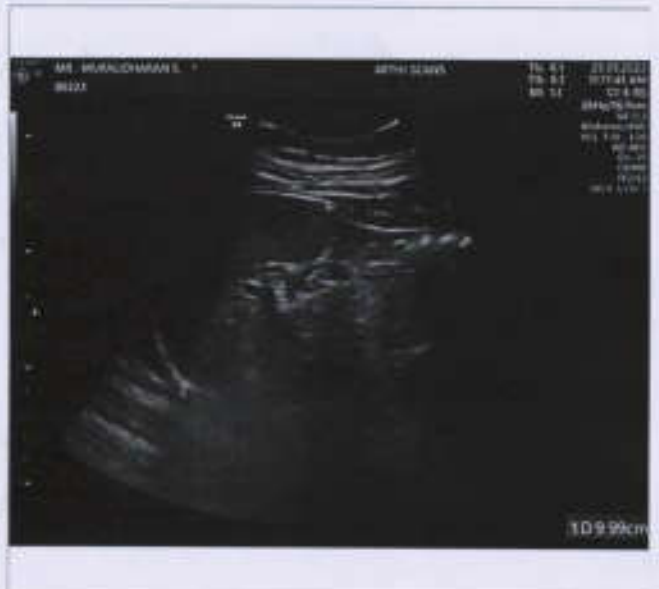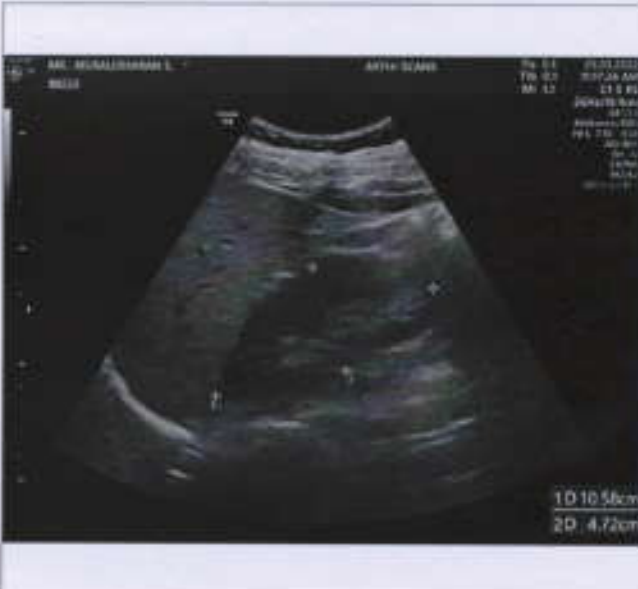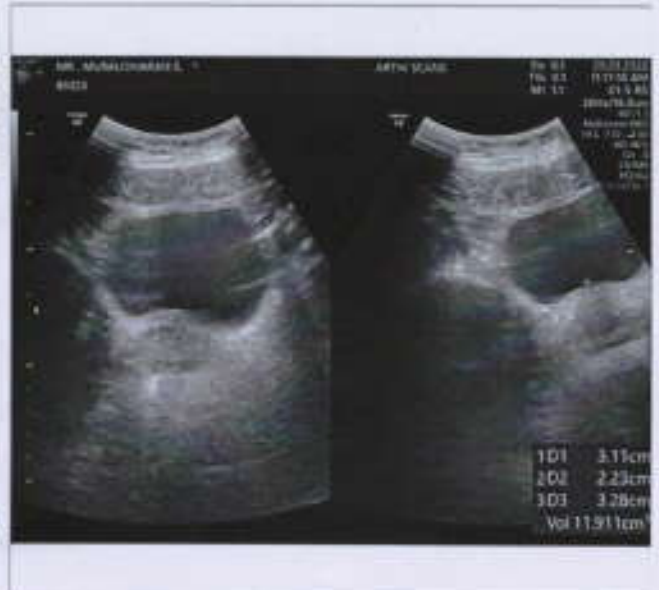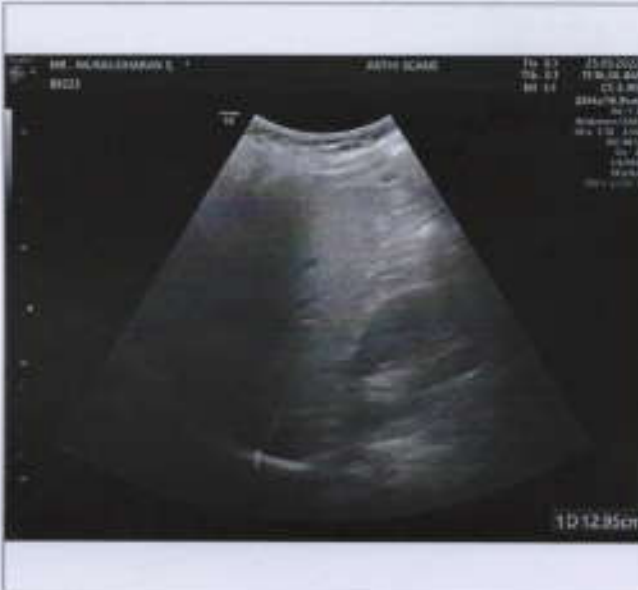Thank you for the courtesy of this referral

Foot Note: Patient's identity is not verified. Report is not valid for medico legal purpose.

Dr. Lokesh Babu, MD.,RD.,  
Reg. No: 113030

# ABI SCANS AND LABS

MR . MURALIDHARAN S /M 89223 25-Mar-2022 09:13:37 AM








இந்திய சர்க்கார்  
 Government of India



முருகிதரன் டி  
 Muralidharan S  
 சமூக நல அமைச்சு  
 துணைவர் / SDA

21/11/2013

7568 8195 0406

எனது ஆதார். எனது அடையாளம்




இந்திய சமூக நல அமைச்சு  
 Unique Identification Authority of India

முகவரி: C/O செந்தமரன், பழைய நெடு வீதி எண் 54, சாஸ்திரி வீதி, சென்னை-600015, சென்னைக்குள் எ. 46, சென்னைக்குள், தமிழ்நாடு, 600015



7568 8195 0406

 1947
 help@uidai.gov.in
 www.uidai.gov.in

[Handwritten Signature]