

NAME: MR. SOMNATH SATPUTE	DATE: 14/04/2023
AGE/SEX: 35 YEARS / MALE	REFERRED BY: HEALTH CHECKUP

XRAY CHEST PA (VIEW)

Both the lungs are clear and do not show any obvious focal lesion.

Bilateral costo-phrenic and cardio-phrenic angles appear clear.

There is no evidence of pleural effusion or pneumothorax on either side.

Both the hilum appear normal.

Domes of diaphragm have normal contours and positions.

Visualised bones and soft tissues reveal no abnormality.

CONCLUSION:

No significant abnormality is seen.

Advise clinical correlation.


DR TRIPTI PAREEK
(DNB RADIOLOGIST)

NAME: MR. SOMNATH SATPUTE	DATE: 14/04/2023
AGE/ SEX: 35 YEARS/ MALE	REFERRED BY: HEALTH CHECKUP
<u>ULTRASOUND ABDOMEN & PELVIS</u>	

Clinical profile- Health checkup

Liver: Normal in size (13.7 cm), shape and shows normal echotexture. No evidence of any space occupying lesion seen. Intrahepatic biliary radicals are not dilated. Portal vein is normal in caliber.

Gallbladder: GB is partially distended. No evidence of any calculus seen. No wall thickening/pericholecystic fluid collection noted. CBD is normal in caliber.

Pancreas: Head & part of the body is visualized, appears normal in bulk & echotexture. Rest of the pancreas is obscured by bowel gases.

Spleen: Appears normal in size (11.5 cm), shape and echotexture. No calcification or mass is seen. Splenic vein is not dilated.

Kidneys: Right Kidney – 9 x 4.1 cm. Left Kidney – 10.1 x 5.5 cm.

Both kidneys are normal in size, shape, positions and echotexture. Bilateral corticomedullary differentiation appears normal. No hydronephrosis seen. No evidence of any calculus or mass lesion seen.

Urinary Bladder: is well distended. No evidence of calculus/ wall thickening noted.

Prostate is normal in size and echotexture.

Free fluid: No evidence of any free fluid in peritoneal cavity.

IMPRESSION:

No significant abnormality seen.

Clinical correlation is suggested.


DR TRIPTI PAREEK
(DNB RADIOLOGIST)

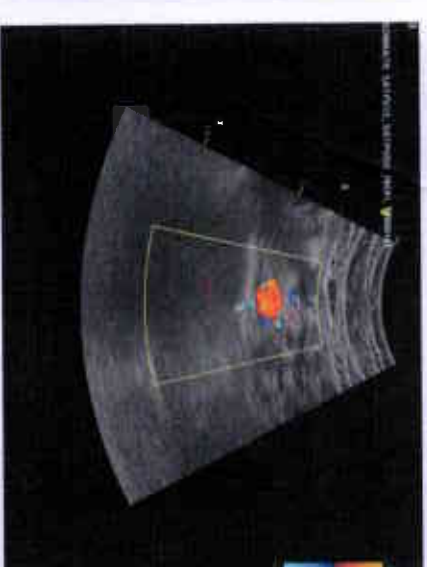
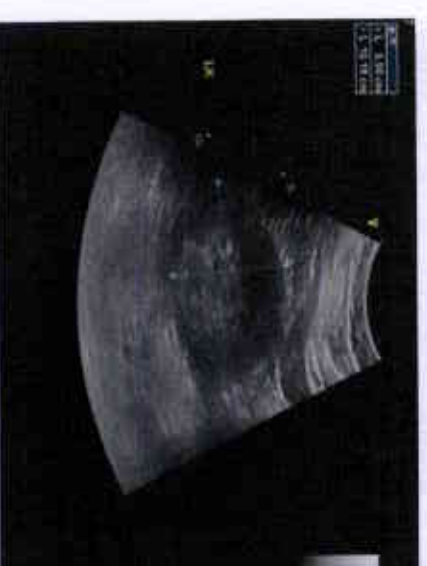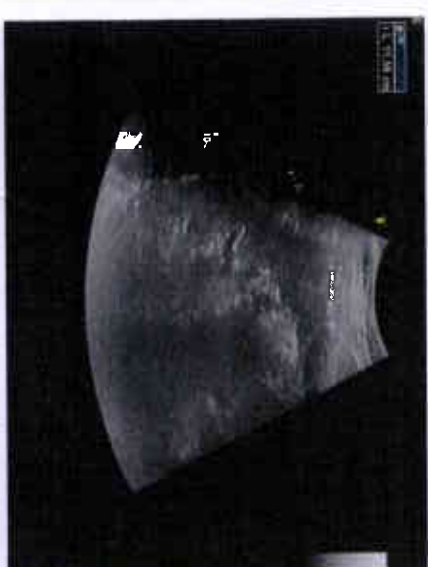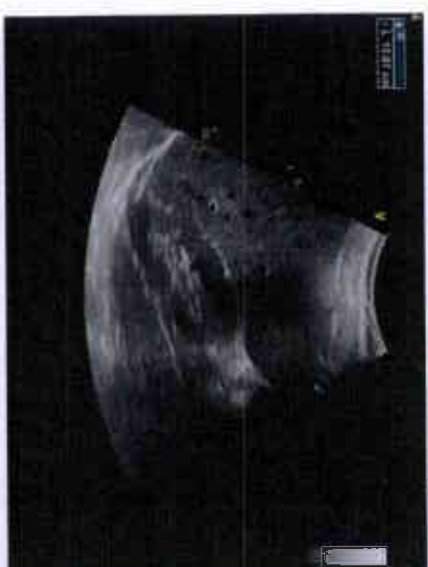
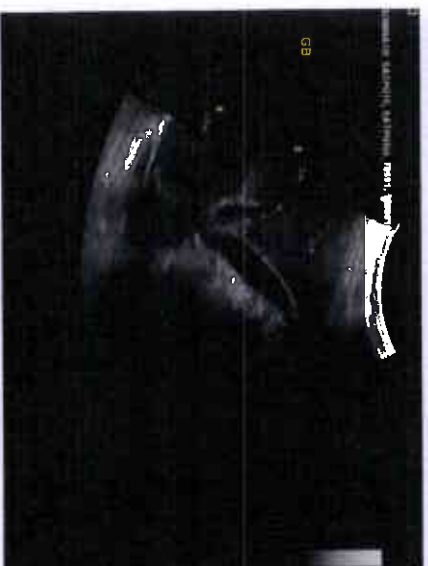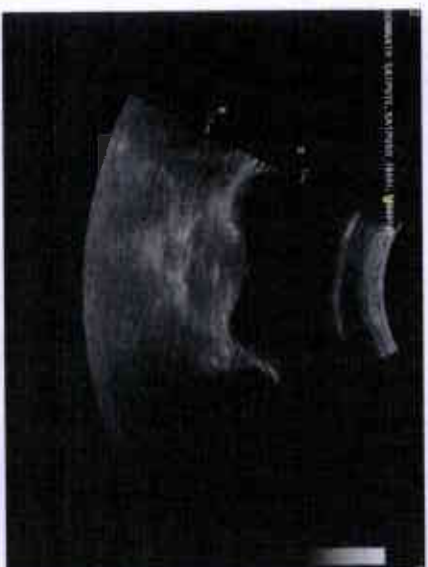
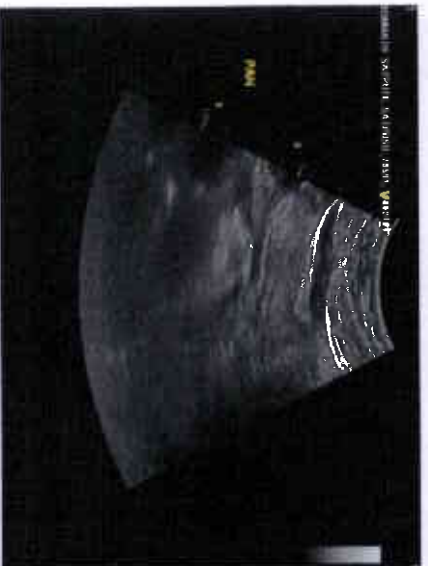MAGNUM MULTISPECIALTY HOSPITAL
NASIK ROAD, NASHIK

Name **SATPUTE, SOMNATH**

Sex **Male**

Age **35**

Date **14/04/2023**



PATIENT NAME: - SOMNATH SATPUTE

AGE/SEX- 36 YRS / M

DATE :-14/04/2023

REF:- MEDIWHEEL HEALTH-CHECK UP

Normal LV Size & Function

No regional wall motion abnormality.

Normal LV & RV systolic function. LVEF-60%.

No S/o Diastolic Dysfunction.

Left atrium is normal.

Normal RA and RV size and shape.

Normal RV systolic function.

PASP - 20mmHg

No Pulmonary Hypertension.

IVC Collapsing with respiration. No Clot/Vegetation.

IVS and IAS are intact.

Normal pericardium. No effusion.

IMPRESSION:- Good LV Function with LVEF- 60%



DR. RAHUL SHIRWALE
M.D. (Medicine)
D.M. (Cardiology)
Consultant Cardiologist
Regd. No. 2010041390