



2DECHO&DOPPLER REPORT

NAME: MR. GHOLVE PRADIP AGE:33Yrs/M DATE: 12/11/2022

MITRAL VALVE: has thin leaflets with normal subvalvar motion.
No mitral regurgitation .E= 0.78 & A=0.44m/sec, E/A ratio- 1.78, E/E' ratio-6.69
AORTIC VALVE : has three thin leaflets with normal opening
No aortic regurgitation.AVPG= 3.37 mmHg
PULMONARY VALVE; NORMAL,PVPG= 3.08 mmHg
LEFT VENTRICLE : is normal , has normal wall thickness, No RWMA at rest .
Normal LV systolic function. EF - 60%.
LEFT ATRIUM: is normal.
RIGHT ATRIUM & RIGHT VENTRICLE: normal in size. TAPSE =21 mm.
TRICUSPID VALVE & PULMONARY VALVES : normal.
Trivial TR, PPG = 20 mmHg. PA Pressure = 25 mmHg.
No PH.
No pericardial effusion.
M- MODE :

AORTA	LA	LVI DD	LVIDS	IVS	PW	LVEF
34mm	32mm	42mm	24mm	10mm	10mm	60%

IMP : Normal LV Systolic function. EF-60%.
No diastolic dysfunction
No RWMA at rest
Normal Valves and Chambers
IAS & IVS Intact
No clot / vegetation / thrombus / pericardial effusion.

DR. KEDAR KULKARNI
DNB(MEDICINE), DNB(CARDIOLOGY)
CONSULTANT INTERVENTIONAL CARDIOLOGIST

Name: GHOLVE PRADIP.	Exam Date : 12-Nov-2022 13:40
Age : 033Y	Accession: 82719134017
Gender: M	Exam: ABDOMEN AND PELVIS
PID: P00000449074	Physician: HOSPITAL CASE ^{^^^}
OPD :	

ULTRASOUND OF ABDOMEN AND PELVIS

Liver appears normal in size 13.6 cm , shape and echotexture. No focal lesion is seen. No intrahepatic biliary radicle dilatation seen. The portal vein and CBD appear normal.

Gall bladder is well distended with normal wall thickness. No calculus or sludge is seen.
Pancreas appears normal in size and echotexture. No focal lesion is seen.
Spleen appears normal in size and echotexture. No focal lesion is seen.

Right kidney measures 9.3 x 4.0 cms. Left kidney measures cms. Both kidneys appear normal in size, shape & echotexture. They show good cortico-medullary differentiation. There is no hydronephrosis, hydroureter or calculus seen on either side.

The urinary bladder is well distended. Wall thickness is normal. No mass lesion or calculus is seen.

Prostate is normal in size, shape and echotexture. No obvious focal lesion is seen on present transabdominal study.

Visualised bowel loops are non-dilated and show normal peristalsis.
There is no ascites or significant lymphadenopathy seen.

IMPRESSION :No abnormality detected.



DR. YATIN R. VISAVE
CONSULTANT RADIOLOGIST
MBBS, DMRD
Regd. No. 090812

Date: 14-Nov-2022 10:07:40

Name: GHOLVE PRADIP .
Age : 33 Years
Gender: M
PID: P00000449074
OPD :

Exam Date : 12-Nov-2022 13:07
Accession: 82749153311
Exam: CHEST X RAY
Physician: HOSPITAL CASE^{^^^}

Clinical Profile : Health Check

Radiograph Chest PA View :

Both lung fields normal.

Both costo-phrenic angles are clear.

Cardiac silhouette and aortic knuckle are normal.

Both hilar shadows and the diaphragmatic contours are normal.

Thoracic soft tissues and the rib cage normal.

Impression :

No significant abnormality noted.



DR. YATIN R. VISAVE
CONSULTANT RADIOLOGIST
MBBS, DMRD
Regd. No. 090812

Date: 14-Nov-2022 11:55:32

Dental OPD

12.11.2022

Ms. Pradip. N. Gholre

33/M.

C/C:- Pt. has come for regular dental check up.

O/E:-

- Gen. stains (+++) and calculus (++) present.
- Chewee's Keratosis present.

Dx:-

- CGG. \bar{c} localised periodontitis in \odot anterior.

Rx:-

- Scaling and Root planing.

Priya
(Dr. Priya Lalawalkar
MDS)

Medication:
Symptoms:

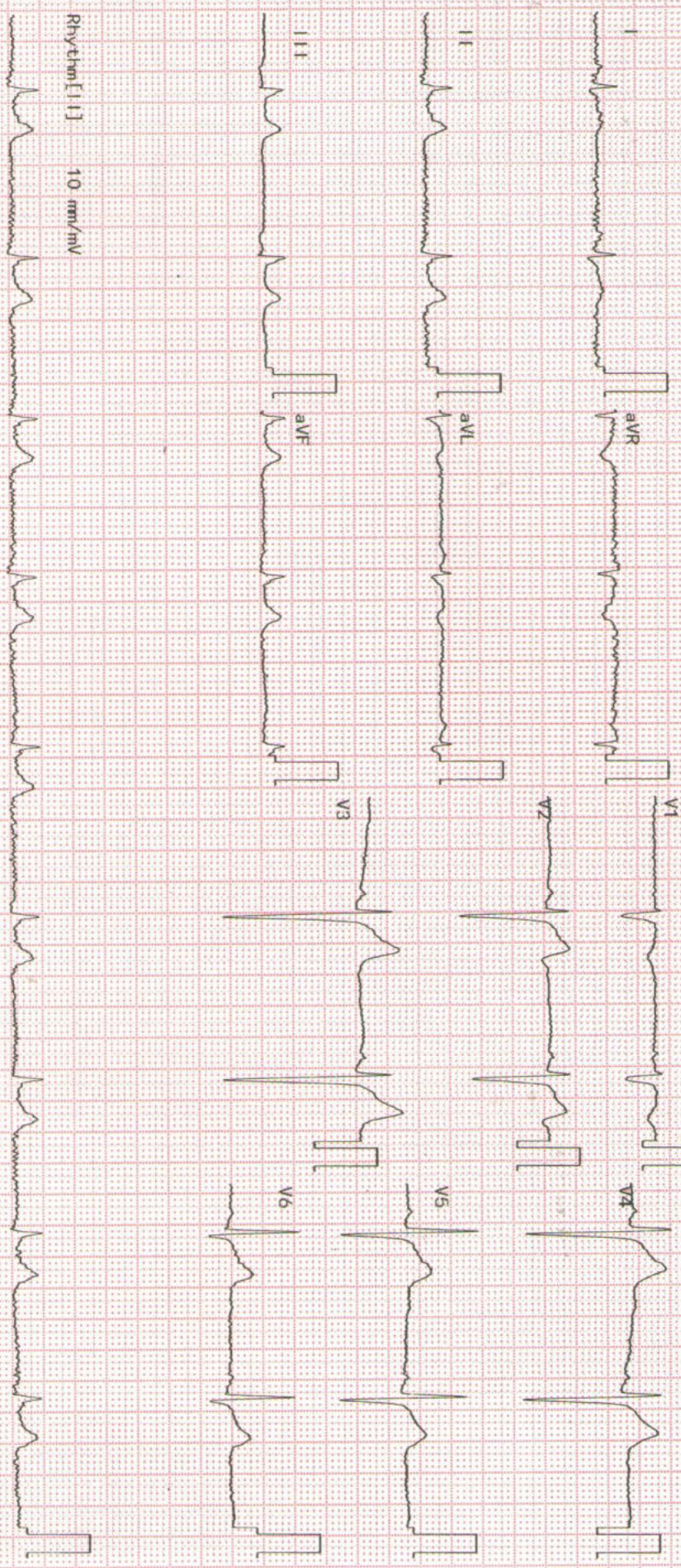
History:
Vent. rate 56 bpm
PR int 132 ms
QRS dur 96 ms
QT/QTc(E) int 386/ 378 ms
P/QRS/T axis -30/ 48/ 69 °
RV5/SV1 amp 1.23/ 0.52 mV
RV6/SV1 amp 1.75 mV

Unconfirmed Report
Reviewed by:

10 mm/mV 25 mm/s Filter: H50 D 35 Hz 10 mm/mV

10 mm/mV

10 mm/mV



2350K 02-03 04-05 Dept:

Exam: RUBY HALL CLINIC HINJEWADI