

आयकर विभाग  
INCOME TAX DEPARTMENT

भारत सरकार  
GOVT. OF INDIA


S KIRTHIKA  
SRINIVASAN

29/09/1994  
Permanent Account Number

CTJPK2170B

S. Kirthika  
Signature

10112012



# Master Health Check-up

SENTHIL  
MULTI SPECIALITY  
HOSPITAL



547, PERUNDURAI ROAD, ERODE-638011.

☎ 0424-2260375, 2260376, 2260377

Name : Miss. Kirthika

Date : 10/02/2024 I.D.No. 170/45

Age : 29 Occupation : -

Sex : Male  Female  Tel. No 88 384-55928

Address : Dossinivasan. 1/27 F

Examined by Dr.: DR. Cholera Priya Kondu

Sillanlathu. Kathedi. Salem.

CONSULTANT : PHYSICIAN-IN-CHARGE

## MEDICAL SUMMARY

Chief complaints :

Patient came with clo  
irregular periods since 1 year.

History of Present illness :

clo occ. Brownish discharge  
+ foul smelling ⊕.

No lower abdominal pain.

No other complaints.

# Systemic Review

## I. Cardiovascular System :

- Chest pain
- Breathing Difficulty
- Palpitation
- Swelling-feet
- History of High Blood Pressure
- Any medications

## II. Respiratory system including naso bronchial complaints:

- Sneezing
- Running nose
- Nose block
- Cough
- Dyspnoea
- Wheezing

## III. Dental: Normal

## IV. Gastro Intestinal system :

- Appetite Normal
- Abdominal pain
- Flatulence and Dyspepsia
- Bowel habits Normal
- Peptic ulcers Nil
- Mouth ulcers Nil
- Piles Nil

## V. Genito urinary :

- Frequency 5-6 / Day
- Burning Nil
- Urgency Nil
- Hesitency Nil
- Prostate enlargement
- Hydrocele
- GYN
- Dribbling Nil
- Overflow
- Night

## VI. Central Nervous System :

- Headache
- Giddiness
- Memory and Concentration Normal
- Neuritis
- Subjective
- objective
- Aura
- Sleep Normal pattern

VII. Eyes :

→

Vision Wearing Spectacles since  
Hearing Normal (10) years.

VIII. Ears :

IX. Spine & Joints : Normal

X. Skin: Black spots on facial region.

XI. General Symptoms:

XII. Present Medications

Nil

### Past History

Medical ⊖

Surgical ⊖

Personal History : Unmarried

Marital Status : S / M / W

Habits-Cigarettes

Tobacco & Snuff

No. of Children

Diet

Veg. / Non-Veg.

Alcohol

Physical Activity (N)

Mixed

### Drug Allergies

Nil

### Family History :

Father 55 Alive, Polio.

Mother 52 Alive, no comorbidities

Siblings Elder sister 32 Alive Healthy.

Diabetes ⊖ B.P.

Heart ⊖ C.V.A. ⊖

Allergies ⊖

Cancer ⊖ Epilepsy ⊖

Endocrine & Others ⊖

## Physical Examination

**General :** Build *mod* Height *152 cm* Weight *53 kg* Clubbing  
Anaemia  Icterus  Cyanosis   
Oedema  Glands

**HENT :**

**CVS :** Heart Rate & Rhythm *82/min*  
B.P. : Supine *120/70 mmHg* Sitting *130/70 mmHg* Standing *130/70 mmHg*  
Chest shape  
Heart Sounds *S1 S2*   
Murmurs  
Thrills

**RS :** Rate & Type *NV BSS*   
Breath Sounds

**Abdomen :** Appearance *Normal*  
Liver  Spleen  Kidney  Colon   
Tenderness  
Bowel Sounds *BS*  Fluid *No free fluid*

## HYDROCELE & HERNIAL ORIFICES

**GYNEC** *1-2 days / 2-3 months no clots .*  
*4-5 pads / day .*

**CNS :** Cranial Nerves  
Sensory System  
Motor System  
Reflexes

**EYES AND FUNDUS** *Spectacles .*

**SKIN**

**EXTREMITIES**




Final Impression :

**MASTER HEALTH CHECK-UP**

Fit / Healthy .

ADVISED :

MEDICAL OFFICER

  
**Dr. GOKULAPRIYA R. NARIVAS**  
M.D. (O.G.), F.M.S.  
Reg. No. 28662  
CONSULTANT OBSTETRICIAN & GYNECOLOGIST  
SENTHIL MULTI SPECIALITY HOSPITAL  
No.547, Perundurai Road, ERODE - 11



# SMS DIAGNOSTIC CENTRE

## Senthil Multi Speciality Hospital

No. 547, Perundururai Road,  
Erode - 638 011  
Email: smshospitalerode@gmail.com

Phone : 0424 2260375 / 2260376 / 2260377  
Emergency Helpline : 88 830 55 555



Patient ID : 0200034450  
Patient Name : **MS. KIRTHIKA.S**  
Age /Sex : **29 Y/ F**  
Ref By : **HEALTH CHECKUP**  
Referred By : Dr.Dr.C.SENTHILVEL., M.D (Gen) .,D.M (Neuro)

SID No : **02107860**  
Collected Date : 10/02/2024 / 11:14  
Received Date : 10/02/2024 / 11:14  
Reported Date : 10/02/2024 / 14:27

### Final Test Report

Specimen	Test Name (Method)	Result	Flag	Units	Reference Value
<b>BIOCHEMISTRY</b>					
<b>RENAL FUNCTION TEST-INSURANCE (RFT)</b>					
Serum	<b>UREA</b> ( Urease/GLDH )	16.9		mg/dl	Adult less than (65 y) <50
Serum	<b>BLOOD UREA NITROGEN (BUN)</b> ( Urease -GLDH /End Point )	7.8		mg/dl	9.5 - 20
<b>Interpretation :</b>					
Serum	<b>CREATININE</b> ( Jaffe's Kinetic )	0.72		mg/dl	Female : 0.60-1.2
Serum	<b>BUN/CREATININE RATIO</b>	10.8		Ratio	12.1 - 20.1
Serum	<b>URIC ACID</b> ( Uricase / Bichromatic end Point )	4.0		mg/dl	Female: <7.0 Male: <7.0 Male:(>65Y)<8.4
<b>Interpretation :</b>					
<b>HAEMATOLOGY</b>					
<b>COMPLETE BLOOD COUNT (CBC)</b>					
EDTA	<b>TOTAL WBC COUNT.</b> ( Electrical Impedance )	6160		Cells / Cumm	4000 to 11000
<b>DIFFERENTIAL COUNT</b>					
EDTA	<b>Polymorphs</b>	56.7		%	40.0 - 65.0
EDTA	<b>Lymphocytes</b>	37.6		%	20.0 - 45.0
EDTA	<b>Eosinophils</b>	2.0		%	1.0 - 6.0
EDTA	<b>Monocyte</b>	3.0		%	2.0 - 8.0
EDTA	<b>Basophils</b>	0.7		%	0.0 - 1.0
EDTA	<b>HAEMOGLOBIN (Hb)</b>	12.2		g/dL	12 - 16
EDTA	<b>PCV (HCT)</b>	37.2		%	Female 37 - 47

<b>Biochemistry &amp; Molecular Biology</b> Mr K.Kamalasekaran M.Sc (UK) Dr S.Sowmya PhD   Mr B.Baskar MSc	<b>Microbiology</b> Dr M. Banumathy MD Mr S.Soundarapandian M.Sc	<b>Pathology</b> Dr S.Aravinth MD
--	--	--------------------------------------

Powered By	<b>CISTRON</b> BIOLOGICAL LABORATORY	Disclaimer: Isolated Laboratory Investigations are never conclusive. But should be used along with the other clinical examinations and related investigations to confirm the final diagnosis. The result of a laboratory investigation is dependent on the methodology used and sample received. <b>WE WISH YOU A HEALTHY LIFE</b>
cistronlabs@gmail.com   www.cistronlabs.com		





# SMS DIAGNOSTIC CENTRE

## Senthil Multi Speciality Hospital

No. 547, Perundururai Road,  
Erode - 638 011  
Email: smshospitalerode@gmail.com

Phone : 0424 2260375 / 2260376 / 2260377  
Emergency Helpline : 88 830 55 555



Patient ID : 0200034450  
Patient Name : **MS. KIRTHIKA.S**  
Age /Sex : **29 Y/ F**  
Ref By : **HEALTH CHECKUP**  
Referred By : Dr.Dr.C.SENTHILVEL., M.D (Gen) .,D.M (Neuro)

SID No : **02107860**  
Collected Date : 10/02/2024 / 11:14  
Received Date : 10/02/2024 / 11:14  
Reported Date : 10/02/2024 / 14:27

### Final Test Report

Specimen	Test Name (Method)	Result	Flag	Units	Reference Value
EDTA	RBC COUNT	4.27		millions / cumm	Female: 3.8 - 4.8
EDTA	MCV	87.1		fl	76 - 96
EDTA	MCH	28.5		pg	27 - 31
EDTA	MCHC	32.7		%	30 - 35
EDTA	PLATELET COUNT	3.16		Lakhs / Cumm	1.5 - 4.0
EDTA	MPV (Electrical Impedance)	8		fl	6 - 10
cit.Blood	ESR ( 30 mins /1 hr ) ( Westergren's )	10		mm/hr	Male <50 Years: 0 - 15 > 50 Years :0 - 20 Female <50 Years: 0 - 20 >50 Years : 0 - 30

### BLOOD GROUPING & RH TYPING

EDTA	Blood Group	"B"
EDTA	RH Typing	NEGATIVE

### BIOCHEMISTRY

Plasma	BLOOD GLUCOSE (Fasting) ( GOD/POD )	92.5	mg/dl	70 - 110
Plasma	BLOOD GLUCOSE (Post Prandial) ( GOD/POD )	102.0	mg/dl	80-140
	HbA1C			



#### Biochemistry & Molecular Biology

Mr K.Kamalasekaran M.Sc (UK)

Dr S.Sowmya PhD | Mr B.Baskar MSc

#### Microbiology

Dr M. Banumathy MD

Mr S.Soundarapandian M.Sc

#### Pathology

Dr S.Aravinth MD

Powered By



**CISTRON**  
BIOLOGICAL LABORATORY

Disclaimer:

Isolated Laboratory Investigations are never conclusive. But should be used along with the other clinical examinations and related investigations to confirm the final diagnosis. The result of a laboratory investigation is dependent on the methodology used and sample received. **WE WISH YOU A HEALTHY LIFE**

cistronlabs@gmail.com www.cistronlabs.com



# SMS DIAGNOSTIC CENTRE

## Senthil Multi Speciality Hospital

No. 547, Perundururai Road,  
Erode - 638 011  
Email: smshospitalerode@gmail.com

Phone : 0424 2260375 / 2260376 / 2260377  
Emergency Helpline : 88 830 55 555



Patient ID : 0200034450  
Patient Name : **MS. KIRTHIKA.S**  
Age /Sex : **29 Y/ F**  
Ref By : **HEALTH CHECKUP**  
Referred By : Dr.Dr.C.SENTHILVEL., M.D (Gen) .,D.M (Neuro)


SID No : **02107860**  
Collected Date : 10/02/2024 / 11:14  
Received Date : 10/02/2024 / 11:14  
Reported Date : 10/02/2024 / 14:27

### Final Test Report


Specimen	Test Name (Method)	Result	Flag	Units	Reference Value
EDTA	<b>Glycosylated Haemoglobin (HbA1c)</b>	5.0		%	Non Diabetic : Less than 6 % Diabetic Range : Good Control - 6.1 - 7.0 % Fair Control - 7.1 - 8.0 % Unsatisfactory Control - 8.1 - 10 % Poor Control : Above 10 % Method:HPLC

**Notes** : HBA1C is an Index of Your Blood Glucose control for the past three Months.

EDTA **Estimated Average Glucose (eAG)** 96.8 mg/dl

  
Verified By  
Mr. B.Baskar  
Lab Incharge



  
Dr. S. Aravindh.,M.D (Path)  
Consultant Pathologist



**Biochemistry & Molecular Biology**

Mr K.Kamalasekaran M.Sc (UK)

Dr S.Sowmya PhD | Mr B.Baskar MSc

**Microbiology**

Dr M. Banumathy MD

Mr S.Soundarapandian M.Sc

**Pathology**

Dr S.Aravindh MD

Powered By



**CISTRON**  
BIOLOGICAL LABORATORY

Disclaimer:

Isolated Laboratory Investigations are never conclusive. But should be used along with the other clinical examinations and related investigations to confirm the final diagnosis. The result of a laboratory investigation is dependent on the methodology used and sample received. **WE WISH YOU A HEALTHY LIFE**

cistronlabs@gmail.com www.cistronlabs.com



# SMS DIAGNOSTIC CENTRE

## Senthil Multi Speciality Hospital

No. 547, Perundurai Road,  
Erode - 638 011  
Email: smshospitalerode@gmail.com

Phone : 0424 2260375 / 2260376 / 2260377  
Emergency Helpline : 88 830 55 555



Patient ID : 0200034450

Patient Name : **MS. KIRTHIKA.S**

Age /Sex : **29 Y/ F**

Ref By : **HEALTH CHECKUP**

Referred By : Dr.Dr.C.SENTHILVEL., M.D (Gen) .,D.M (Neuro)

SID No : **02107860**

Collected Date : 10/02/2024 / 11:14

Received Date : 10/02/2024 / 11:14

Reported Date : 10/02/2024 / 14:27

**Final Test Report**

Specimen	Test Name (Method)	Result	Flag	Units	Reference Value
<b>BIOCHEMISTRY</b>					
<b>LIPID PROFILE</b>					
Serum	<b>TOTAL CHOLESTEROL</b> ( Oxidase-Peroxidase )	200.0		mg/dl	Less Than 220
<b>Interpretation :</b>					
Serum	<b>TRIGLYCERIDES (TGL)</b> ( GPO- Bichromatic end Point )	115.6		mg/dl	Less Than 150
<b>Interpretation :</b>					
Serum	<b>HDL CHOLESTEROL</b> ( Enzymatic )	49.7		mg/dl	NCEP guidelines (Coronary heart disease risk) < 40 : High Risk 40 - 60 : Normal Risk >= 60 : Low Risk
Serum	<b>LDL - CHOLESTEROL</b> ( Calculated )	127.2		mg/dl	Less Than 170
<b>Interpretation :</b>					
Serum	<b>VLDL CHOLESTEROL</b> ( Calculated )	23.1		mg/dl	Less than 46
Serum	<b>NON HDL CHOLESTEROL</b> ( Calculated )	<b>150.3</b>	H	mg/dl	< 130
Serum	<b>TOTAL CHOL/HDL CHOL. RATIO</b> ( Calculated )	4			Less than 4.5



**Biochemistry & Molecular Biology**

Mr K.Kamalasekaran M.Sc (UK)

Dr S.Sowmya PhD | Mr B.Baskar MSc

**Microbiology**

Dr M. Banumathy MD

Mr S.Soundarapandian M.Sc

**Pathology**

Dr S.Aravinth MD

Powered By



**CISTRON**  
BIOLOGICAL LABORATORY

Disclaimer:

Isolated Laboratory Investigations are never conclusive. But should be used along with the other clinical examinations and related investigations to confirm the final diagnosis. The result of a laboratory investigation is dependent on the methodology used and sample received.

**WE WISH YOU A HEALTHY LIFE**

[cistronlabs@gmail.com](mailto:cistronlabs@gmail.com)

[www.cistronlabs.com](http://www.cistronlabs.com)



# SMS DIAGNOSTIC CENTRE

## Senthil Multi Speciality Hospital

No. 547, Perundurair Road,  
Erode - 638 011  
Email: smshospitalerode@gmail.com

Phone : 0424 2260375 / 2260376 / 2260377  
Emergency Helpline : 88 830 55 555



Patient ID : 0200034450

Patient Name : **MS. KIRTHIKA.S**

Age /Sex : **29 Y/ F**

Ref By : **HEALTH CHECKUP**

Referred By : Dr.Dr.C.SENTHILVEL., M.D (Gen) .,D.M (Neuro)

SID No : **02107860**

Collected Date : 10/02/2024 / 11:14

Received Date : 10/02/2024 / 11:14

Reported Date : 10/02/2024 / 14:27

**Final Test Report**


Specimen	Test Name (Method)	Result	Flag	Units	Reference Value
	LDL/HDL Ratio	2.6			2.5 - 3.5

Verified By  
Mr. B.Baskar  
Lab Incharge



*S. Aravinth.*

Dr. S. Aravinth.,M.D (Path)  
Consultant Pathologist



<b>Biochemistry &amp; Molecular Biology</b> Mr K.Kamalasekaran M.Sc (UK) Dr S.Sowmya PhD   Mr B.Baskar MSc	<b>Microbiology</b> Dr M. Banumathy MD Mr S.Soundarapandian M.Sc	<b>Pathology</b> Dr S.Aravinth MD
--	--	--------------------------------------

Powered By **CISTRON BIOLOGICAL LABORATORY**

Disclaimer: Isolated Laboratory Investigations are never conclusive. But should be used along with the other clinical examinations and related investigations to confirm the final diagnosis. The result of a laboratory investigation is dependent on the methodology used and sample received. **WE WISH YOU A HEALTHY LIFE** ✉ cistronlabs@gmail.com 🌐 www.cistronlabs.com



**SMS DIAGNOSTIC CENTRE**  
**Senthil Multi Speciality Hospital**

No. 547, Perundururai Road,  
 Erode - 638 011  
 Email: smshospitalerode@gmail.com

Phone : 0424 2260375 / 2260376 / 2260377  
 Emergency Helpline : 88 830 55 555



Patient ID : 0200034450  
 Patient Name : **MS. KIRTHIKA.S**  
 Age /Sex : **29 Y/ F**  
 Ref By : **HEALTH CHECKUP**  
 Referred By : Dr.Dr.C.SENTHILVEL., M.D (Gen) .,D.M (Neuro)

SID No : **02107860**  
 Collected Date : 10/02/2024 / 11:14  
 Received Date : 10/02/2024 / 11:14  
 Reported Date : 10/02/2024 / 14:27

**Final Test Report**

Specimen	Test Name (Method)	Result	Flag	Units	Reference Value
<b>BIOCHEMISTRY</b>					
<b>LIVER FUNCTION TEST (LFT)</b>					
Serum	<b>BILIRUBIN ( TOTAL )</b> ( Diazo )	0.36		mg/dl	Adults & children up to 1.0
Serum	<b>BILIRUBIN (DIRECT)</b> ( Diazo )	0.24		mg/dl	0.2 - 0.4
<b>Interpretation :</b>					
Serum	<b>BILIRUBIN (INDIRECT)</b> ( Calculated )	<b>0.12</b>	<b>L</b>	mg/dl	0.2 - 1.0
<b>TOTAL PROTEIN &amp; A/G RATIO</b>					
Serum	<b>TOTAL PROTEIN</b> ( Biuret / End Point )	6.7		gm/dl	6.6-8.7
<b>Interpretation :</b>					
Serum	<b>ALBUMIN</b> ( Bromcresol Green(BCG) )	3.8		gm/dl	Adults 3.4-4.8
Serum	<b>GLOBULIN</b> ( Calculated )	<b>2.9</b>	<b>L</b>	g/dL	Adults 3.0 - 3.5
Serum	<b>A/G Ratio</b>	1.31			1.2 -1.5
<b>Interpretation :</b>					
Serum	<b>SGOT (AST)</b> ( Modified With out P-5-P )	18		U/L	Female : up to 32
Serum	<b>SGPT (ALT)</b> ( Modified With out P-5-P )	24		U/L	Females: up to 31
Serum	<b>ALKALINE PHOSPHATASE</b> ( p-NPP- (AMP Buffer) )	57		U/L	42 - 98
Serum	<b>GAMMA GT</b> ( IFCC )	23.0		U/L	Male :10 - 50 Female :7 - 35
<b>Interpretation :</b>					
Urine	<b>URINE SUGAR (PP)</b> ( Urstick Method )	Nil			



<b>Biochemistry &amp; Molecular Biology</b> Mr K.Kamalasekaran M.Sc (UK) Dr S.Sowmya PhD   Mr B.Baskar MSc	<b>Microbiology</b> Dr M. Banumathy MD Mr S.Soundarapandian M.Sc	<b>Pathology</b> Dr S.Aravinth MD
--	--	--------------------------------------



# SMS DIAGNOSTIC CENTRE

## Senthil Multi Speciality Hospital

No. 547, Perundururai Road,  
Erode - 638 011  
Email: smshospitalerode@gmail.com

Phone : 0424 2260375 / 2260376 / 2260377  
Emergency Helpline : 88 830 55 555



Patient ID : 0200034450  
Patient Name : **MS. KIRTHIKA.S**  
Age /Sex : **29 Y/ F**  
Ref By : **HEALTH CHECKUP**  
Referred By : Dr.Dr.C.SENTHILVEL., M.D (Gen) .,D.M (Neuro)

SID No : **02107860**  
Collected Date : 10/02/2024 / 11:14  
Received Date : 10/02/2024 / 11:14  
Reported Date : 10/02/2024 / 14:27  
**Final Test Report**

Specimen	Test Name (Method)	Result	Flag	Units	Reference Value
<b>IMMUNOLOGY</b>					
<b>THYROID FUNCTION TEST (FREE)</b>					
Serum	<b>FT3</b> ( ECLIA )	3.69		pg/ml	Adults:2.0 - 4.4
Serum	<b>FT4</b> ( ECLIA )	1.13		ng/dL	Adults:0.70 - 2.00
Serum	<b>TSH (Thyroid Stimulating Hormone)</b> ( ECLIA )	1.330		µIU/ml	Adult-0.35-5.5
<b>CLINICAL PATHOLOGY</b>					
<b>URINE ROUTINE ANALYSIS</b>					
Urine	<b>Color</b>	Straw Yellow			Pale yellow
Urine	<b>Appearance</b>	Slightly Turbid			Clear
Urine	<b>Sp.Gravity</b>	1.020			1.010 - 1.025
Urine	<b>pH</b>	5.5			5.0 - 8.0
Urine	<b>Proteins</b>	Nil			Nil
Urine	<b>Sugar (F/ R/ PP)</b>	Nil			Nil
<b><u>MICROSCOPY</u></b>					
Urine	<b>Pus Cells</b>	3 - 5			0 - 5 /hpf
Urine	<b>Epithelial Cells</b>	1 - 2			0 - 5 /hpf
Urine	<b>RBC's</b>	Nil			Nil
Urine	<b>Casts</b>	Nil			Nil
Urine	<b>Crystals</b>	Nil			Nil



<b>Biochemistry &amp; Molecular Biology</b> Mr K.Kamalasekaran M.Sc (UK) Dr S.Sowmya PhD   Mr B.Baskar MSc	<b>Microbiology</b> Dr M. Banumathy MD Mr S.Soundarapandian M.Sc	<b>Pathology</b> Dr S.Aravinth MD
--	--	--------------------------------------



# SMS DIAGNOSTIC CENTRE

## Senthil Multi Speciality Hospital

No. 547, Perundururai Road,  
Erode - 638 011  
Email: smshospitalerode@gmail.com

Phone : 0424 2260375 / 2260376 / 2260377  
Emergency Helpline : 88 830 55 555



Patient ID : 0200034450

Patient Name : **MS. KIRTHIKA.S**

Age /Sex : **29 Y/ F**

Ref By : **HEALTH CHECKUP**

Referred By : Dr.Dr.C.SENTHILVEL., M.D (Gen) .,D.M (Neuro)

SID No : **02107860**

Collected Date : 10/02/2024 / 11:14


Received Date : 10/02/2024 / 11:14

Reported Date : 10/02/2024 / 14:27

Final Test Report

Specimen	Test Name (Method)	Result	Flag	Units	Reference Value
Urine	Others	Nil			Nil

End Of Report

  
Verified By  
Mr. B.Baskar  
Lab Incharge



  
Dr. S. Aravindh.,M.D (Path)  
Consultant Pathologist

Biochemistry & Molecular Biology

Mr K.Kamalasekaran M.Sc (UK)

Dr S.Sowmya PhD | Mr B.Baskar MSc

Microbiology

Dr M. Banumathy MD

Mr S.Soundarapandian M.Sc

Pathology

Dr S.Aravindh MD

Powered By



**CISTRON**  
BIOLOGICAL LABORATORY

Disclaimer:

Isolated Laboratory Investigations are never conclusive. But should be used along with the other clinical examinations and related investigations to confirm the final diagnosis. The result of a laboratory investigation is dependent on the methodology used and sample received. **WE WISH YOU A HEALTHY LIFE**

cistronlabs@gmail.com

www.cistronlabs.com



# SMS SCANS

- 3D ULTRASOUND SCAN
- ECHO CARDIOGRAPHY

- COLOUR DOPPLER
- TRANSCRANIAL DOPPLER



NAME: MISS. KIRTHIKA

AGE: 29 YRS

SEX: FEMALE,

DATE: 10.02.2024

REF BY: DR. C. SENTHILVEL M.D.,DM (Neuro).

## ULTRASOUND ABDOMEN AND PELVIS

Liver : Size is normal. Echogenecity Normal.  
Intrahepatic biliary radicles normal.  
CBD and portal vein normal.

Gall bladder : Distended. Wall normal. No calculus.

Pancreas : Head, neck, body and tail appears normal.

Spleen : Size is normal Echogenecity normal.

Aorta and IVC : Normal.

Right kidney : Size normal. Cortical echoes normal.  
Corticomedullary differentiation maintained.  
Pelvicalyceal system normal. No calculus

Left kidney : Size normal. Cortical echoes normal.  
Corticomedullary differentiation maintained.  
Pelvicalyceal system Normal .No calculus

Urinary bladder : Distended. Wall regular.

Uterus : Normal in size and echotexture.ET 5mm

Ovaries : Both the ovaries are enlarged and polycystic in nature .No dominant follicle

Right ovary :4.2 x 2.4 cms ;Left Ovary 4.0x 2.1 cms

## IMPRESSION:

➤ B/L POLYCYSTIC OVARIES



  
DR.R.TAMILANBAN MBBS.,DNB(Rad),  
Consultant Radiologist



**SENTHIL MULTI SPECIALITY HOSPITAL**

547, PERUNDURAI ROAD, ERODE -638 011.

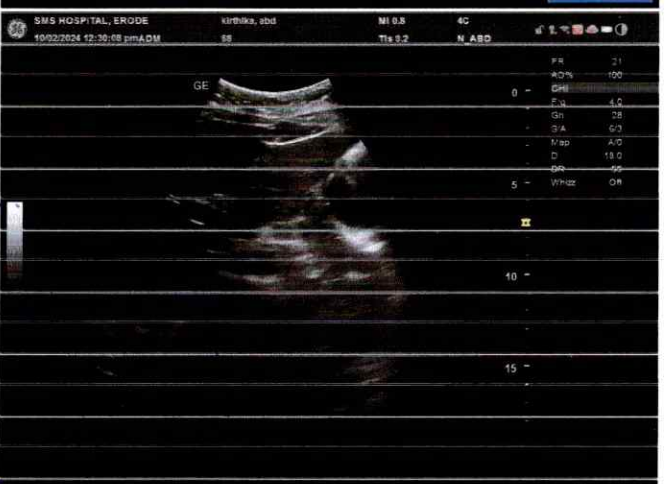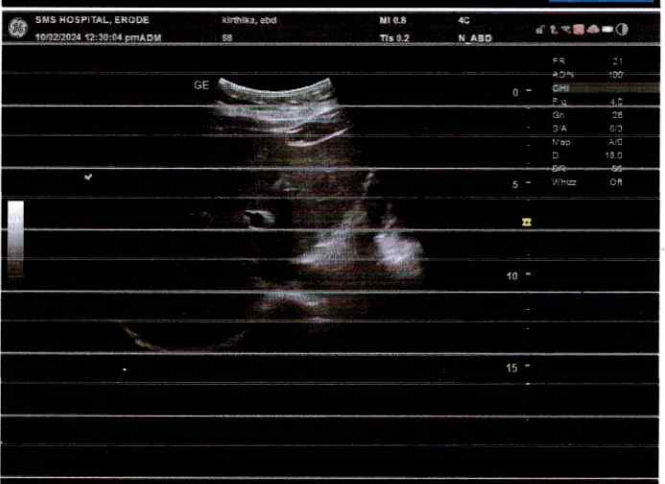
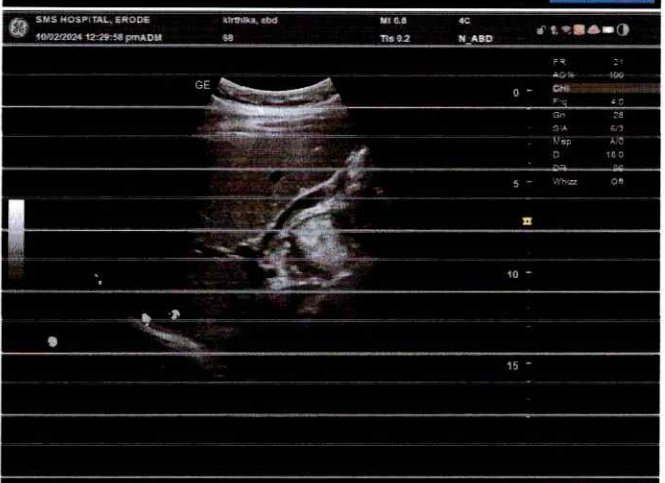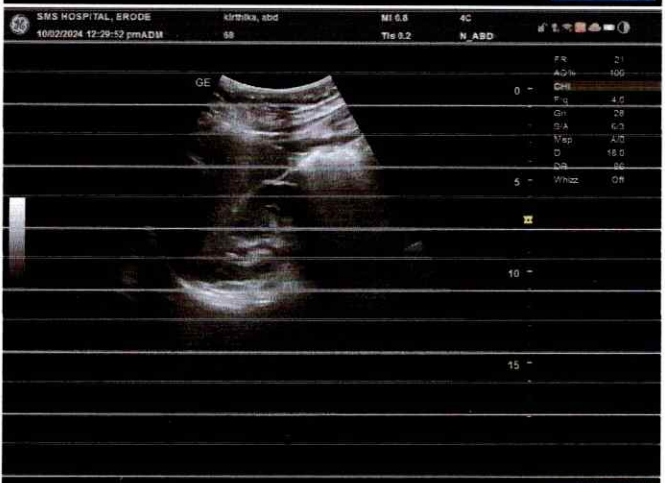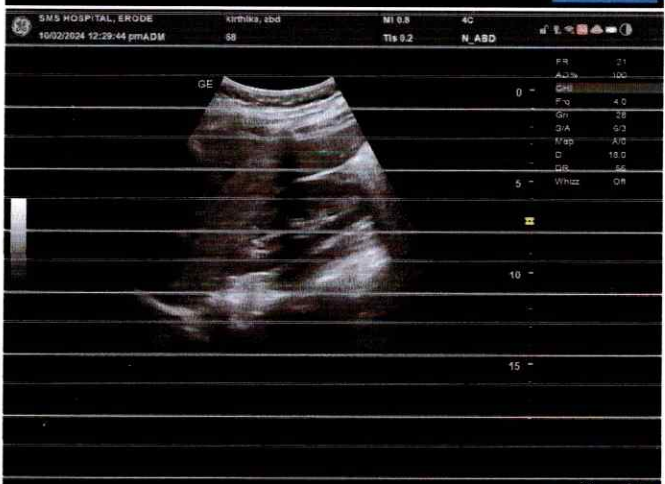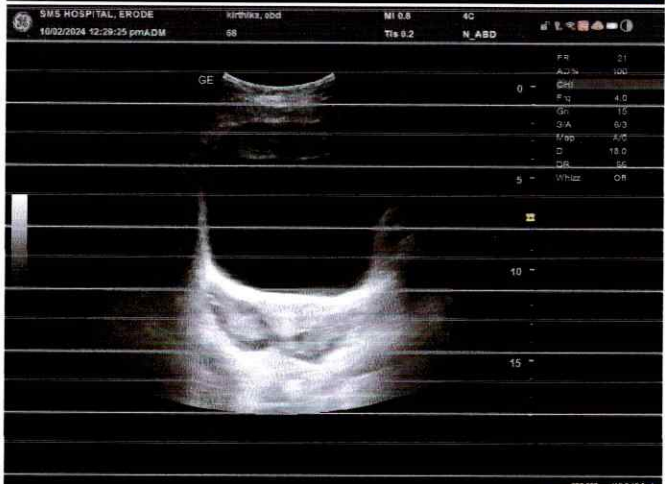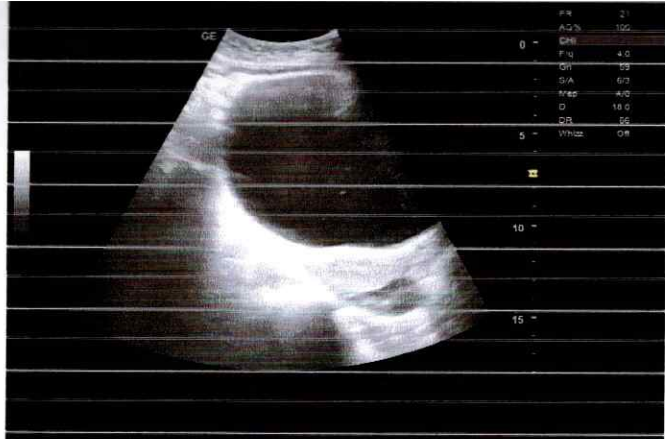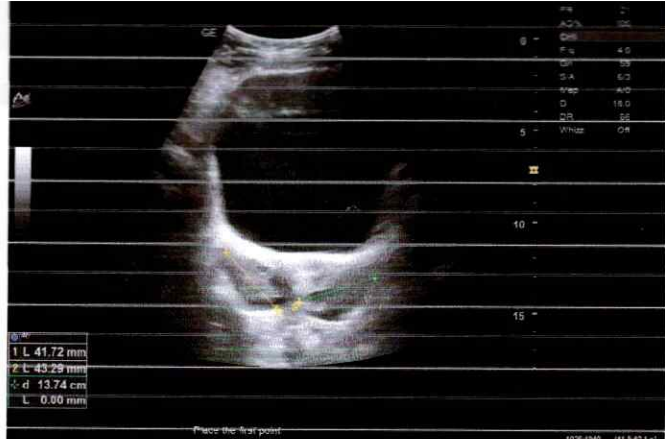© 0424 -2260375, 2260376, 2260377, Fax: 0424 -2260374

EMERGENCY AMBULANCE SERVICE 98432 55055

Healing With A Humane Touch









# SMS SCANS

• 3D ULTRASOUND SCAN  
• ECHO CARDIOGRAPHY

• COLOUR DOPPLER  
• TRANSCRANIAL DOPPLER



**NAME: MISS. KIRTHIKA**

**AGE: 29 YRS**

**SEX: FEMALE**

**DATE : 10.02.2024**

**REF BY: DR. C. SENTHILVEL M.D.,DM (Neuro).**

## ***ECHO CARDIOGRAPHY REPORT***

**Left ventricle:** Normal in size and function. EF – 64 %. No regional wall motion abnormality. No LV hypertrophy.

**Right ventricle :** Normal in size and function .

**Inter ventricular septum :** Intact

**Left atrium:** Normal.

**Right atrium:** Normal.

**Interatrial septum :** Intact

**Mitral valve :** Normal leaflet motion . No MS / No MR .

**Aortic valve :** Normal leaflet motion . No AS/ No AR

**Tricuspid valve :** Normal leaflet motion. No TR

**Pulmonary valve :** Normal .

**Ascending aorta and arch:** Normal

**IVC:**1.2 cm, 30 % inspiratory collapse.

**Pericardium :** No pericardial effusion



**SENTHIL MULTI SPECIALITY HOSPITAL**

547, PERUNDURAI ROAD, ERODE -638 011.

© 0424 -2260375, 2260376, 2260377, Fax: 0424-2260374

EMERGENCY AMBULANCE SERVICE 98432 55055

Healing With A Humane Touch




**IMPRESSION :**

NO REGIONAL WALL MOTION ABNORMALITY

NORMAL LV SYSTOLIC FUNCTION

NORMAL LV DIASTOLIC FUNCTION

NO PULMONARY HYPERTENSION



**DR. ANANDHAKUMAR, MBBS, MD, DNB[CARDIO]**

**Consultant Interventional Cardiologist**

**Dr. R. ANANDHAKUMAR**

MBBS.. MD.. (Gen.Med).. DNB (Cardiology)

**Interventional Cardiologist**

**Reg.No : 84943**

**Patient Information**

**Name:** KIRTHIKA, ECHO  
**Birthdate:**  
**Perf. Physician:**

**Patient Id:** DGTF  
**Sex:**  
**Ref. Physician:**

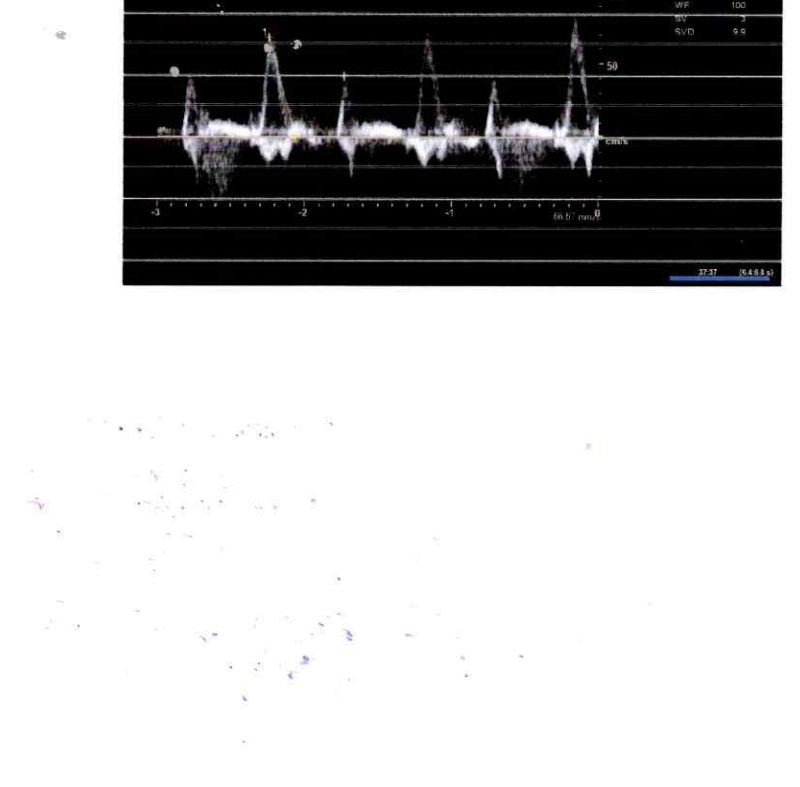
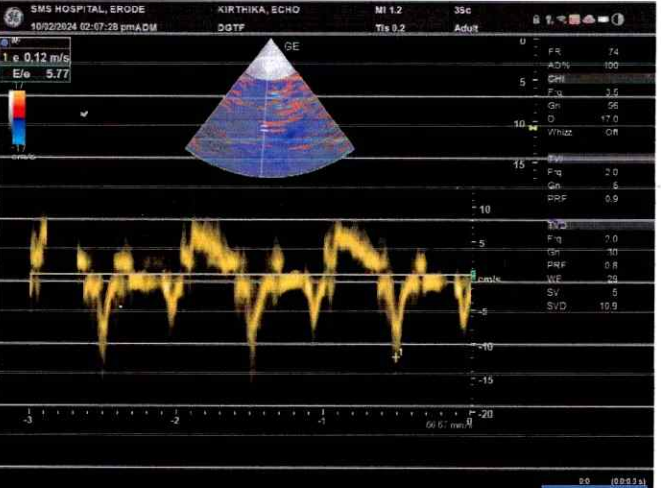
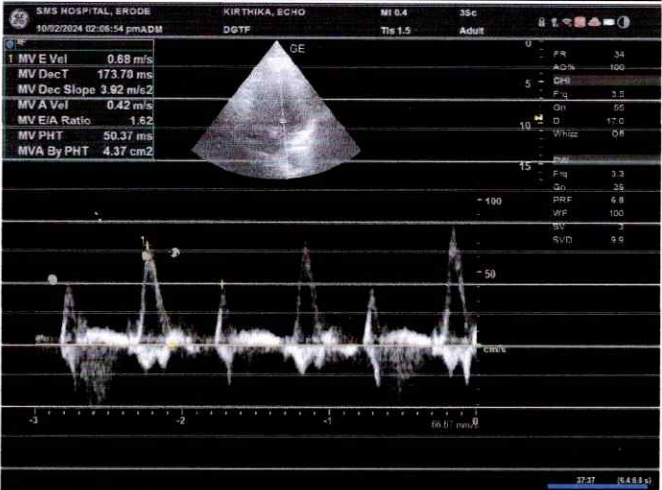
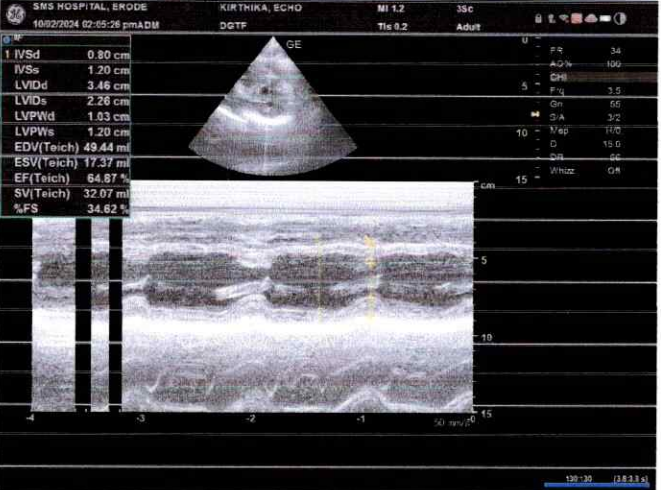
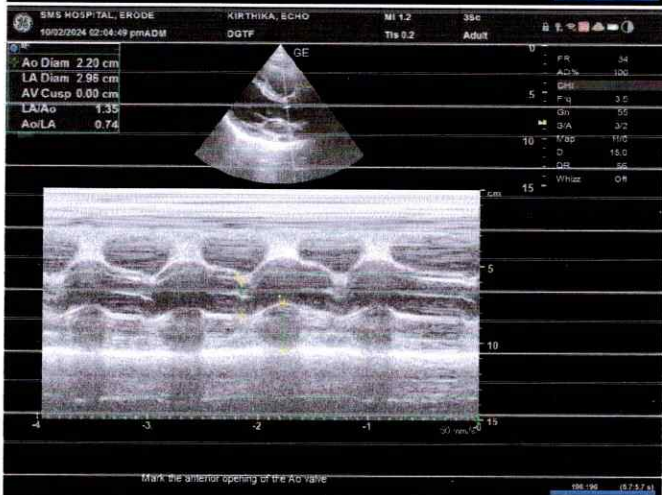
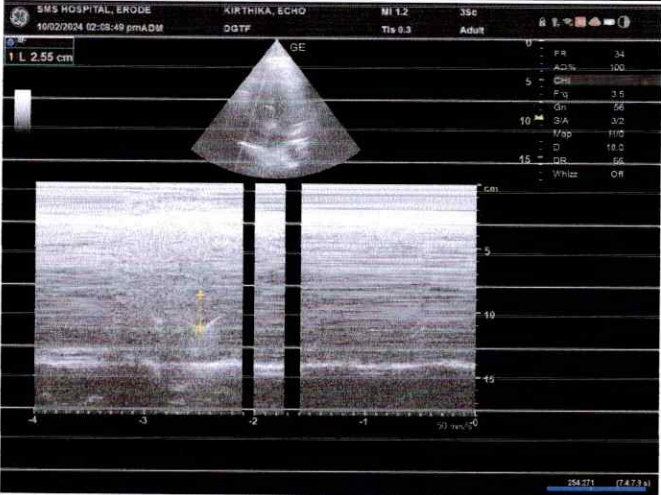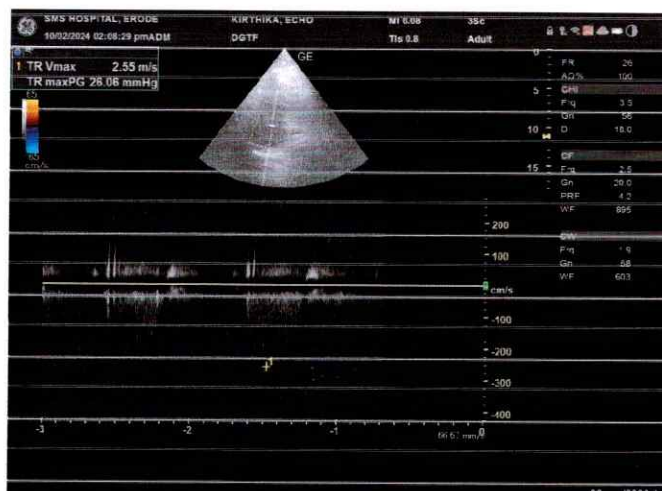
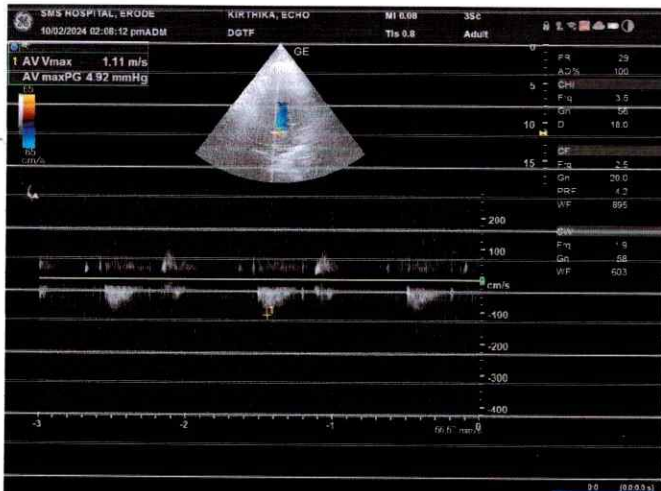
**Date:** 10/02/2024  
**Accession #:**  
**Operator:** ADM

**Measurements**

**2D**

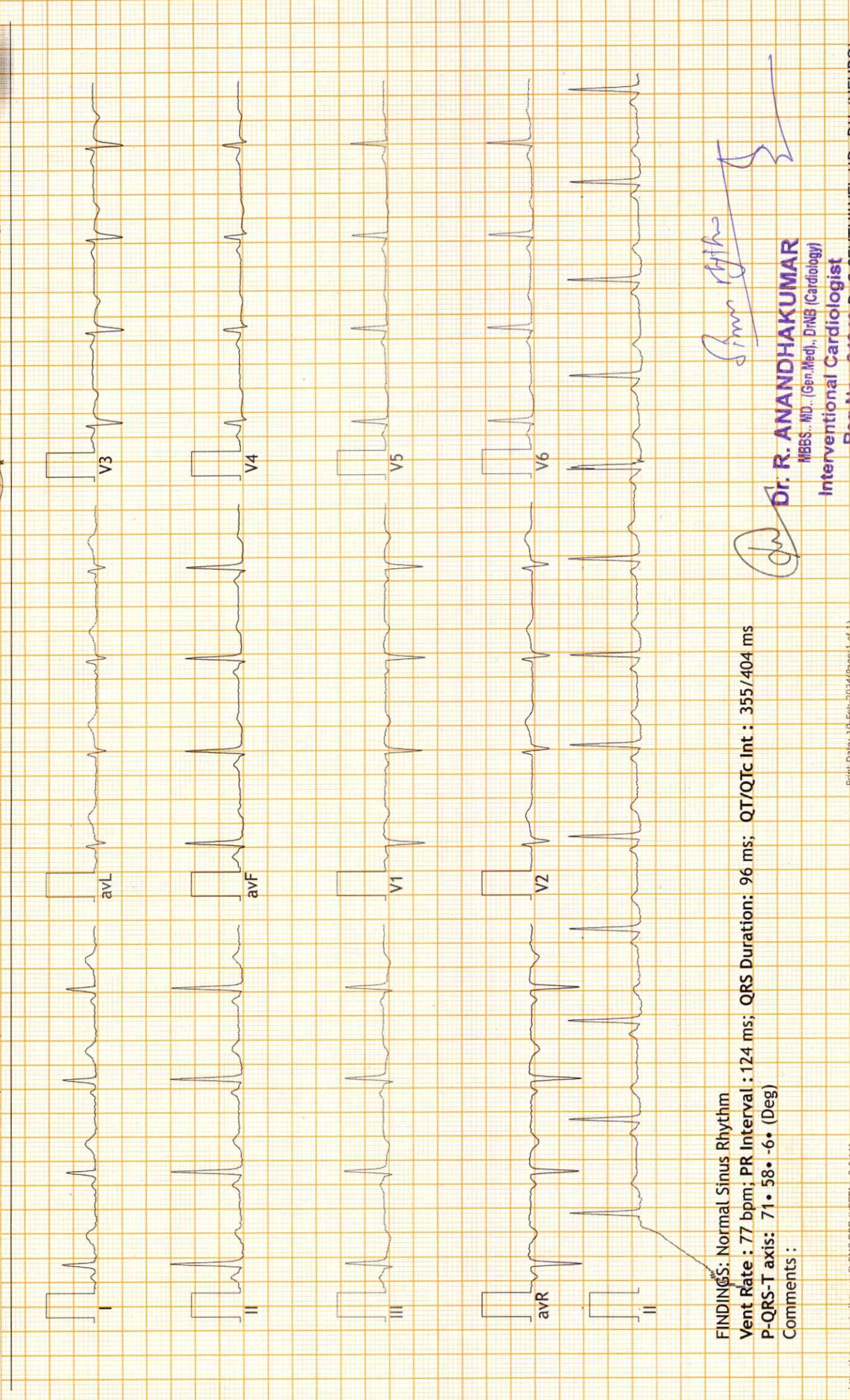
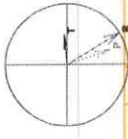**M-Mode & PW**

IVSd	0.80 cm
LVIDd	3.46 cm
LVPWd	1.03 cm
IVSs	1.20 cm
LVIDs	2.26 cm
LVPWs	1.20 cm
EDV(Teich)	49.44 ml
ESV(Teich)	17.37 ml
EF(Teich)	64.87 %
%FS	34.62 %
SV(Teich)	32.07 ml
MV E Vel	0.68 m/s
MV DecT	173.70 ms
MV Dec Slope	3.92 m/s <sup>2</sup>
MV A Vel	0.42 m/s
MV E/A Ratio	1.62
MV PHT	50.37 ms
MVA By PHT	4.37 cm <sup>2</sup>
e	0.12 m/s
E/e	5.77
AV Vmax	1.11 m/s
AV maxPG	4.92 mmHg
TR Vmax	2.55 m/s
TR maxPG	26.06 mmHg



315888 / Ms Kirthika 29Yrs-5Months/Female 53 Kgs/152 Cms BP: \_\_\_/\_\_\_ mmHg HR: 77 bpm  
Ref.: PRE EMPLOYEE Test Date: 10-Feb-2024(10:50:49) Notch: 50Hz 0.05Hz - 35Hz 10mm/mV 25mm/Sec

PR Interval: 124 ms  
QRS Duration: 96 ms  
QT/QTc: 355/404ms  
P-QRS-T Axis: 71 - 58 - -6 (Deg)



FINDINGS: Normal Sinus Rhythm  
Vent Rate : 77 bpm; PR Interval : 124 ms; QRS Duration: 96 ms; QT/QTc Int : 355/404 ms  
P-QRS-T axis: 71 • 58 • -6 • (Deg)  
Comments :

*Signature*

*Signature*

**Dr. R. ANANDHAKUMAR**  
MBBS., M.D., (Gen.Med), DrNB (Cardiology)  
Interventional Cardiologist  
Reg.No : 84943 Dr. C.SENTHILVEL MD, DM, (NEURO)ARTS



**SMS**

# SENTHIL MULTI SPECIALITY HOSPITAL

*Healing with a humane touch*

547, Perundurai Road, Erode - 638 011.  
E-Mail: smshospital\_erode@yahoo.co.in

Phone : (0424) 2260 375, 376, 377

Emergency Helpline: 88 830 55 555, 81 100 00 699



**PATIENT NAME** : MISS. KIRTHIKA  
**AGE** : 29 YRS / FEMALE  
**CHEST X-RAY** : PA View  
**DATE** : 10.02.2024

## X-RAY CHEST- REPORT

Trachea in mid line

Both Hilar regions normal.

CT Ratio normal

Both lung fields normal

Thoracic Bony cage normal

Soft tissue normal.

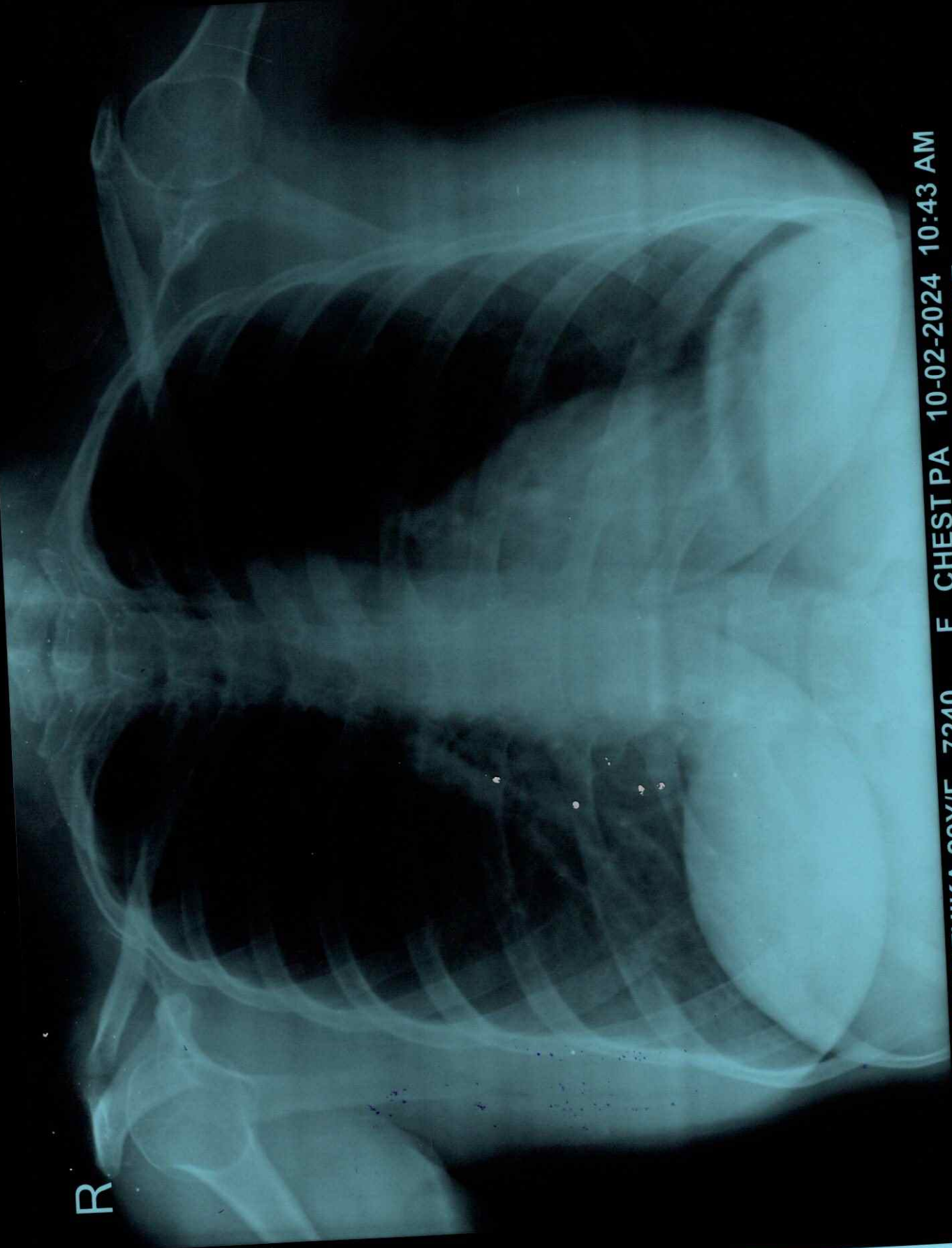
### IMPRESSION:

- ESSENTIALLY NORMAL STUDY .



  
DR. R.TAMILANBAN MBBS., DNB (Rad),  
Consultant Radiologist

R



MISS, KIRTHIKA 29Y/F 7240 F CHEST PA 10-02-2024 10:43 AM  
SENTHIL MULTISPECIALITY HOSPITAL, ERODE