

018699\_Hindi\_UP12\_402(Gen4\_0001)

आधार - आम आदमी का अधिकार

3155 4318 4755

नेहा बंसल  
Neha Bansal

जन्म वर्ष / Year of Birth : 1991  
महिला / Female

भारत सरकार  
GOVERNMENT OF INDIA

18

19

20

21

22

23

24

25

26

27

28

29

30

31

32

33

34

35

36

37

38

39

40

41

42

43

44

45

46

47

48

49

50

51

52

53

54

55

56

57

58

59

60

61

62

63

64

65

66

67

68

69

70

71

72

73

74

75

76

77

78

79

80

81

82

83

84

85

86

87

88

89

90

91

92

93

94

95

96

97

98

99

100

Dr. POOJA GARG  
M.B.B.S. - D.M.R.D  
Reg No. DMC/RD/33398  
Radiologist

ONEPLUS ULTIMOUND  
47, Harsh Vihar, Pitam Pura  
Delhi-110034  
Ph. 011-42480101, 953991305  
E-mail: oneplusul@gmail.com

भारतीय विशिष्ट पहचान प्राधिकरण  
UNIQUE IDENTIFICATION AUTHORITY OF INDIA

Address: D/O: Hansraj, House no. 3, old anaj mandi road, Opposite sushila bhawan street, Hisar, Hisar, Haryana, 125001

D/O: हंसराज, हाउस नं. 3, ओल्ड अनाज मंडी रोड, सुशीला भवन सड़क के सामने, हिसार, हरियाणा, 125001


P.O. Box No. 1947  
Bengaluru-560 001

www.uidai.gov.in

help@uidai.gov.in

1947  
1800 180 1947

*For actual purpose*



*[Handwritten signature]*

*[Handwritten signature]*  
DR. PUCHHARG  
M.E.S. D.M.R.D  
Reg No DMCR/03398  
Radiologist

ONEPLUS ULTRASOUND LAB  
47, Harsh Vihar, Pitam Pura,  
Delhi-110034  
Ph. 011-42480101, 9599913051  
E-mail: oneplusul@gmail.com



# ONEPLUS ULTRASOUND LAB

47, HARSH VIHAR, PITAMPURA, DELHI- 110034

Ms. NEHA BANSAL

Age : 31/F

Ref. by : MEDIWHEEL

Indication1 :

Indication2 :

Indication3 :

COMMENTS : Sinus Tachycardia

ID : 2122

HMM : 154/98

Recorded : 25-2-2023 12:15

Medication1 :

Medication2 :

Medication3 :

BPMM : 121

P Axis : 116/78 deg

QRS Axis : 69 deg

T Axis : 51 deg

deg : -98 deg

Unconfirmed Report Reviewed By:

Cardiologist

P duration : 96 msec

PR duration : 123 msec

QRS duration : 103 msec

QT interval : 256 msec

QTc interval : 362 msec

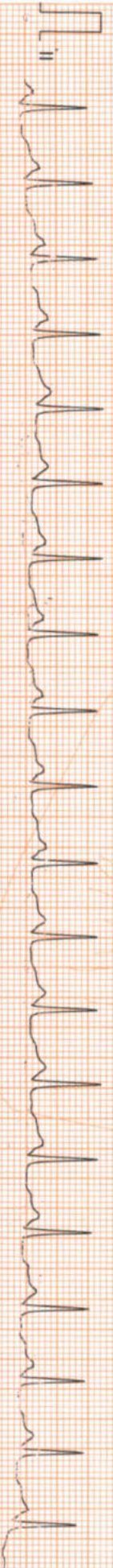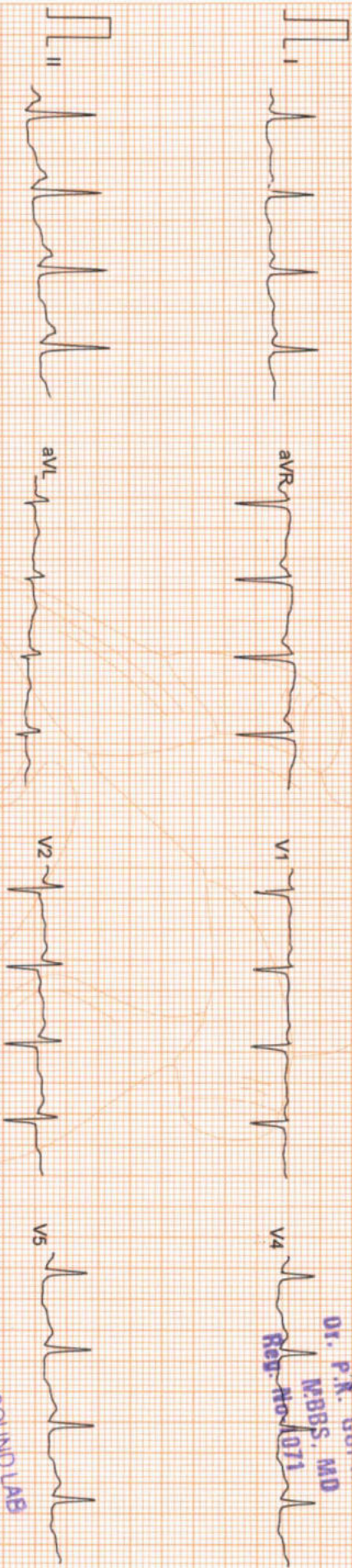
Raw E.C.G.(Seq)

WNL

Dr. P.K. Gupta

MBBS, MD

Reg. No. 1071



ONEPLUS ULTRASOUND LAB  
47, Harsh Vihar, Pitampura,  
Delhi-110034  
Ph: 011-42480101, 9539913051  
E-mail: oneplusul@gnmail.com

Filtered

25mm/sec 10mm/mV

CardiCom, INDIA



# ONEPLUS ULTRASOUND LAB

47, HARSH VIHAR PITAMPURA DELHI 110034

Ms. NEHA BANSAL

ID : 995

Age : 31/F  
H/Wt : 154/98  
Recorded : 25-2-2023 12:19

Ref. by : MEDIWHEEL  
Indication1 :  
Indication2 :  
Indication3 :

TREADMILL TEST SUMMARY REPORT  
Protocol: BRUCE  
History:  
Medication1 :  
Medication2 :  
Medication3 :

PHASE	PHASE TIME	STAGE TIME	SPEED (Km./Hr.)	GRADE (%)	H.R. (BPM)	B.P. (mmHg)	RPP X100	II	ST LEVEL (mm) V2	V5	METS
SUPINE											
STANDING					131	116/78	151	-0.7	0.0	-0.6	
STAGE 1	2:59	2:59	2.70	10.00	119	116/78	138	-0.9	-0.2	-0.6	
STAGE 2	5:59	2:59	4.00	12.00	139	116/78	161	-0.7	0.0	-0.5	4.80
STAGE 3	7:29	1:29	5.40	14.00	153	130/80	198	-0.8	0.0	-0.6	7.10
PEAK EXER	7:43	1:43			164	150/88	246	-0.6	0.3	-0.3	8.54
RECOVERY	2:59	2:59	0.00	0.00	166	150/88	249	-0.4	0.5	-0.1	
					134	120/80	160	-0.7	0.1	-0.5	8.77

## RESULTS

Exercise Duration : 7.43 Minutes  
Max Heart Rate : 166 bpm  
Max Blood Pressure : 150/88 mmHg  
Max Work Load : 8.77 METS  
Reason of Termination :

7.43 Minutes  
166 bpm 87 % of target heart rate 189 bpm  
150/88 mmHg  
8.77 METS

## IMPRESSIONS

Negative for inducible ischemia.

Dr. P.K. GUPTA  
MD  
Cardiologist

*[Signature]*

ONEPLUS ULTRASOUND LAB  
47, Harsh Vihar, Pitampura, Delhi-110034  
Ph: 011-43480101, 9555913131  
E-mail: oneplusul@gnj.com



# ONEPLUS ULTRASOUND LAB

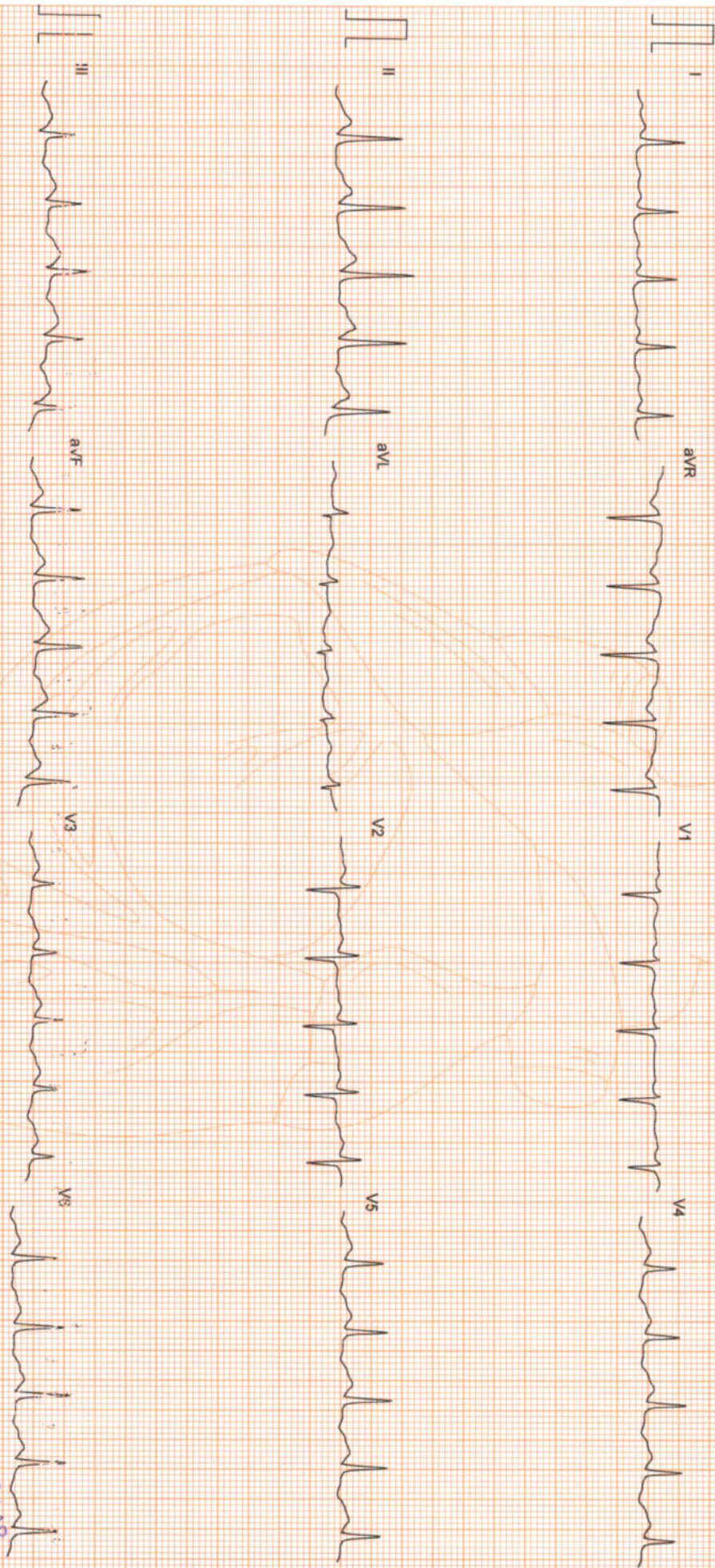
SUPINE  
PRETEST

ST @ 10mm/mV  
80ms PostJ

Ms. NEHA BANSAL  
I.D. : 995  
AGE/SEX : 31/F  
RECORDED : 25-2-2023 12:19

RATE : 131 BPM  
B.P. : 116/78 mmHg

RAW E.C.G.



Filtered

25mm/sec 10mm/mV

CardCom, INDIA Ph.-091-731-2620740, TeleFax:091-731-2431214

ONEPLUS ULTRASOUND LAB  
47, Marsh Vihar, Palm Pura,  
Delhi-110034  
Ph. 011-47488101, 9559913051  
Email: kmc@usul@grmhl.com



Ms. NEHA BANSAL

I.D. : 995

AGE/SEX : 31/F

RECORDED : 25-2-2023 12:19

RATE : 119 BPM

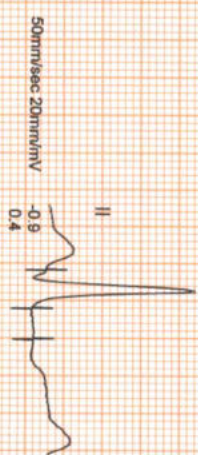
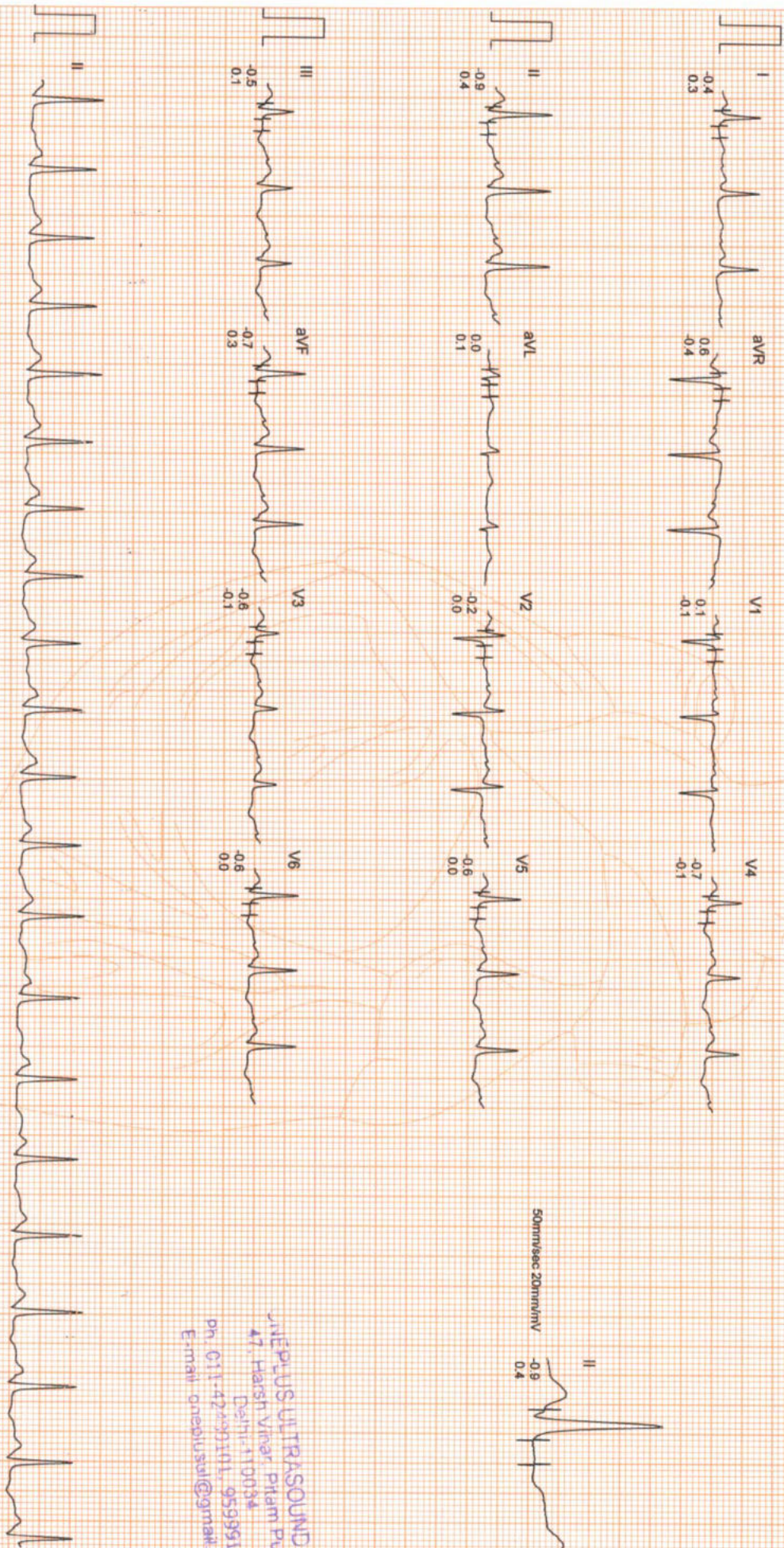
B.P. : 116/78 mmHg

# ONEPLUS ULTRASOUND LAB

STANDING  
PRETEST

ST @ 10mm/mV  
80ms PostJ

LINKED MEDIAN



ONEPLUS ULTRASOUND LAB  
 47, Harsh Vihar, Pitam Pura,  
 Delhi-110034  
 Ph: 011-42499211, 9599913051  
 E-mail: oneplusul@gmail.com

Filtered

Computer Corrected Baseline

25mm/sec 10mm/mV

CardiCom, INDIA Ph.: 091-731-2620740, TeleFax: 091-731-2431214



# ONEPLUS ULTRASOUND LAB

Ms. NEHA BANSAL

I.D. : 995

AGE/SEX : 31/F

RECORDED : 25-2-2023 12:19

RATE : 139 BPM

B.P. : 116/78 mmHg

BRUCE

EXERCISE 1

PHASE TIME : 2:59

STAGE TIME : 2:59

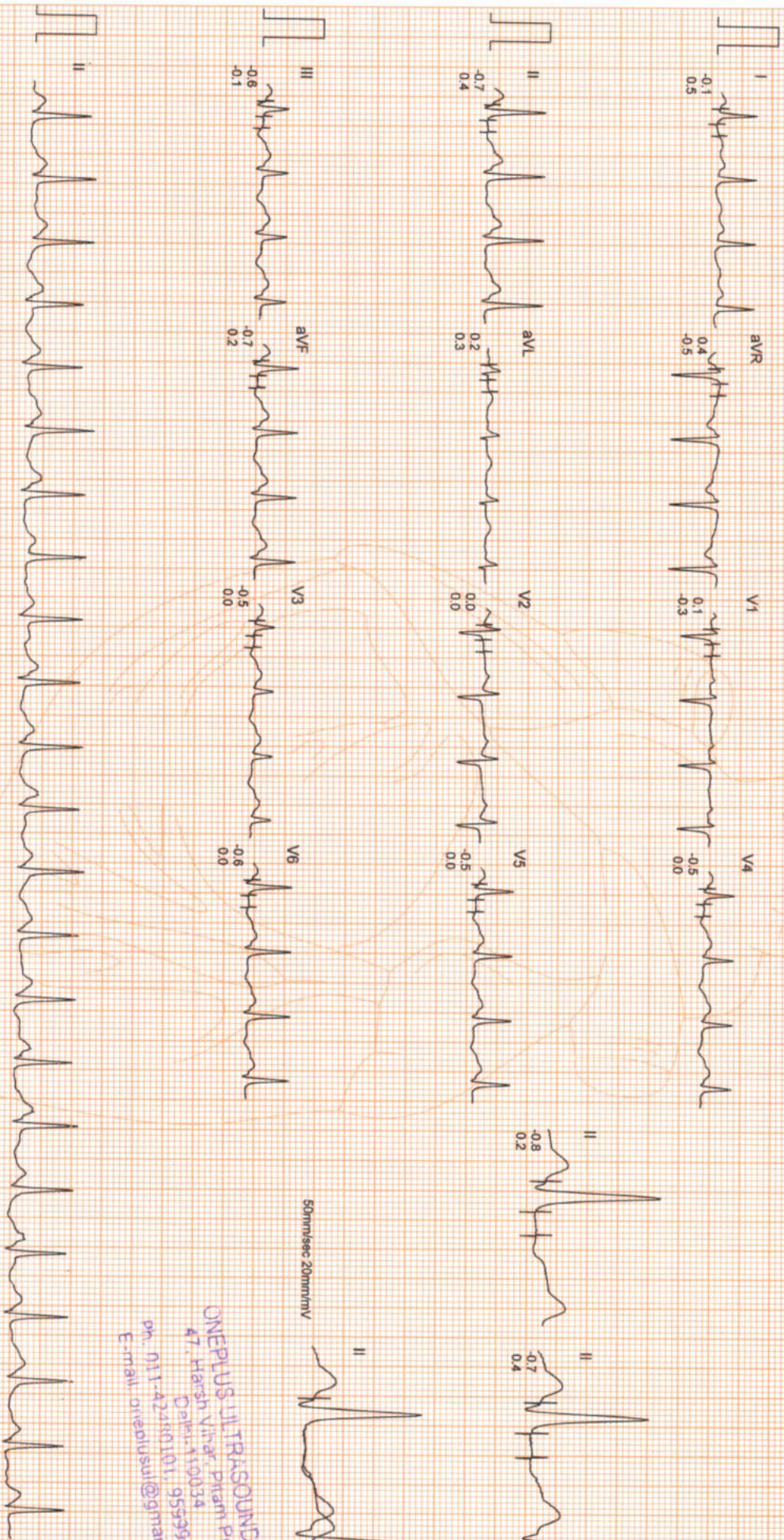
ST @ 10mm/mV

80ms PostJ

SPEED : 2.7 Km./hr.

GRADE : 10.0 %

LINKED MEDIAN



Filtered Computer Corrected Baseline

25mm/sec 10mm/mV

CardiCom, INDIA Ph.:091-731-2820740, TeleFax:091-731-2431214

ONEPLUS ULTRASOUND LAB  
47, Harsh Vihar Pitam Pura,  
Delhi-110034  
Ph. 011-42460101, 9539913051  
E-mail: oneplusul@gmail.com



# ONEPLUS ULTRASOUND LAB

Ms. NEHA BANSAL

I.D. : 995

AGE/SEX : 31/F

RECORDED : 25-2-2023 12:19

RATE : 153 BPM

B.P. : 130/80 mmHg

BRUCE

EXERCISE 2

PHASE TIME : 5:59

STAGE TIME : 2:59

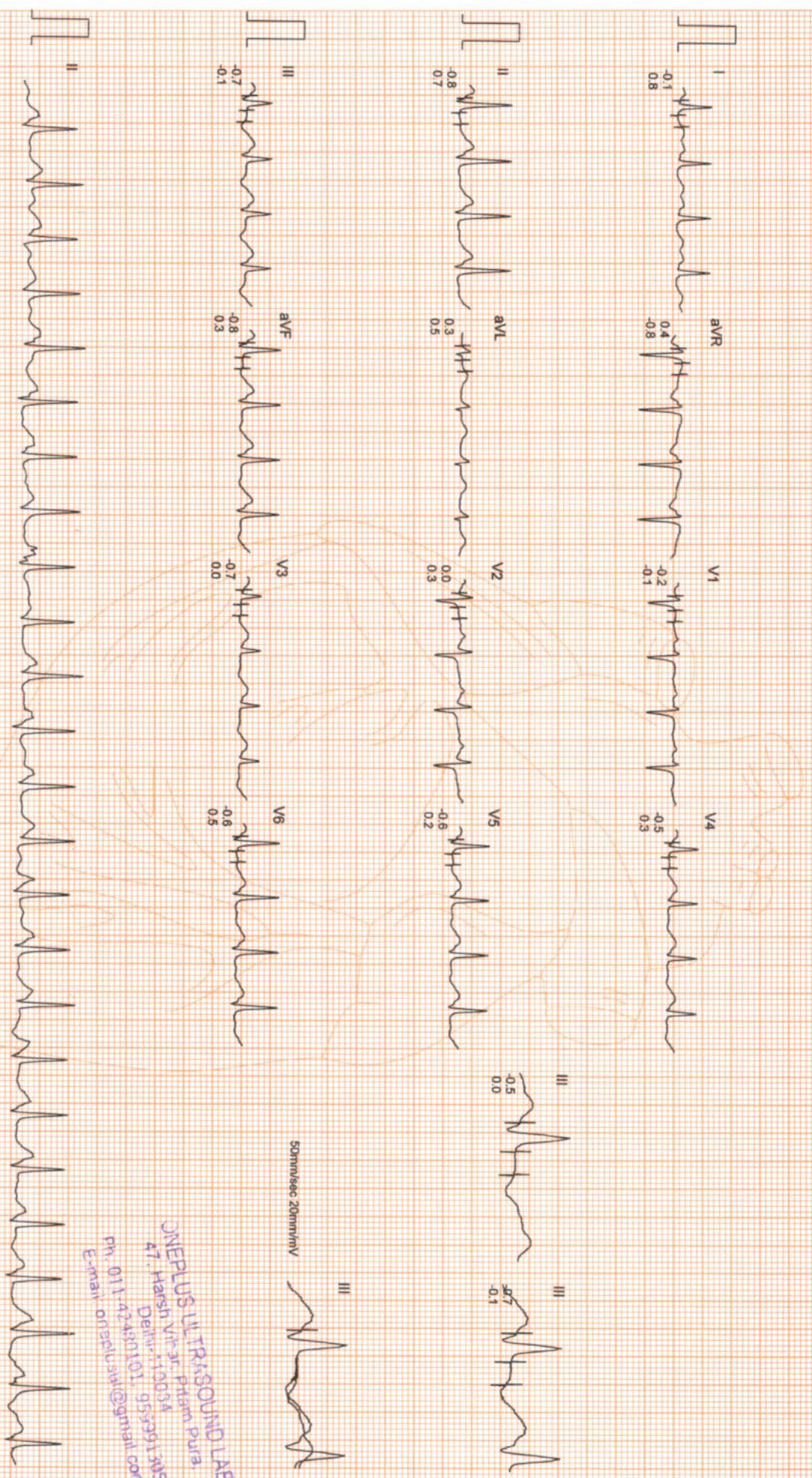
ST @ 10mm/mV

80ms PostJ

SPEED : 4.0 Km./Hr.

GRADE : 12.0%

LINKED MEDIAN



ONEPLUS ULTRASOUND LAB  
47, Harsn Vihar, Pitampura,  
Delhi-110034  
Ph. 011-42480101, 9559913051  
E-mail: onepplus@gmail.com



# ONEPLUS ULTRASOUND LAB

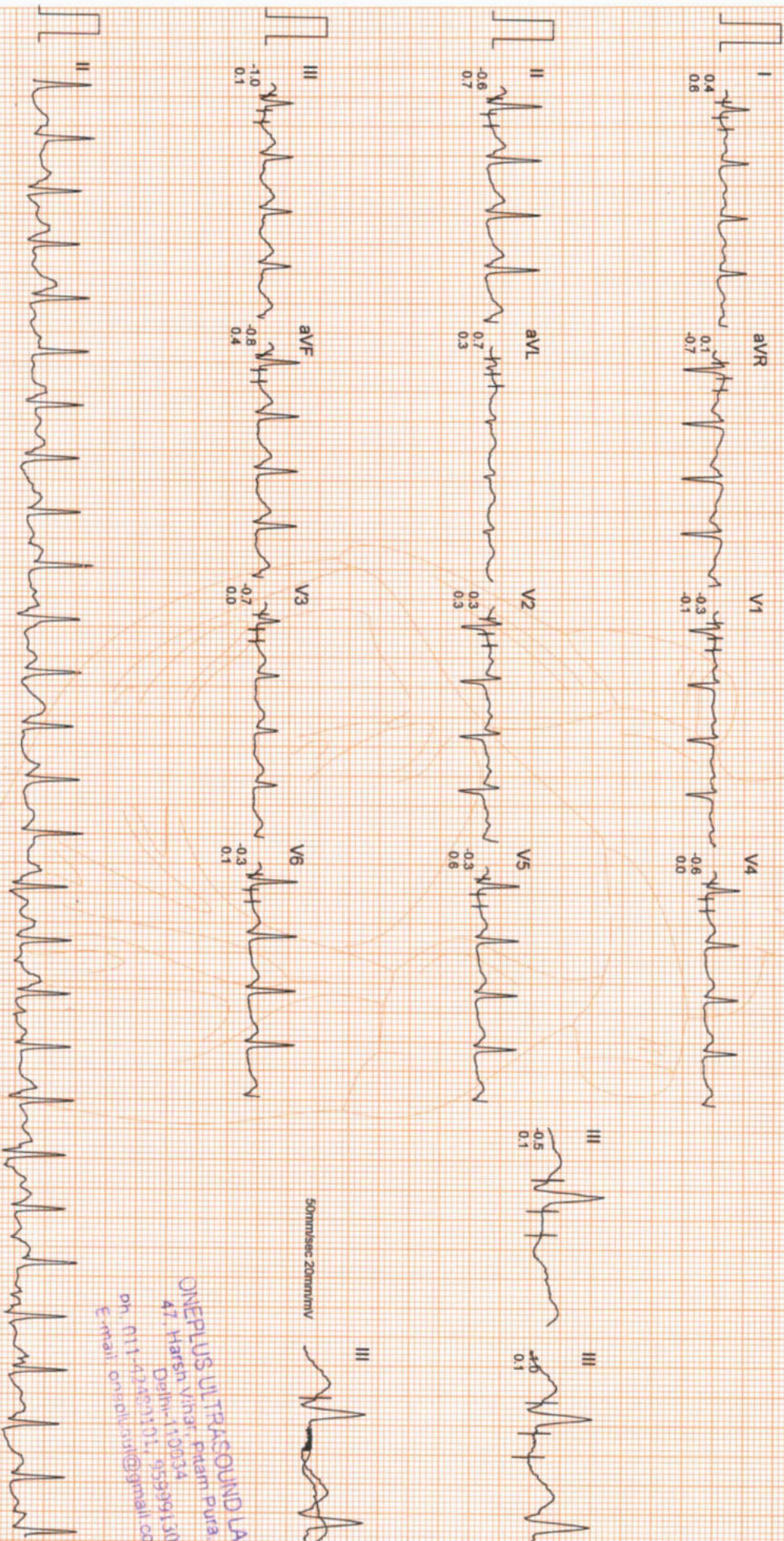
Ms. NEHA BANSAL  
I.D. : 995  
AGE/SEX : 31/F  
RECORDED : 25-2-2023 12:19

RATE : 164 BPM  
B.P. : 150/88 mmHg

BRUCE  
EXERCISE 3  
PHASE TIME : 7:29  
STAGE TIME : 1:29

ST @ 10mm/mV  
80ms PostJ  
SPEED : 5.4 Km./Hr.  
GRADE : 14.0%

LINKED MEDIAN



ONEPLUS ULTRASOUND LAB  
47, Harsh Vihar, Patna, Pura,  
Delhi-110034  
Ph: 011-43461101, 9599913051  
E-mail: onepplusul@ gmail.com

Filtered

Computer Corrected Baseline

25mm/sec 10mm/mV

CardiCom, INDIA Ph. 091-731-2620740, Tele/Fax 091-731-2431214



# ONEPLUS ULTRASOUND LAB

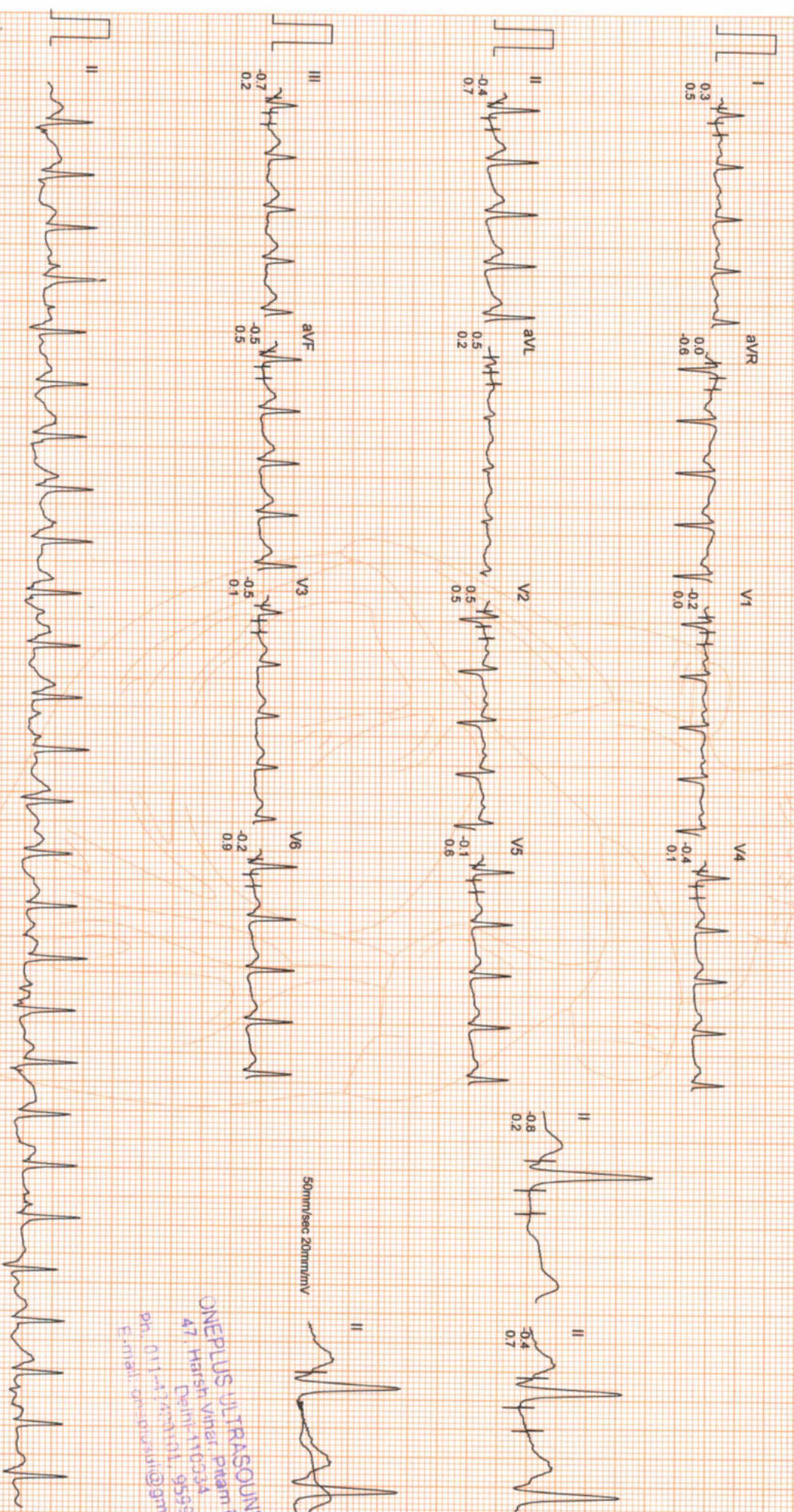
Ms. NEHA BANSAL  
I.D. : 995  
AGE/SEX : 31/F  
RECORDED : 25-2-2023 12:19

RATE : 166 BPM  
B.P. : 150/88 mmHg

BRUCE  
PEAK EXER  
PHASE TIME : 7:43  
STAGE TIME : 1:43

ST @ 10mm/mV  
80ms PostJ  
SPEED : 5.4 Km./HR.  
GRADE : 14.0 %

LINKED MEDIAN



50mm/Sec 20mm/mV

ONEPLUS ULTRASOUND LAB  
47, Harsh Vihar, Pitam Pura,  
Delhi-110034  
Ph: 011-47767171, 9593913051  
E-mail: on-plusuldi@gmail.com

Filtered

Computer Corrected Baseline

25mm/Sec 10mm/mV

CardiCom, INDIA Ph: 091-731-2620740, Telefax: 091-731-2431214



Ms. NEHA BANSAL

I.D. : 995

AGE/SEX : 31/F

RECORDED : 25-2-2023 12:19

RATE : 134 BPM

B.P. : 120/80 mmHg

# ONEPLUS ULTRASOUND LAB

BRUCE

RECOVERY

PHASE TIME : 2:59

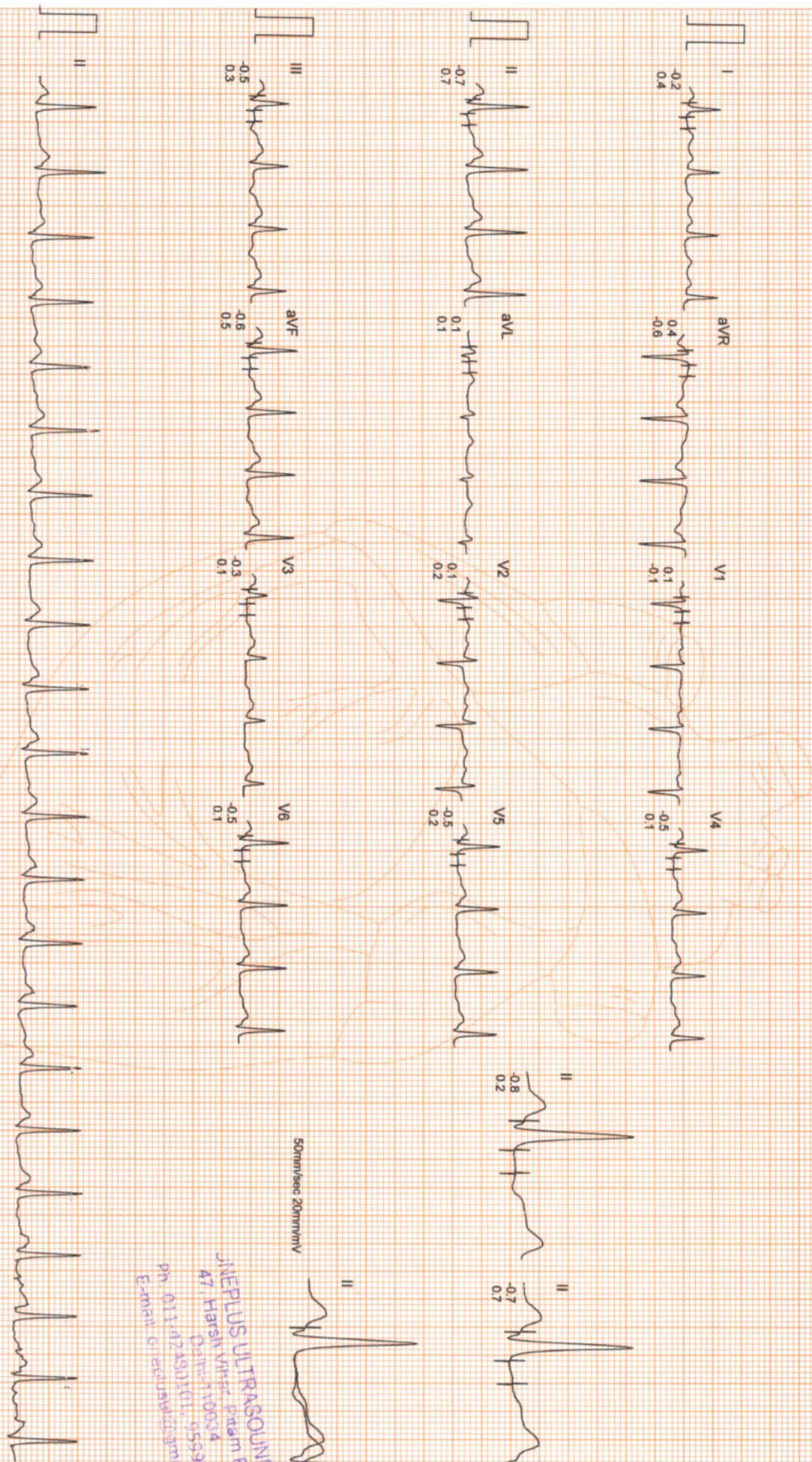
ST @ 10mm/mv

80ms PostJ

SPEED : 0.0 Km./Hr.

GRADE : 0.0 %

LINKED MEDIAN



50mm/sec 20mm/mV

**JNEPLUS ULTRASOUND LAB**  
 47, Harsh Vihar, Pitam Pura,  
 Gurgaon-110034  
 Ph. 011-42430101, 95539413051  
 E-mail: o\_echography@gmail.com

Filtered Computer Corrected Baseline

25mm/sec 10mm/mV

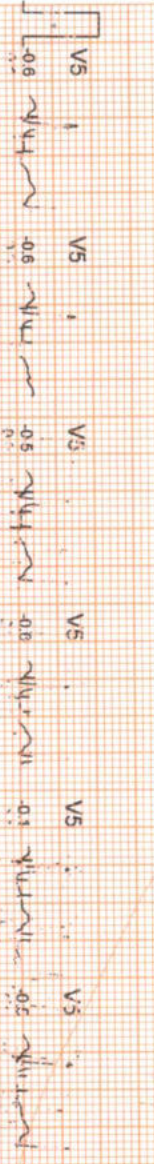
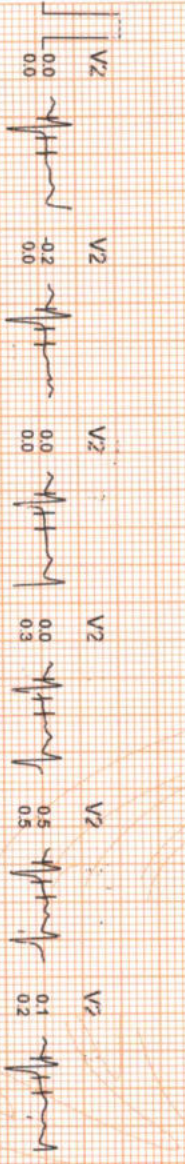
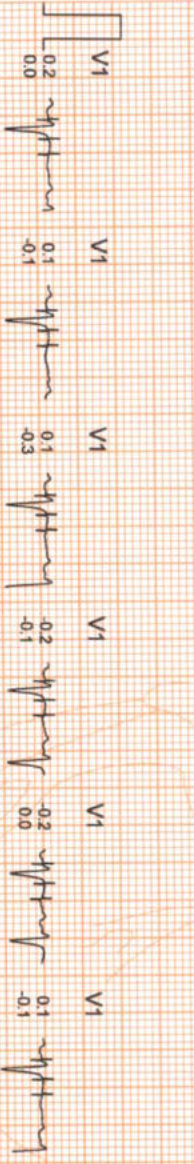
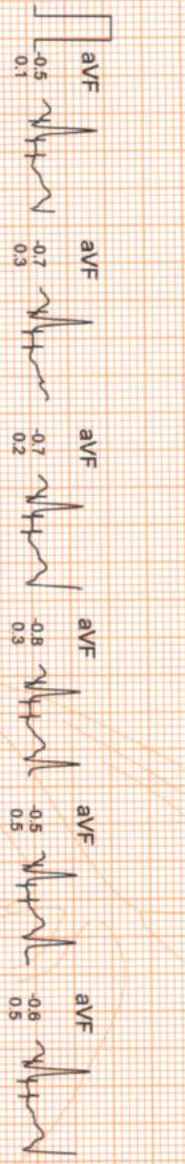
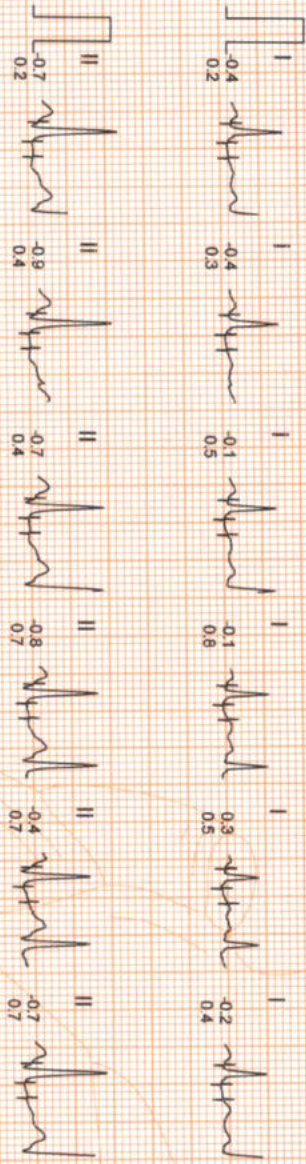
CardiCom, INDIA Ph.:091-731-2620740, TeleFax:091-731-2431214



# ONEPLUS ULTRASOUND LAB

AVG E.C.G.

STAGE	STAGE 1	STAGE 2	PEAK EXERCISE	RECOVERY
SUPINE	STANDING	STAGE 1	STAGE 2	RECOVERY
0.0Kmph 0.0% 131 bpm B.P. 116/78 80ms Post	0.0Kmph 0.0% 119 bpm B.P. 116/78 80ms Post	2.59 2.59 4.0Kmph 10.0% 139 bpm B.P. 118/78 80ms Post	7.43 1.43 5.4Kmph 12.0% 166 bpm B.P. 150/88 80ms Post	2.59 2.59 0.0Kmph 0.0% 134 bpm B.P. 120/80 80ms Post



ONEPLUS ULTRASOUND LAB  
 47, H. Harsh Vihar, Pitampura  
 Delhi-110034  
 Ph: 011-26236910, 26236911, 26236912  
 Email: onepplusultrasound@gmail.com

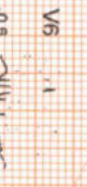
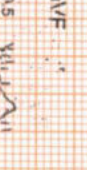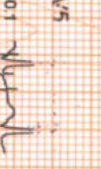

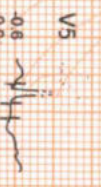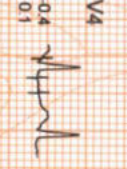
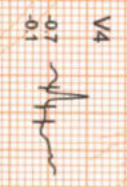
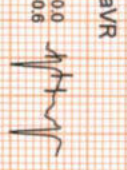

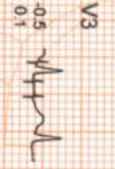
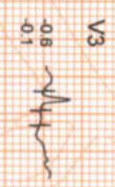
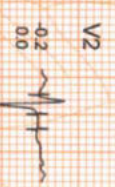
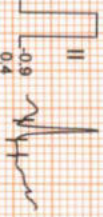
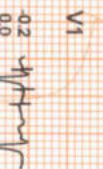
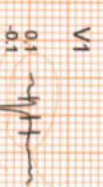
STANDING  
0.0kmph  
0.0%  
119 bpm  
B.P. 116/78  
80ms Postu

PEAK EXERCISE  
7.43  
1.43  
5.4kmph  
14.0%  
166 bpm  
B.P. 150/86  
80ms Postu

STANDING  
0.0kmph  
0.0%  
119 bpm  
B.P. 116/78  
80ms Postu

PEAK EXERCISE  
7.43  
1.43  
5.4kmph  
14.0%  
166 bpm  
B.P. 150/86  
80ms Postu



ONEPLUS ULTRASOUND LAB  
47, H.H. Nagar, Perambur Pura,  
Duraiyoddi, Chennai - 600017  
Ph: 011-43539113  
E-mail: onepplusultrasound@gmail.com









# OnePLUS Ultrasound Lab

**Dr. Nitin Agarwal**  
Pathologist & Director  
Ex. Sr. Res. MAMC  
& Lok Nayak Hospital  
Ex. Chief of Lab Dr. Lal Path Labs.

**Dr. Pooja (Garg) Agarwal**  
Radiologist & Director  
MAMC & Lok Nayak Hospital



QUALITY FIRST... ALWAYS!			
NAME	:Mrs. NEHA BANSAL	Barcode No	:10138661
AGE/GENDER	:31 YRS/Female	SPECIMEN DATE	:25/Feb/2023 09:23AM
PATIENT ID	:109744	SPECIMEN RECEIVED	:25/Feb/2023 09:38AM
REFERRED BY	:Dr. MEDIWHEEL	REPORT DATE	:25/Feb/2023 03:46PM
CENTRE NAME	:ONEPLUS ULTRASOUND LAB	LAB NO.	:012302250012

Test Name	Result	Unit	Ref. Range
-----------	--------	------	------------

## HAEMATOLOGY

### Medi Wheel Health checkup < 40 Female

<b>Glycosylated Hemoglobin (HbA1c)</b>	5.2	%	Non Diabetic adults <5.7 Prediabetic (at risk) 5.7-6.4 Diabetes >6.4
<b>Estimated average blood glucose (eag)</b>	103		

Reference range (mg/dl):

90 - 120:Excellent control, 121 - 150:Good Control, 151 - 180:Average Control, 181 - 210:Action Suggested  
>211:Panic value

### BLOOD GROUP (ABO)

B

### Rh typing

POSITIVE

### NOTE :

- \* Apart from major A,B,H antigens which are used for ABO grouping and Rh typing, many minor blood group antigens exist. Agglutination may also vary according to titre of antigen and antibody.
- \* So before transfusion, reconfirmation of blood group as well as cross-matching is needed.
- \* Presence of maternal antibodies in newborns, may interfere with blood grouping.
- \* Auto agglutination (due to cold antibody, falciparum malaria, sepsis, internal malignancy etc.) may also cause erroneous result.

### CBC

Haemoglobin	12.3	g/dl	11.5-15.0
Total Leucocyte Count	4900	/cumm	4000-10000
<b>Differential leucocyte count</b>			
Neutrophils	61.9	%	40-80
Lymphocyte	32.60	%	20-40
Monocytes	3.00	%	2-10
Eosinophils	2.0	%	1-6
Basophils	0.5	%	0-2
RBC Count	5.00	million/cumm	3.8-4.8

Checked By.

Dr. NITIN AGARWAL  
MBBS, MD (Path)  
DMC/R/01436

47, Harsh Vihar, Pitampura, New Delhi-110034 | Ph.: 011-42480101, 9599913051

E-mail: [oneplusul@gmail.com](mailto:oneplusul@gmail.com) | Web.: [www.oneplusul.in](http://www.oneplusul.in)

Page 1 of 5 Page 4 of 4





# OnePLUS Ultrasound Lab

QUALITY FIRST... ALWAYS!

**Dr. Nitin Agarwal**

Pathologist & Director  
Ex. Sr. Res. MAMC  
& Lok Nayak Hospital  
Ex. Chief of Lab Dr. Lal Path Labs.

**Dr. Pooja (Garg) Agarwal**

Radiologist & Director  
MAMC & Lok Nayak Hospital



NAME	:Mrs. NEHA BANSAL	Barcode No	:10138661
AGE/GENDER	:31 YRS/Female	SPECIMEN DATE	:25/Feb/2023 09:23AM
PATIENT ID	:109744	SPECIMEN RECEIVED	:25/Feb/2023 09:38AM
REFERRED BY	:Dr. MEDIWHEEL	REPORT DATE	:25/Feb/2023 03:46PM
CENTRE NAME	:ONEPLUS ULTRASOUND LAB	LAB NO.	:012302250012

Test Name	Result	Unit	Ref. Range
PCV(Hematocrit)	41.8	%	36-46
MCV	83.3	fL	83-101
MCH	24.6	Pg	27-32
MCHC	29.5	G/dL	32-35
Platelet count	291000	/cumm	150000-450000
RDW-CV	16	%	11.4-14.0
ESR(WESTEGRENS METHOD)	10	mm/1hr	<20

### BIOCHEMISTRY

<u>Blood sugar fasting</u>	97	mg/dL	70-110
<u>Blood sugar pp</u>	100	mg/dL	70.0-140.0
<u>Bun (blood urea nitrogen )</u>	11.60	mg/dl	7-18.7
<u>Uric acid, serum</u>	4.2	mg/dl	2.6-6.0
<u>Creatinine, serum</u>	0.64	mg/dl	0.50-1.0

### LFT(LIVER FUNCTION TEST)

Bilirubin Total	0.54	mg/dl	0.1-1.2
Bilirubin Conjugated	0.24	mg/dl	0-0.4
Bilirubin Unconjugated	0.30	mg/dl	up to 0.7
SGOT (AST)	22	U/L	0-46
SGPT (ALT)	28	U/L	0-49
Alkaline phosphatase	108	U/L	35-104
Gamma glutamyl transpeptidase	26	U/L	5.0-32.0
Total Protein	7.4	gm/dl	6.60 - 8.70
Albumin serum	4.2	g/dL	3.0-5.2
Globulin	3.20	gm/dl	1.8-3.4
Albumin/Globulin Ratio	1.31		1.10 - 2.50

### LIPID PROFILE

Cholesterol	172	mg/dl	50-200
Triglycerides	114	mg/dL	25-150

Checked By.

Dr. NITIN AGARWAL  
MBBS, MD (Path)  
DMC/R/01436

47, Harsh Vihar, Pitampura, New Delhi-110034 | Ph.: 011-42480101, 9599913051

E-mail: [oneplusul@gmail.com](mailto:oneplusul@gmail.com) | Web.: [www.oneplusul.in](http://www.oneplusul.in)

Page 2 of 5





# OnePLUS Ultrasound Lab

QUALITY FIRST... ALWAYS!

**Dr. Nitin Agarwal**

Pathologist & Director  
Ex. Sr. Res. MAMC  
& Lok Nayak Hospital  
Ex. Chief of Lab Dr. Lal Path Labs.

**Dr. Pooja (Garg) Agarwal**

Radiologist & Director  
MAMC & Lok Nayak Hospital



NAME	:Mrs. NEHA BANSAL	Barcode No	:10138661
AGE/GENDER	:31 YRS/Female	SPECIMEN DATE	:25/Feb/2023 09:23AM
PATIENT ID	:109744	SPECIMEN RECEIVED	:25/Feb/2023 09:38AM
REFERRED BY	:Dr. MEDIWHEEL	REPORT DATE	:25/Feb/2023 03:46PM
CENTRE NAME	:ONEPLUS ULTRASOUND LAB	LAB NO.	:012302250012

Test Name	Result	Unit	Ref. Range
HDL Cholesterol	46	mg/dL	40 - 60
LDL cholesterol	103	mg/dL	< 130
VLDL cholesterol	22.8	mg/dL	5-40
Cholesterol/HDL Ratio	3.7		Low Risk 3.3-4.97 Average Risk 4.4-7.1 Moderate Risk 7.1-11.0 High Risk >11.0
LDL/HDL Ratio	2.2		0 - 3.55

According to ATP III and NCEP guidelines

Parameter	Normal	Desirable	Borderline	High
Total cholesterol	<200		200-239	240
Triglycerides	<150	150-199	200-499	500
LDL	Optimal <100 Near Optimal 100-129	130-159	160-180	190
HDL	<40 : LOW 60 : HIGH			

### BUN/Creatinine ratio

Bun (blood urea nitrogen )	11.60	mg/dl	7-18.7
CREATININE	0.64	mg/dl	0.30-1.10
BUN/Creatinine ratio	18.13		10.0 - 20.0

### ENDOCRINOLOGY

#### THYROID PROFILE(T3,T4,TSH)

Triiodothyronine total [t3]	0.96	ng/dl	0.52-1.9
Thyroxine total [t4]	6.80	µg/dl	4.8-11.6
TSH (Thyroid Stimulating Hormone)	2.00	µIU/ml	0.25-5.0

#### AGE WISE VARIATION IN TSH

Checked By.

Dr. NITIN AGARWAL  
MBBS, MD (PATHOLOGIST)  
DMC/R/01436

47, Harsh Vihar, Pitampura, New Delhi-110034 | Ph.: 011-42480101, 9599913051

E-mail: oneplusul@gmail.com | Web.: www.oneplusul.in

Page 3 of 5

Clinical correlation is essential for final diagnosis. • If test results are unsatisfactory please contact personally or on phone. • This report is for perusal of doctors only.  
• All disputes Subject to Delhi Jurisdiction only. • Not for medicolegal purposes. • All congenital anomalies in a foetus may not be diagnosed in routine obstetric ultrasound.





# OnePLUS

## Ultrasound Lab

QUALITY FIRST... ALWAYS!

**Dr. Nitin Agarwal**  
Pathologist & Director  
Ex. Sr. Res. MAMC  
& Lok Nayak Hospital  
Ex. Chief of Lab Dr. Lal Path Labs.

**Dr. Pooja (Garg) Agarwal**  
Radiologist & Director  
MAMC & Lok Nayak Hospital



NAME	:Mrs. NEHA BANSAL	Barcode No	:10138661
AGE/GENDER	:31 YRS/Female	SPECIMEN DATE	:25/Feb/2023 09:23AM
PATIENT ID	:109744	SPECIMEN RECEIVED	:25/Feb/2023 09:38AM
REFERRED BY	:Dr. MEDIWHEEL	REPORT DATE	:25/Feb/2023 03:46PM
CENTRE NAME	:ONEPLUS ULTRASOUND LAB	LAB NO.	:012302250012

Test Name	Result	Unit	Ref. Range
<b>AGE</b>	<b>TSH(<math>\mu</math>IU/ml)</b>	<b>AGE</b>	<b>TSH(<math>\mu</math>IU/ml)</b>
1-4 weeks	1.00 - 19.0	16-20 yrs	0.25 - 5.0
1-12 mths	1.70 - 9.1	21 - 80 yrs	0.25 - 5.0
1-5 yrs	0.80 - 8.2	I <sup>st</sup> trimester	0.25 - 5.0
6-10 yrs	0.25 - 5.0	II <sup>nd</sup> trimester	0.50 - 5.0
11-15 yrs	0.25 - 5.0	II <sup>rd</sup> trimester	0.4 - 6.0

### Reference ranges - Interpretation of Diagnostic tests - (Jacques Wallach)

1. Primary hypothyroidism is accompanied by depressed serum T3 and T4 values and elevated serum TSH level.
2. Primary hyperthyroidism is accompanied by elevated serum T3 and T4 levels along with depressed TSH values.
3. Slightly elevated T3 levels may be found in pregnancy and estrogen therapy, while depressed levels may be encountered in severe illness, renal failure and during therapy with drugs like propranolol and propyl thiouracil.
4. Although elevated TSH levels are nearly always indicative of primary hypothyroidism, and may be seen in secondary thyrotoxicosis

## CLINICAL PATHOLOGY

### URINE ROUTINE

#### Physical examination

Quantity	30	ML
Colour	PALE YELLOW	
Transparency	CLEAR	CLEAR
Sp.gravity	1.010	1.010-1.030
pH	6.50	
Reaction	ACIDIC	ACIDIC

#### Chemical examination

Urine protein	NIL	NIL
Urine sugar	NIL	NIL
Bilirubin, urine	NEGATIVE	NEGATIVE
Urobilinogen	NORMAL	NORMAL
Ketones	NEGATIVE	NEGATIVE

#### Microscopic examination

Checked By.

Dr. NITIN AGARWAL  
MBBS, MD (Path)  
DMC/R/01436  
DR. NITIN AGARWAL  
MBBS, MD (PATHOLOGIST)

47, Harsh Vihar, Pitampura, New Delhi-110034 | Ph.: 011-42480101, 9599913051

E-mail: oneplusul@gmail.com | Web.: www.oneplusul.in

Page 4 of 5





# OnePLUS Ultrasound Lab

QUALITY FIRST... ALWAYS!

**Dr. Nitin Agarwal**

Pathologist & Director  
Ex. Sr. Res. MAMC  
& Lok Nayak Hospital  
Ex. Chief of Lab Dr. Lal Path Labs.

**Dr. Pooja (Garg) Agarwal**

Radiologist & Director  
MAMC & Lok Nayak Hospital



NAME	:Mrs. NEHA BANSAL	Barcode No	:10138661
AGE/GENDER	:31 YRS/Female	SPECIMEN DATE	:25/Feb/2023 09:23AM
PATIENT ID	:109744	SPECIMEN RECEIVED	:25/Feb/2023 09:38AM
REFERRED BY	:Dr. MEDIWHEEL	REPORT DATE	:25/Feb/2023 03:46PM
CENTRE NAME	:ONEPLUS ULTRASOUND LAB	LAB NO.	:012302250012

Test Name	Result	Unit	Ref. Range
Pus cells.	1-2	/HPF	1-2
Epithelial cells	2-3	/HPF	0-5
R.B.C.	NIL	/HPF	NIL
Casts	NIL	/HPF	NIL
Crystals	NIL	/HPF	NIL
Bacteria	NIL	/HPF	NIL
Others.	NIL		NIL

\*\*\* End Of Report \*\*\*

Checked By.

DR. NITIN AGARWAL  
MBBS,MD(PATHOLOGIST)

Dr NITIN AGARWAL  
MBBS, MD (Path)  
DMC(R)

47, Harsh Vihar, Pitampura, New Delhi-110034 | Ph.: 011-42489101, 9599913051

E-mail: [oneplusul@gmail.com](mailto:oneplusul@gmail.com) | Web.: [www.oneplusul.in](http://www.oneplusul.in)

Page 5 of 5



Name	: Mrs. NEHA BANSAL	Age/Sex	: 30 YRS/Female
Ref. By	: Dr. MEDIWHEEL	Lab No	: 012302250012
Date	: 25-Feb-2023	Patient ID	: LSHHI109744

### ULTRASOUND EXAMINATION----WHOLE ABDOMEN

**Liver** is enlarged in size (19.0 cm) and normal in outline with altered echopattern. Diffuse increase in echogenicity of liver parenchyma is noted, suggestive of fatty infiltration (grade II). No abscess or mass lesion seen. Hepatic veins, portal vein, IVC and aorta are normal. Intrahepatic biliary radicles are not dilated. CBD is normal in caliber.

**Gall bladder** is well distended with anechoic lumen. Wall thickness is normal.

**Both kidneys** are normal in size, shape, position, outline and echopattern. Corticomedullary differentiation is maintained. No pelvicalyceal dilation or calculus or mass lesion is seen.

**Spleen** is normal in size and echotexture. No mass lesion seen.

**Pancreas** is normal in size, outline and echotexture.

**Urinary bladder** is normal in shape and position. No evidence of intravesical stone or mass seen.

**Uterus** is normal in size (measures 7.3 x 4.3 x 3.5 cm), shape, position and echopattern. No mass seen.

**Uterine cavity** is empty. **Endometrial thickness** is 8.9 mm.

**Right ovary** is mildly bulky in size, **left ovary** is normal in size however both ovaries appear rounded with prominent echogenic stroma. Multiple small 2 - 3 mm sized follicles (antral follicle count >20) are seen in both ovaries. No dominant follicle seen.

**Ovarian measurements are --**

Rt. ovary – 4.2 x 2.4 x 2.1 cm, vol. 11.7 cc.

Lt. ovary – 3.0 x 2.5 x 2.3 cm, vol. 9.5 cc.

No abnormal bowel wall thickening seen in right iliac fossa.

No free fluid seen anywhere in abdomen.

**IMPRESSION:**

- Fatty infiltration of liver (grade II) with hepatomegaly.
- Polycystic appearance of bilateral ovaries.

**ADVICE:** Please correlate clinically and with hormonal profile.

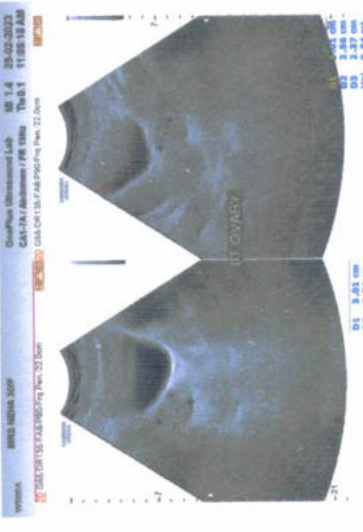
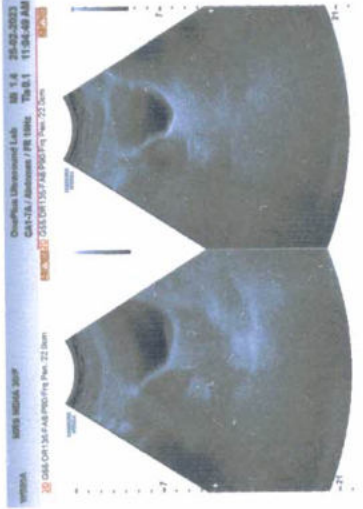

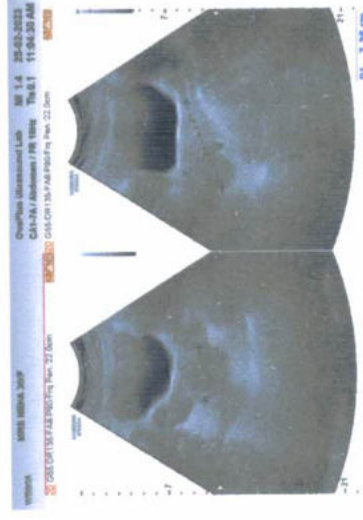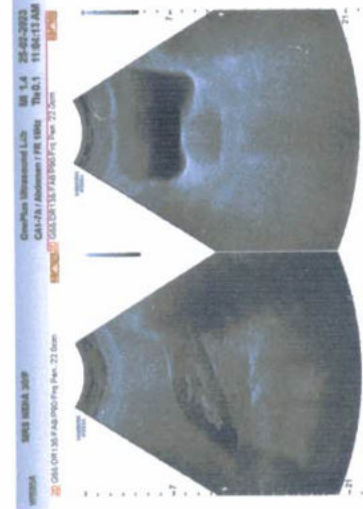


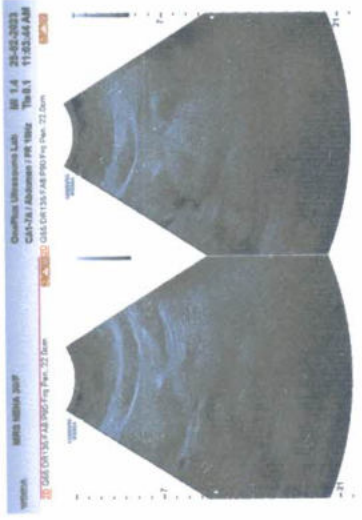

Dr. POOJA GARG  
M.B.B.S., D.M.R.D.  
Reg No. DMC/R/03398  
Radiologist  
DR. POOJA GARG  
RADIOLOGIST  
REG NO- DMC/R/03398

Type By : darshita

47, Harsh Vihar, Pitampura, New Delhi-110034 | Ph.: 011-42480101, 9599913051

E-mail: oneplusul@gmail.com | Web.: www.oneplusul.in













**OnePLUS**  
Ultrasound Lab  
— QUALITY FIRST... ALWAYS! —

**Dr. Nitin Agarwal**  
Pathologist & Director  
Ex. Sr. Res. MAMC  
& Lok Nayak Hospital  
Ex. Chief of Lab Dr. Lal Path Labs.

**Dr. Pooja (Garg) Agarwal**  
Radiologist & Director  
MAMC & Lok Nayak Hospital

Name	: Mrs. NEHA BANSAL	Age/Sex	: 30 YRS/Female
Ref. By	: Dr. MEDIWHEEL	Lab No	: 012302250012
Date	: 25-Feb-2023	Patient ID	: LSHHI109744

### X-ray-Chest PA view

Bony cage and soft tissues are normal.  
Cardiothoracic ratio is normal.  
Mediastinum is normal.  
Both hila are normal.  
Both costophrenic angles are clear.  
Both domes of diaphragm are normal.  
Lung fields are clear. No parenchymal lesion seen.

**IMPRESSION: Normal Study.**

**DR. POOJA GARG**  
RADIOLOGIST  
REG NO- DMC/R/03398  
M.B.B.S., D.M.R.C.  
Reg No. DMC/R/03398  
Radiologist


Type By : darshita

47, Harsh Vihar, Pitampura, New Delhi-110034 | Ph.: 011-42480101, 9599913051  
E-mail: [oneplusul@gmail.com](mailto:oneplusul@gmail.com) | Web.: [www.oneplusul.in](http://www.oneplusul.in)

Clinical correlation is essential for final diagnosis. • If test results are unsatisfactory please contact personally or on phone. • This report is for perusal of doctors only.  
• All disputes Subject to Delhi Jurisdiction only. • Not for medicolegal purposes. • All congenital anomalies in a foetus may not be diagnosed in routine obstetric ultrasound.



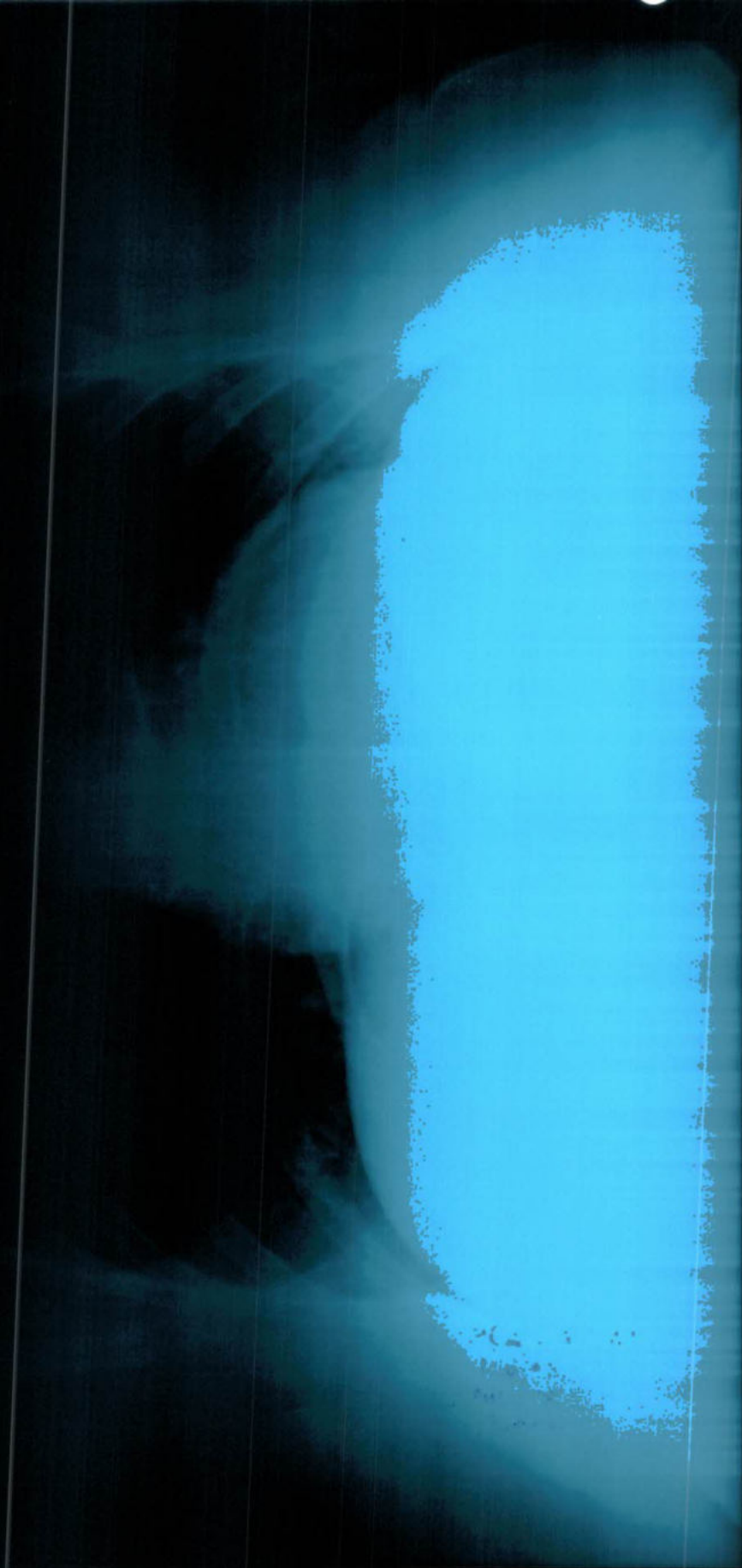
ONEPL US NI TRVSGUNDI AV 47 HARSH AIHAR PITAMPURA  
MRS NEHA BANSAL 30 YRS 52/5/5053 F CHEST BY AIEM 5152/5053



R



R



MRS. NEHA BANSAL 30 YRS 25/2/2023 F CHEST PA VIEW 2/25/2023  
ONEPI US UI TRASOUND LAB.47 HARSH VIHAR PITAMPURA