



YASHFEEN CARDIAC HOSPITAL™

At. & Po. Viraval, Navsari. 396 445. Phone (H) (02637) 235725

Website : www.yashfeenhospital.in E-mail : info@yashfeenhospital.in
(For Laboratory Reports Only)



Patient Name : HINABEN RAMANBHAI RATHOD Age : 31 Years Sex : F
Ref By Dr. : - Area : Vanesha Date : 14/09/2024
Sample Time : 14/09/2024 08:55 No : 13 Time : 12:44PM

HAEMOGRAM

Test	Findings	UOM	Normal Range
HAEMOGLOBIN	12.8	g/dl	M-13.5-17.0 gm/dl F-11.5-15.5 gm/dl
HAEMOGRAM			
RED BLOOD CELL	4.59	10 ⁶ /μL	3.76-5.70
TOTAL LEUCOCYTE COUNT	7600	10 ³ /μL	4,000-11,000cells/cumm
Differential Count			
Neutrophil	54	%	40-75 %
Lymphocytes	40	%	20-40 %
Eosinophil	1	%	01-06 %
Monocytes	5	%	02-10 %
Basophils	0	%	00-00 %
PLATELET COUNT	290000	10 ³ /μL	1.5-5.5 Lacs/cumm
RBC INDICES			
P.C.V.	36.6	%	Male-40-56%, Female-37-47%
M.C.V.	79.7	fL	76.0-94.0
M.C.H.	27.8	pg	27.0-30.0
M.C.H.C.	34.9	g/dl	30.0-35.0
BLOOD GROUP	" B "	-	-
RH FACTOR	POSITIVE	-	-
E.S.R.(1 hour)	2	mm/hr.	Male-5-10 mm/hr, Female-5-20 mm/hr

Remarks

Designed By: Sarita Infotech Pvt. Ltd., Navsari

P. Chaudh.
Dr. PIYUSH B. CHAUDHARI

M. D. Medicine
Reg. No. G-21518

Yashfeen Cardiac Hospital

Signature
Signature

Technician

Thanks for Reference



YASHFEEN CARDIAC HOSPITAL™

At. & Po. Viraval, Navsari. 396 445. Phone (H) (02637) 235725

Website : www.yashfeenhospital.in E-mail : info@yashfeenhospital.in

(For Laboratory Reports Only)



Patient Name : HINABEN RAMANBHAI RATHOD

Age : 31 Years Sex : F

Ref By Dr. : -

Area : Vanesha Date : 14/09/2024

Sample Time : 14/09/2024 08:56 No : 13

Time : 12:44PM

HAEMOGLOBIN A1 C ESTIMATION

Test	Findings	UOM	Normal Range
Hb A1C	5.6	%	>8 :Action Suggested, 7-8 :Good Control, <7 :Goal, 6-7 :Near Normal Glycemia, <6 :Non-diabetic Level
Technique METHOD - HPLC		-	
Mean Blood Glucose	115.1	mg/dL	



P. Chaud.
Dr. PIYUSH B. CHAUDHARI
M.D. Medicine
Reg. No. G-21518

Remarks

Designed By : Santa Infotech Pvt. Ltd., Navsari

Yashfeen Cardiac Hospital

Signature


Technician

Thanks for Reference



YASHFEEN CARDIAC HOSPITAL™

At. & Po. Viraval, Navsari. 396 445. Phone (H) (02637) 235725
Website : www.yashfeenhospital.in E-mail : info@yashfeenhospital.in
(For Laboratory Reports Only)



Patient Name : HINABEN RAMANBHAI RATHOD Age : 31 Years Sex : F
Ref By Dr. : - Area : Vanesha Date : 14/09/2024
Sample Time : 14/09/2024 08:56 No : 13 Time : 12:44PM

LIPID PROFILE TEST REPORT

Test	Findings	UOM	Normal Range
S.CHOLESTEROL	137.8	mg/dL	<200:Desirable, 200-239:Borderline High, >=240:High
HDL CHOLESTEROL	49.3	mg/dL	<40:Low(High Risk), >=60:High(Low Risk)
LDL CHOLESTEROL	92.4	mg/dL	<100.0: Optimal, 100.0-129.0: Nearoptimal/ Aboveoptimal, 130.0-159.0:Borderline High, 160.0-189.0:High, >=190.0:Very High
VLDL CHOLESTEROL	9.2	mg/dL	Upto 40.0 mg/dL
S.TRIGLYCERIDES	46.0	mg/dL	<150.0:Normal, 150.0-199.0:Borderline high, 200.0-499.0:High, >=500.0:Very High
CHOL/ HDL RATIO	2.8	mg/dL	LESS THAN 5.0
LDL/ HDL RATIO	1.9	mg/dL	LESS THAN 5.0



P. Chaudh.
Dr. PIYUSH B. CHAUDHARI
M.D. Medicine
Reg. No. G-21518

Remarks

Designed By Santa Infotech Pvt. Ltd., Navsari

Yashfeen Cardiac Hospital

Signature


Technician

Thanks for Reference



YASHFEEN CARDIAC HOSPITAL™

At. & Po. Viraval, Navsari. 396 445. Phone (H) (02637) 235725
Website : www.yashfeenhospital.in E-mail : info@yashfeenhospital.in
(For Laboratory Reports Only)



Patient Name : HINABEN RAMANBHAI RATHOD
Ref By Dr. : -
Sample Time : 14/09/2024 08:56 No : 13

Age : 31 Years Sex : F
Area : Vanesha Date : 14/09/2024
Time : 12:44PM

LIVER FUNCTION TEST REPORT

Test	Findings	UOM	Normal Range
TOTAL BILIRUBIN	0.5	mg/dL	0-1.0 mg/dL
DIRECT BILIRUBIN	0.2	mg/dL	0-0.8 mg/dL
INDIRECT BILIRUBIN	0.3	mg/dL	0-0.2 mg/dL
SGPT	10.2	U/L	Below 40.0 U/L
S.ALKALINE PHOSPHATASE	63.9	U/L	Child-170.0-515.0 U/L, Adults-37.0-147.0 U/L
TOTAL PROTEIN	7.1	g/dl	6.0-8.0 g/dl
ALBUMIN	4.6	g/dl	3.0-5.0 g/dl
GLOBULIN	2.5	g/dl	3.0-3.5 g/dl
A/G	1.8	g/dl	
SGOT	11.6	U/L	Below 40.0 U/L



Remarks

Designed By : Sarita Infotech Pvt. Ltd., Navsari

P. Chaudh.
Dr. PIYUSH B. CHAUDHARI
M.D. Medicine
Reg. No. G-21518

Yashfeen Cardiac Hospital

signature

Technician

Thanks for Reference



YASHFEEN CARDIAC HOSPITAL™

At. & Po. Viraval, Navsari. 396 445. Phone (H) (02637) 235725
Website : www.yashfeenhospital.in E-mail : info@yashfeenhospital.in
(For Laboratory Reports Only)



Patient Name : HINABEN RAMANBHAI RATHOD Age : 31 Years Sex : F
Ref By Dr. : - Area : Vanesha Date : 14/09/2024
Sample Time : 14/09/2024 08:56 No : 13 Time : 12:44PM

THYROID FUNCTION TEST REPORT

Test	Findings	UOM	Normal Range
T3 (TRIODOTHYRONINE)	1.29	ng/ml	Newborns:0.73-2.88, 6 Days-3 Months:0.80-2.75, 4-12Months:0.86-2.65, 1-6 Years:0.92-2.48, 7-11 Years:0.93-2.31, 12-20Years:0.91-2.18, Adults:0.80-2.00
T4 (THYROXINE)	8.11	µg/dl	Newborns:5.04-18.5, 6 Days-3 Months:5.41-17.0, 4-12 Months:5.67-16.0, 1-6 Years:5.95-14.7, 7-11 Years:5.99-13.8, 12-20 Years:5.91-13.2, Adults:5.10-14.1
TSH	1.76	µIU/ml	Newborns:0.70-15.2, 6 Days-3 Months:0.72-11.0, 4-12 Months:0.73-8.35, 1-6 Years:0.70-5.97, 7-11 Years:0.60-4.84, 12-20 Years:0.51-4.30, Adults:0.27-4.20

TECHNIQUE

ELECTROCHEMILUMINESCEN
CE

Remarks

Designed By : Sarita Infotech Pvt. Ltd., Navsari

P. Chell
Dr. PIYUSH B. CHAUDHARI
M.D. Medicine
Reg. No. G-21518

Anah

signature

Technician

Thanks for Reference

Yashfeen Cardiac Hospital



YASHFEEN CARDIAC HOSPITAL™

At. & Po. Viraval, Navsari. 396 445. Phone (H) (02637) 235725

Website : www.yashfeenhospital.in E-mail : info@yashfeenhospital.in

(For Laboratory Reports Only)



Patient Name : HINABEN RAMANBHAI RATHOD

Age : 31 Years Sex : F

Ref By Dr. : -

Area : Vanesha Date : 14/09/2024

Sample Time : 14/09/2024 08:56 No : 13

Time : 12:45PM

GGT TEST REPORT

Test	Findings	UOM	Normal Range
SERUM GGT	30.0	U/L	10.0-71.0 U/L



P. Chaudh.
Dr. PIYUSH B. CHAUDHARI
M.D. Medicine
Reg. No. G-21518

Remarks

Designed By : Sarita Infotech Pvt. Ltd., Navsari

Yashfeen Cardiac Hospital

Signature

Technician

Thanks for Reference



YASHFEEN CARDIAC HOSPITAL™

At. & Po. Viraval, Navsari. 396 445. Phone (H) (02637) 235725

Website : www.yashfeenhospital.in E-mail : info@yashfeenhospital.in
(For Laboratory Reports Only)



Patient Name : HINABEN RAMANBHAI RATHOD Age : 31 Years Sex : F
Ref By Dr. : - Area : Vanesha Date : 14/09/2024
Sample Time : 14/09/2024 08:56 No : 13 Time : 12:45PM

ROUTINE URINE ANALYSIS

Test	Findings	UOM	Normal Range
------	----------	-----	--------------

PHYSICAL EXAMINATION

Quantity	-	-	
Colour	YELLOW	-	
Appearance	CLEAR	-	
Reaction	ACIDIC	-	
Sp. Gravity	1.004	-	

CHEMICAL EXAMINATION

U.Albumin	NIL	-	
Sugar	NIL	-	
Acetone	NIL	-	
Bile Salt	NIL	-	
Bile Pigment	NIL	-	
Occult Blood	NIL	-	

MICROSCOPIC EXAMINATION

Pus Cells	1-2	/hpf	
Epithelial cells	3-4	/hpf	
Red cells	ABSENT	/hpf	
Casts	-	/hpf	
Crystals	AMORPHOUS SEEN	/hpf	
Others	BACTERIA {FEW} SEEN	/hpf	



P. Chaudh.
Dr. PIYUSH B. CHAUDHARI
M.D. Medicine
Reg. No. G-21518

Remarks

Designed By Sarita Infotech Pvt. Ltd., Navsari

Yashfeen Cardiac Hospital

Signature

Technician

Thanks for Reference



YASHFEEN CARDIAC HOSPITAL™

At. & Po. Viraval, Navsari. 396 445. Phone (H) (02637) 235725

Website : www.yashfeenhospital.in E-mail : info@yashfeenhospital.in

(For Laboratory Reports Only)



Patient Name : HINABEN RAMANBHAI RATHOD

Age : 31 Years Sex : F

Ref By Dr. : -

Area : Vanesha Date : 14/09/2024

Sample Time : 14/09/2024 08:56 No : 13

Time : 12:45PM

BLOOD SUGAR TEST REPORT

Test	Findings	UOM	Normal Range
FASTING BLOOD SUGAR	89.1	mg/dL	70-110 mg/dL
FASTING URINE SUGAR	NIL	-	NIL
POSTPANDRIAL BLOOD SUGAR	111.0	mg/dL	70-140 mg/dL
POSTPANDRIAL URINE SUGAR	N.R	-	NIL



P. Chaudh.
Dr. PIYUSH B. CHAUDHARI
M.D. Medicine
Reg. No. G-21518

Remarks

Designed By Sarita Infotech Pvt. Ltd., Navsari

Yashfeen Cardiac Hospital

Rathod

signature

Thanks for Reference

Technician



YASHFEEN CARDIAC HOSPITAL™

At. & Po. Viraval, Navsari. 396 445. Phone (H) (02637) 235725

Website : www.yashfeenhospital.in E-mail : info@yashfeenhospital.in
(For Laboratory Reports Only)



Patient Name : HINABEN RAMANBHAI RATHOD
Ref By Dr. : -
Sample Time : 14/09/2024 08:57 No : 13

Age : 31 Years Sex : F
Area : Vanesha Date : 14/09/2024
Time : 12:45PM

BIOCHEMICAL TEST REPORT

Test	Findings	UOM	Normal Range
S.CREATININE	0.5	mg/dL	Male-0.9-1.4 mg/dL, Female-0.8-1.2 mg/dL
BLOOD UREA NITROGEN	4.7	mg/dL	4.7-23.0 mg/dL
S.URIC ACID	4.8	mg/dL	Male:3.5-7.2 mg/dL, Female:2.6-6.0 mg/dL



P. Chaudhary
Dr. PIYUSH B. CHAUDHARI
M.D. Medicine
Reg. No. G-21518

Remarks

Designed By : Sarita Infotech Pvt. Ltd., Navsari

Yashfeen Cardiac Hospital

Signature

signature

Technician

Thanks for Reference



(Regd. No. E / 1390 / Navsari)

YASHFEEN CARDIAC HOSPITAL™

MANAGED BY :- YASHFEEN FOUNDATION

VIRAVAL, NAVSARI. 396 445. PHONE : (H) (02637) 235725

Website : www.yashfeenhospital.in E-mail : info@yashfeenhospital.in

(Stationary For Report Only)

2D ECHO CARDIOGRAPHY COLOUR DOPPLER REPORT

Patient Name & No	: HINABEN RAMANBHAI RATHOD CH24022602	Age/Sex	UHID :	: 2686
Doctor	: Mohil Nagad	31/ F	No :	: 2765
Referred By	:		Date :	: 14/09/2024

M-Mode findings

LVIDd : 39mm
 LVIDs : 26mm
 IVSd : 09mm
 PWd : 09mm
 EF : 60%
 Aorta : 20mm
 LA : 27mm

2D Imaging

Aortic Valve : Trileaflet, Normal
 Mitral Valve : Thin, Pliable, Normal Mobility, Normal function
 Tricuspid Valve : Normal
 Pulmonary Valve : Normal

=> : All cardiac chambers are normal sized.
 => : All cardiac valves are normal.
 => : No regional wall motion abnormality.
 => : Normal LV systolic function.
 => : Normal LV diastolic function.
 => : IAS/IVS intact.
 => : No obvious clots/ vegetations/ or effusion.
 => : IVC Normal size.

Doppler Findings

=> : No MS/MR, No TS/TR, No AS/AR & No PS/PR
 Mitral inflow Pattern : E > A
 Tissue Doppler Findings : E' > A'

Impression : Normal LVEF:60%, No RWMA.



Report Prepared By

Report Checked By
Dr. DHARMENDRA DESAI
 M.D. (Fty.) Dip. Cardiology
 Non-Invasive Cardiologist
 Reg. No. G-45284
 YASHFEEN GROUP OF HOSPITAL

YASHFEEN IMAGING & RADIOLOGY DEPARTMENT

MANAGED BY :- YASHFEEN FOUNDATION

VIRAVAL, NAVSARI. 396 445. PHONE : (H) (02637) 235725

Website : www.yashfeenhospital.in E-mail : info@yashfeenhospital.in

Patient's Name:	HINABEN R. RATHOD	Age & Sex:	31Yrs/F
Ref. by Dr.	SELF	Date:	14-09-2024

X RAY CHEST (PA VIEW)

Both lung fields appear normal.
Both hila appear normal.
Both CP angles appear clear.
Cardiac size appears within normal limit.
Both domes of diaphragm appear normal.
Bony thoracic cage appears normal.

IMPRESSION:

- Normal X-ray chest (PA view).




Dr. Dharmesh Desai
(M.D. Radiology)
Reg. No. G - 45284

YASHFEEN GROUP OF HOSPITAL

Please contact immediately for any typographical error.
This is only professional opinion, not a final diagnosis. Kindly correlate clinically. Not valid for medicolegal purpose.

HINABEN ,
ID:
DOB:
31 Years , ,
Female ,Unknown
Med.:
Location:
Referring Physician:
Notes:

14-09-2024 10:11:50

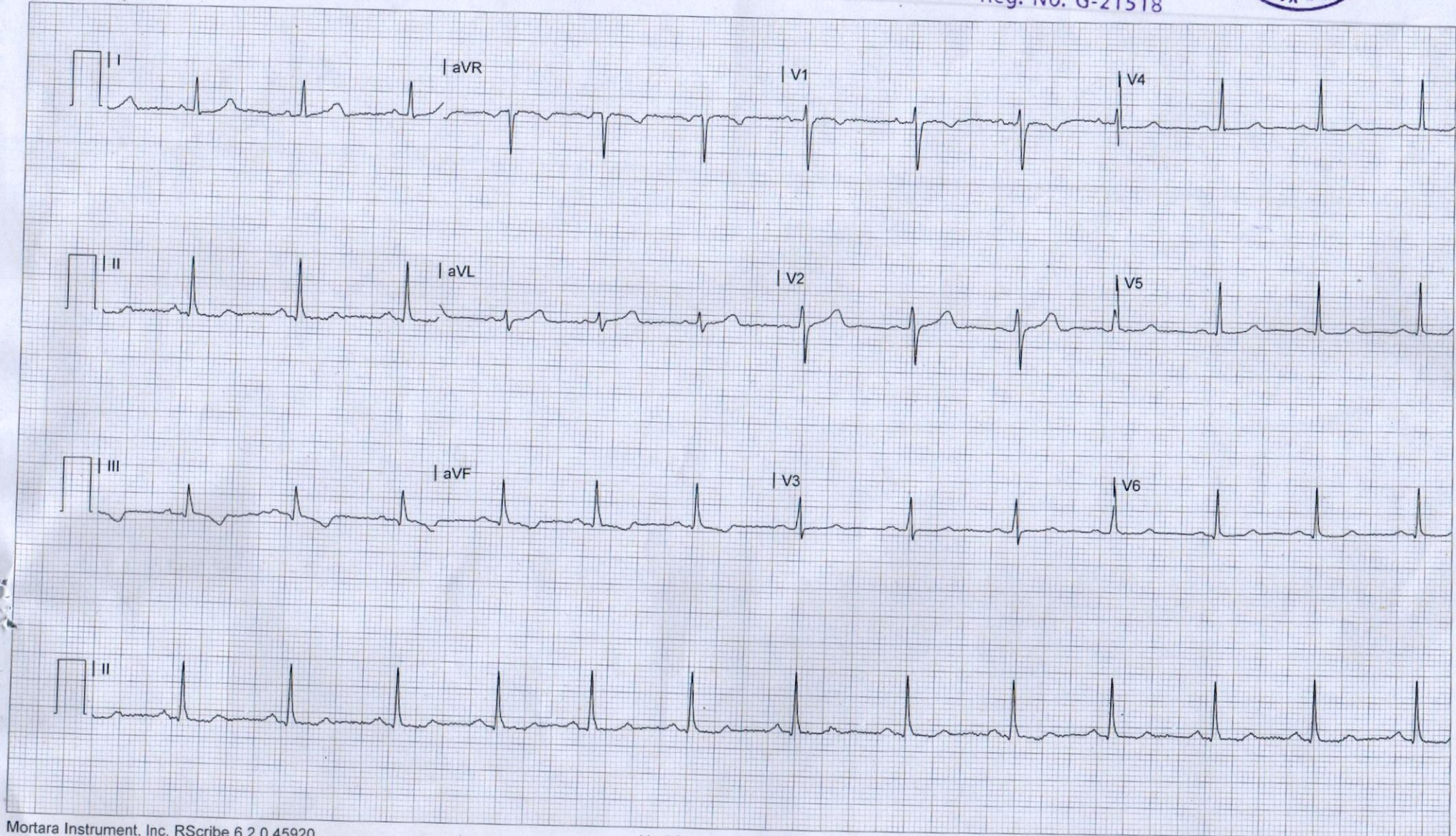
Vent. Rate: 81 BPM
PR int: 153 ms
QRS dur: 84 ms
QT/QTc: 355/392 ms
P-R-T axes: 54 58 -15
Avg. RR: 737 ms
QTcB: 413 ms
QTcF: 393 ms

SINUS RHYTHM
NONSPECIFIC T-WAVE ABNORMALITY
ABNORMAL ECG

UNCONFIRMED REPORT
Reviewed by:

f.cheer
Dr. PIYUSH B. CHAUDHARI
M.D. Medicine
Reg. No. G-21518

Signed by:



YASHFEEN IMAGING & RADIOLOGY DEPARTMENT

MANAGED BY :- YASHFEEN FOUNDATION

VIRAVAL, NAVSARI. 396 445. PHONE : (H) (02637) 235725

Website : www.yashfeenhospital.in E-mail : info@yashfeenhospital.in

Name	HINABEN R. RATHOD	Age	31Y/F
Ref by Dr	SELF	Date	14/09/2024

USG ABDOMEN & PELVIS (SCREENING)(TVS)

Liver appears normal in size & shape with normal echopattern.
No e/o focal or diffuse lesion. IHBR appear normal.
PV and CBD appear normal.

Gall bladder appears distended & normal in shape & size. No e/o calculus or mass seen.
Walls appear normal.

Pancreas appears normal in size and echogenicity. No e/o focal or diffuse lesion.

Spleen appears normal in size and shows normal echopattern. No e/o focal lesion.

Both Kidneys appear normal in size and echopattern. CM Differentiation is preserved.
No e/o calculus or hydronephrosis on either side.
Perirenal spaces appear normal on either side.
Suprarenal regions appear normal on either side. No e/o mass lesion.

Bladder is empty (due to non-compliance of patient). Adv: Follow up USG with normally distended bladder.

Uterus appears anteverted, normal in size & shows heterogeneously hypo echoic rounded lesions involving anterior and posterior walls. Largest measures 4 x 5 mm in anterior wall.
Endometrial cavity is empty. ET- 11 mm.

Both ovaries appear mildly bulky and shows multiple subcentimeter size follicles (mostly peripherally situated) with echogenic stroma suggest PCOD changes.
Right ovary measures 3.8 x 2.0 x 3.0 cm (volume 11 cc)
Left ovary measures 4.2 x 2.1 x 3.0 cm (volume 14 cc)
No e/o adnexal mass on either side.

RIF region appears normal.

No e/o ascites.

IMPRESSION:

1. Uterine fibroids.
2. Both ovaries show PCOD changes.

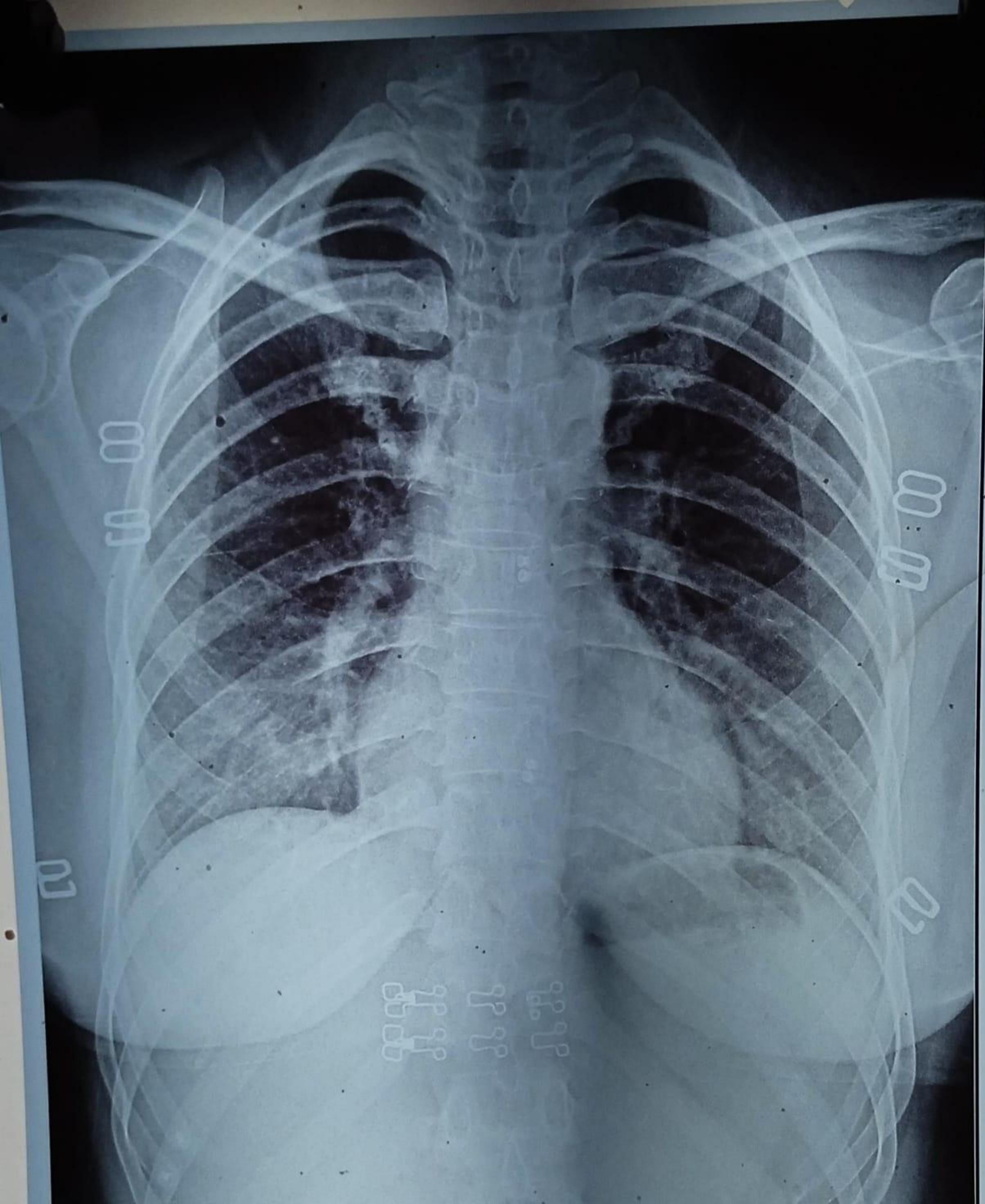


Dr. DHARMESH DESAI

(M.D. Radiology)
Dr. Dharmesh Desai
Reg. No. MG - 45284

YASHFEEN GROUP OF HOSPITALS

Please contact immediately for any typographical error.
This is only professional opinion, not a final diagnosis. Kindly correlate clinically. Not valid for medicolegal purpose.



H24022602 HINABEN R RATHOD 31/Y 140924296 ChestErect PA 14/09/2024
YASHFEEN GROUP OF HOSPITALS NAVSARI PH:9924047789