

Mr. Mahesh Sroamy 3577K

29/11/14

Urine 4/m Blood (+)
Grade I Fatty liver
Single cyst in right lobe of liver
Tiny calculi nonobstructing in kidney

- Drink plenty of water
- Urologist reference
- Gastroenterologist reference
- Daily 30 min walking
- Repeat Urine R/m after 7 days

Dr. Milind Shinde



Dr. MILIND SHINDE
MBBS, DNB Medicine
Reg. No. 2011/05/1544

PUNE LAB ADDRESS: Seraph Centre, Opp. BSNL Exchange, Shahu College Road, Off Pune-Satara Road, Behind Panchami Hotel, Pune - 411009

CENTRAL PROCESSING LAB: 2nd Floor, Aston, Sundervan Complex, Above Mercedes Showroom, Andheri West, Mumbai - 400053

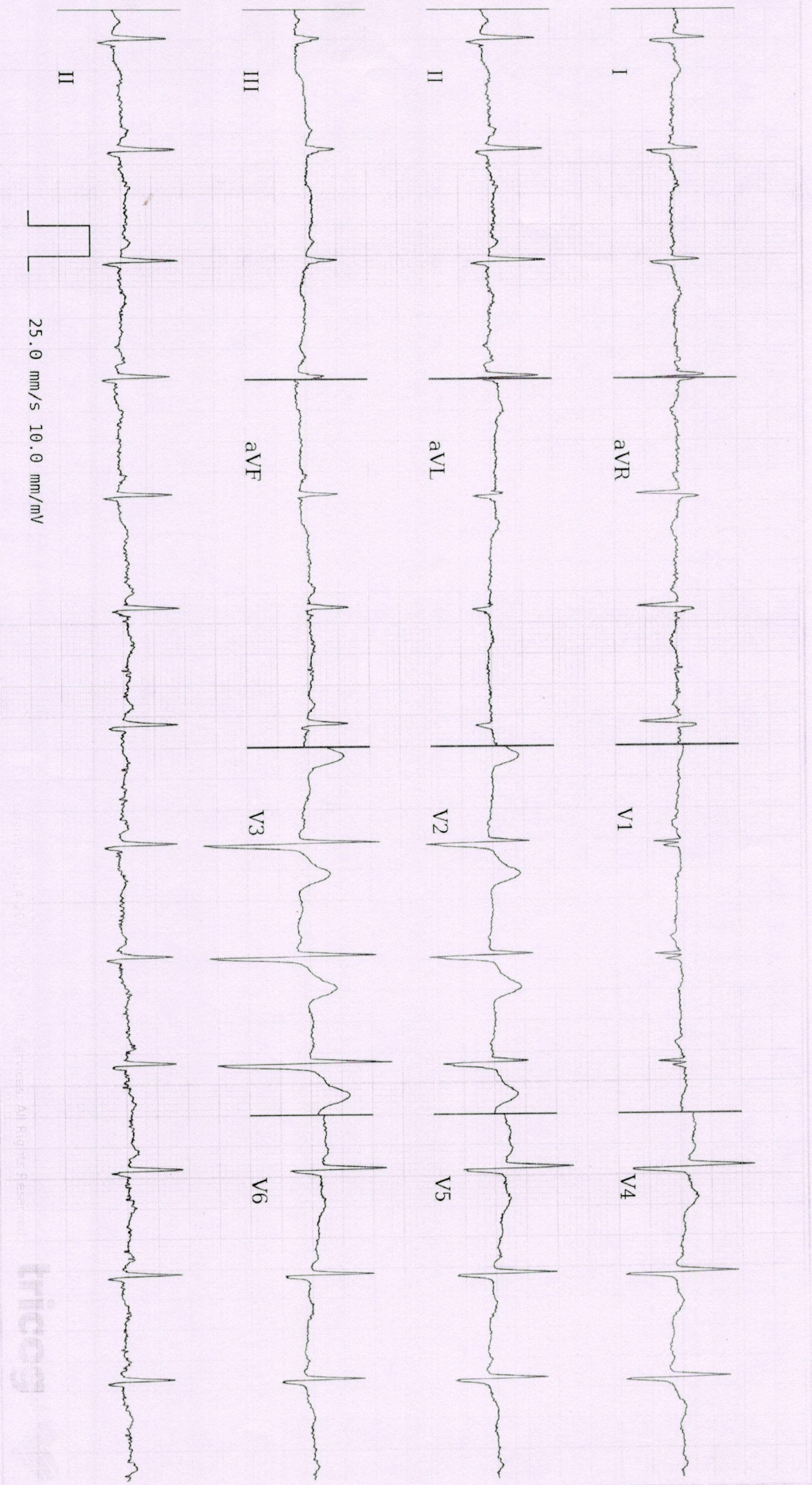
HEALTHLINE - MUMBAI: 022-6170-0000 | **OTHER CITIES:** 1800-266-4343 | **For Feedback -** customerservice@suburbandiagnosics.com | www.suburbandiagnosics.com

Brief Disclaimer: (1) Suburban Diagnostics ensures that the tests are conducted with utmost care and safety and are performed on samples received as per the sample collection guide of Suburban Diagnostics. (2) Sample may be rejected if unacceptable for the requested tests. (3) Test results may vary from laboratory to laboratory and also in some parameters from time to time for the same patient. (4) Report must not be copied in part, only in full. (5) This report is not valid for medico-legal purposes. (6) Patient information or data will not be communicated to a third party except in the case of a notifiable disease to a Public Care Unit. (7) Suburban Diagnostics reserves the right to subcontract samples to other laboratories as required. (8) Suburban Diagnostics is not liable for any penalties or liabilities arising out of or relating in any way to these services and/or content or information provided herein. (9) For the elaborated disclaimer, please turn over the page or visit our website.

SUBURBAN DIAGNOSTICS - LULLANAGAR, PUNE

Patient Name: MAHESH SIDDARAM SWAMY Date and Time: 27th Nov 21 10:42 AM

Patient ID: 2133132787



25.0 mm/s 10.0 mm/mV

Age 34 2 22
 years months days

Gender Male

Heart Rate 83 bpm

Patient Vitals

BP: NA

Weight: NA

Height: NA

Pulse: NA

Spo2: NA

Resp: NA

Others:

Measurements

QSRD: 86 ms

QT: 368 ms

QTc: 432 ms

PR: 130 ms

P-R-T: 66° 80° 20°

REPORTED BY

(Signature)

Dr.Milind Shinde
 MBBS, DNB Medicine
 2011/05/1544

ECG Within Normal Limits: Sinus Rhythm, Normal Axis. Please correlate clinically.

Disclaimer: 1) Analysis in this report is based on ECG alone and should be used as an adjunct to clinical history, symptoms, and results of other invasive and non-invasive tests and must be interpreted by a qualified physician. 2) Patient vitals are as entered by the clinician and not derived from the ECG.

PATIENT NAME: MR. MAHESH SIDDARAM SWAMY.

AGE: 34 YEARS/M.

DATE: 27.11.2021.

CID NO : 2133132787.

2D ECHOCARDIOGRAPH & COLOUR DOPPLER

M - Mode values

Doppler Values

AORTIC ROOT (mm)	26	PULMONARY VEL (m/sec)	0.9
LEFT ATRIUM (mm)	27	PG (mmHg)	3
RV (mm)	10	AORTIC VEL (m/sec)	1.2
IVS - S (mm)	11	PG (mmHg)	6
LVID - D (mm)	43	MITRAL E WAVE (m/sec)	1.1
LVID - S (mm)	24	A WAVE (m/sec)	0.6
LVPW - D (mm)	10	TRICUSPID VEL. (m/sec)	
EJECTION FRACTION (%)	60	PG (mmHg)	

REPORT:

Normal size LV.
Normal LV systolic function, LVEF 60 %
No regional wall motion abnormality.
Normal sized other cardiac chambers.

Mitral valve has normal leaflets with normal flow. No mitral regurgitation. Normal flow velocities noted across the valve.
Aortic valve has three thin leaflets with normal structure and function. No aortic regurgitation.
Normal Tricuspid & pulmonary valves.
No tricuspid regurgitation.
PA pressures Normal.


Intact IAS and IVS.
No clots, vegetations, pericardial effusion noted.

IMPRESSION :

NORMAL LV SIZE AND FUNCTION.

NORMAL VALVES.

NORMAL PA PRESSURE.



Dr. ANUJA MULAY
M.B.B.S, MD, DNB (CARDIOLOGY)
Reg. No. 2003/03/1418

Dr. Anuja Mulay, Cardiologist.
M. D., D.N.B Card.

....End of Report....

ADDRESS: Seraph Centre, Opp. BSNL Exchange, Shahu College Road, Off Pune-Satara Road, Behind Panchami Hotel, Pune - 411009

CENTRAL PROCESSING LAB: 2nd Floor, Aston, Sundervan Complex, Above Mercedes Showroom, Andheri West, Mumbai - 400053

HEALTHLINE - MUMBAI: 022-6170-0000 | OTHER CITIES: 1800-266-4343 | For Feedback - customerservice@suburbandiagnosics.com | www.suburbandiagnosics.com

CID : 2133132787
Name : Mr MAHESH SIDDARAM SWAMY
Age / Sex : 34 Years/Male
Ref. Dr :
Reg.Location : Lulla Nagar, Pune Main Centre
Report Date : 27-Nov-2021 / 11:01
Printed : 27-Nov-2021 / 11:01

USG (ABDOMEN + PELVIS)

LIVER : The liver is normal in size, shape and smooth margins.

It shows raised parenchymal echo pattern s/o grade I fatty infiltration.

The intra hepatic biliary and portal radical appear normal. **Simple cyst of size 22 x 19 mm is seen in right lobe of liver.**
The main portal vein and CBD appears normal.

GALL BLADDER : The gall bladder is physiologically distended. The visualized gall bladder appears normal.
No evidence of pericholecystic fluid is seen.

PANCREAS : The pancreas is well visualised and appears normal. No evidence of solid or cystic mass lesion is noted.

KIDNEYS : Right kidney measures 10.9 x 4.1 cm. There is 3.2 mm calculus seen in mid pole.

Left kidney measures 10.4 x 5.4 cm. There is 4.2 mm calculus seen in lower pole.

Few tiny calculi (2 to 3 mm) seen in mid pole.

Both the kidney shows multiple pyramidal tip calcifications / calculi (1- 2 mm).

No evidence of hydronephrosis, hydroureter or mass lesion seen.

Both the kidneys are normal in size, shape and echotexture.

SPLEEN : The spleen is normal in size, shape and echotexture. No evidence of focal lesion is noted.

URINARY BLADDER : The urinary bladder is well distended. It shows thin walls and sharp mucosa.
No evidence of calculus is noted. No mass or diverticulum is seen.

PROSTATE : The prostate is normal in size and echotexture.

Visualized small bowel loops appear non-dilated. Gaseous distension of large bowel loops.
There is no evidence of any lymphadenopathy or ascitis.

IMPRESSION :

- Grade I fatty liver.
- Simple cyst in right lobe of liver.
- Bilateral non-obstructing renal calculi.

Advice - Clinical and lab correlation.

-----End of Report-----

R. Rawal.
Dr. PALLAVI RAWAL
MBBS, MD Radiology
Reg No 2013/04/1175

ADDRESS: Seraph Centre, Opp. BSNL Exchange, Shahu College Road, Off Pune-Satara Road, Behind Panchami Hotel, Pune - 411009

CENTRAL PROCESSING LAB: 2nd Floor, Aston, Sundervan Complex, Above Mercedes Showroom, Andheri West, Mumbai - 400053

HEALTHLINE - MUMBAI: 022-6170-0000 | OTHER CITIES: 1800-266-4343 | For Feedback - customerservice@suburbandiagnosics.com | www.suburbandiagnosics.com

CID#	: 2133132787	SID#	: 177804497295
Name	: MR.MAHESH SIDDARAM SWAMY	Registered	: 27-Nov-2021 / 08:57
Age / Gender	: 34 Years/Male	Collected	: 27-Nov-2021 / 08:57
Ref. Dr	: -	Reported	: 27-Nov-2021 / 09:23
Reg.Location	: Lulla Nagar, Pune (Main Centre)	Printed	: 27-Nov-2021 / 09:24

X-RAY CHEST PA VIEW

The lung fields are clear with no parenchymal lesion.

The cardiothoracic ratio is maintained and the cardiac outline is normal

The domes of the diaphragm are normal.


The cardio and costophrenic angles are clear.

Bony thorax is normal.

IMPRESSION:

No significant abnormality detected.

*** End Of Report ***



Dr.Pallavi Rawal
MD. RADIODIAGNOSIS
RADIOLOGIST

ADDRESS: Seraph Centre, Opp. BSNL Exchange, Shahu College Road, Off Pune-Satara Road, Behind Panchami Hotel, Pune - 411009

CENTRAL PROCESSING LAB: 2nd Floor, Aston, Sundervan Complex, Above Mercedes Showroom, Andheri West, Mumbai - 400053

HEALTHLINE - MUMBAI: 022-6170-0000 | **OTHER CITIES:** 1800-266-4343 | **For Feedback -** customerservice@suburbandiagnosics.com | **www.suburbandiagnosics.com**