

Compose

Inbox

Starred

Snoozed

Sent

Drafts

More

## Fwd: Health Check up Booking Request Code(PKG10000227),Beneficiary Co



**Vijay Kumar** <VIJAY.KUMAR12@bankofbaroda.com>  
to me

[Get Outlook for Android](#)

**From:** Mediwheel <customercare@policywheel.com>

**Sent:** Monday, August 8, 2022 4:40:17 PM

**To:** Vijay Kumar <VIJAY.KUMAR12@bankofbaroda.com>

**Cc:** Mediwheel CC <customercare@mediwheel.in>; Mediwh

**Subject:** Health Check up Booking Request(bobE14805),Pack

**\*\*सावधान:** यह मेल बैंक डोमेन के बाहर से आया है.

**\*\*CAUTION:** THIS MAIL IS ORIGINATED FROM  
ATTACHME



Mediwheel

Meet

New meeting

Join a meeting



Bill of Supply (Interim Bill)



Patient ID : 20220803681  
Age/Sex : 35y / F  
Patient Name : RINKU KUMARI RAY  
Dr. Name : DR HIREN PATEL  
Referred By : self  
SAC : 9993 "Service covered under healthcare services"  
Class : Contract  
PAN Card : AAQCS5566G

Visit No. : OPD20220810245(OPD)  
Bill No. : OPD20220810245  
Bill Date : N/A  
Speciality : Intensivist  
Company Name : Mediwheel Health Check Up  
GSTIN : 24AAQCS5566G2ZW  
City/Village : Vadodara

Expense Details	Qty	Rate	Gross Amount	Waive	Net Amount
<b>Visit Charge</b>					
13-Aug-2022 Physician First Consultation OPD	1.0	0.00	0.0	0.0	0.00
Ophthalmologist First Consultation OPD	1.0	0.00	0.0	0.0	0.00
<b>Visit Charge (Subtotal)</b>			<b>0.0</b>	<b>0.0</b>	<b>0.00</b>
<b>PATHOLOGY</b>					
13-Aug-2022 CBC, ESR	1.0			0.0	
Urine R/M	1.0			0.0	
STOOL EXAMINATION	1.0			0.0	
Blood Group	1.0			0.0	
FBS & PPBS	1.0			0.0	
TFT (Thyroid Function Test)	1.0			0.0	
RENAL FUNCTION TEST	1.0			0.0	
LFT (Liver Function Test)	1.0			0.0	
Lipid Profile	1.0			0.0	
HBA1C	1.0			0.0	
MediWheel Full Body Health Check-Up(Female Below 40)	1.0	2000.00	2000.0	0.0	2000.00
<b>PATHOLOGY (Subtotal)</b>			<b>2000.0</b>	<b>0.0</b>	<b>2000.00</b>
<b>Radiology</b>					
13-Aug-2022 X-RAY CHEST PA	1.0			0.0	
USG WHOLE ABDOMEN SCREENING	1.0			0.0	
X-RAY CHEST PA	1.0	0.00	0.0	0.0	0.00
USG WHOLE ABDOMEN SCREENING	1.0	0.00	0.0	0.0	0.00
<b>Radiology (Subtotal)</b>			<b>0.0</b>	<b>0.0</b>	<b>0.00</b>
<b>Non Invasive Cardiology</b>					
13-Aug-2022 ECG Charge(OPD Base)	1.0	0.00	0.0	0.0	0.00
ECHO COLOUR DOPPLER SCREENING	1.0	0.00	0.0	0.0	0.00
<b>Non Invasive Cardiology (Subtotal)</b>			<b>0.0</b>	<b>0.0</b>	<b>0.00</b>

Total Bill Amount  
Net payable amount  
Bill Outstanding

2000.00  
2000.00  
2000.00

Received With Thanks From RINKU KUMARI RAY of Rs 0.0 /-  
(Rs Zero Only)

Printed By : (Vaishali Salunke)  
For , Savita Hospital Live





# Savita

**Superspeciality Hospital**  
(A Unit of Solace Healthcare Pvt. Ltd.)

Parivar Char Rasta, Waghodia-Dabhoi Ring Road, Vadodara-390019

☎ 0265-2578844 / 2578849 ✉ mh@savitahospital.com 🌐 savitahospital.com

## PHYSICIAN EXAMINATION

**Name:- RINKU KUMARI RAY**

**Age: 35/FEMALE**

**Reg.No: 20220803681**

**DOE: 13/08/2022**

### Physical Examination:

**Height: 160CM**

**Weight: 71KG**

**PULSE: 100**

**Temperature: NORMAL**

**BMI: 27.07**

**BP: 104/70**

**SPO2- 96%**

**Chief Complaint: NAD**

**Past History: NAD**

**General Examination: NAD**

**Systemic Examination: NAD**

**INVESTIGATION :**

**ADVICE: NAD**

**DR HIREN PATEL.**





## Examination By Ophthalmologist

Name:- RINKU KUMARI RAY

Age:36/FEMALE

Reg.No: 20220803681

DOE: 13/08/2022

Present Complaints: NAD

Medical History: NAD

Examination Of Eye:	<u>Right</u>	<u>Left</u>
External Examination :	NAD	NAD
Ati Seg Examination:	A/S WNL	NAD
Schiotz Tonometry IOP:	NAD	NAD

Fundus: NILL

Without Glass Distant Vision: 6/6 \_\_\_\_\_ 6/6

Near Vision: \_\_N6 \_\_\_\_\_ N6

With Glass Distant Vision: WNL \_\_\_\_\_ WNL

Near Vision: WNL \_\_\_\_\_ WNL

Colour Vision (With Ishihara Chart): WNL

Advice: NAD

DR CHETAN CHAUHAN



CANON RK-F2  
13/AUG/2022 13:07  
No. :003109  
NAME : M/F

<RIGHT>  
[REF] VD: 0.0  
SPH CYL AX  
+0.25 -0.50 179

<LEFT >  
[REF]  
+0.25 -0.75 6

PD : 61 mm

SOLACE HEALTH CARE  
WAGHODIA ROAD,  
VADODARA.




<b>Patient Name :</b>	RINKU KUMARI RAY	<b>Sample No. :</b>	20220806064 
<b>Patient ID :</b>	20220803681	<b>Visit No. :</b>	OPD20220810245
<b>Age/Sex :</b>	35y/Female	<b>Call. Date :</b>	13-Aug-2022 11:37
<b>Consultant :</b>	DR HIREN PATEL	<b>S. Coll. Date :</b>	13-Aug-2022 13:20
<b>Ward :</b>	-	<b>Report Date :</b>	13-Aug-2022 15:47

### CBC, ESR

Investigation	Result	Normal Value
Hemoglobin :	11.2 gm/dl [L]	12.5 to 16.0 gm/dl
P.C.V. :	35.5 % [L]	37.0 to 47.0 %
M.C.V. :	78.2 fL	78 to 100 fL
M.C.H. :	24.7 pg [L]	27 to 31 pg
M.C.H.C. :	31.5 g/dl [L]	32 to 36 g/dl
RDW :	13.8 %	11.5 to 14.0 %
RBC Count :	4.54 X 10 <sup>6</sup> / cumm	4.2 to 5.4 X 10 <sup>6</sup> / cumm
Polymorphs :	63 %	38 to 70 %
Lymphocytes :	33 %	15 to 48 %
Eosinophils :	02 %	0 to 6 %
Monocytes :	02 % [L]	3 to 11 %
Basophils :	000 %	0.0 to 1.0 %
Total :	100	< 100 > 100
WBC Count :	8000 /cmm	4000 to 10000 /cmm
Platelets Count :	158000 /cmm	1,50,000 to 4,50,000 /cmm
ESR - After One Hour :	73 mm/hr [H]	1 to 20 mm/hr
P/S :		

**Dr. Mehul Desai**  
G-9521



<b>Patient Name :</b>	RINKU KUMARI RAY	<b>Sample No. :</b>	20220806064 
<b>Patient ID :</b>	20220803681	<b>Visit No. :</b>	OPD20220810245
<b>Age/Sex :</b>	35y/Female	<b>Call. Date :</b>	13-Aug-2022 11:37
<b>Consultant :</b>	DR HIREN PATEL	<b>S. Coll. Date :</b>	13-Aug-2022 13:20
<b>Ward :</b>	-	<b>Report Date :</b>	13-Aug-2022 15:47

### Blood Group


Investigation	Result	Normal Value
<b>BLOOD GROUP :</b>		
<b>ABO</b>	A	
<b>Rh</b>	Positive	

### FBS & PPBS

Investigation	Result	Normal Value
Blood Sugar (FBS) :	85 mg/dl	74 - 100 mg/dl
Urine Sugar ( FUS ) :	Nil	
Blood Sugar (PP2BS) :	100 mg/dl	70 to 120 mg/dl
Urine Sugar ( PP2US ) :	Nil	

### HBA1C

Investigation	Result	Normal Value
Glycosylated Hb :	5.4 %	Near Normal Glycemia : 6 to 7 Excellent Control : 7 to 8 Good Control : 8 to 9 Fair Control : 9 to 10 Poor Control : > 10
Average Plasma Glucose of Last 3 Months :	108.28	



**Dr. Mehul Desai**  
G-9521



# Savita

**Superspeciality Hospital**  
(A Unit of Solace Healthcare Pvt. Ltd.)


Parivar Char Rasta, Waghodia-Dabhoi Ring Road, Vadodara-390019

☎ 0265-2578844 / 2578849 ✉ mh@savitahospital.com 🌐 savitahospital.com

<b>Patient Name :</b>	RINKU KUMARI RAY	<b>Sample No. :</b>	20220806064 
<b>Patient ID :</b>	20220803681	<b>Visit No. :</b>	OPD20220810245
<b>Age/Sex :</b>	35y/Female	<b>Call. Date :</b>	13-Aug-2022 11:37
<b>Consultant :</b>	DR HIREN PATEL	<b>S. Coll. Date :</b>	13-Aug-2022 13:20
<b>Ward :</b>	-	<b>Report Date :</b>	13-Aug-2022 15:47


## RENAL FUNCTION TEST

Investigation	Result	Normal Value
Creatinine :	1.1 mg/dl	0.6 - 1.4 mg/dl
Urea :	26 mg/ dl	13 - 45 mg/dl
Uric Acid :	4.1 mg/dl	3.5 - 7.2 mg/dl
Calcium :	8.8 mg/dl	8.5 - 10.5
Phosphorus :	3.8 mg/dl	1.5 - 6.8




**Dr. Mehul Desai**  
G-9521



<b>Patient Name :</b>	RINKU KUMARI RAY	<b>Sample No. :</b>	20220806064 
<b>Patient ID :</b>	20220803681	<b>Visit No. :</b>	OPD20220810245
<b>Age/Sex :</b>	35y/Female	<b>Call. Date :</b>	13-Aug-2022 11:37
<b>Consultant :</b>	DR HIREN PATEL	<b>S. Coll. Date :</b>	13-Aug-2022 13:20
<b>Ward :</b>	-	<b>Report Date :</b>	13-Aug-2022 15:47

**LFT (Liver Function Test)**

Investigation	Result	Normal Value
Total Bilirubin :	0.5 mg/dl	0.2 to 1.0 mg/dl
Direct Bilirubin :	0.3 mg/dl	0.0 to 0.2 mg/dl
Indirect Bilirubin :	0.2 mg/dl	0.0 to 0.8 mg/dl
AST (SGOT) :	20 U/L	5 to 34 U/L
ALT (SGPT) :	26 U/L	0 to 55 U/L
Total Protein (TP) :	6.7 g/dL	6.4 to 8.3, g/dl
Albumin (ALB) :	3.6 g/dl	3.5 to 5.2 g/dl
Globulin :	3.1 g/dl	2.3 to 3.5 g/dl
A/G Ratio :	1.16	
Alkaline Phosphatase (ALP) :	129 U/L	40 to 150 U/L
GAMMA GT. :	19 U/L	7 to 35 U/L



**Dr. Mehul Desai**  
G-9521






# Savita

**Superspeciality Hospital**  
(A Unit of Solace Healthcare Pvt. Ltd.)

Parivar Char Rasta, Waghodia-Dabhoi Ring Road, Vadodara-390019


☎ 0265-2578844 / 2578849 ✉ mh@savitahospital.com 🌐 savitahospital.com

<b>Patient Name :</b>	RINKU KUMARI RAY	<b>Sample No. :</b>	20220806064 
<b>Patient ID :</b>	20220803681	<b>Visit No. :</b>	OPD20220810245
<b>Age/Sex :</b>	35y/Female	<b>Call. Date :</b>	13-Aug-2022 11:37
<b>Consultant :</b>	DR HIREN PATEL	<b>S. Coll. Date :</b>	13-Aug-2022 13:20
<b>Ward :</b>	-	<b>Report Date :</b>	13-Aug-2022 15:47

## Lipid Profile


Investigation	Result	Normal Value
Sample :	Fasting	
Sample Type :	Normal	
Cholesterol (Chol) :	190 mg/dl	Low risk : < 200 Moderate risk : 200 - 239 High risk : > or = 240
Triglyceride :	115 mg/dl	Normal : < 200.0 High : 200 - 499 Very High : > or = 500
HDL Cholesterol :	50 mg/dl	Low risk : > or = 60 mg/dL High risk : Up to 35 mg/dL
LDL :	117 mg/dl [L]	131.0 to 159.0(N) < 130.0(L) > 159.0(H)
VLDL :	23 mg/dl	Up to 0 to 34 mg/dl
LDL/HDL Ratio :	2.34	Low risk : 0.5 to 3.0 Moderate risk : 3.0 to 6.0 Elevted level high > 6.0
Total Chol / HDL Ratio :	3.8	Low Risk : 3.3 to 4.4 Average Risk : 4.4 to 7.1 Moderate Risk : 7.1 to 11.0 High Risk : > 11.0
Total Lipids :	655 mg/dl	400 to 700 mg/dl

**Note :-** Lipemic samples give high triglyceride value and falsely low LDL value.



**Dr. Mehul Desai**  
G-9521



<b>Patient Name :</b>	RINKU KUMARI RAY	<b>Sample No. :</b>	20220806064 
<b>Patient ID :</b>	20220803681	<b>Visit No. :</b>	OPD20220810245
<b>Age/Sex :</b>	35y/Female	<b>Call. Date :</b>	13-Aug-2022 11:37
<b>Consultant :</b>	DR HIREN PATEL	<b>S. Coll. Date :</b>	13-Aug-2022 13:20
<b>Ward :</b>	-	<b>Report Date :</b>	13-Aug-2022 15:47

### Urine R/M

Investigation	Result	Normal Value
Quantity - :	20 ml	
Colour - :	Pale Yellow	
Reaction (pH) :	5.0	4.6-8.0
Turbidity :	Clear	
Deposit :	Absent	Absent
Sp.Gravity :	1.025	1.005-1.010
Protein :	Absent	Absent
Glucose :	Absent	Absent
Bile Salts :	Absent	Absent
Bile pigments :	Absent	Absent
Ketones :	Absent	Absent
Urobilinogen :	Absent	
Blood :	Absent	Absent
Pus Cells :	0-1 /hpf	0-5/hpf
Red Blood Cells :	0-1 /hpf	Absent
Epithelial Cells :	7-10 /hpf	



**Dr. Mehul Desai**  
G-9521

13-Aug-22 11:47:33 AM

KUMAR, RINKU  
Female

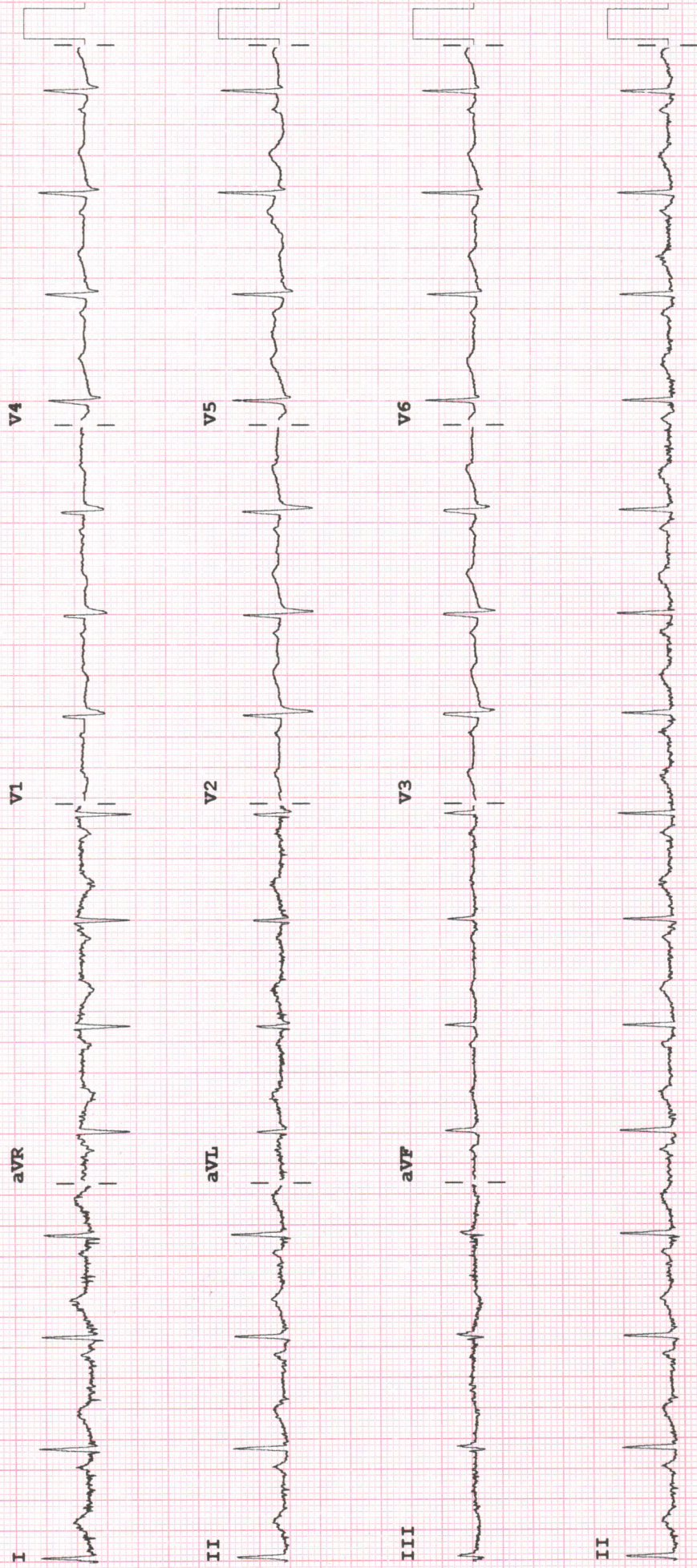
25 Years

Rate 88  
PR 132  
QRSD 72  
QT 364  
QTc 441

--AXIS--

P 32  
QRS 45  
T 11

12 Lead; Standard Placement



Device:

Speed: 25 mm/sec Limb: 10 mm/mV Chest: 10.0 mm/mV

F 50~ 0.50-150 Hz W

PH09

P?



**2D-ECHOCARDIOGRAPHY AND COLOR DOPPLER REPORT**

**NAME: RINKU K RAY**

**DATE : 13/08/2022**

**AGE/SEX: 35YRS/FEMALE**

**REF BY: DR. HIREN PATEL**

**OBSERVATION:**

- NORMAL LV SIZE AND NORMAL LV SYSTOLIC FUNCTION. LVEF = 60% (VISUAL).
- NO E/O LV DIASTOLIC DYSFUNCTION.
- NO RWMA AT REST.
- NO MR. NO MS.
- NO AR. NO AS.
- NO TR. NO PAH.
- NORMAL SIZED LA, RA & RV WITH NORMAL RV SYSTOLIC FUNCTION.
- NORMAL SIZED MPA, RPA & LPA.
- INTACT IAS AND IVS.
- NO E/O INTRACARDIAC CLOT/VEGETATION/ PE.
- NORMAL IVC.

**CONCLUSION:**

- NORMAL LV/RV SIZE AND SYSTOLIC FUNCTION.
- NO RWMA AT REST.
- LVEF = 60% (VISUAL).

**DR.NIRAV BHALANI**  
[CARDIOLOGIST]

**DR.ARVIND SHARMA**  
[CARDIOLOGIST]

**DR. CHIRAG SHETH**  
[CARDIOLOGIST]

*Handwritten signature and initials in blue ink.*



**Saturday, August 13, 2022**

**RINKUKUMARI RAY**

**35 YEARS/FEMALE**

**ULTRASONOGRAPHY OF ABDOMEN AND PELVIS SCREENING**

**Liver** shows normal size and echogenicity. No mass lesion detected.  
PV, CBD and intrahepatic biliary radicals shows no dilatation.

**The gall bladder** is distended and show normal gall bladder wall thickness. There is no evidence of gallstones.

**Spleen** appears normal in size and echotexture. No evidence of focal lesion.  
**Pancreas** appears normal in size and echotexture. No focal lesion.

Both kidneys show normal size, position and cortical echogenicity.  
Corticomedullary differentiation is preserved bilaterally.  
**No calculus or hydronephrosis on either side.**

**The urinary bladder** is partially distended and appears normal. No evidence of any calculus or mass lesion is noted.  
No evidence of Lymphadenopathy or ascites seen.  
No e/o dilated bowel loops seen.

**CONCLUSION:**

**NO SONOGRAPHIC ABNORMALITY IS DETECTED.**

  
**DR SARJAN VASAVA, DMRD**



**Saturday, August 13, 2022**  
**RINKU KUMARI RAY**  
**35 YEARS/FEMALE**

**CHEST X RAY PA VIEW**

Both the lung fields appear normal.

Both costophrenic angles appear clear.

Cardiac silhouette appear normal.

Both hila appears normal.

Mediastinum and aorta appear normal.

Bony thorax appears normal.

No evidence of free gas seen under dome of diaphragm.

**COMMENTS:**

- **NORMAL BOTH LUNG FIELDS.**
- **NORMAL CARDIAC SIZE.**

**Dr. Sarjan Vasava**  
DMRD