

PANACEA HOSPITAL

B 36/44 F.K KABIR NAGAR, DURGAKUND
TOLLFREE NO-18001233070. Whatsapp No - 8795832852
www.piire.org
panaceaquery@gmail.com|panceahospitalit@gmail.com



OP Slip

Print Date : 29-Feb-2024 11:14AM



UHID No :- UD-23240006502 **OP No** :- OP-23240019943 **OP Date** :- 29 Feb 2024 11:11AM
Patient Name :- Mrs VARSHA PARJAPATI **Age/Sex** :- 30 Y/Female **Mobile No** :- 9616165393
Husband :- HARIOM PARJAPATI **Department** :- GENERAL MEDICINE
Pay Type :- Cash **Consultant** :- Dr Pallavi Mishra (MBBS,MD,MBBS)
Token No :- NOR. - 1 **Paid/Bal** :- 0.00 /30.00
Patient Type :- Normal
Address :- D 37/88 A GODOWLIA BARDEO -221001,varanasi

BP :- 90/70 **Rx**
height :- 152
Weight (kg) :- 52
BMI :- 22.50

CH - 82
NC - 28
WE - 88
PR - 62
SPO2 - 98
PEFR - 300

Tab. Celimas MZ 1Tm
Ts. An Lok (500mg)
Ts. Seas M 1g 1/2 Tm

Pallavi Mishra
DR. Pallavi Mishra
MBBS, MD (GENERAL MEDICINE)
MCI Reg. No. 52033

Printed By : Mr Siddhant Dwivedi
Created By : Mr Siddhant Dwivedi



PANACEA HOSPITAL

B 36/44 F.K KABIR NAGAR, DURGAKUND
TOLLFREE NO-18001233070. Whatsapp No - 8795832852
www.piire.org
panaceaquery@gmail.com|panceahospitalit@gmail.com



OP Slip

Print Date : 29-Feb-2024 11:13AM



UHID No :- UD-23240006502	OP No :- OP-23240019943	OP Date :- 29 Feb 2024 11:11AM
Patient Name :- Mrs VARSHA PARJAPATI	Age/Sex :- 30 Y/Female	Mobile No :- 9616165393
Husband :- HARIOM PARJAPATI	Department :- OPHTHALMOLOGY	
Pay Type :- Cash	Consultant :- Dr Santosh Verma (MBBS,MS)	
Token No :- NOR. - 1	Paid/Bal :- 0.00 /30.00	
Patient Type :- Normal		
Address :- D 37/88 A GODOWLIA BARDEO -221001,varanasi		

BP :-
height :-
Weight (kg) :-
BMI :-

Rx

VA { 616 --- MS 2/7
616 --- 616 2/7

Near { +2.6
NG

2- Locally BLE

1- h. Lubstone ultra-QID

0000

Printed By : Mr Siddhant Dwivedi

Created By : Mr Siddhant Dwivedi


Dr. SANTOSH VERMA
MBBS, MS (Ophthalmologist)
MCI Reg. No. 09-3452 of 1



PANACEA HOSPITAL

B 36/44 F.K KABIR NAGAR, DURGAKUND
TOLLFREE NO-18001233070. Whatsapp No - 8795832852
www.paire.org
panaceaquery@gmail.com | panceahospitalit@gmail.com



OP Slip

Print Date : 29-Feb-2024 11:12AM



UHID No	:- UD-23240006502	OP No	:- OP-23240019943	OP Date	:- 29 Feb 2024 11:11AM
Patient Name	:- Mrs VARSHA PARJAPATI	Age/Sex	:- 30 Y/Female	Mobile No	:- 9616165393
Husband	:- HARIOM PARJAPATI	Department	:- DENTAL		
Pay Type	:- Cash	Consultant	:- Dr SHRUTI MISHRA (AA)		
Token No	:- NOR. - 1	Paid/Bal	:- 0.00 /30.00		
Patient Type	:- Normal				
Address	:- D 37/88 A GODOWLIA BARDEO -221001, varanasi				

BP :-
height :-
Weight (kg) :-
BMI :-

Rx c/c = patient came for routine dental checkup .

O/E ⇒ stain / calculus ++ / ++

P/P ⇒ Chronic gen gingivitis

T/A ⇒ Scaling & polishing /

Shruti

Dr. SHRUTI MISHRA
BDS, (DENTIST)
MCI Reg. No. (A-09784)

Printed By : Mr Siddhant Dwivedi

Created By : Mr Siddhant Dwivedi



PANACEA HOSPITAL

B 36/44 F.K KABIR NAGAR, DURGAKUND
TOLLFREE NO-18001233070. Whatsapp No - 8795832852
www.piire.org
panaceaquery@gmail.com|panceahospitalit@gmail.com



OP Slip

Print Date : 29-Feb-2024 02:34PM



UHID No	:- UD-23240006502	OP No	:- OP-23240019987	OP Date	:- 29 Feb 2024 2:34PM
Patient Name	:- Mrs VARSHA PARJAPATI	Age/Sex	:- 30 Y/Female	Mobile No	:- 9616165393
Husband	:- HARIOM PARJAPATI	Department	:- OBST. & GYNAECOLOGY		
Pay Type	:- Cash	Consultant	:- Dr VANDANA SINGH (MBBS,MS)		
Token No	:- NOR. - 6	Paid	:- 0.00		
Patient Type	:- Normal				
Address	:- D 37/88 A GODOWLIA BARDEO -221001,varanasi				

B+ve

BP :- 90/70
height :- 152
Weight (kg) :- 52
BMI :- 22.50

Rx

cpo- nil.

CH - 82
NC - 28
WC - 88
PR - 69
SPO₂ - 98
PEFR - 300

LMP - 24/2/24

P₁+L₁ - 2 1/2 y LSLS.

↳ 6m back took MTP kit.

Pap smear
1) Tab albendazole 400 mg x 4/s. stat.
2) AF kit as advised.
both husband & wife.

Printed By : Mr Nitin Kumar Yadav
Created By : Mr Nitin Kumar Yadav

Vandana Singh
VANDANA SINGH
MBBS, DGO. (OBST & GYN)
MCI REG. NO. 43474

Facilities:

All clinical Biomedical & Hematology Investigations including Bone Marrow Examination VPT, Podiascan & Complete Foot Care (First Time in Purvanchal) All Hormonal Investigation by Chemiluminescent Method Visceral Fat by (AB-140) Ambulatory BP Monitoring CGMS & Insulin Pump Available PFT, 2D-ECHO (Color Doppler), Holter, TMT, Cardiac-3 available VIA, VILI, Colposcopy available Special Endocrinological Investigation Protocols.

ISO 9001:2008 Certified
Mobile: 9389994334, 9554572190, 9453837595



Panacea Pathology

Clinical Reference Lab

Persistence, Preparedness and Precision
EQAS (CMC Vellore Attached) & IQAS System
पूर्वांचल की सर्वोत्तम गुणवत्ता वाली पैथोलॉजी

UHID No :- UD-23240006502 **Booking No/Date** :- 37 / 29-Feb-2024 12:18 PM
Patient Name :- Mrs VARSHA PARJAPATI **Age/Sex** :- 30 Y/F
Husband :- HARIOM PARJAPATI **OP No** :- OP-23240019943
Address :- D 37/88 A GODOWLIA BARDEO -221001 , varanasi **Mobile No** :- 9616165393
Consultant :- Dr Pallavi Mishra (MBBS,MD)

Investigations	Observations	Biological Ref. Interval	Unit
HAEMATOLOGY			
CBC			
HAEMOGLOBIN <i>DefaultMethod / test Machine</i>	10.1	12.50 - 15.00	gm/dl
TLC <i>Methology / Carm</i>	5,000	4000.00 - 11000.00	Cells/cumm.
DLC DIFFERENTIAL LEUCOCYTE COUNT			
NEUTROPHILS	58	40.00 - 75.00	%
LYMPHOCYTES	28	20.00 - 45.00	%
EOSINOPHILS	08	1.00 - 6.00	%
MONOCYTES	06	2.00 - 10.00	%
BASOPHILS	00	<1-2	%
PLATELET COUNT	2.11	1.50 - 4.10	lacs /cumm
PCV	32.1	33.00 - 42.00	%
RBC <i>Methology / Carm</i>	3.60	3.50 - 4.50	million/cumm
MCV(MEAN CELL VOLUME)	89.2	83.00 - 101.00	fl
MCH(MEAN CELL HAEMOGLOBIN)	28.1	27.00 - 32.00	pg
MCHC	31.5	31.50 - 35.00	gm%
RDW-CV	11.9	11.00 - 16.00	%
RDW-SD	43.2	37.00 - 57.00	fl

* END OF REPORT *

Consulting Pathologist
DR. UMESH KUMAR
MBBS, MD (PATHOLOGIST),
MCh, Pathology

Lab Technician

Timing : 24/7 hrs

This Report is not valid for medico legal purpose

Note: These tests have technical limitations. Clinico-pathological interpretation is necessary. In case of any disparity test may be repeated immediately.

Address : 36/44 FK Kabir Nagar, Durgakund, Varanasi – 221005

Email: dramishra@gmail.com, drpallaviojha@gmail.com Website: panaceahospital.org

Facilities:

All clinical Biomedical & Hematology Investigations including Bone Marrow Examination VPT, Podiascan & Complete Foot Care (First Time in Purvanchal) All Hormonal Investigation by Chemiluminescent Method Visceral Fat by (AB-140) Ambulatory BP Monitoring CGMS & Insulin Pump Available PFT, 2D-ECHO (Color Doppler), Holter, TMT, Cardiac-3 available VIA, VILI, Colposcopy available Special Endocrinological Investigation Protocols.

ISO 9001:2008 Certified

Mobile: 9389994334, 9554572190, 9453837595

**Panacea Pathology****Clinical Reference Lab**

Persistence, Preparedness and Precision
EQAS (CMC Vellore Attached) & IQAS System
पूर्वांचल की सर्वोत्तम गुणवत्ता वाली पैथोलॉजी

UHID No :- UD-23240006502 **Booking No/Date** :- 37 / 29-Feb-2024 12:18 PM
Patient Name :- Mrs VARSHA PARJAPATI **Age/Sex** :- 30 Y/F
Husband :- HARIOM PARJAPATI **OP No** :- OP-23240019943
Address :- D 37/88 A GODOWLIA BARDEO -221001 **Mobile No** :- 9616165393
, varanasi
Consultant :- Dr Pallavi Mishra (MBBS,MD)

Investigations	Observations	Biological Ref. Interval	Unit
----------------	--------------	--------------------------	------

HAEMATOLOGY

ESR	28.0	0.00 - 20.00	mm at 1 hr
BLOOD GROUP ABO & RH FACTOR			
BLOOD GROUP	"B"		
RH FACTOR	POSITIVE		
HBA1C -(BY GOLD STANDARD METHOD :HPLC)	5.4	Normal: 4.0 - 5.4 Prediabetic : 5.5 -6.3 Diabetes mellitus := 6.4	%

BIOCHEMISTRY**BLOOD SUGAR FASTING**

GLUCOSE	87.0	60.00 - 100.00	mg/dl
PRE-DIABETICS(IMPAIRED FASTING TOLER)	-	100.00 - 125.00	mg/dl
DIABETICS	-	upto 126	mg/dl
TARGET IN DM	-	80.00 - 130.00	mg/dl

BIOCHEMISTRY**PPBS(POST PRANDIAL BLOOD SUGAR)**

POST PRANDIAL BLOOD GLUCOSE(2 HR AFTER MEAL)	123.0	110.00 - 150	mg/dl
IGT(2 HR 75GM GLUCOSE)	-	140.00 - 199.00	mg/dl
DIABETES	-	upto200	mg/dl

Lab Technician

Consulting Pathologist
DR. UMESH KUMAR
MBBS,MD (PATHOLOGIST)
M.D. Pathology

Timing : 24/7 hrs

This Report is not valid for medico legal purpose

Note: These tests have technical limitations. Clinico-pathological interpretation is necessary. In case of any disparity test may be repeated immediately.

Address : 36/44 FK Kabir Nagar, Durgakund, Varanasi - 221005

Email: dramishra@gmail.com, drpallaviojha@gmail.com Website: panaceahospital.org

Facilities:

All clinical Biomedical & Hematology Investigations including Bone Marrow Examination
VPT, Podiascan & Complete Foot Care (First Time in Purvanchal)
All Hormonal Investigation by Chemiluminescent Method
Visceral Fat by (AB-140) Ambulatory BP Monitoring
CGMS & Insulin Pump Available
PFT, 2D-ECHO (Color Doppler), Holter, TMT, Cardiac-3 available
VIA, VILI, Colposcopy available
Special Endocrinological Investigation Protocols.

ISO 9001:2008 Certified

Mobile: 9389994334, 9554572190, 9453837595

**Panacea Pathology****Clinical Reference Lab**

Persistence, Preparedness and Precision
EQAS (CMC Vellore Attached) & IQAS System
पूर्वांचल की सर्वोत्तम गुणवत्ता वाली पैथोलॉजी

UHID No :- UD-23240006502 **Booking No/Date** :- 37 / 29-Feb-2024 12:18 PM
Patient Name :- Mrs VARSHA PARJAPATI **Age/Sex** :- 30 Y/F
Husband :- HARIOM PARJAPATI **OP No** :- OP-23240019943
Address :- D 37/88 A GODOWLIA BARDEO -221001 **Mobile No** :- 9616165393
, varanasi
Consultant :- Dr Pallavi Mishra (MBBS,MD)

Investigations	Observations	Biological Ref. Interval	Unit
TARGET IN DM	-	80.00 - 130.00	mg/dl

BIOCHEMISTRY**LIPID PROFILE**

TOTAL CHOLESTROL	119.0	Desirable : - < 200 mg/dL Borderline: - 200 - 239 mg/dL High : - > 240mg/dL	mg/dl
TRIGLYCERIDES	129.0	35.00 - 160.00	mg/dl
HDL CHOLESTROL	28.0	42.00 - 88.00	mg/dl
LDL CHOLESTROL	65.2	< 130	mg/dl
VLDL	25.80	< 40	mg/dl
CHOLESTROL/ HDL RATIO	4.25	< 3.0 LOW RISK, 3.0-5.0 AVG RISK, > 5.0 HIGH RISK	ratio
LDL/HDL RATIO	2.33	< 3	ratio

LFT (LIVER FUNCTION TESTS)

TOTAL BILIRUBIN	0.47	0.00 - 1.20	mg/dl
DIRECT BILIRUBIN	0.23	0.00 - 0.30	
INDIRECT BILIRUBIN	0.24	0.20 - 0.70	mg/dl
SGOT	21.0	2.00 - 31.00	U/L
SGPT	29.0	10.00 - 45.00	U/L

Lab Technician

Umesh Kumar
Consulting Pathologist
DR. UMESH KUMAR
MBBS, MD (PATHOLOGIST)
MD, Reg Pathology

Timing : 24/7 hrs

This Report is not valid for medico legal purpose

Note: These tests have technical limitations. Clinico-pathological interpretation is necessary. In case of any disparity test may be repeated immediately.

Address : 36/44 FK Kabir Nagar, Durgakund, Varanasi - 221005

Email: dramishra@gmail.com, drpallaviojha@gmail.com Website: panaceahospital.org

Facilities:

All clinical Biomedical & Hematology Investigations including Bone Marrow Examination
 VPT, Podiascan & Complete Foot Care (First Time in Purvanchal)
 All Hormonal Investigation by Chemiluminescent Method
 Visceral Fat by (AB-140) Ambulatory BP Monitoring
 CGMS & Insulin Pump Available
 PFT, 2D-ECHO (Color Doppler), Holter, TMT, Cardiac-3 available
 VIA, VILI, Colposcopy available
 Special Endocrinological Investigation Protocols.

ISO 9001:2008 Certified
 Mobile: 9389994334, 9554572190, 9453837595



Panacea Pathology

Clinical Reference Lab

Persistence, Preparedness and Precision
 EQAS (CMC Vellore Attached) & IQAS System
 पूर्वांचल की सर्वोत्तम गुणवत्ता वाली पैथोलॉजी

UHID No :- UD-23240006502
Patient Name :- Mrs VARSHA PARJAPATI
Husband :- HARIOM PARJAPATI
Address :- D 37/88 A GODOWLIA BARDEO -221001, varanasi
Consultant :- Dr Pallavi Mishra (MBBS,MD)

Booking No/Date :- 37 / 29-Feb-2024 12:18 PM
Age/Sex :- 30 Y/F
OP No :- OP-23240019943
Mobile No :- 9616165393

Investigations	Observations	Biological Ref. Interval	Unit
ALKALINE PHOSPHATASE	73.0	25.00 - 140.00	U/L
TOTAL PROTIENS	7.3	6.60 - 8.70	g/dl
ALBUMIN	4.2	3.50 - 5.20	gm%
GLOBULIN	3.1	1.50 - 3.60	gms/dl
A/G RATIO	1.35	2:1	RATIO
RFT (RENAL FUNCTION TESTS)			
BLOOD UREA	24.0	10.00 - 50.00	mg/dl
SERUM CREATININE	0.77	0.60 - 1.60	mg/dl
URIC ACID	4.98	2.50 - 6.80	mg/dl

IMMUNOLOGY

THYROID PROFILE (T3,T4,TSH)

T3	1.06	0.60 - 1.81	ng/ml
T4	7.8	4.50 - 10.90	ug/dl
TSH	3.10	0.39 - 6.10	uIU/mL

PARASITOLOGY

STOOL ROUTINE

Lab Technician

Timing : 24/7 hrs

This Report is not valid for medico legal purpose

Consulting Pathologist
 DR. UMESH KUMAR
 MBBS, MD (PATHOLOGIST)
 MCh (Pathology)

Note: These tests have technical limitations. Clinico-pathological interpretation is necessary. In case of any disparity test may be repeated immediately.

Address : 36/44 FK Kabir Nagar, Durgakund, Varanasi - 221005

Email: dramishra@gmail.com, drpallaviojha@gmail.com Website: panaceahospital.org

Facilities:

All clinical Biomedical & Hematology Investigations including Bone Marrow Examination
 VPT, Podiascan & Complete Foot Care (First Time in Purvanchal)
 All Hormonal Investigation by Chemiluminescent Method
 Visceral Fat by (AB-140) Ambulatory BP Monitoring
 CGMS & Insulin Pump Available
 PFT, 2D-ECHO (Color Doppler), Holter, TMT, Cardiac-3 available
 VIA, VILI, Colposcopy available
 Special Endocrinological Investigation Protocols.

ISO 9001:2008 Certified

Mobile: 9389994334, 9554572190, 9453837595

**Panacea Pathology****Clinical Reference Lab**

Persistence, Preparedness and Precision
 EQAS (CMC Vellore Attached) & IQAS System
 पूर्वीचल की सर्वोत्तम गुणवत्ता वाली पैथोलॉजी

UHID No :- UD-23240006502 **Booking No/Date** :- 37 / 29-Feb-2024 12:18 PM
Patient Name :- Mrs VARSHA PARJAPATI **Age/Sex** :- 30 Y/F
Husband :- HARIOM PARJAPATI **OP No** :- OP-23240019943
Address :- D 37/88 A GODOWLIA BARDEO -221001 **Mobile No** :- 9616165393
 , varanasi
Consultant :- Dr Pallavi Mishra (MBBS,MD)

Investigations	Observations	Biological Ref. Interval	Unit
GROSS EXAMINATON			
COLOR <i>Methology</i>	YELLOW	CLEAR YELLOW	
CONSISTANCY	NORMAL		
BLOOD	ABSENT		
MUCUS	ABSENT		
MICROSCOPIC EXAMINATON			
OVA OR EGGS OF HELMINTHS	ABSENT		
CYST OF PROTOZOA	ABSENT		
PUS CELLS	04-05	2.00 - 3.00	/HPF
RBC <i>Methology / Carm</i>	NIL	3.50 - 4.50	million/cumm

* END OF REPORT *

Lab Technician

Timing : 24/7 hrs

This Report is not valid for medico legal purpose

Consulting Pathologist
 DR. UMESH KUMAR
 MBBS, MD (PATHOLOGIST)
 MCI Reg. No. 41413

Note: These tests have technical limitations. Clinico-pathological interpretation is necessary. In case of any disparity test may be repeated immediately.

Address : 36/44 FK Kabir Nagar, Durgakund, Varanasi – 221005

Email: dramishra@gmail.com, drpallaviojha@gmail.com Website: panaceahospital.org

Facilities:

All clinical Biomedical & Hematology Investigations including Bone Marrow Examination
 VPT, Podiascan & Complete Foot Care (First Time in Purvanchal)
 All Hormonal Investigation by Chemiluminescent Method
 Visceral Fat by (AB-140) Ambulatory BP Monitoring
 CGMS & Insulin Pump Available
 PFT, 2D-ECHO (Color Doppler), Holter, TMT, Cardiac-3 available
 VIA, VILI, Colposcopy available
 Special Endocrinological Investigation Protocols.

ISO 9001:2008 Certified

Mobile: 9389994334, 9554572190, 9453837595

**Panacea Pathology****Clinical Reference Lab**

Persistence, Preparedness and Precision
 EQAS (CMC Vellore Attached) & IQAS System
 पूर्वांचल की सर्वोत्तम गुणवत्ता वाली पैथोलॉजी

UHID No	:- UD-23240006502	Booking No/Date	:- 36 / 29-Feb-2024 12:18 PM
Patient Name	:- Mrs VARSHA PARJAPATI	Age/Sex	:- 30 Y/F
Husband	:- HARIOM PARJAPATI	OP No	:- OP-23240019943
Address	:- D 37/88 A GODOWLIA BARDEO -221001 varanasi	Mobile No	:- 9616165393
Consultant	:- Dr Pallavi Mishra (MBBS,MD)		

Investigations	Observations	Biological Ref. Interval	Unit
<u>BIOCHEMISTRY</u>			
BUN	12.0	7.00 - 21.00	mg/dl

* END OF REPORT *

Lab Technician

Timing : 24/7 hrs

This Report is not valid for medico legal purpose

Consulting Pathologist
 DR. UMESH KUMAR
 MBBS, MD (PATHOLOGIST)
 NCD Reg. No. 4143

Note: These tests have technical limitations. Clinico-pathological interpretation is necessary. In case of any disparity test may be repeated immediately.

Address : 36/44 FK Kabir Nagar, Durgakund, Varanasi – 221005

Email: dramishra@gmail.com, drpallaviojha@gmail.com Website: panaceahospital.org



PANACEA HOSPITAL



A shelter for many hearts A Home for many lives

(An ISO 9001:2008 Certified Organisation)

Lab Attached with CMC Under EQAS Scheme

Dept. of Radiodiagnosis - 32 Slice CT Scan, 3D/4D USG, 2D ECHO, Colour Doppler, Intervention Procedures, Digital X-Ray

NAME: VARSHA PRAJAPATI
REF.DR. DR.ASHUTOSH MISHRA(MD)

AGE/SEX: 30 YRS/FEMALE
DATE: 29/02/2024

ULTRA SOUND WHOLE ABDOMEN REPORT

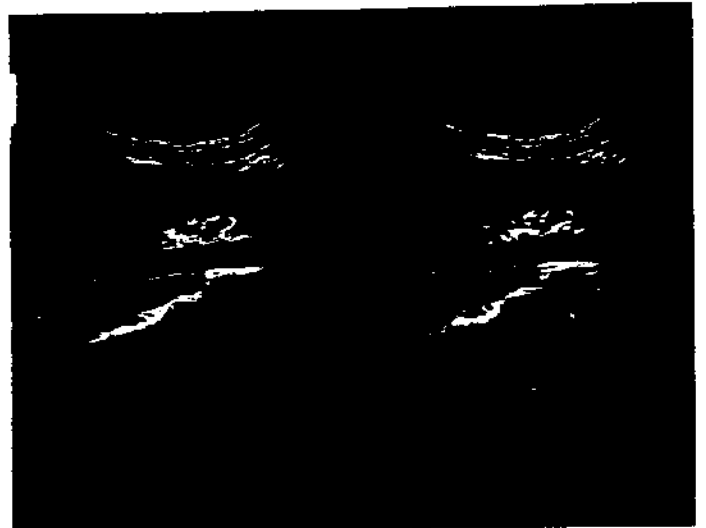
- Liver:** Normal in size, shape & echogenicity. Intra & extra hepatic biliary Radicals & Vascular structures are normal. Margins are smooth and regular.
- Gall bladder:** Normally distended with echo free lumen.
- Portal vein:** Normal in course and caliber.
- CBD diameter:** Visualized part normal in course & caliber.
- Pancreas:** Normal in size, shape & echogenicity. Margins are smooth & regular. No diffuse/ focal lesion seen. Pancreatic duct not visualized.
- Spleen:** Normal in size, shape & echogenicity. Margins are smooth & regular. No diffuse / focal lesion seen. Splenic vessels at hilum is normal.
- Kidney:** Both normal in size, shape echogenicity & position. Cortical-medullary differentiation is maintained. Pelvicalyceal system normal. No evidence of any calculus/mass lesion seen. No hydronephrosis/ hydroureter seen. No suprarenal mass lesion.
- Urinary bladder:** Normally distended with normal wall thickness. No echogenic foci lumen or diverticula seen. Both VUJ appears normal. No evidence of calculus / mass lesion seen.
- Uterus:** Uterus size and shape are normal Margins are smooth & regular. Endometrial thickness measures .
- Ovary:** Bilateral ovaries show normal size, and morphology.
- Others:** No free fluid in peritoneal cavity.
No free fluid in bilateral pleural cavity.
No evidence of significantly enlarged retroperitoneal/ mesenteric lymph nodes noted.
- IMPRESSION: -** **NO OBVIOUS SONOLOGICAL ABNORMALITY SEEN.**

Please correlate clinically and further investigations.


Radiologist
Dr. Rahul Kumar Tiwari
MBBS, MD (Radio Diagonosis)
Reg. No. 57557

Disclaimer: This report is not valid for Madicolegal or Judicial Purpose. Radiological diagnosis is solely interpretation of images produced by tissue & may not be always conclusive.

Address : B36/44 B4 Kabir Nagar (Near Sanjay Shiksha Niketan), Durgakund, Varanasi
Mobile : 9554572190 / 9453837595 / Recpn, 9389994334
Email : dramishra@gmail.com, drpallaviojha@gmail.com, Website : www.piire.org





Call Now - 1800-123-3070

PANACEA HOSPITAL



A shelter for many hearts A Home for many lives

(An ISO 9001:2008 Certified Organisation)
Lab Attached with CMC Under EQAS Scheme

Dept. of Radiodiagnosis - 32 Slice CT Scan, 3D/4D USG, 2D ECHO, Colour Doppler, Intervention Procedures, Digital X-Ray

PATIENT'S NAME	: VARSHA PRAJAPATI	AGE30Y/SEX:F 24Y
REF. BY	: Dr. ASHUTOSH MISHRA(MD)	DATE:29/02/2024

X-RAY CHEST (PA VIEW)

- Bilateral lung fields appear normal.
- Trachea and mediastinum appear normal in position.
- Both hila appear normal in size and are symmetrical.
- Transverse cardiac diameter is within normal limits.
- Great vessels appear normal
- Both CP angles appear clear. Normal position and contour diaphragms noted.
- Bony rib cage and soft tissue shadows appear normal.

IMPRESSION

- **No obvious abnormality noted in the chest radiograph.**

Thanks for reference.

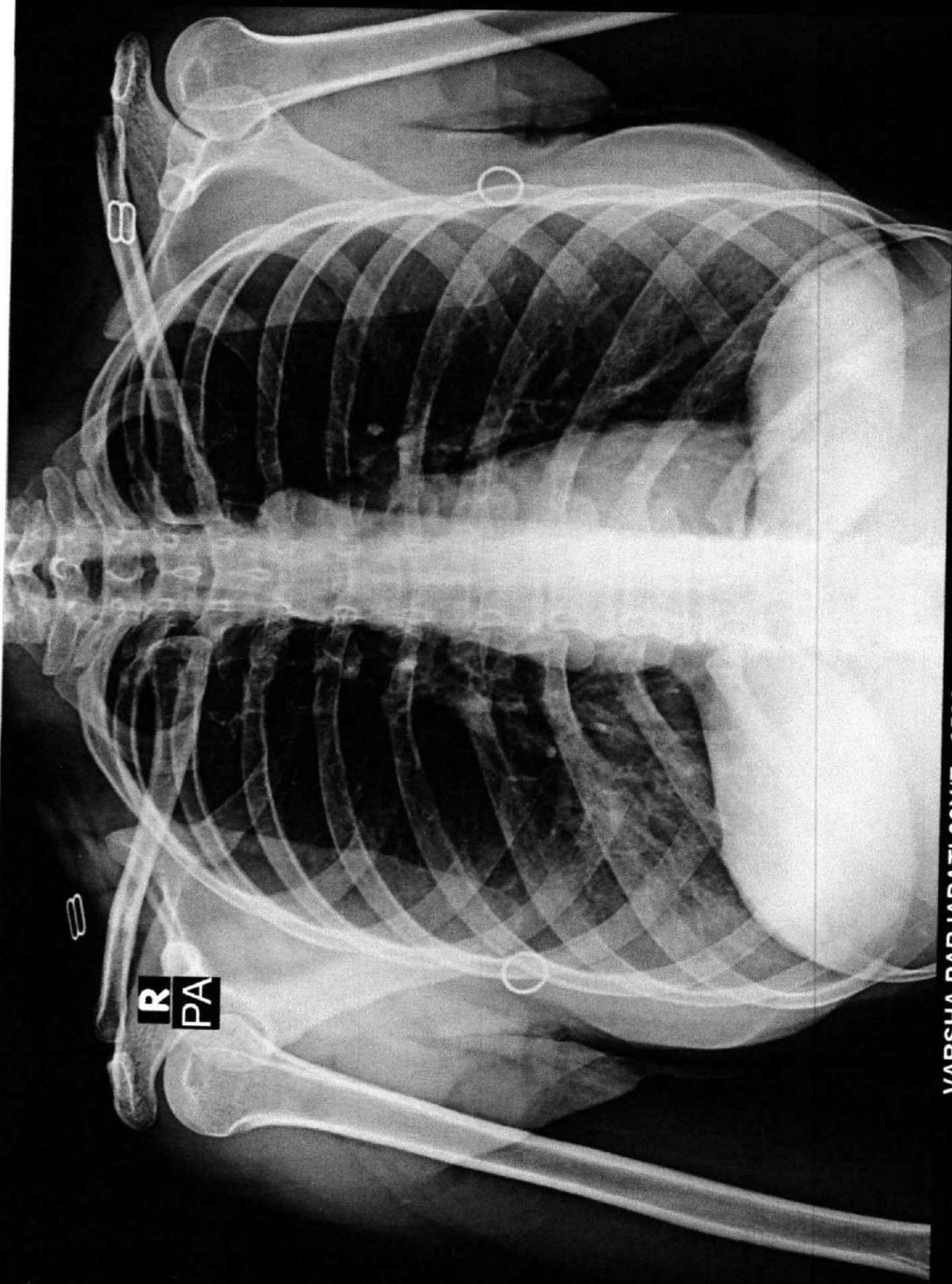
Radiologist
Dr. Ranjita Tiwari
MBBS, MD (Radio Diagonosis)
Reg. No. 57557

Disclaimer: This report is not valid for Madicolegal or Judicial Purpose. Radiological diagnosis is solely interpretation of images produced by tissue & may not be always conclusive.

Address : B36/44 B4 Kabir Nagar (Near Sanjay Shiksha Niketan), Durgakund, Varanasi

Mobile : 9554572190 / 9453837595 / Recpn, 9389994334

Email : dramishra@gmail.com, drpallaviojha@gmail.com, Website : www.piire.org



R
PA

VARSHA PARJAPATI 30Y/F 6502 F CHEST P.A. 29-Feb-24 11:51 AM

PANACEA HOSPITAL, KABIR NAGAR, DURGAKUND, VARANASI



Call Now - 1800-123-3070

PANACEA HOSPITAL



A shelter for many hearts A Home for many lives

(An ISO 9001:2008 Certified Organisation)
Lab Attached with CMC Under EQAS Scheme

Dept. of Radiodiagnosis - 32 Slice CT Scan, 3D/4D USG, 2D ECHO, Colour Doppler, Intervention Procedures, Digital X-Ray

PATIENT'S NAME : VARSHA PRAJAPATI

AGE/SEX: 30 Y/F

REF. BY : Dr. ASHUTOSH MISHRA (MD)

Thursday, February 29, 2024

Echo - Cardiography


MITRAL VALVE Doppler	AML - normal morphology MV Flow - E - 0.8 A-0.5 E/A=1.65	PML - normal morphology MVA - 3.0 cm ² Mitral Regurgitation - No
TRICUSPID VALVE Doppler	Normal TV Flow - No	Tricuspid Regurgitation - No
PULMONARY VALVE Doppler	Normal PV Flow - No	Pulmonary Regurgitation - No
AORTIC VALVE Doppler	Trileaflet-No AV Flow - no	Aortic Regurgitation - no
MEASUREMENT	Aorta - 22.8 (20-38) mm IVS ed - 8.6 (6-12) mm LVID ed - 30.8 (35-55) mm LVPW ed - 14.3 (6-12) mm OA - 7 (> 5) mm	LA - 26.3 (24-32) mm IVS es - 14.3 (6-12) mm LVID es - 21.1 (24-40) mm LVPW es - 18.8 (6-12) mm EPSS - 4 (< 9) mm

CONCLUSION

All cardiac chamber dimensions are WNL
No valvular abnormalities
Good LV systolic function present Modified Simpson's method (4C, 2C) (LVEF=61%)
No diastolic dysfunction present (E/A = 1.65)
No RWMA
No pericardial effusion
Intact IAS / IV
No PAH
No intra cardiac mass /thrombus /vegetation

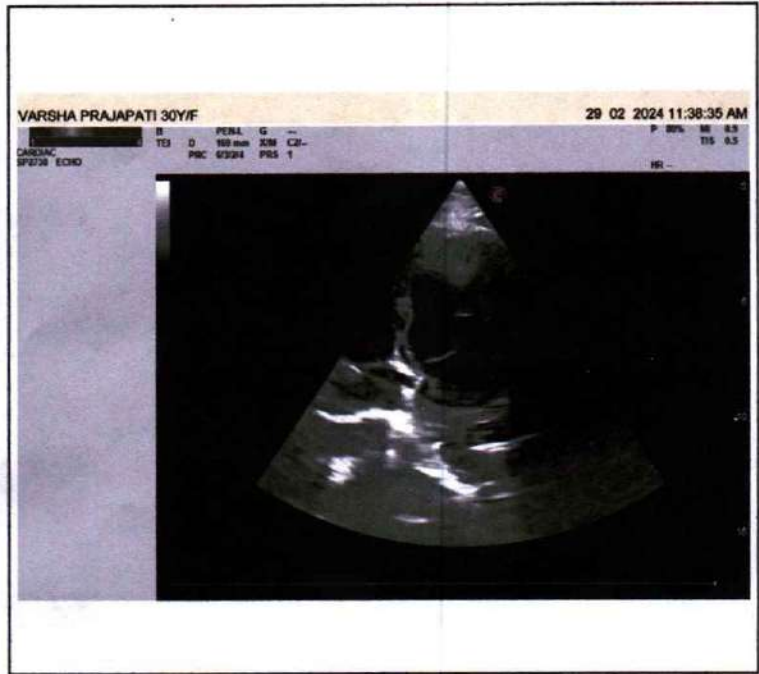
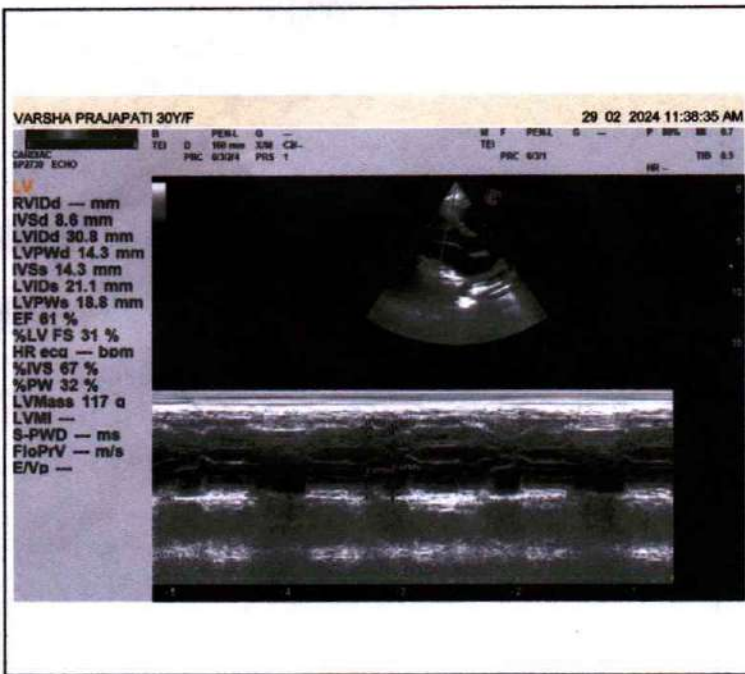
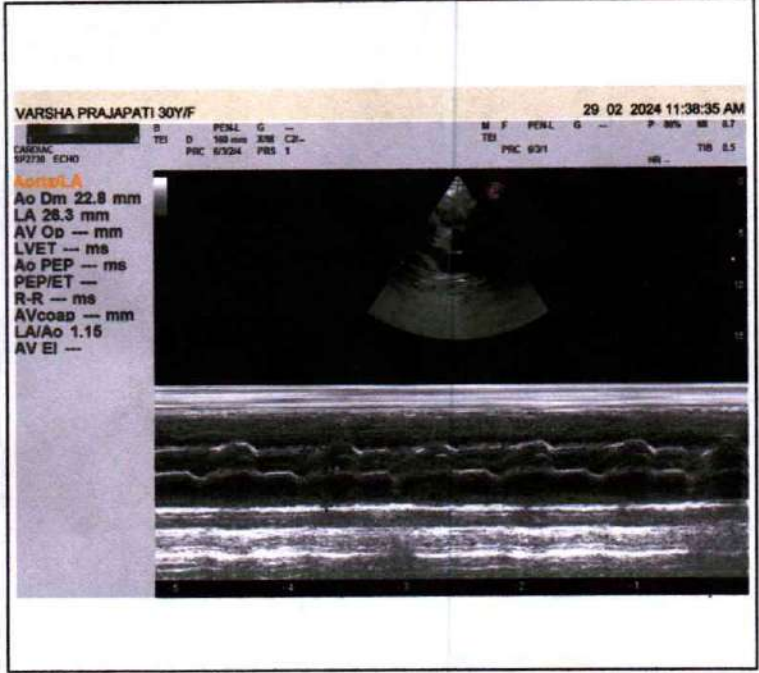
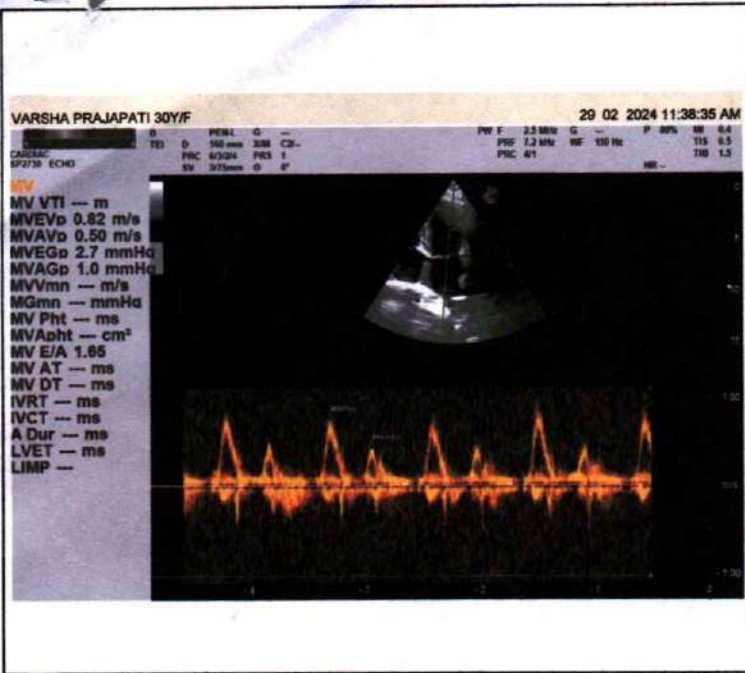IMPRESSION **Normal Echocardiogram**


Niraj Mishra
Physician Assistant
(PIIRE)


DR. Pallavi Misra
MBBS, MD(GENERAL MEDICINE)
MCI Reg. No. 52033
Women Cardiologist
Diabetocardiologist

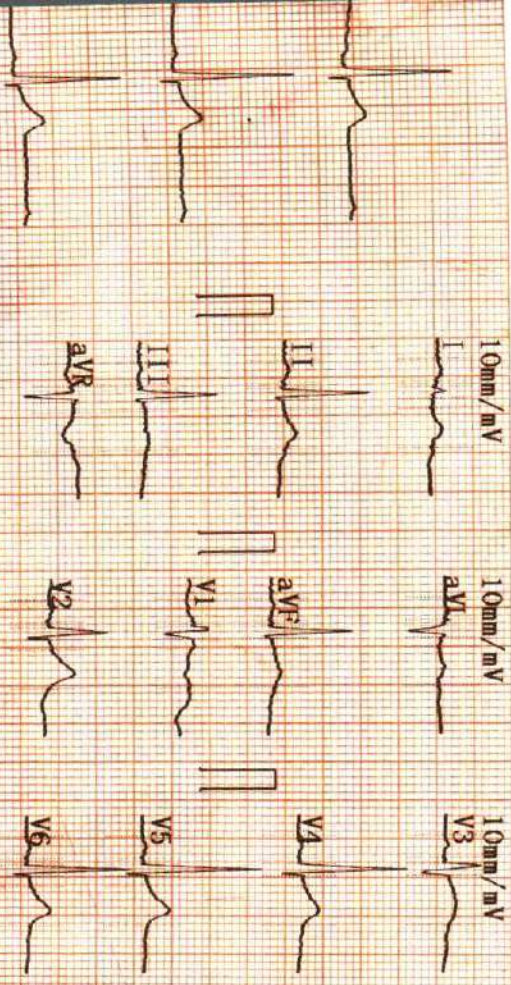
Disclaimer: This report is not valid for Madicolegal or Judicial Purpose. Radiological diagnosis is solely interpretation of images produced by tissue & may not be always conclusive.

Address : B36/44 B4 Kabir Nagar (Near Sanjay Shiksha Niketan), Durgakund, Varanasi
Mobile : 9554572190 / 9453837595 / Recpn, 9389994334
Email : dramishra@gmail.com, drpallaviojha@gmail.com, Website : www.piire.org



2024-02-29 12:13

<< Conclusions >>



ID :
 Name : **Varsha**
 Sex : **F.**
 Height : **152**
 SYS :
 DIA :
 HR : **75**
 PR Interval : **153**
 P Duration : **120**
 QRS Duration : **64**
 T Duration : **205**
 QT/QTc : **324/363**
 P/QRS/T Axis : **44.5/89.9/91.4**
 R(N5)/S(V1) : **1.55/0.38**
 R(V5)/S(V1) : **1.94**

Age : **30**
 Weight : **52 kg**
 Cardiac electric axis normal
 ST depression, mild high lateral myocardial ischemia.
 Report need physician confirm

DR. Parvathy Misra
 MBBS, MD(GENERAL MEDICINE)
 MCI Reg. No.52033

Physician

AUTO 10mm/mV

I

II

III

10mm/mV

aVR

aVL

aVF

10mm/mV

V1

V2

V3

10mm/mV

V4

V5

V6