



PANACEA HOSPITAL

B 36/44 F.K KABIR NAGAR, DURGAKUND
TOLLFREE NO-18001233070. Whatsapp No - 8795832852
www.piire.org
panaceaquery@gmail.com|panceahospital@gmail.com



OP Slip

Print Date : 13-Apr-2024 12:38PM



UHID No :- UD-24250000243	OP No :- OP-24250000886	OP Date :- 13 Apr 2024 12:37PM
Patient Name :- Mrs KALPANA PANDEY	Age/Sex :- 30 Y/Female	Mobile No :- 9953004111
Husband :- PRASHANT KUMAR	Department :- OPHTHALMOLOGY	
Pay Type :- Cr	Consultant :- Dr SANTOSH VERMA (MBBS,MS)	
Token No :- NOR. - 8	Paid :- 0.00	
Patient Type :- Normal		
Address :- SHUKLAPURA POST DARIYAPUR DHAMAR BHOJPUR,802156,BIHAR		

BP :- 90/60
 height :- 159
 Weight (kg) :- 46.6
 BMI :-
 SpO2 - 99
 PR - 77
 PEFr - 250
 CO2 - 78
 NE - 28
 CH - 78

Rx

< 6/9 - 6/6' ~~+~~
 6/6' M1 ~~+~~

Atmo Last BE. 2 yrs back
 BE - ant. segment: wNL
 BE - Central fundus: wNL

Adv

- Refraction
- Dilated fundus exam
- OCT (an) BE

Cap 2001E plus / esp / ody
 Q/R
 G. CUBSTONE ULTRA 135

Adv: R/L Refraction

Printed By : Mr Nitin Kumar Yadav
 Created By : Mr Nitin Kumar Yadav

Dr. SANTOSH VERMA
 MBBS, MS (Ophthalmologist)
 MCI Reg. No. 09-34327



PANACEA HOSPITAL

B 36/44 F.K KABIR NAGAR, DURGAKUND
TOLLFREE NO-18001233070. Whatsapp No - 8795832852
www.piire.org
panaceaquery@gmail.com|panceahospitalit@gmail.com



OP Slip

Print Date : 13-Apr-2024 12:01PM



UHID No :- UD-24250000243	OP No :- OP-24250000845	OP Date :- 13 Apr 2024 10:56AM
Patient Name :- Mrs KALPANA PANDEY	Age/Sex :- 30 Y/Female	Mobile No :- 9953004111
Husband :- PRASHANT KUMAR	Department :- GENERAL MEDICINE	
Pay Type :- Cr	Consultant :- Dr Pallavi Mishra (MBBS,MD,MBBS)	
Token No :- NOR. - 4	Paid/Bal :- 0.00 /1030.00	
Patient Type :- Normal		
Address :- SHUKLAPURA POST DARIYAPUR DHAMAR BHOJPUR,802156,BIHAR		

BP :- 90/60
 height :- 159
 Weight (kg) :- 46.6
 BMI :-
 SpO2 - 99
 PR - 77
 PFER - 250
 WC - 78
 NC - 28
 CH - 78

Rx

Δ COPD.
Anemias.

R

Rotabel - Atmar 100 250 6
 Cap. Metformin 250 6
 Tan Montmor 100

~~ADJ
 Se 250 1 DEC
 PPT
 R~~

[Signature]
 DR. Pallavi Misra
 MBBS, MD(GENERAL MEDICINE)
 MCI Reg. No.52033

Printed By : Mr Nitin Kumar Yadav
 Created By : Mr Nitin Kumar Yadav



PANACEA HOSPITAL

B 36/44 F.K KABIR NAGAR, DURGAKUND
TOLLFREE NO-18001233070. Whatsapp No - 8795832852
www.piire.org
panaceaquery@gmail.com|panceahospitalit@gmail.com



OP Slip

Print Date : 13-Apr-2024 12:36PM



UHID No :- UD-24250000243	OP No :- OP-24250000883	OP Date :- 13 Apr 2024 12:36PM
Patient Name :- Mrs KALPANA PANDEY	Age/Sex :- 30 Y/Female	Mobile No :- 9953004111
Husband :- PRASHANT KUMAR	Department :- DENTAL	
Pay Type :- Cr	Consultant :- Dr SHRUTI MISHRA (AA)	
Token No :- NOR. - 6	Paid :- 0.00	
Patient Type :- Normal		
Address :- SHUKLAPURA POST DARIYAPUR DHAMAR BHOJPUR,802156,BIHAR		

BP :- 90/60
 height :- 139
 Weight (kg) :- 46.6
 BMI :-
 SpO2 - 99
 PR - 77
 PEFr - 250
 Wc - 78
 Mc - 28
 CH - 78

Rx C.C. ⇒ patient came for routine dental check up.
 O/E ⇒ stain/calculus ⇒ ++/+++
 P/O ⇒ chronic gen gingivitis.
 T/A ⇒ Scaling & polishing

Shruti
Dr. SHRUTI MISHRA
 BDS, (DENTIST)
 MCI Reg. No. (A-09784)

Printed By : Mr Nitin Kumar Yadav
 Created By : Mr Nitin Kumar Yadav



PANACEA HOSPITAL

B 36/44 F.K KABIR NAGAR, DURGAKUND
TOLLFREE NO-18001233070. Whatsapp No - 8795832852
www.piire.org
panaceaquery@gmail.com|panceahospital@gmail.com



OP Slip

Print Date : 13-Apr-2024 12:37PM



UHID No :- UD-24250000243	OP No :- OP-24250000884	OP Date :- 13 Apr 2024 12:36PM
Patient Name :- Mrs KALPANA PANDEY	Age/Sex :- 30 Y/Female	Mobile No :- 9953004111
Husband :- PRASHANT KUMAR	Department :- DERMATOLOGY	
Pay Type :- Cr	Consultant :- Dr DR ASHUTOSH MISHRA (MBBS,MD)	
Token No :- NOR. - 6	Paid :- 0.00	
Patient Type :- Normal		
Address :- SHUKLAPURA POST DARIYAPUR DHAMAR BHOJPUR,802156,BIHAR		

BP :- 90/60
 height :- 159
 Weight (kg) :- 46.6
 BMI :-
 SpO2 - 99
 PR - 77
 PEFR - 250
 WC - 78
 NE - 28
 CH - 78

Rx

1st visit

3rd day

Rx

- Hydrell cream C!
- mandre family face wash C!
- minoxidil 5% sol C!
- ketoclear soap ATD
- Hair serum → B/w ATD



Printed By : Mr Nitin Kumar Yadav
Created By : Mr Nitin Kumar Yadav



PANACEA HOSPITAL

B 36/44 F.K KABIR NAGAR, DURGAKUND
TOLLFREE NO-18001233070. Whatsapp No - 8795832852
www.piire.org
panaceaquery@gmail.com|panceahospitalit@gmail.com



OP Slip

Print Date : 13-Apr-2024 12:37PM



UHID No	:- UD-24250000243	OP No	:- OP-24250000885	OP Date	:- 13 Apr 2024 12:37PM
Patient Name	:- Mrs KALPANA PANDEY	Age/Sex	:- 30 Y/Female	Mobile No	:- 9953004111
Husband	:- PRASHANT KUMAR	Department	:- OBST. & GYNAECOLOGY		
Pay Type	:- Cr	Consultant	:- Dr VANDANA SINGH (MBBS,MS)		
Token No	:- NOR. - 4	Paid	:- 0.00		
Patient Type	:- Normal				
Address	:- SHUKLAPURA POST DARIYAPUR DHAMAR BHOJPUR,802156,BIHAR				

BP :- 90/60
 height :- 159
 Weight (kg) :- 46.6
 BMI :-
 SpO2 - 99
 PR - 77
 PFER - 230
 WC - 78
 NC - 28
 CH - 78

Rx
 Gp → generalized weakness

hb - 8.3
 LMP - 3/4/24
 P1H0 L1 - 2nd try. NVD ♀.

adu - Pap smear.

HbA1c - 5.5 - Tab Insulin XT 1 x BD x 30d.

- Tab calcium 1 x OD x 30d.

- Arcal O3 1 x weekly x 8 weeks.

- Nutrimix 2Tg x OD x milks.

Printed By : Mr Nitin Kumar Yadav
 Created By : Mr Nitin Kumar Yadav

DR. VANDANA SINGH Page 1 of 1
 MBBS, DGO. (OBST & GYN)
 ICI REG. NO. 43474

Facilities:

All clinical Biomedical & Hematology Investigations including Bone Marrow Examination
 VPT, Podiascan & Complete Foot Care (First Time in Purvanchal)
 All Hormonal Investigation by Chemiluminescent Method
 Visceral Fat by (AB-140) Ambulatory BP Monitoring
 CGMS & Insulin Pump Available
 PFT, 2D-ECHO (Color Doppler), Holter, TMT, Cardiac-3 available
 ViA, VILI, Colposcopy available
 Special Endocrinological Investigation Protocols.

ISO 9001:2008 Certified

Mobile: 9389994334, 9554572190, 9453837595



Panacea Pathology

Clinical Reference Lab

Persistence, Preparedness and Precision
 EQAS (CMC Vellore Attached) & IQAS System
 पूर्वांचल की सर्वोत्तम गुणवत्ता वाली पैथोलॉजी

UHID No	-- UD-24250000243	Booking No/Date	-- 46 / 13-Apr-2024 12:51 PM
Patient Name	-- Mrs KALPANA PANDEY	Age/Sex	-- 30 Y/F
Husband	-- PRASHANT KUMAR	OP No	-- OP-24250000845
Address	-- SHUKLAPURA POST DARIYAPUR DHAMAR BHOJPUR,802156 , BIHAR	Mobile No	-- 9953004111
Consultant	-- Dr Pallavi Mishra (MBBS,MD)		

Investigations	Observations	Biological Ref. Interval	Unit
HAEMATOLOGY			
CBC			
HAEMOGLOBIN <i>DefaultMethod / test Machine</i>	8.3	12.50 - 15.00	gm/dl
TLC <i>Methology / Carm</i>	4,500	4000.00 - 11000.00	Cells/cumm.
DLC DIFFERENTIAL LEUCOCYTE COUNT			
NEUTROPHILS	63	40.00 - 75.00	%
LYMPHOCYTES	32	20.00 - 45.00	%
EOSINOPHILS	02	1.00 - 6.00	%
MONOCYTES	03	2.00 - 10.00	%
BASOPHILS	00	<1-2	%
PLATELET COUNT	2.03	1.50 - 4.10	lacs /cumm
PCV	29.2	33.00 - 42.00	%
RBC <i>Methology / Carm</i>	3.83	3.50 - 4.50	million/cumm
MCV(MEAN CELL VOLUME)	76.1	83.00 - 101.00	fl
MCH(MEAN CELL HAEMOGLOBIN)	21.6	27.00 - 32.00	pg
MCHC	28.4	31.50 - 35.00	gm%
RDW-CV	15.0	11.00 - 16.00	%
RDW-SD	46.1	37.00 - 57.00	fl

Lab Technician

Timing : 24/7 hrs

This Report is not valid for medico legal purpose

Consulting Pathologist

Dr. Umesh Kumar
 DR. UMESH KUMAR
 MBBS,MD (PATHOLOGIST)

MCI Reg. No. 41413

Note: These tests have technical limitations. Clinico-pathological interpretation is necessary. In case of any disparity test may be repeated immediately.

Address : 36/44 FK Kabir Nagar, Durgakund, Varanasi - 221005

Email: dramishra@gmail.com, drpallaviojha@gmail.com Website: panaceahospital.org

Facilities:

All clinical Biomedical & Hematology Investigations including Bone Marrow Examination
 VPT, Podiascan & Complete Foot Care (First Time in Purvanchal)
 All Hormonal Investigation by Chemiluminescent Method
 Visceral Fat by (AB-140) Ambulatory BP Monitoring
 CGMS & Insulin Pump Available
 PFT, 2D-ECHO (Color Doppler), Holter, TMT, Cardiac-3 available
 VIA, VILI, Colposcopy available
 Special Endocrinological Investigation Protocols.

ISO 9001:2008 Certified

Mobile: 9389994334, 9554572190, 9453837595

**Panacea Pathology****Clinical Reference Lab**

Persistence, Preparedness and Precision
 EQAS (CMC Vellore Attached) & IQAS System
 पूर्वांचल की सर्वोत्तम गुणवत्ता वाली पैथोलॉजी

UHID No :- UD-24250000243 **Booking No/Date** :- 46 / 13-Apr-2024 12:51 PM
Patient Name :- Mrs KALPANA PANDEY **Age/Sex** :- 30 Y/F
Husband :- PRASHANT KUMAR **OP No** :- OP-24250000845
Address :- SHUKLAPURA POST DARIYAPUR DHAMAR BHOJPUR,802156 , BIHAR **Mobile No** :- 9953004111
Consultant :- Dr Pallavi Mishra (MBBS,MD)

Investigations	Observations	Biological Ref. Interval	Unit
<u>URINE EXAMINATION</u>			
URINE ROUTINE EXAMINATION			
<u>PHYSICAL EXAMINATION</u>			
QUANTITY	25		ml
COLOR <i>Methodology</i>	STRAW	CLEAR YELLOW	
APPEARANCE <i>DefaultMethod</i>	CLEAR	CLEAR	
<u>CHEMICAL EXAMINATION</u>			
SPECIFIC GRAVITY	1.020	1.01 - 1.03	
PH	5.5	4.60 - 8.00	
GLUCOSE	NIL	60.00 - 100.00	mg/dl
PROTEIN-	NIL		
<u>MICROSCOPIC EXAMINATION</u>			
PUS CELLS	01-02	2.00 - 3.00	/HPF
RBCS (RED BLOOD CELLS)	NIL	3.50 - 4.50	/HPF
EPITHELIAL CELLS	NIL		/HPF
CASTS	ABSENT	ABSENT	
CRYSTALS	ABSENT	ABSENT	

Consulting Pathologist

Dr. Umesh Kumar

M.D., Pathology

Lab Technician

Timing : 24/7 hrs

This Report is not valid for medico legal purpose

Note: These tests have technical limitations. Clinico-pathological interpretation is necessary. In case of any disparity test may be repeated immediately.

Address : 36/44 FK Kabir Nagar, Durgakund, Varanasi – 221005

Email: dramishra@gmail.com, drpallaviojha@gmail.com Website: panaceahospital.org

Facilities:

All clinical Biomedical & Hematology Investigations including Bone Marrow Examination
 VPT, Podiascan & Complete Foot Care (First Time in Purvanchal)
 All Hormonal Investigation by Chemiluminescent Method
 Visceral Fat by (AB-140) Ambulatory BP Monitoring
 CGMS & Insulin Pump Available
 PFT, 2D-ECHO (Color Doppler), Holter, TMT, Cardiac-3 available
 ViA, ViLi, Colposcopy available
 Special Endocrinological Investigation Protocols.

ISO 9001:2008 Certified

Mobile: 9389994334, 9554572190, 9453837595



Panacea Pathology

Clinical Reference Lab

Persistence, Preparedness and Precision
 EQAS (CMC Vellore Attached) & IQAS System
 पूर्वांचल की सर्वोत्तम गुणवत्ता वाली पैथोलॉजी

UHID No	:- UD-24250000243	Booking No/Date	:- 46 / 13-Apr-2024 12:51 PM
Patient Name	:- Mrs KALPANA PANDEY	Age/Sex	:- 30 Y/F
Husband	:- PRASHANT KUMAR	OP No	:- OP-24250000845
Address	:- SHUKLAPURA POST DARIYAPUR DHAMAR BHOJPUR, 802156, BIHAR	Mobile No	:- 9953004111
Consultant	:- Dr Pallavi Mishra (MBBS,MD)		

Investigations	Observations	Biological Ref. Interval	Unit
----------------	--------------	--------------------------	------

HAEMATOLOGY

ESR	42.0	0.00 - 20.00	mm at 1 hr
BLOOD GROUP ABO & RH FACTOR			
BLOOD GROUP	"A"		
RH FACTOR	POSITIVE		
HBA1C -(BY GOLD STANDARD METHOD :HPLC)	5.5	Normal: 4.0 - 5.4 Prediabetic : 5.5 -6.3 Diabetes mellitus := 6.4	%

BIOCHEMISTRY**BLOOD SUGAR FASTING**

GLUCOSE	95.0	60.00 - 100.00	mg/dl
PRE-DIABETICS(IMPAIRED FASTING TOLER)	-	100.00 - 125.00	mg/dl
DIABETICS	-	upto 126	mg/dl
TARGET IN DM	-	80.00 - 130.00	mg/dl

BIOCHEMISTRY**PPBS(POST PRANDIAL BLOOD SUGAR)**

POST PRANDIAL BLOOD GLUCOSE(2 HR AFTER MEAL)	121.0	110.00 - 150	mg/dl
IGT(2 HR 75GM GLUCOSE)	-	140.00 - 199.00	mg/dl
DIABETES	-	upto200	mg/dl

Consulting Pathologist

Dr. Umesh Kumar
 DR. UMESH KUMAR
 MBBS,MD (PATHOLOGIST)
 MCI Reg. No. 41413

Lab Technician

Timing : 24/7 hrs

This Report is not valid for medico legal purpose

Note: These tests have technical limitations. Clinico-pathological interpretation is necessary. In case of any disparity test may be repeated immediately.

Address : 36/44 FK Kabir Nagar, Durgakund, Varanasi - 221005

Email: dramishra@gmail.com, drpallaviojha@gmail.com Website: panaceahospital.org

Facilities:

All clinical Biomedical & Hematology Investigations including Bone Marrow Examination
 VPT, Podiascan & Complete Foot Care (First Time in Purvanchal)
 All Hormonal Investigation by Chemiluminescent Method
 Visceral Fat by (AB-140) Ambulatory BP Monitoring
 CGMS & Insulin Pump Available
 PFT, 2D-ECHO (Color Doppler), Holter, TMT, Cardiac-3 available
 VIA, VILI, Colposcopy available
 Special Endocrinological Investigation Protocols.

ISO 9001:2008 Certified

Mobile: 9389994334, 9554572190, 9453837595

**Panacea Pathology****Clinical Reference Lab**

Persistence, Preparedness and Precision
 EQAS (CMC Vellore Attached) & IQAS System
 पूर्वांचल की सर्वोत्तम गुणवत्ता वाली पैथोलॉजी

UHID No :- UD-24250000243 **Booking No/Date** :- 46 / 13-Apr-2024 12:51 PM
Patient Name :- Mrs KALPANA PANDEY **Age/Sex** :- 30 Y/F
Husband :- PRASHANT KUMAR **OP No** :- OP-24250000845
Address :- SHUKLAPURA POST DARIYAPUR DHAMAR BHOJPUR, 802156, BIHAR **Mobile No** :- 9953004111
Consultant :- Dr Pallavi Mishra (MBBS,MD)

Investigations	Observations	Biological Ref. Interval	Unit
TARGET IN DM	-	80.00 - 130.00	mg/dl
BIOCHEMISTRY			
LFT (LIVER FUNCTION TESTS)			
TOTAL BILIRUBIN	0.62	0.00 - 1.20	mg/dl
DIRECT BILIRUBIN	0.22	0.00 - 0.30	
INDIRECT BILIRUBIN	0.40	0.20 - 0.70	mg/dl
SGOT	21.0	2.00 - 31.00	U/L
SGPT	25.0	10.00 - 45.00	U/L
ALKALINE PHOSPHATASE	68.0	25.00 - 140.00	U/L
TOTAL PROTIENS	7.2	6.60 - 8.70	g/dl
ALBUMIN	4.0	3.50 - 5.20	gm%
GLOBULIN	3.2	1.50 - 3.60	gms/dl
A/G RATIO	1.25	2:1	RATIO
RFT (RENAL FUNCTION TESTS)			
SERUM CREATININE	0.67	0.60 - 1.60	mg/dl
URIC ACID	3.76	2.50 - 6.80	mg/dl

LIPID PROFILE

Lab Technician

Timing : 24/7 hrs

Consulting Pathologist

Dr. Umesh Kumar
 DR. UMESH KUMAR
 MBBS, MD (PATHOLOGIST)
 MCI Reg. No. 41413

This Report is not valid for medico legal purpose

Note: These tests have technical limitations. Clinico-pathological interpretation is necessary. In case of any disparity test may be repeated immediately.

Address : 36/44 FK Kabir Nagar, Durgakund, Varanasi - 221005

Email: dramishra@gmail.com, drpallaviojha@gmail.com Website: panaceahospital.org

Facilities:

All clinical Biomedical & Hematology Investigations including Bone Marrow Examination
VPT, Podiascan & Complete Foot Care (First Time in Purvanchal)
All Hormonal Investigation by Chemiluminescent Method
Visceral Fat by (AB-140) Ambulatory BP Monitoring
CGMS & Insulin Pump Available
PFT, 2D-ECHO (Color Doppler), Holter, TMT, Cardiac-3 available
VIA, VILI, Colposcopy available
Special Endocrinological Investigation Protocols.

ISO 9001:2008 Certified

Mobile: 9389994334, 9554572190, 9453837595

**Panacea Pathology****Clinical Reference Lab**

Persistence, Preparedness and Precision
EQAS (CMC Vellore Attached) & IQAS System
पूर्वांचल की सर्वोत्तम गुणवत्ता वाली पैथोलॉजी

UHID No :- UD-24250000243 **Booking No/Date** :- 46 / 13-Apr-2024 12:51 PM
Patient Name :- Mrs KALPANA PANDEY **Age/Sex** :- 30 Y/F
Husband :- PRASHANT KUMAR **OP No** :- OP-24250000845
Address :- SHUKLAPURA POST DARIYAPUR
DHAMAR BHOJPUR,802156 , BIHAR **Mobile No** :- 9953004111
Consultant :- Dr Pallavi Mishra (MBBS,MD)

Investigations	Observations	Biological Ref. Interval	Unit
TOTAL CHOLESTROL	138.0	Desirable : - < 200 mg/dL Borderline: - 200 - 239 mg/dL High : - > 240mg/dL	mg/dl
TRIGLYCERIDES	142.0	35.00 - 160.00	mg/dl
HDL CHOLESTROL	39.0	42.00 - 88.00	mg/dl
LDL CHOLESTROL	70.6	<130	mg/dl
VLDL	28.40	<40	mg/dl
CHOLESTROL/ HDL RATIO	3.54	<3.0 LOW RISK, 3.0-5.0 AVG RISK, >5.0 HIGH RISK	ratio
LDL/HDL RATIO	1.81	<3	ratio
YGGT	16.0	10.00 - 50.00	U/L

IMMUNOLOGY**THYROID PROFILE (T3,T4,TSH)**

T3	1.01	0.60 - 1.81	ng/ml
T4	7.6	4.50 - 10.90	ug/dl
TSH	2.15	0.39 - 6.10	uIU/mL

* END OF REPORT *

Consulting Pathologist

DR. UMESH KUMAR
MBBS, MD (PATHOLOGIST),
M.D. Pathology
MCI Reg. No. 41413

Lab Technician

Timing : 24/7 hrs

This Report is not valid for medico legal purpose

Note: These tests have technical limitations. Clinico-pathological interpretation is necessary. In case of any disparity test may be repeated immediately.

Address : 36/44 FK Kabir Nagar, Durgakund, Varanasi - 221005

Email: dramishra@gmail.com, drpallaviojha@gmail.com Website: panaceahospital.org

Facilities:

All clinical Biomedical & Hematology Investigations including Bone Marrow Examination
 VPT, Podiascan & Complete Foot Care (First Time in Purvanchal)
 All Hormonal Investigation by Chemiluminescent Method
 Visceral Fat by (AB-140) Ambulatory BP Monitoring
 CGMS & Insulin Pump Available
 PFT, 2D-ECHO (Color Doppler), Holter, TMT, Cardiac-3 available
 VIA, VILI, Colposcopy available
 Special Endocrinological Investigation Protocols.

ISO 9001:2008 Certified

Mobile: 9389994334, 9554572190, 9453837595



Panacea Pathology

Clinical Reference Lab

Persistence, Preparedness and Precision
 EQAS (CMC Vellore Attached) & IQAS System
 पूर्वांचल की सर्वोत्तम गुणवत्ता वाली पैथोलॉजी

UHID No	:- UD-24250000243	Booking No/Date	:- 20 / 14-Apr-2024 11:51 AM
Patient Name	:- Mrs KALPANA PANDEY	Age/Sex	:- 30 Y/F
Husband	:- PRASHANT KUMAR	OP No	:- OP-24250000845
Address	:- SHUKLAPURA POST DARIYAPUR DHAMAR BHOJPUR, 802156, BIHAR	Mobile No	:- 9953004111
Consultant	:- Dr Pallavi Mishra (MBBS,MD)		

Investigations	Observations	Biological Ref. Interval	Unit
BIOCHEMISTRY			
BUN	8.0	7.00 - 21.00	mg/dl

* END OF REPORT *

Consulting Pathologist

DR. UMESH KUMAR
 MBBS, MD (Pathology) (DIPLOMA IN CLINICAL PATHOLOGY)
 MCI Reg. No. 41413

Lab Technician

Timing : 24/7 hrs

This Report is not valid for medico legal purpose

Note: These tests have technical limitations. Clinico-pathological interpretation is necessary. In case of any disparity test may be repeated immediately.

Address : 36/44 FK Kabir Nagar, Durgakund, Varanasi – 221005

Email: dramishra@gmail.com, drpallaviojha@gmail.com Website: panaceahospital.org



PANACEA HOSPITAL

Call Now - 1800-123-3070



A shelter for many hearts A Home for many lives

(An ISO 9001:2008 Certified Organisation)
Lab Attached with CMC Under EQAS Scheme

Dept. of Radiodiagnosis - 32 Slice CT Scan, 3D/4D USG, 2D ECHO, Colour Doppler, Intervention Procedures, Digital X-Ray

NAME: KALPANA PANDEY
REF.DR.ASHUTOSH MISHRA(MD)

AGE/SEX: 30 YRS/FEMALE
DATE: 13/04/2024

ULTRA SOUND WHOLE ABDOMEN REPORT

Liver: Normal in size (108mm), shape & echogenicity. Intra & extra hepatic biliary Radicals & Vascular structures are normal. Margins are smooth and regular.

Gall bladder: Normally distended with echo free lumen.

Portal vein: Normal in course and caliber.

CBD diameter: Visualized part normal in course & caliber.

Pancreas: Normal in size, shape & echogenicity. Margins are smooth & regular. No diffuse/ focal lesion seen. Pancreatic duct not visualized.

Spleen: Normal in size, shape & echogenicity. Margins are smooth & regular.
No diffuse / focal lesion seen. Splenic vessels at hilum is normal.

Kidney: Both normal in size, shape echogenicity & position. Cortical-medullary differentiation is maintained. Pelvicalyceal system normal. No evidence of any calculus/mass lesion seen
No hydronephrosis/ hydroureter seen. No suprarenal mass lesion.

Urinary bladder: Normally distended with normal wall thickness. No echogenic foci lumen or diverticula seen.
Both VUJ appears normal. No evidence of calculus / mass lesion seen.

Uterus: Uterus is normal in size, Margins are smooth & regular.
Endometrial thickness measures.

Ovary: Bilateral ovaries show normal size and morphology.

Others: No free fluid in peritoneal cavity.
No free fluid in bilateral pleural cavity.
No evidence of significantly enlarged retroperitoneal/ mesenteric lymph nodes noted.

IMPRESSION: - **NO OBVIOUS SONOLOGICAL ABNORMALITY SEEN.**

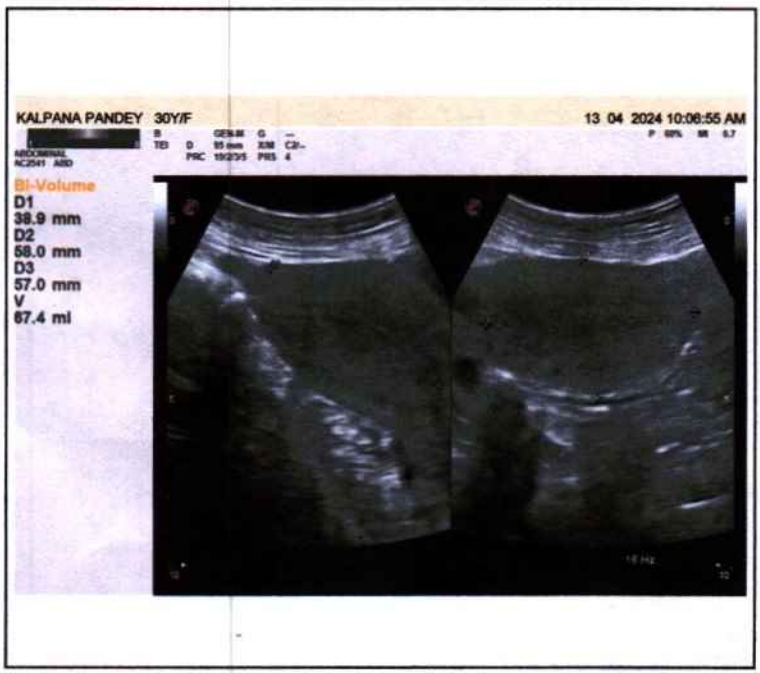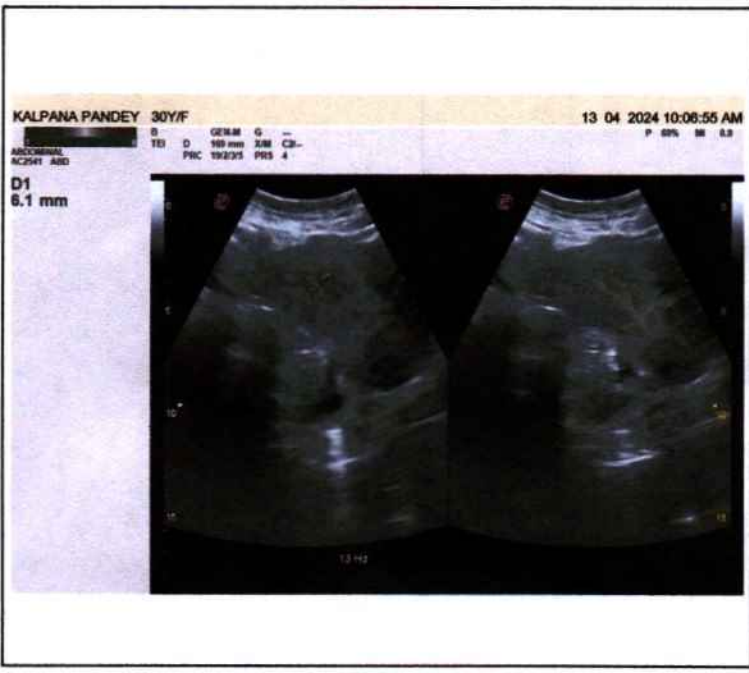
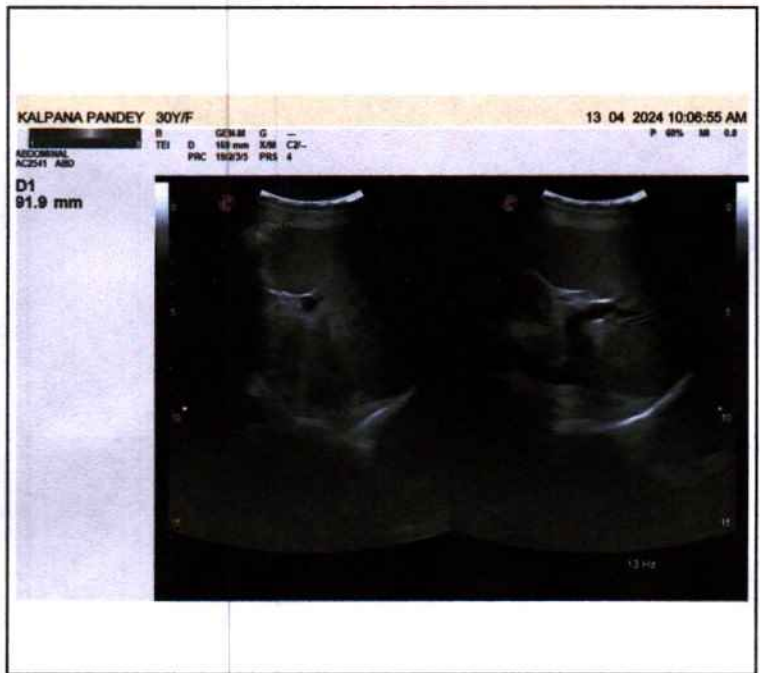
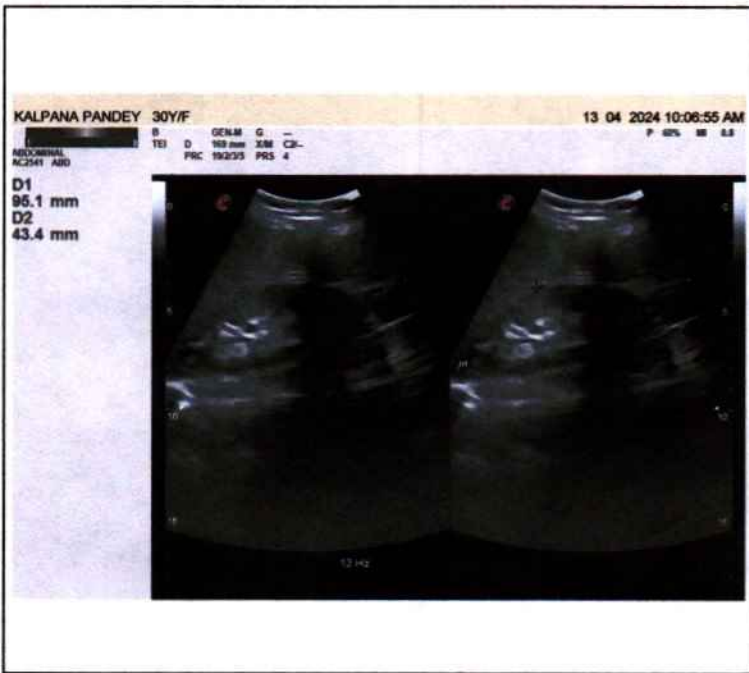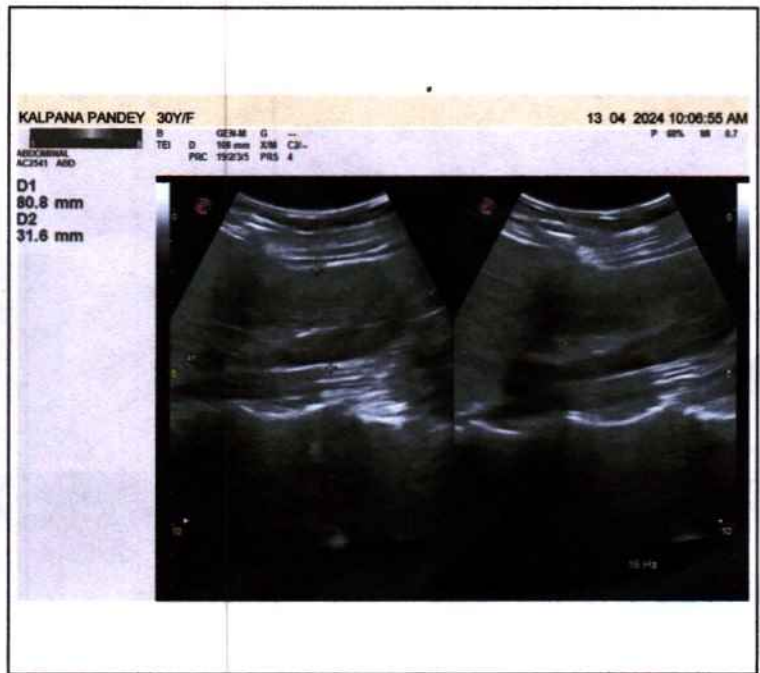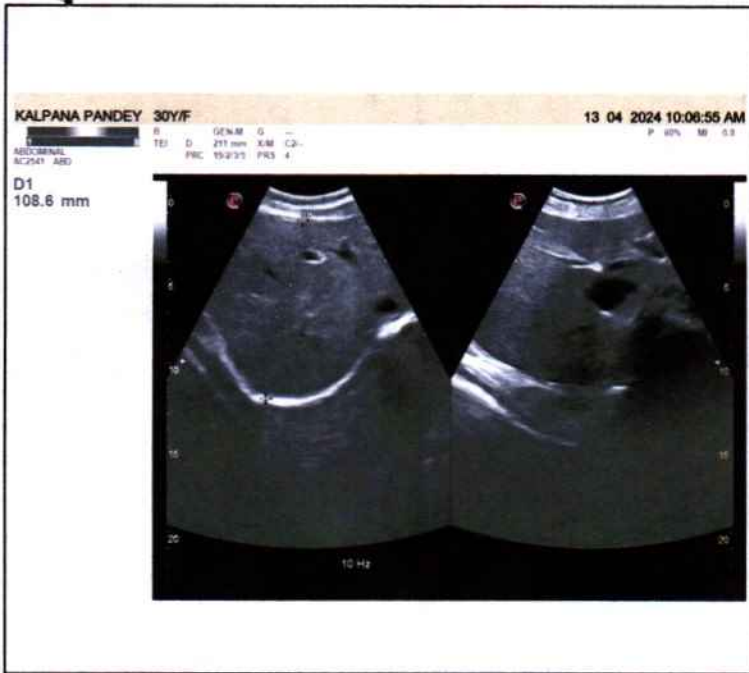Please correlate clinically and further investigations.

Sonologist


Dr. Bahul Kumar Tiwan
MBBS, MD (Radio Diagonosis)
Reg. No. 57557

Disclaimer: This report is not valid for Madicolegal or Judicial Purpose. Radiological diagnosis is solely interpretation of images produced by tissue & may not be always conclusive.

Address : B36/44 B4 Kabir Nagar (Near Sanjay Shiksha Niketan), Durgakund, Varanasi
Mobile : 9554572190 / 9453837595 / Recpn, 9389994334
Email : dramishra@gmail.com, drpallaviojha@gmail.com, Website : www.piiire.org





Call Now - 1800-123-3070

PANACEA HOSPITAL



A shelter for many hearts A Home for many lives

(An ISO 9001:2008 Certified Organisation)
Lab Attached with CMC Under EQAS Scheme

Dept. of Radiodiagnosis - 32 Slice CT Scan, 3D/4D USG, 2D ECHO, Colour Doppler, Intervention Procedures, Digital X-Ray

PATIENT'S NAME : KALPANA PANDEY

AGE/SEX:30Y/F

REF. BY : Dr. ASHUTOSH MISHRA(MD)

DATE 13-04-2024

X-RAY CHEST (AP VIEW)

- Lung fields show hazy opacities in both parahilar, basal zone with mild prominent brochopulmonary markings findings suggestive of MILD BRONCHITIS.
- Rest visualized lung fields appear normal.
- Trachea appear normal in position and course.
- Bony rib cage and soft tissue shadows appear normal.

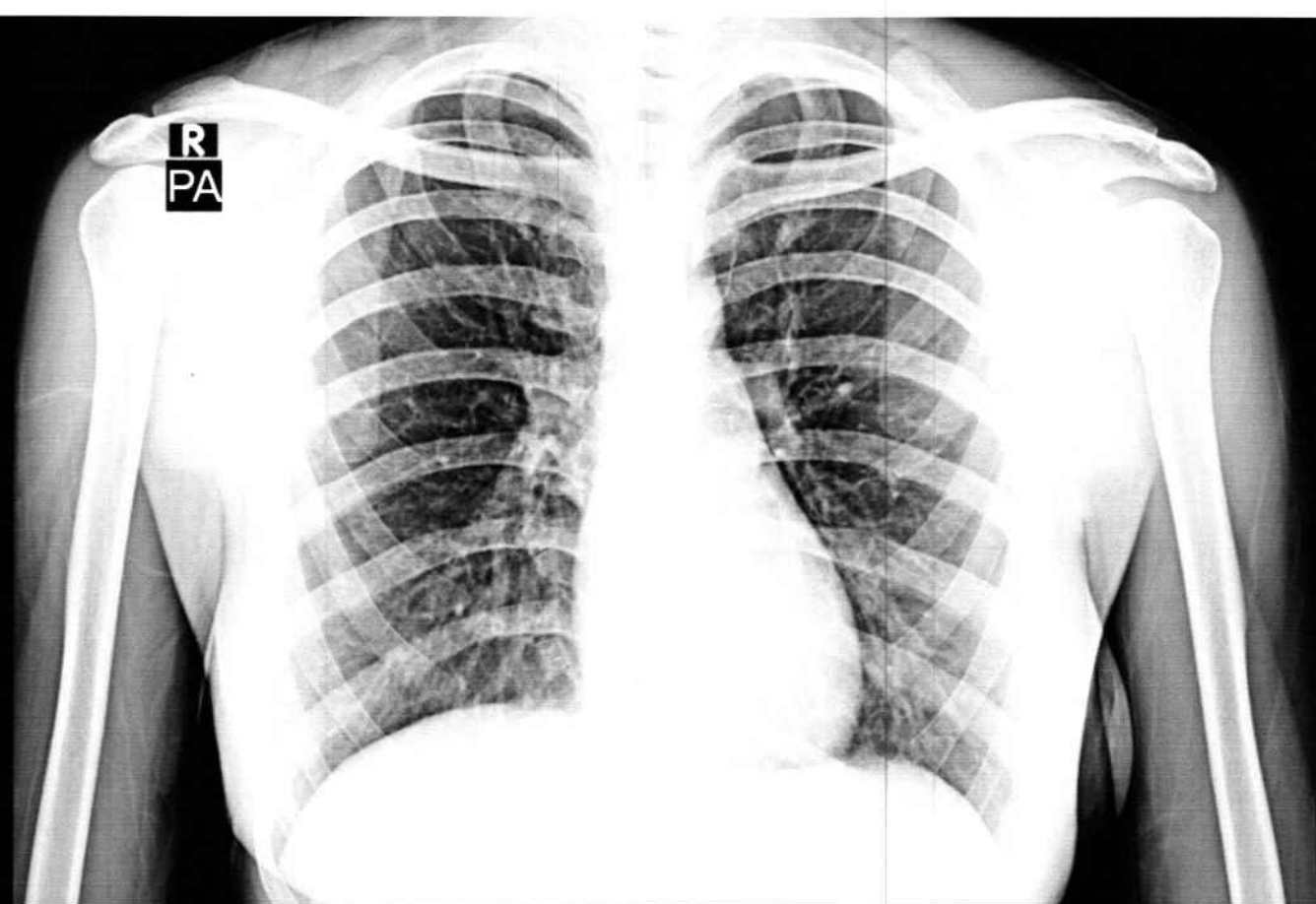
Thanks for reference.

Radiologist

Dr. Rahul Kumar Tiwan
MBBS, MD (Radio Diagonosis)
Reg. No. 57557

Disclaimer: This report is not valid for Madicolegal or Judicial Purpose. Radiological diagnosis is solely interpretation of images produced by tissue & may not be always conclusive.

Address : B36/44 B4 Kabir Nagar (Near Sanjay Shiksha Niketan), Durgakund, Varanasi
Mobile : 9554572190 / 9453837595 / Recpn, 9389994334
Email : dramishra@gmail.com, drpallaviojha@gmail.com, Website : www.piire.org



KALPANA PANDEY 30Y/F 0243 F CHEST P.A. 13-Apr-24 10:29 AM

PANACEA HOSPITAL, KABIR NAGAR, DURGAKUND, VARANASI



PANACEA HOSPITAL



A shelter for many hearts A Home for many lives

(An ISO 9001:2008 Certified Organisation)
Lab Attached with CMC Under EQAS Scheme

Dept. of Radiodiagnosis - 32 Slice CT Scan, 3D/4D USG, 2D ECHO, Colour Doppler, Intervention Procedures, Digital X-Ray

NAME: MRS.KALPANA PANDEY
REF BY: DR. ASHUTOSH MISHRA (MD)

AGE/SEX: 30 YRS / FEMALE
DATE: 13/04/2024

Echo - Cardiography

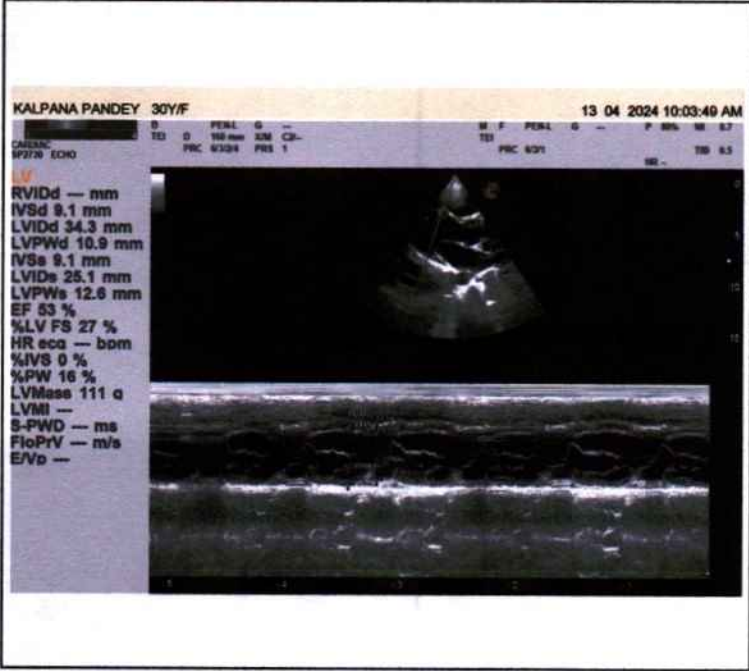
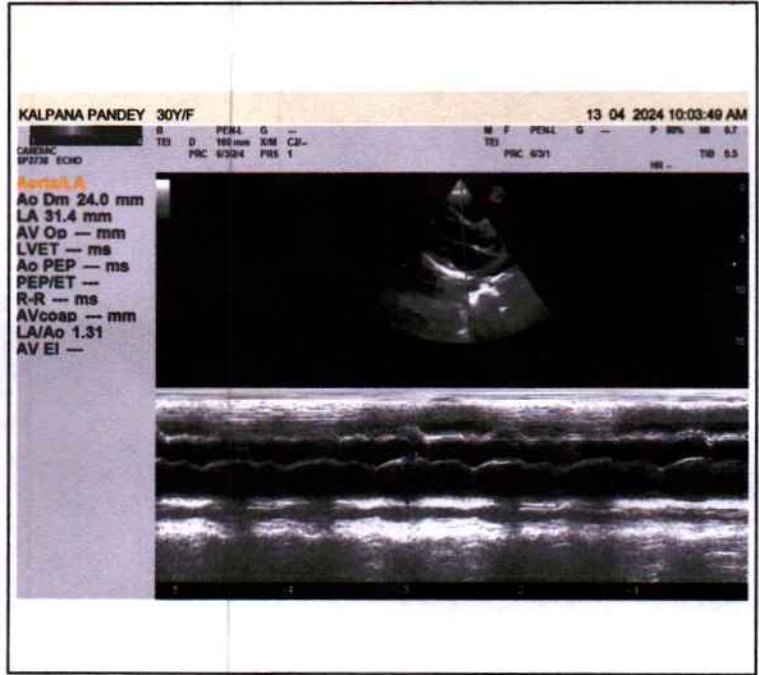
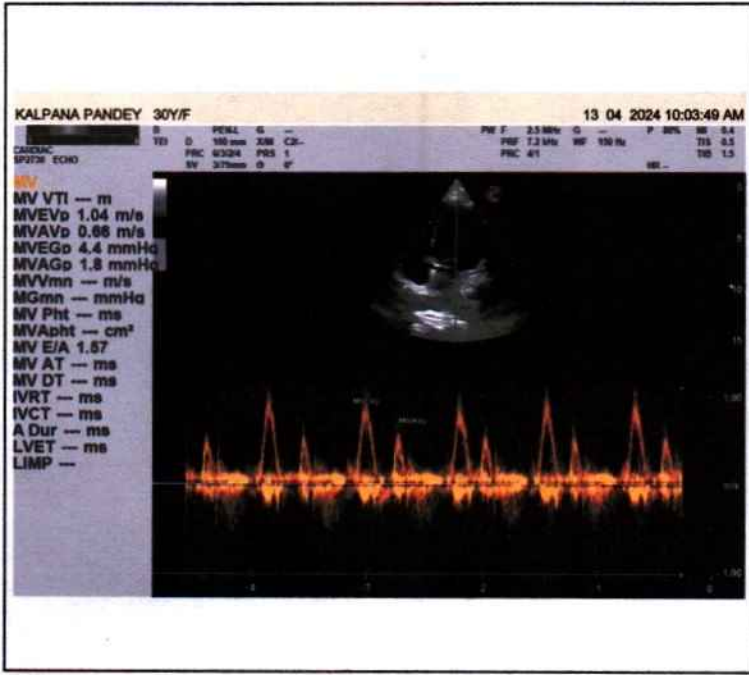
MITRAL VALVE Doppler	AML - normal morphology MV Flow - E - 1.0 A-0.6 E/A=1.57	PML - normal morphology MVA - 3.0 cm ² Mitral Regurgitation - No
TRICUSPID VALVE Doppler	Normal TV Flow -No	Tricuspid Regurgitation -No
PULMONARY VALVE Doppler	Normal PV Flow -No	Pulmonary Regurgitation - No
AORTIC VALVE Doppler	Trileaflet- No AV Flow - no	Aortic Regurgitation - No
MEASUREMENT	Aorta - 24.0 (20-38) mm IVS ed - 9.1 (6 -12) mm LVID ed - 34.3 (35 - 55) mm LVPW ed - 9.1 (6 -12) mm OA - 7 (> 5) mm	LA -31.4 (24-32) mm IVS es -9.1 (6 - 12) mm LVID es - 25.1 (24 - 40) mm LVPW es - 12.6 (6 -12) mm EPSS - 5 (< 9) mm

CONCLUSION All cardiac chamber dimensions are WNL
No valvular abnormalities
Good LV systolic dysfunction present Modified Simpson's method (4C, 2C) (LVEF-53%)
No diastolic dysfunction present (E/A = 1.57)
No RWMA
No pericardial effusion
Intact IAS / IV
No PAH
No intra cardiac mass /thrombus /vegetation

IMPRESSION **Normal Echocardiogram**

Niraj Mishra
Physician Assistant
(PIIRE)


Dr. Pallavi Mishra
MBBS, MD (MED) Lucknow
Echocardiography Specialist
Non-invasive cardiologist
Women Cardiologist
Diabetocardiologist
MBBS MD GENERAL MEDICINE
MCI Reg No: 92033



AUTO 10mm/mV

10mm/mV

10mm/mV

10mm/mV

I

aVR

V1

V4

II

aVL

V2

V5

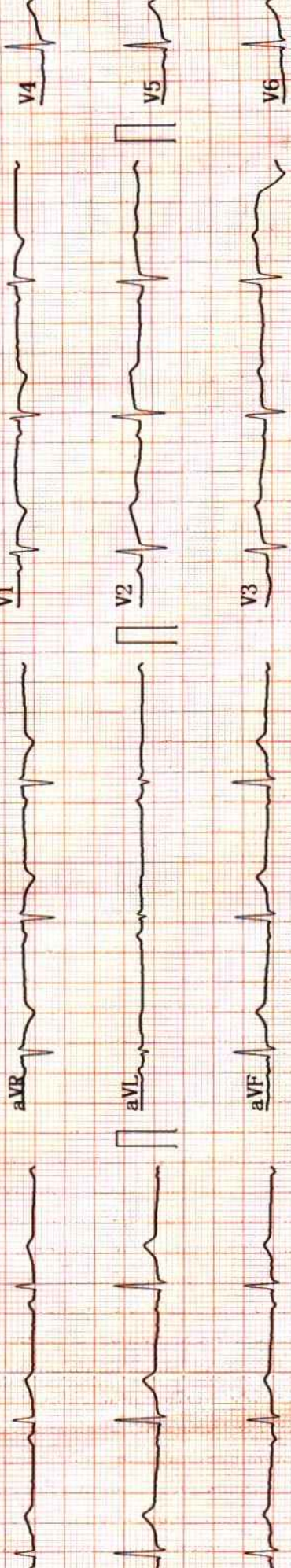
III

aVF

V3

V6

25mm/s AC50Hz+EMG35Hz+DFT



10mm/mV

10mm/mV

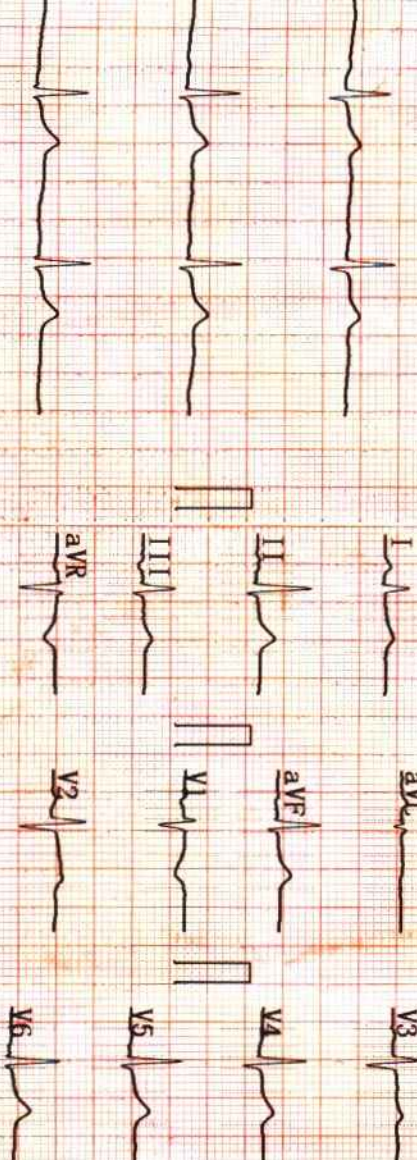
10mm/mV

1970-01-01 23:38

<< Conclusions >>

Cardiac electric axis normal;

Report need physician confirm



ID :
 Name : **Kolpana Pandey**
 Sex : **F**
 Height : **152**
 SYS :
 DIA :
 HR [bpm] : 66
 PR Interval [ms] : 155
 P Duration [ms] : 99
 QRS Duration [ms] : 68
 T Duration [ms] : 172
 QT/QTc [ms] : 368/386
 P/QRS/T Axis [deg] : 1.7/59.9/57.7
 R(V5)/S(V1) [mV] : 0.68/0.32
 R(V5)+S(V1) [mV] : 1.00

Age : **30**
 Weight : **46.6kg**

Physician
DR. Pankaj Misra
 MBBS, MD(GENERAL MEDICINE)
 MCI Reg. No.52033