



PARKLINE DIAGNOSTICS PVT. LTD.

L.G. 3, 4 & 5, Bhuvana Towers, S.D. Road, Secunderabad - 500 003.
Tel : +91 40-2784 5852, 6649 1787, 7995421787, 7093445852, Fax : +91 40 2784 7864
Email parklinediagnostics@gmail.com www.parklinediagnostics.com



NABL Accredited
Certificate No.MC-2566

MEDICAL EXAMINATION REPORT

Name	MS. GOKA Ashwini		Date :	12/03/2022		
Company	C/O: Mediwheel		Reg. No. :	1868622		
Contact No.	9626222515		Sex	<input checked="" type="checkbox"/> F	Age :	<input type="checkbox"/> 34
Type	Pre-Emp		Emp. No.:	114876		
	Overseas		Height	154 cm		
	Annual	<input checked="" type="checkbox"/>	Weight	59 kgs.		
Remarks	- Slightly raised ESR levels Advice follow up. - Advised to improve Hb. levels.					
				DR. PRIYANKA SANNIDHI MBBS Regn. No: 11351		
Fitness Status	Medically Fit / Unfit		Physician's Signature			

COMPREHENSIVE MEDICAL EXAMINATION REPORT

NAME MRS. GOKA Aishwari
AGE 34 Yr.
MARITAL STATUS Married CHILDREN: M F
IDENTIFICATION (IF ANY) A mole on the chest

PAST HISTORY

Any family H/o : High Blood Pressure, Heart Disease, Tuberculosis, Diabetes, Asthma, Cancer
 Father Typhoid NIL Jaundice NIL Pancreatitis Etc. NIL
Any personal H/o Major illness like :
Any H/o STD..... Skin infection.....
H/o Blood Transfusion..... NIL Recent Vaccination..... Covid 19 - 2 doses
H/o Epilepsy..... Giddiness..... NIL
H/o Surgery..... Tubectomy 2008 Fracture in the past..... NIL
(2) Ovarian cyst 2015
Any Personal H/O.

High Blood Pressure, Heart Disease, Tuberculosis, Diabetes, Asthma, Cancer

Drug Abuse, Drug Allergy, Micturition, Bowels, Alcohol, Smoking, Sleep, MC, Wt. Loss/Wt. Gain

Present illness / Medication NIL.

GENERAL EXAMINATION

Conjunctiva : NAD
Skin : NAD
Ears :
Nose :
Throat & Oral Cavity :

Bone, Joints : NAD
Nutritional Status : well non-ed
Lymph Nodes : N.P.
Edema Feet : NIL
Varicose Veins :

Distance Vision : Near Vision :

Right Eye: _____

With glasses / Without glasses

Left Eye : _____

with glasses / without glasses

Right Eye: _____

With glasses / Without glasses

Left Eye : _____

with glasses / without glasses

Colour Vision :

Ophthalmologist's Signature

Right Ear

Left Ear

Hearing :

(N)

(N)

Rinne's Test ;

Weber Test :

Discharge :

NIL

NIL

SYSTEMIC EXAMINATION

Pulse :

80 bpm

B.P. : 110 / 70

Lungs :

A. Shape of Chest

B. Breath Sounds +

C. Adventitious Sounds NIL

Bil. Symmetrical.

Heart :

A. Sounds

B. Murmurs

*S1 S2
NIL*

Nervous System

Abdomen : A. Liver

B. Spleen

C. Piles

D. Any Lump

LNR

NIL

A. Higher Function :

B. Cranial Nerves :

C. Sensory System :

D. Motor System :

E. Jerks :

(N)

General :

A. Hernia

B. Hydrocele

C. Varicocele

NIL

—

—

Breast :

Rt

Lt.

CANDIDATE'S DECLARATION

I hereby solemnly declare that I am not suffering from Asthma, Hypertension, Diabetes, Occult Psychological disorders or any other ailment which can be suppressed without my voluntary declaration.

Date :

G. Ashwin
Signature

Place :

Note : General Physical Examination and Investigation included in the health check-up Have certain limitations and may not be able to detect all latent and asymptomatic diseases. Any new symptoms developing after the health check-up or persisting thereafter should be brought to the attention of the treating physician.

ARKLINE DIAGNOSTICS PVT. LTD.

L.G. 3, 4 & 5, Bhuvana Towers, S.D. Road, Secunderabad - 500 003. Tel : +91 40-2784 5852, 6649 1787, 7995421787,
7093445852, Fax : +91 40 2784 7864 Email parklinediagnostics@gmail.com www.parklinediagnostics.com



NABL Accredited
Certificate No.MC-2566

ENT CONSULTATION

S.No. 1868677

Emp.No.

Date 12/3

Name MS. Goka Ashwini

Age 34 Yrs

Sex M/F

	Right	Left
EARS :		— do.
EAC	: Patent no Cerumen.	— do.
TM	: Intact, readily visible.	
TFT	: Cone of light (+)	
	: Rinne (+ve)	Rinne's +ve.
	: Weber's Central	
NOSE	: Septum (N)	Bilateral sinuses (N) Prox. (N) routed
THROAT	: Oropharynx (N)	Bilateral tonsils (N) moving b.l.
NECK	: (N)	
IMPRESSION:	ENT clinically NAD	

[Handwritten Signature]

Signature



Phone: 27844043
66339096

SECUNDERABAD DENTAL HOSPITAL

CENTRE FOR ADVANCED DENTAL CARE

12/3/22

ORAL & MAXILLOFACIAL SURGEONS

Dr. Kazim Himathi M.D.S.

Dr. Gautam Dendukuri

FDSRCS (Eng), FFDRCS (Ire),
FFDRCS (OMFS), (Ire)

PISTHODONTIST

Dr. Chandrakanth Reddy M.D.S.

ENDODONTIST

Dr. Ram Narayan Reddy M.D.S.

ORTHODONTIST

Dr. Rajesh Reddy M.D.S., M.Orth RCS.

Dr. Sudeep Bhalerao M.D.S.

PERIODONTIST

Dr. Veerendranath Reddy M.D.S.

PEDODONTIST

Dr. Soumya M.D.S.

Dr. Mounika M.D.S.

DENTAL SURGEONS

Dr. N. Jagadish Rao B.D.S.

Dr. Baisakhi Saha B.D.S.

Mrs. Goka Ashvini
34y/F

Patient has come for a ~~general~~ ^{regular}
dental check-up


O/E

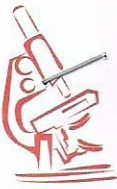1. Calculus +
2. Stains +

Treatment Plan

1. Adv. full mouth scaling.

Samp





PARKLINE DIAGNOSTICS PVT. LTD.

L.G. 3, 4 & 5, Bhuvana Towers, Sarojini Devi Road, Secunderabad - 500 003 Tel. +91 40-2784 5852
6649 1787 Fax :+91 40 2784 7864 Email : parklinediagnostics@gmail.com www.parklinediagnostics.com



NABL Accredited
Certificate No. MC-2566

TEST REPORT

Name : Ms . GOKA ASHWINI [114876]
Age / Gender : 34 Years / Female
Ref.By : Medi Wheel
Req. No : BIL1868677

TID : UMR0739423
Registered on : 12-Mar-2022 09:25 AM
Reported On : 13-Mar-2022 09:05 AM

ABDOMINO-PELVIC ULTRASONOGRAPHY

LIVER is normal shape, size (12.0 cms) and has uniform echopattern.
No evidence of focal lesion or intrahepatic biliary ductal dilatation.
Hepatic and portal vein radicals are normal.

GALL BLADDER shows normal shape and has clear contents.
Gall bladder wall is of normal thickness.
CBD is of normal calibre.

PANCREAS has normal shape, size and uniform echopattern.
No evidence of ductal dilatation or calcification.

SPLEEN shows normal shape, size and echopattern.

KIDNEYS move well with respiration and have normal shape, size and echopattern.
Cortico- medullary differentiations are well made out.
No evidence of calculus or hydronephrosis.
Right kidney measures: 9.2 x 4.0 cms, Left kidney measures: 10.0 x 4.6 cms.

URINARY BLADDER shows normal shape and wall thickness.
It has clear contents. No evidence of diverticula.

UTERUS is anteverted has normal shape and size.
It has uniform myometrial echopattern.
Endometrial echo is of normal thickness 5.2 mm.
Uterus measures 6.9 x 4.3 x 3.1 cms.


OVARIES are normal in size, shape and echotexture.
Right ovary: 2.3 x 2.1 cms, Left ovary: 3.0 x 2.2 cms.

No evidence of free fluid in the abdomen and pelvis.

IMPRESSION:

* No sonographic abnormality detected.

Suggested clinical correlation and follow up


Dr. Abid Yazden
Consultant Radiologist

The Test marked with * are not accredited by NABL

Lab Timings (Weekdays) : 7.00 am to 8.30 pm
Sundays & Holidays : 7.00 am to 1.00 pm

Radiologists Timings (Weekdays) : 7.30 am to 1.30 pm
& 5.30 pm to 7.45 pm
Sundays & Holidays : 7.30 am to 9.30 am

Page: 1 of 1

Free Home Visit for Sample Collection.

Call : 7995421787, 7093445852, 8121147282, 9885202212



PARKLINE DIAGNOSTICS PVT. LTD.

L.G. 3, 4 & 5, Bhuvana Towers, Sarojini Devi Road, Secunderabad - 500 003 Tel. +91 40-2784 5852
6649 1787 Fax : +91 40 2784 7864 Email : parklinediagnostics@gmail.com www.parklinediagnostics.com



NABL Accredited
Certificate No. MC-2566

TEST REPORT

Name : Ms . GOKA ASHWINI [114876]
Age / Gender : 34 Years / Female
Ref.By : Medi Wheel
Req. No : BIL1868677

TID : UMR0739423
Registered on : 12-Mar-2022 09:25 AM
Reported On : 13-Mar-2022 11:50 AM

X-RAY CHEST PA VIEW

Lung fields are clear.

Cardia is normal.


Hila are normal.

C P angles are free.

Bony cage is normal.

Soft tissues are normal.

IMPRESSION : NORMAL CHEST X-RAY


Dr. D.J. MOHAN
MD DMRD
(Reg No. 8995)
Consultant Radiologist

The Test marked with*are not accredited by NABL

Lab Timings (Weekdays) : 7.00 am to 8.30 pm

Sundays & Holidays : 7.00 am to 1.00 pm

Radiologists Timings (Weekdays) : 7.30 am to 1.30 pm

Sundays & Holidays

Page: 1 of 1

& 5.30 pm to 7.45 pm

: 7.30 am to 9.30 am

Free Home Visit for Sample Collection.

Call : 7995421787, 7093445852, 8121147282, 9885202212

PATIENT SUMMARY REPORT

PARKLINE DIAGNOSTICS PVT.LTD

ID : 1868677
NAME : **MS GOKA ASHWINI**
AGE / SEX : 34 / FEMALE

HEIGHT (cm) : 154
WEIGHT (kg) : 59
PROTOCOL : BRUCE

REF. BY : MEDIWHEEL
DONE BY : DR NAVEEN KUMAR C
TECHNICIAN : G.M.SURESH

CASE HISTORY :
MEDICATION :
OBJECT OF TEST : Routine Check Up.
RISK FACTOR : None.
ACTIVITY : Very Active.
OTHER INVESTIGATION : ECG
REASON FOR TERMINATION : THR ACHIEVED
EXERCISE TOLERANCE : Moderate (< 10 METS). *8 METS*
EXERCISE INDUCED ARRHYTHMIAS : No.
HAEMO RESPONSE : Normal.
CHRONO RESPONSE : Normal.
FINAL IMPRESSION :
EXTRA COMMENTS : *Negative for inducible ischemia*

BPL-DYNATRAC

Dr. NAVEEN KUMAR .C
M.D., D.M.
Consultant Cardiologist
Reg. No. 52291

Confirmed By : _____

Signature

ID: 1868677

12-03-2022 10:15:40 AM

CARDIART

MS.GOKA ASHWINI

Female 34Years

incomplete RBBB

Dr. NAVEEN KUMAR .C
M.D., D.M.
Consultant Cardiologist
Reg. No: 52291

HR : 75 bpm
P : 92 ms
PR : 121 ms
QRS : 85 ms
QT/QTc : 372/417 ms
P:QRS/T : 55/26/30 °
RV5/SV1 : 1.581/0.637 mV

Diagnosis Information:
Sinus Rhythm
Poor R Wave Progression(V2)

Report Confirmed by: