

भारत सरकार
आधार  
Government of India



Sheenki Sharma  
 Date of Birth/DOB: 01/09/1987  
 Female/ FEMALE


2147 9814 5002

VID : 9146 4467 0407 7654


मेरा आधार, मेरी पहचान

*Handwritten signature*

*Handwritten initials*  
**KAPIL HOSPITAL**  
 Near New Courts,  
 Civil Lines, Jalandhar


भारतीय विधिपट्ट पहचान अधिकरण
आधार  
Unique Identification Authority of India

**Address:**  
 W/O: Pankej Kumar, House No - 676 - A,  
 Surya Enclave, Post - Chogltti, Near GGS  
 Avenue, Jalandhar, Punjab, Jalandhar - I,  
 Jalandhar,  
 Punjab - 144009



2147 9814 5002

VID : 9146 4467 0407 7654

1947 | help@uidai.gov.in | www.uidai.gov.in



# KAPIL HOSPITAL

Multispeciality, Comprehensive & Intensive Care Centre  
A Centre approved for Cashless Hospitalization by all Insurance Companies/TPAs/GIPSA  
Civil Lines, Rajinder Nagar, opp. Commissioner's Office, Jalandhar City.(PB.)-144 001



Phone : 0181-2230822, 2235822  
Telefax : 0181-2230822 (R)2456833  
e-mail : guptakapil.12@gmail.com  
Website: www.kapilhospitaljalandhar.com

**NABH CERTIFIED HOSPITAL**

## Page No.1

NAME	SHEENKI SHARMA	DATE	23/03/2023
HUSBAND NAME	PANKAJ KUMAR		
AGE	35/Yrs	HOSPITAL ID	162/23
SEX	Female		
MARITAL STATUS	Married	EXAMINED BY	Dr. KAPIL GUPTA

## PERSONAL HISTORY

HISTORY OF PRESENTING ILLNESS :	Nothing significant
PAST HISTORY	Nil

DIET	Non-Vegetarian	BOWELS	Normal
APPETITE	Good	MICTURITION	Normal
SLEEP	Normal	HABITS	SMOKING: Nil
ALLERGY	Nil		ALCOHOL: Nil

## PHYSICAL EXAMINATION

HEIGHT	159cm	VISION	6/6 B/E
WEIGHT	62 Kg	Chest:94/100cm	
BP	100/70 mmhg	Abdomen:86cm	COULOUR VISION - Normal
PULSE	72/mnt	Dental check up	Normal
RESP. RATE	18/mnt	Spo2 : 99%	
TEMP	98.0° F		
SKIN	Normal		

KAPIL HOSPITAL  
Near New Courts,  
Civil Lines, Jalandhar



# KAPIL HOSPITAL

Multispeciality, Comprehensive & Intensive Care Centre  
A Centre approved for Cashless Hospitalization by all Insurance Companies/TPAs/GIPSA  
Civil Lines, Rajinder Nagar, opp. Commissioner's Office, Jalandhar City.(PB.)-144 001

Phone : 0181-2230822, 2235822  
Telefax : 0181-2230822 (R)2456833  
e-mail : guptakapil.12@gmail.com  
Website: www.kapilhospitaljalandhar.com



**NABH CERTIFIED HOSPITAL**

## Page No.2

	JVP	Normal
	APEX BEAT	5 <sup>th</sup> ICS mid clavicular line
<b>CVS</b>	THRILLS	Absent
	HEART SOUNDS	Normal
	MURMURS	Absent

	TRACHEAL POSITION	Central
	SHAPE OF CHEST	Normal
<b>RS</b>	MOVEMENTS	Equal Bilateral
	BREATH SOUNDS	Vesicular
	ADVENTITIOUS SOUNDS	Absent

	TENDERNESS	Nil
	LIVER	Normal
<b>ABDOMEN</b>	SPLEEN	Not Palpable
	KIDNEY	Normal
	FREE FLUID	Absent
	BOWEL SOUND	Normal
	HERNIAL ORIFICES	Normal

	HIGHER MENTAL FUNCTION	Normal
	CRANIAL NERVES	Normal
<b>CNS</b>	SENSORY SYSTEMS	Normal
	MOTER SYSTEMS	No Abnormality
	REFLEXES	Normal

MUSCULOSKELETAL SYSTEM	Normal
------------------------	--------

**IMPRESSION: - CLINICALLY AND INVESTIGATION WISE FIT.**

DOCTOR SIGNATURE & SEAL :

**DR KAPIL GUPTA**

**MD**

**KAPIL HOSPITAL**  
Near New Courts,  
Civil Lines, Jalandhar

Optimal (mitral and limb)

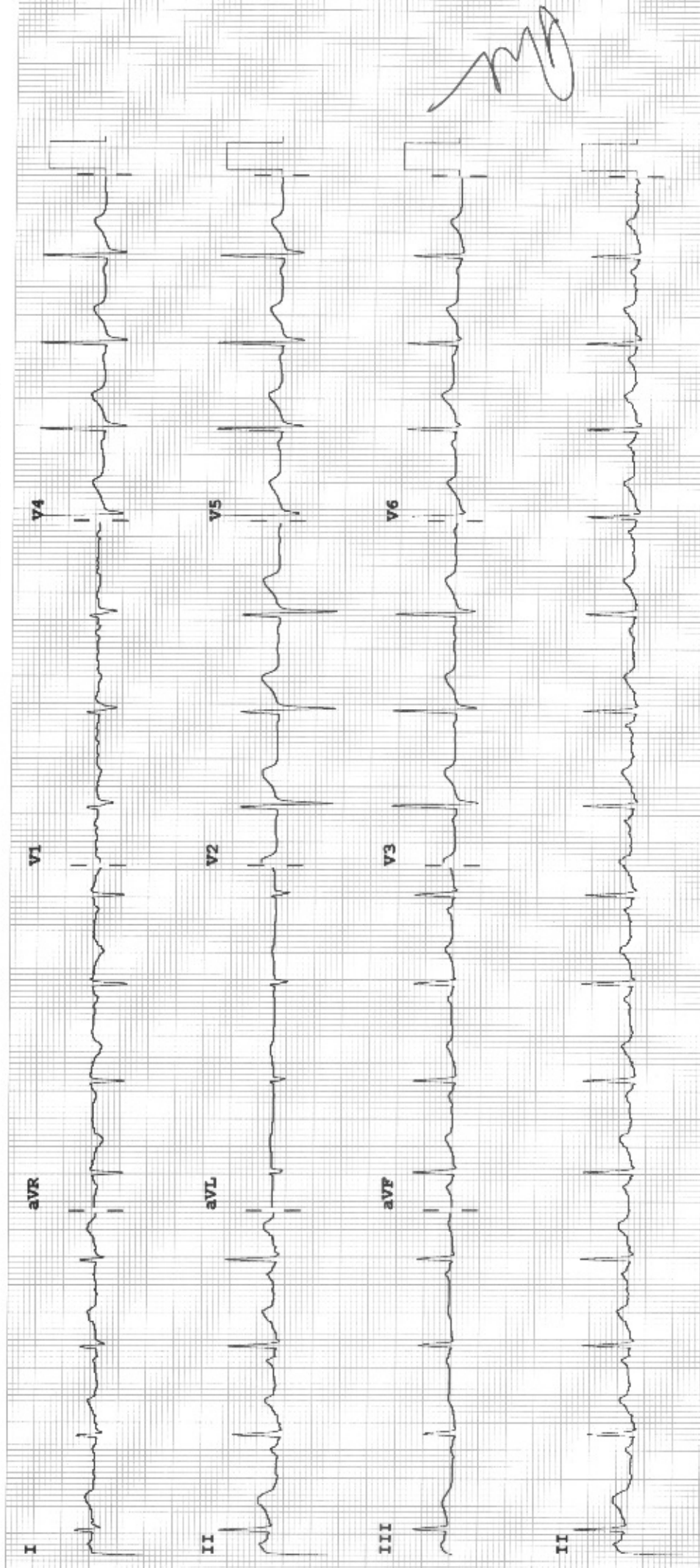
hyl

KAPIL HOSPITAL  
Near New Courts,  
Civil Lines, Jalandhar

Rate 91  
PR 128  
QRSD 82  
QT 363  
QTc 447

--AXIS--  
P 69  
QRS 76  
T 37

12 Lead; Standard Placement



Device: Speed: 25 mm/sec Limb: 10 mm/mV Chest: 10.0 mm/mV

F 60~ 0.50~ 40 Hz W PH10 CL P?



# K. S. Clinical Lab.



Phone : 0181-2230822, 2235822  
 Telefax : 0181-2230822 (R)2456833  
 e-mail : guptakapil.12@gmail.com  
 Website: www.kapilhospitaljalandhar.com

## Inside Kapil Hospital

### NABH ACCREDITED HOSPITAL

A CENTRE APPROVED FOR CASHLESS HOSPITALIZATION

NEAR NEW COURTS, JALANDHAR CITY.

Authorised Collection Centre for Dr. Lal Path., Reliance, Metropolis etc.

#### Outpatient

First Name: Mrs Sheenki

Sample Type:

Sample ID: 981

Last Name: Sharma

Department:

Run Time: 2023/03/24 11:19

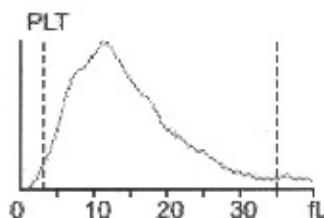
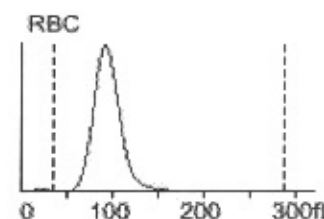
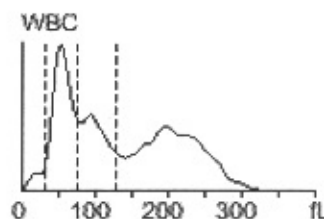
Gender: Female

Med Rec. No.:

Age: 35 Year

Diagnosis:

Parameter	Result	Ref. Range	Unit
1 WBC	5.51	3.50-9.50	10 <sup>3</sup> /uL
2 Lym%	28.8	20.0-50.0	%
3 Gran%	49.1 ↓	50.0-70.0	%
4 Mid%	22.1 ↑	3.0-9.0	%
5 Lym#	1.59	1.10-3.20	10 <sup>3</sup> /uL
6 Gran#	2.70	2.00-7.00	10 <sup>3</sup> /uL
7 Mid#	1.22 ↑	0.10-0.90	10 <sup>3</sup> /uL
8 RBC	4.28	3.80-5.10	10 <sup>6</sup> /uL
9 HGB	12.7	11.5-15.0	g/dL
10 HCT	40.4	35.0-45.0	%
11 MCV	94.3	82.0-100.0	fL
12 MCH	29.6	27.0-34.0	pg
13 MCHC	31.3 ↓	31.6-35.4	g/dL
14 RDW-CV	12.8	11.5-14.5	%
15 RDW-SD	49.3	35.0-56.0	fL
16 PLT	242	125-350	10 <sup>3</sup> /uL
17 MPV	10.7	7.0-11.0	fL
18 PDW-SD	12.6	9.0-17.0	fL
19 PDW-CV	13.9	10.0-17.9	%
20 PCT	0.259	0.108-0.282	%
21 P-LCR	32.6	11.0-45.0	%
22 P-LCC	79	30-90	10 <sup>3</sup> /uL





Phone : 0181-2230822, 2235822  
 Telefax : 0181-2230822 (R)2456833  
 e-mail : guptakapil.12@gmail.com  
 Website: www.kapilhospitaljalandhar.com

# K. S. Clinical Lab.

Inside Kapil Hospital

**NABH ACCREDITED HOSPITAL**

A CENTRE APPROVED FOR CASHLESS HOSPITALIZATION

NEAR NEW COURTS, JALANDHAR CITY.

Authorised Collection Centre for Dr. Lal Path., Reliance, Metropolis etc.



<b>Client Name: Mrs. Sheenki Sharma</b>	<b>Age/Sex: 35Yrs/Female</b>
<b>Date: 23/03/2023</b>	<b>Incharge: Dr. Kapil Gupta MD</b>
<b>Wellness</b>	

<b>Lipid Profile</b>	<b>Patients Value</b>	<b>Normal Range</b>
S.Cholesterol	168.0 mg/dl	150-220.0 mg/dl
S.H.D.L.Cholesterol	36.5 mg/dl	29-67.0 mg/dl
S.V.L.D.L.Cholesterol	30.2 mg/dl	05-24.0 mg/dl
S.L.D.L.Cholesterol	101.3 mg/dl	<100.0 mg/dl
S.Triglycerides	151.0 mg/dl	35-160.0 mg/dl
Cholesterol/HDL Ratio	4.6	3.0-6.0
HDL/LDL ratio	2.77	3.5-5.0

<b>Liver Function Test</b>	<b>Patients Value</b>	<b>Normal Range</b>
S.Bilirubin (Total)	0.5 mg/dl	0.2-1.0 mg/dl
S.Bilirubin (Direct)	0.2 mg/dl	0.2-0.4 mg/dl
S.Bilirubin (Indirect)	0.3 mg/dl	0.2-0.6 mg/dl
S.G.O.T	23.0 Units/ml	5-35 Units/ml
S.G.P.T	27.0 Units/ml	7-40 Units/ml
AST/ALT ratio	0.85	1.0-2.1
S.Alkaline Phosphatase	95.0 U/L	43-240 U/L
Total Proteins	7.1 gm/dl	6.0-8.0 gm/dl
Albumin	4.0 gm/dl	3.8-5.0 gm/dl
Globulin	3.1 gm/dl	2.3-3.5 gm/dl
S.G.G.T.P	23.0 IU/L	17-70 IU/L

<b>Investigations</b>	<b>Patients Value</b>	<b>Normal Range</b>
S.Creatinine	0.7 mg/dl	0.4-1.2 mg/dl
B. Urea	21.0 mg/dl	10-50 mg/dl
BUN	9.8 mg/dl	10-20 mg/dl
BUN/Creatinine Ratio	14.0	10-20 range
Blood Sugar(F)	76.0 mg/dl	70-110 mg/dl
Blood Sugar(PP)	93.0 mg/dl	80-140 mg/dl
S.Uric Acid	5.1 mg/dl	2.5-7.5 mg/dl
E.S.R	6.0mm/1st hr	5.0-10.mm/1st hr

**KAPIL HOSPITAL**  
 Near New Courts,  
 Civil Lines, Jalandhar

**Dr. Kapil Gupta**  
 M.D.

Lab. Technician



Phone : 0181-2230822, 2235822  
 Telefax : 0181-2230822 (R)2456833  
 e-mail : guptakapil.12@gmail.com  
 Website: www.kapilhospitaljalandhar.com

# K. S. Clinical Lab.

Inside Kapil Hospital

**NABH ACCREDITED HOSPITAL**

A CENTRE APPROVED FOR CASHLESS HOSPITALIZATION

NEAR NEW COURTS, JALANDHAR CITY.

Authorised Collection Centre for Dr. Lal Path., Reliance, Metropolis etc.



<i>Client Name: Mrs. Sheenki Sharma</i>	<i>Age/Sex: 35Yrs/Female</i>
<i>Date: 23/03/2023</i>	<i>Incharge: Dr. Kapil Gupta MD</i>
<i>Wellness</i>	

## THYROID FUNCTION TEST:

<u>Investigation</u>	<u>Observed Value</u>	<u>Unit</u>	<u>Biological Reference Interval</u>
Thyroid Panel-1			
T3 (Total)	103.12	ng/dl	70-204 First Trimester:81-190 Second Trimester:100-260 Third Trimesters:100-260
T4 (Total)	9.10	µg/dl	5.0-12.5
TSH (Ultrasensitive)	3.0	µIU/ML	0.45-4.5 First Trimester : 0.1-2.5 Second Trimester : 0.2-3.0 Third Trimester :0.3-3.0

References:1.Interpretaion of thyroid function tests.Dayan et al.  
 THELANCET.Vol357.Febuary24,2001.

2.Laboratory Evaluation of Thyroid function, India Thyroid Guidelines,

Lab-Technician

KAPIL HOSPITAL  
 Near New Courts,  
 Civil Lines, Jalandhar

*Dr. Kapil Gupta*  
 M.D.



# K. S. Clinical Lab.

Inside Kapil Hospital

**NABH ACCREDITED HOSPITAL**

A CENTRE APPROVED FOR CASHLESS HOSPITALIZATION

NEAR NEW COURTS, JALANDHAR CITY.

Authorised Collection Centre for Dr. Lal Path., Reliance, Metropolis etc.



Phone : 0181-2230822, 2235822  
Telefax : 0181-2230822 (R)2456833  
e-mail : guptakapil.12@gmail.com  
Website: www.kapilhospitaljalandhar.com

<i>Client Name: Mrs. Sheenki Sharma</i>	<i>Age/Sex: 35Yrs/Female</i>
<i>Date: 23/03/2023</i>	<i>Incharge: Dr. Kapil Gupta MD</i>
<i>Wellness</i>	

## INTERPRETATION:-

Fasting Blood Sugar: 76.0mg/dl (Normal value: 70-110.0 mg/dl)

Clients HbA1c: 4.8 % (Normal value (4.0% - 6.0 %))

HBA1C	NORMAL RANGE	
	Non Diabetic	4.0% - 6.0%
	Good Control	6.1% - 8.0%
	Poor Control	8.1% - 9.0%
	Unsatisfactory	>9%

### Note:-

- 1. A three monthly monitoring is recommended in diabetics.
- 2. Since HbA1c concentration represents the integrated values for blood glucose over the preceding 6-10 weeks and is not affected by daily glucose fluctuation, exercise and recent food intake, it is a more useful tool for monitoring diabetics.

### Clinical Use:-

- Clinical management of diabetes mellitus through routine monitoring.
- Assess compliance with therapeutic regimen.

### Report Completed:-

### Test Requested:

GLYCOSYLATED HEMOGLOBIN/HbA1c

Lab. Technician

KAPIL HOSPITAL  
Near New Courts,  
Civil Lines, Jalandhar  
**Dr. Kapil Gupta**  
M.D.





Phone : 0181-2230822, 2235822  
Telefax : 0181-2230822 (R)2456833  
e-mail : guptakapil.12@gmail.com  
Website: www.kapilhospitaljalandhar.com

# K. S. Clinical Lab.

Inside Kapil Hospital

**NABH ACCREDITED HOSPITAL**

A CENTRE APPROVED FOR CASHLESS HOSPITALIZATION

NEAR NEW COURTS, JALANDHAR CITY.

Authorised Collection Centre for Dr. Lal Path., Reliance, Metropolis etc.



<i>Client Name: Mrs. Sheenki Sharma</i>	<i>Age/Sex: 35Yrs/Female</i>
<i>Date: 23/03/2023</i>	<i>Incharge: Dr. Kapil Gupta MD</i>
<i>Wellness</i>	

<i>Investigation</i>	<i>Patients Value</i>
Blood Group	B
Rh Typing	Positive

<i>Urine Analysis</i>	
Color	Pale Yellow
Sugar	Nil
Albumin	Nil
Ketones	Nil
Bilirubin	Nil
Urobilinogen	Normal
Leucocyte esterase	Negative
<i>Microscopic Examination/HPF</i>	
Leucocytes/Pus Cells	2-3
R.B.Cs.	Nil
Casts	Nil
Epithelial Cells	0-1
Significant Crystals	Nil
Specific Gravity	1.010
PH	5.0

Lab. Technician

KAPIL HOSPITAL  
Near New Courts,  
Civil Lines, Jalandhar  
**Dr. Kapil Gupta**  
M.D.



# K. S. Clinical Lab.

Inside Kapil Hospital

**NABH ACCREDITED HOSPITAL**

A CENTRE APPROVED FOR CASHLESS HOSPITALIZATION

NEAR NEW COURTS, JALANDHAR CITY.

Authorised Collection Centre for Dr. Lal Path., Reliance, Metropolis etc.



Phone : 0181-2230822, 2235822  
Telefax : 0181-2230822 (R)2456833  
e-mail : guptakapil.12@gmail.com  
Website: www.kapilhospitaljalandhar.com

<i>Client Name: Mrs. Sheenki Sharma</i>	<i>Age/Sex: 35Yrs/Female</i>
<i>Date: 23/03/2023</i>	<i>Incharge: Dr. Kapil Gupta MD</i>
<i>Wellness</i>	

<i>Urine Analysis</i>	
Color	Pale Yellow
Sugar (PP)	Nil
Albumin	Nil
Ketones	Nil
Bilirubin	Nil
Urobilinogen	Normal
Leucocyte esterase	Negative
<i>Microscopic Examination/HPF</i>	
Leucocytes/Pus Cells	1-2
R.B.Cs.	Nil
Casts	Nil
Epithelial Cells	Nil
Significant Crystals	Nil
Specific Gravity	1.010
PH	5.0

Lab. Technician

KAPIL HOSPITAL  
Near New Courts,  
Civil Lines, Jalandhar  
**Dr. Kapil Gupta**  
M.D.



# KAPIL HOSPITAL

Multispeciality, Comprehensive & Intensive Care Centre  
A Centre approved for Cashless Hospitalization by all Insurance Companies/TPAs/GIPSA  
Civil Lines, Rajinder Nagar, opp. Commissioner's Office, Jalandhar City.(PB.)-144 001

**NABH CERTIFIED HOSPITAL**



Phone : 0181-2230822, 2235822  
Telefax : 0181-2230822 (R)2456833  
e-mail : guptakapil.12@gmail.com  
Website: www.kapilhospitaljalandhar.com

Client Name: Mrs. Sheenki Sharma	Age/Sex: 35Yrs/Female
Date: 23/03/2023	Incharge: Dr. Kapil Gupta MD
Wellness	

## X-RAY CHEST REPORT

### REPORT:

- Trachea is centrally placed.
- Heart size is normal.
- Both costo – phrenic and cardio – phrenic angles are clear.
- Chest is Emphysematous.
- Prominent BV markings at right with changes of bronchiectasis seen at right middle & lower lobe.
- Both domes of diaphragms are normal with non delineated cupulae and margins.
- Normal sub – diaphragmatic stomach shadow noticed.
- Soft tissue shadows and bony structures are normal.
- No definitive other pulmonary parenchymal disease.

### OPINION/IMPRESSION:-

**\* Bronchiectasis Right Middle & Lower lobe –Rest within Normal Limits**

(Advice: Sputum for AFB & Spirometry or HRCT Chest if cough persistent)

KAPIL HOSPITAL

Near New Courts,  
Civil Lines, Jalandhar

**DR. KAPIL GUPTA**

**MD**

Medical & Heart Specialist

**Please Correlate clinically and with related investigation may be more informative**

**Disclaimer:** In case of any discrepancy due to typing error or machinery error please get it rectified immediately.



# KAPIL HOSPITAL

Multispeciality, Comprehensive & Intensive Care Centre  
A Centre approved for Cashless Hospitalization by all Insurance Companies/TPAs/GIPSA  
Civil Lines, Rajinder Nagar, opp. Commissioner's Office, Jalandhar City.(PB.)-144 001

**NABH CERTIFIED HOSPITAL**



Phone : 0181-2230822, 2235822  
Telefax : 0181-2230822 (R)2456833  
e-mail : guptakapil.12@gmail.com  
Website: www.kapilhospitaljalandhar.com

## ULTRA SONOGRAPHY REPORT

<b>Patient Name:</b> Mrs. Sheenki Sharma	<b>Age/Sex:</b> 35Yrs/ Female
<b>PART Scanned:-</b> ABDOMEN	<b>Sonography Window :-</b> Good/Bad/Reasonable
<b>Non fasting</b>	<b>23/03/2023</b>

**Liver:** is normal in size to 11.0.cm, shape, outline and show echogenicity. No sol. is seen. I.H.B.R. are normal. Portal vein is 10.6. No pathology seen in Porta.

**Gall Bladder** is normal in size. Walls are normal. No calculus/sol. seen.

The cleavage line between the liver and gall bladder is maintained. To be repeated on fasting

**Common Bile Duct:** is normal in calibre. No obstruction /mass/calculus could be seen up to the length scanned.

**Pancreas:** is normal in size, shape, outline and echopattern. PD is normal. No sol. seen. Peripancreatic region is normal.

**Spleen:** is normal in size and echopattern. No sol. seen. Splenic vein is normal in size. No collaterals could be seen.

**Kidneys:** Both kidneys are normal in size, shape, outline and parenchymal echopattern. Cortico medullary distinction is well maintained bilaterally. Central echoes are compact. No calculi/hydronephrosis seen in both kidneys. Peri renal area is normal Rt kidney 10.8x 3.4cm, Lt kidney 10.5 x 4.0cm.

**Ureters:** seem to be normal upto the parts scanned.

**Uterus:** Transverse & longitudinal sonography of pelvis shows normal size uterus. The endometrial image is sharp & clear. No evidence of myoma. Left ovary is of normal size, but right ovarian small cyst shows size of 2.3 x 2.4mm. No adenexal mass seen. No fluid collection in the cul-de-sac. To be repeated in post evaluation stage of periods.

**Urinary Bladder:** is normal. No calculus/mass is seen. UB wall is normal. Psoas muscles seem to be normal.

**Bowel loops:** Right iliac region seem to be grossly normal. No sol. seen. No free fluid/gross lymphadenopathy noted.

**Pleural:** spaces are normal.


**Impression:** Small right ovarian cyst- Rest US Scan study normal

**Please correlate clinically and with related investigation which may be more informative**

Owing to technical limitations of the procedure, there may be false positive or false negative interpretation. Ultrasound scan is supplement not substitute of clinical assessment.

Kindly repeat on fasting if USS got done on non-fasting status and on full bladder if done on empty bladder. The present study cannot completely confirm (1) absence of any or (2) presence of ureteric or gall bladder calculus due to positioning or non-visualization of ureter and gall bladder window

**Date:** 23/03/2023

  
**Dr. Kapil Gupta**  
MD  
KAPIL HOSPITAL  
Near New Courts,  
Civil Lines, Jalandhar