

SARDA

CENTRE FOR DIABETES & SELF CARE

NAME: MR. RATNAKAR CHOLE

SEX : Male

REF. BY : MEDIWHEEL

DATE:14/03/2022

BLOOD SUGAR EXAMINATION

TEST	RESULT
Fasting Blood Sugar:	98 mg/dl
Post Meal Blood Sugar Level:	119 mg/dl

REFERANCE RANGE :	NON DIABETIC	IGT	DIABETIC
FASTING	≤ 90 MG	90-126 mg %	≥ 126 mg %
POSTMEAL	≤ 140 mg	140-200mg%	≥ 200 mg

GYCOCYTED HAEMOGLOBIN

TEST	RESULT	NORMAL
HbA1C:	5.5 %	4.7-5.9 %
M.B.G	105.55% mg	70 - 120 mg

INTERPRETATION:

FOR DIABETIC PATIENT

Good Control: 6.0 - 7.0 %

Fair Diabetic Control: 7.0 - 8.0 %

Unsatisfactory control: 8.0 - 10 %

Poor Diabetic Control: Above 10 %

Dr.S R. SARDA

Dr. Sampat Sarda

M.D. (Pathology)
SARDA CENTRE FOR DIABETES & SELF CARE
4, Vyankateshnagar, Jalna Road, Aurangabad
Phone No. 2333851, 2334858

SARDA

CENTRE FOR DIABETES & SELF CARE

NAME: MR. RATNAKAR CHOLE

SEX : Male

REF. BY : MEDIWHEEL

DATE:14/03/2022

COMPLETE BLOOD COUNT

TEST	RESULT	NORMAL RANGE
WBC COUNT	10600 /cumm	4.0 - 11.0 x 10 ³ /cumm
Haemoglobin:	15.5 g%	13.0 - 18.0 g%
Platelets:	2,34000 /cumm	1,50,000 - 4,50,000 / cumm
Red Blood Cells:	5.52 /Mill/ul	4.20 - 6.00 Mill/ul
MCV:	81.1 fL	80.0 - 97.0 fL
MCH:	28.0 pg	26.0 - 32.0 pg
MCHC:	34.6 g/dL	31.0 - 36.0 g/dL
HCT:	44.7 %	37.0 - 51.0 %
Differential Count		
Neutrophils:	66 %	40 - 75 %
Lymphocyte:	29 %	20 - 45 %
Monocytes:	03 %	2 - 10 %
Eosinophills:	02 %	1 - 06 %
Basophills:	00 %	0 - 1 %
ESR:	08 mm at 1 Hr.	Male: 0 - 8 mm at 1 Hr. Female: 0 - 20 mm at 1 Hr.

BLOOD GROUP

BLOOD GROUP	:	"B"
R.H.FACTOR	:	POSITIVE

Dr. S R. SARDA

M.D. Reg. No.56462

SARDA CENTER FOR DIABETES & SELF CARE

4, Vyanktesh Nagar, Jalna Road, Aurangabad

M.D.(Pathology), 2334853

SARDA

CENTRE FOR DIABETES & SELF CARE

NAME: MR. RATNAKAR CHOLE

SEX : Male

REF. BY : MEDIWHEEL

DATE:14/03/2022

BLOOD PROFILE

TEST	RESULT	NORMAL
BLOOD UREA N2	13 mg%	5-25 mg %
CREATININE	1.1mg%	0.6-1.4 mg %
BILIRUBIN TOTAL	0.67mg%	0.2-1.0 mg
DIRECT	0.20	0.0-0.3
INDIRECT	0.47	0.3-0.7
S.G.O.T	16 IU/L	15-40 IU/L
S.G.P.T	19 IU/L	15-40 IU/L
ALK PHOSPHATASE	115 IU/L	70-306 IUL
S.PROTEIN TOTAL	7.4gm%	6.0-8.0 gm%
ALBUMIN	3.9gm%	3.2-4.4 gm%
GLOBULINS	3.5gm%	2.3-3.5 gm%
ALB/GLO RATIO	1.1	
G.G.T.P	30	upto50IU
SR.URIC ACID	4.7	3.5-7.0 mg %\$sruric-

Dr.S R. SARDA

M.D Reg. No.56462

SARDA CENTER FOR DIABETES & SELF CARE

4, Vyanktesh Nagar, Jalna Road, Aurangabad

M.D.(Pathology) 3051, 2334853

SARDA

CENTRE FOR DIABETES & SELF CARE

NAME: MR. RATNAKAR CHOLE

SEX : Male

REF. BY : MEDIWHEEL

DATE:14/03/2022

EXAMINATION OF STOOL

Physical Examination

Colour	Brownish
Consistency	Semisolid
Blood (Gross)	Absent
Mucus	Absent

Microscopic Examination

Red Blood Cells	Absent
Pus Cells	OCCASIONAL / hpf
Macrophages	
Ova	Absent
Cyst	Absent
Parasites	

Remark :

Dr. S R. SARDA

M.D. Reg. No. 56462

Dr. Sampat Sarda CENTRE FOR DIABETES & SELF CARE

M.D. (Pathology) 4, Vyanktesh Nagar, Jalna Road, Aurangabad

Phone No. 2333851, 2334858

SARDA

CENTRE FOR DIABETES & SELF CARE

NAME: MR. RATNAKAR CHOLE

SEX : Male

REF. BY : MEDIWHEEL

DATE:14/03/2022

THYROID FUCTION TEST

TEST	RESULT	NORMAL RANGE
Total T 3 :	172 ng/ml	60-181 ng/ml
Total T 4 :	8.3 ug/dl	4.87 - 11.72 ug/dl
TSH Ultrasensitive :	1.20 uIU/ml	0.35 -5.5uIU/ml

PROSTATIC SPECIFIC ANTIGEN

TEST	RESULT	UNIT	REFERENCE RANGE
PROSTATIC SPECIFIC ANTIGEN	0.742	ng/ml	0.0 - 4.0 ng/ml

Dr. S. R. SARDA

M.D. (Pathology)

Dr. Sampat Sarda

M.D. (Pathology)

CENTRE FOR DIABETES & SELF CARE

4, Vyanktesh Nagar, Jalna Road, Aurangabad

Phone No. 2333851, 2334853

SARDA

CENTRE FOR DIABETES & SELF CARE

NAME: MR. RATNAKAR CHOLE

SEX : Male

REF. BY : MEDIWHEEL

DATE:14/03/2022

Urine Routine Examination

Physical Examination

Colour:	Pale Yellow
Appearance:	Clear
Reaction:	Acidic
Deposit	Absent

Chemical Examination:

Specific Gravity	1.010
Albumin	Absent
Sugar:	Absent
Acetone:	----
Bile Salts	----
Bile Pigment:	----

Microscopic Examination

RBC :	Absent
Pus Cells:	OCASSIONAL/HPF
Epihtelial cells:	Absent
Crystals:	Absent
Casts:	Absent

Dr.S R. SARDA

M.D Reg. No.56462

CENTRE FOR DIABETES & SELF CARE

4, Vyanktesh Nagar, Jalna Road, Aurangabad

551, 2334853

SARDA
Dr.Sampat Sarda
M.D.(Pathology)

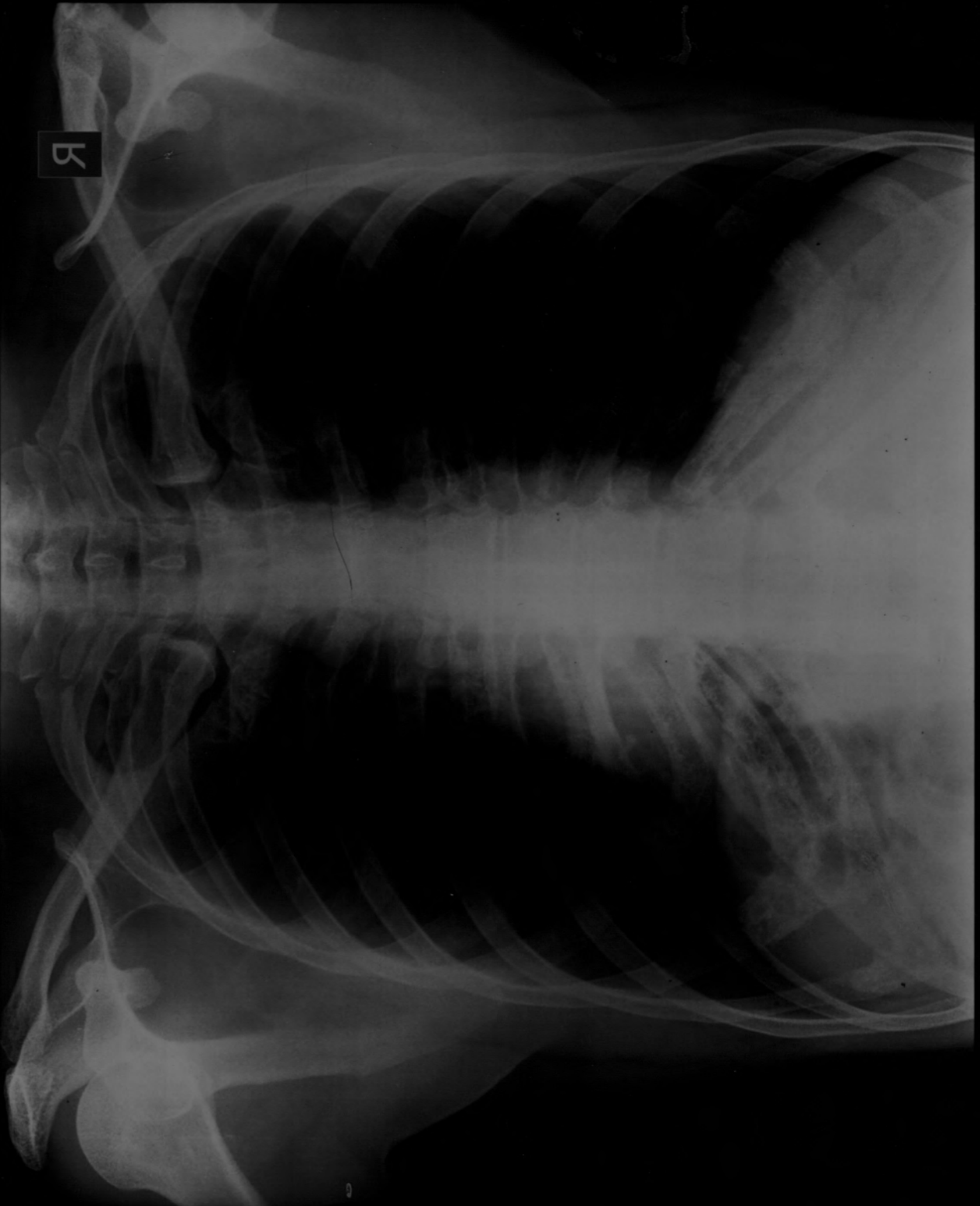
Ellora Diagnostic Centre, Aurangabad (0540) 5323185

Chest : PA Patient ID :

MR. RATNAKAR CHOLE Age : 40 YRS Male

Ref Doc : DR. S.SARDA

Date : 14-03-2025 AM 11:26:18



R

SARDA

CENTRE FOR DIABETES & SELF CARE

NAME: MR. RATNAKAR CHOLE

SEX : Male

REF. BY : MEDIWHEEL

DATE:14/03/2022

LIPID PROFILE

Serum Cholesterol :	177 mg/dl	130 - 250 mg/dl
HDL Cholesterol:	37 mg/dl	30 - 95 mg/dl
Serum Triglyceride:	139 mg/dl	up to 165 mg/dl
LDL Cholesterol:	112.2 mg/dl	up to 165 mg/dl
VLDL Cholesterol:	27.8 mg/dl	up to 40 mg/dl
LDL. / HDL Cholesterol Ratio:	3.03	Low risk : 0.5 - 3.0 Moderate risk: 3.0 - 6.0 High risk: > 6.0
CHOL./HDL Cholesterol Ratio:	4.78	Low risk : 3.3 - 4.4 Average risk: 4.4 - 7.1 Moderate risk: 7.0 - 11.0 High risk: > 11

Dr.S R. SARDA

M.D Reg. No.50462

SARDA CENTER FOR DIABETES & SELF CARE

4, Vyanktesh Nagar, Jalna Road, Aurangabad

Ph: 2333851, 2334858

Dr. Sampat Sarda

M.D.(Pathology)

**SARDA
CENTRE FOR DIABETES & SELF CARE**

4, Vyankatesh Nagar, Jainna Road, Aurangabad. Ph. : (0240) 2333851, 2334858.

Name : Mr. Rathnakar Chole Age : 40yr
BOB

CLINICAL SUMMARY :

Weight : _____ Height (Cms) : _____ Blood Pressure : _____

ECG FINDINGS :

Rate : 72/min ORS. Complex : R

Rhythm : R ST Segment : R

Mechanism : R T. Wave : R

Axis : R QT Interval : R

P. Wave : R PR Interval : R

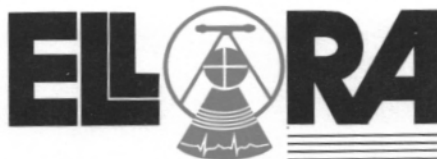Recommendation : nm

Dr. A.S. SARDA
M.D. Reg. No. 71570

SARDA CENTER FOR DIABETES & SELF CARE
4, Vyankatesh Nagar, Jainna Road, Aurangabad
Pincode: No. 233335, 2334858

Date : 14/3/22

DIGITAL X-RAY
INTERVENTIONAL RADIOLOGY
3D/4D SONOGRAPHY & COLOR DOPPLER
2-D ECHOCARDIOGRAPHY
PERIPHERAL COLOR DOPPLER
HI-SPEED HELICAL C.T. SCAN
C.T. ANGIOGRAPHY
PATHOLOGY LAB. SERVICES



DIAGNOSTIC CENTRE
X-RAY, IMAGING & PATHOLOGY

1, VYANKATESH NAGAR, OPP. SFS
HIGH SCHOOL, JALNA ROAD,
AURANGABAD - 431005
☎ : 0240-2353182, 2325282, 8446100111

Ratnakar Chole

14-03-2022

Ref. by:

CHEST PA VIEW

Trachea central.

Apices are clear.

Both lung fields appeared well pneumatised and appeared normal.

Both cp angles are clear.

Cardiac silhouette appeared normal.

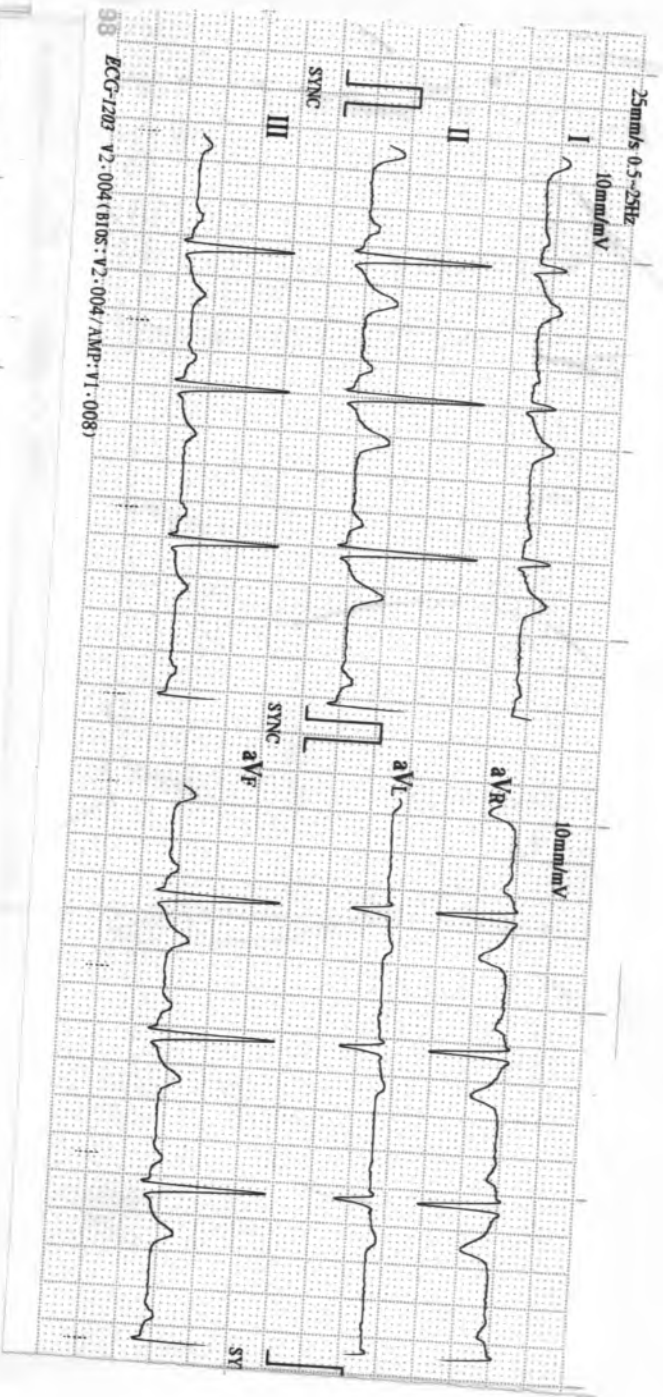
IMPRESSION :

NORMAL CHEST.

DR. P. A. BARJATYA
M.B.B.S., M.D.
9823344449



DR. G. S. LAHOTI
M.B.B.S., D.M.R.D.
9850171587



98 ECG-1203 v2.004 (BIOS: v2.004 / AMP: v1.008)

BIOMEDIC'S SADASHIV PETH PUNE-30 CELL-9822198798

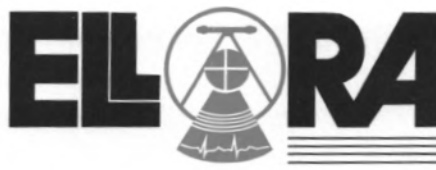03/14/2022 10:01
 ID : 59222
 Name: *P. S. S.*
 Sex: *M*
 Age: *45*
 HR : 73 bpm
 R-R : 816 ms
 P-R : 185 ms
 QRS : 125 ms
 QT/QTc : 360/398 ms
 P/QRS/T : 73/78/61
 RV5/SV1 : 1.840/0.790 mV
 RV5/SV1 : 2.630 mV

Machine Interpretation Only

Confirm with Physician

Physician: _____

DIGITAL X-RAY
INTERVENTIONAL RADIOLOGY
3D/4D SONOGRAPHY & COLOR DOPPLER
2-D ECHOCARDIOGRAPHY
PERIPHERAL COLOR DOPPLER
HI-SPEED HELICAL C.T. SCAN
C.T. ANGIOGRAPHY
PATHOLOGY LAB. SERVICES



DIAGNOSTIC CENTRE
X-RAY, IMAGING & PATHOLOGY

1, VYANKATESH NAGAR, OPP. SFS
HIGH SCHOOL, JALNA ROAD,
AURANGABAD - 431005
☎ : 0240-2353182, 2325282, 8446100111

14-03-2022

Mr. RATNAKAR CHOLE
40 YRS

USG ABDOMEN

Liver is normal in size, shape and echotexture.
Intrahepatic biliary radicles and portovenous echocomplex appeared normal.
No e/o any solid, cystic, diffuse parenchymal pathology seen.
Normal cbd and portal vein.

Gallbladder is well distended and appeared normal, no e/o any gallbladder calculus. Normal gb wall thickness.
Pancreas is normal in size, shape and echotexture.
Normal peripancreatic fat planes.
Spleen is normal in size, shape and echotexture.
Both kidneys are normal in size, shape and echotexture. No e/o any calculus seen, No e/o hydronephrosis.

Urinary bladder is well distended and appeared normal, no e/o any intravesical pathology. No e/o ascitis / paraaortic adenopathy.
Prostate measures 35x 30x 29mm with approximate weight of 15.3cc.

IMPRESSION

**NORMAL LIVER, SPLEEN, PANCREAS, GALLBLADDER, BOTH KIDNEYS,
URINARY BLADDER -
NORMAL PROSTATE.**

**Note : SCANNING DONE IN COVID 19 PANDEMIC PERIOD , PATIENT DID NOT
GIVE ANY OBVIOUS HISTORY PERTAINING TO COVID 19 INFECTION.**



DR. P. A. BARJATYA
M.B.B.S., M.D.
9823344449

DR. G. S. LAHOTI
M.B.B.S., D.M.R.D.
9850171587

Ellora Diagnostic Centre, Aurangabad (0540) 5323185

Chest - PA Patient ID

MR. RATNAKAR CHOLE Age : 40 YRS Male

Date : 14-03-2025 AM 11:29:18

Ref Dr - DR. S. SARDA

