



Government of India

निर्भय वर्मा
Nirbhay Verma
जन्म तिथि/DOB: 17/04/1987
पुरुष/ MALE

2197 1308 1987
VID: 9154 1160 0616 7351

मेरा आधार, मेरी पहचान




भारतीय विशिष्ट पहचान अधिकरण
Unique Identification Authority of India

पता:
श्रीमज: राजेंद्र वर्मा, 197, आई - ब्लॉक, यू आई टी
कॉलोनी, सेक्टर - 14, गवर्धन विलास (ग्रामीण),
उदयपुर,
राजस्थान - 313001

Address:
S/O: Rajendra Verma, 197, I - Block, U I
T Colony, Sector - 14, Goverdhan Vilas
(Rural), Udaipur,
Rajasthan - 313001

2197 1308 1987
VID: 9154 1160 0616 7351

QR Code with Photograph



1987 help@uidai.gov.in www.uidai.gov.in

2197



Aravali Hospital

332, Ambamata Scheme, Udaipur - 313 004
T: 91 294 2430222, 2431222
email : aravalihospital@yahoo.com



गुणवत्ता पूर्ण चिकित्सा सेवाओं के लिये
भारत सरकार की
क्वालिटी काउंसिल ऑफ इण्डिया (QCI-NABH)
द्वारा प्रमाणित

TO WHOM SO EVER IT MAY CONCERN

This is to certify **MR. NIRBHAY SINGH** aged 37 years male has undergone his physical check-up and routine blood test. He has no physical illness detected. He is physically fit.

Vitals:-

Pulse	:	80 per minute
BP	:	140/80 mmHg
Height	:	174 cms.
Weight	:	80 Kgs.
BMI	:	26.4
Medical history	:	NAD

Clinical Findings: -

Per Abdomen	:	NAD
CVS/CNS	:	NAD
Lungs	:	Clear
Skin	:	NAD
Vision/Color	:	R-6/6, L-6/6, Normal
Dental	:	NAD

NOTE : MILD RAISED SUGAR, CONTROL DIET AND DAILY WALKING.

Sangeeta
(Dr. Sangeeta Gupta)
Reg. No. 018332 (RMC)



Dated: 05/06/2024



Helpline : 9352 108 108

www.aravalihospital.in



Aravali Hospital

332, Ambamata Scheme, Udaipur - 313 004

T: 91 294 2430222, 2431222

email : aravalihospital@yahoo.com



गुणवत्ता पूर्ण चिकित्सा सेवाओं के लिये
भारत सरकार की
क्वालिटी काउंसिल ऑफ इण्डिया (QCI-NABH)
द्वारा प्रमाणित

Name Mr. NIRBHAY VERMA	Visit Date & Time 05/06/2024 09:37:21	PATIENT ID 11242054
Age 37 Yrs Sex Male	Sample Accepted : 05/06/2024 13:46:50	
	Test Authenticated at : 05/06/2024 18:16:02	Ref. By



HAEMATOLOGY

Test Name	Value	Status	Unit	Biological Ref Interval
HAEMOGLOBIN (HB)	16.1	H	gm %	11.0 - 16.0
RBC Count	5.25		X10 ⁶ /UL	3.50 - 5.50
PCV	45.8		%	36.0 - 48.0
MEAN CORP. VOLUME (MCV)	87.2		fL	80.0 - 99.0
MEAN CORP. HB (MCH)	30.7		pg	27.0 - 32.0
MEAN CORP. HB CON. (MCHC)	35.2		g/dL	32.0 - 36.0
RDW-CV	13.7		%	11.0 - 16.0
RDW-SD	46.0		fl	35.0 - 56.0
TLC Count	5.69		/cmm	4.00 - 11.00
Differential Leucocyte Count (DLC)				
POLYMORPH	57		%	45 - 75
LYMPHOCYTE	35		%	20 - 45
EOSINOPHIL	03		%	01 - 06
MONOCYTE	05		%	01 - 10
BASOPHIL	00		%	00 - 01
TOTAL PLATELET COUNT	220		x10 ³ /uL	150 - 450
MPV	8.3			7.4 - 10.4
PDW	13.9		%	10.0 - 17.0
PCT	0.2		%	0.1 - 0.3
P-LCR	20.4		%	11.0 - 45.0
P-LCC	45.0			30.0 - 90.0



DR. NARENDRA MOGRA
RMC NO5394

Helpline : 9352 108 108

www.aravalihospital.in





Aravali Hospital

332, Ambamata Scheme, Udaipur - 313 004

T: 91 294 2430222, 2431222

email : aravalihospital@yahoo.com



गुणवत्ता पूर्ण चिकित्सा सेवाओं के लिये
भारत सरकार की
क्वालिटी काउंसिल ऑफ इण्डिया (QCI-NABH)
द्वारा प्रमाणित

Name Mr. NIRBHAY VERMA	Visit Date & Time 05/06/2024 09:37:21	PATIENT ID 11242054
Age 37 Yrs Sex Male	Sample Accepted : 05/06/2024 13:46:50	Ref. By
	Test Authenticated at : 05/06/2024 18:16:02	



HAEMATOLOGY

Test Name	Value	Status	Unit	Biological Ref Interval
ESR	14		mm/1st hr.	0 - 20
Blood Group (ABORH)	'AB' POSITIVE			



DR. NARENDRA MOGRA
RMC NO5394

Helpline : 9352 108 108

www.aravalihospital.in





Aravali Hospital

332, Ambamata Scheme, Udaipur - 313 004
T: 91 294 2430222, 2431222
email : aravalihospital@yahoo.com



गुणवत्ता पूर्ण चिकित्सा सेवाओं के लिये
भारत सरकार की
क्वालिटी काउंसिल ऑफ इण्डिया (QCI-NABH)
द्वारा प्रमाणित

Name **Mr. NIRBHAY VERMA**

Visit Date & Time 05/06/2024 09:37:21

PATIENT ID **11242054**

Age 37 Yrs Sex Male

Sample Accepted : 05/06/2024 13:46:50

Test Authenticated at : 05/06/2024 18:16:02

Ref. By



BIOCHEMISTRY

Test Name	Value	Status	Unit	Biological Ref Interval
BILIRUBIN-TOTAL	1.01		mg/dl	0.20 - 1.20
BILIRUBIN-DIRECT	0.24		mg/dl	0.00 - 0.25
BILIRUBIN-INDIRECT	0.77	H	mg/dl	0.10 - 0.40
BLOOD SUGAR (FASTING)	113.2	H	mg/dl	60.0 - 110.0
BLOOD SUGAR (PP)	176.7	H	mg/dl	110.0 - 140.0
CREATININE	0.98		mg/dl	0.50 - 1.30
BUN	12.70		mg/dl	7.00 - 22.00
SGPT-ALT	23.31		U/L	0.00 - 45.00



DR. NARENDRA MOGRA
RMC NO5394

Helpline : 9352 108 108

www.aravalihospital.in





Aravali Hospital

332, Ambamata Scheme, Udaipur - 313 004

T: 91 294 2430222, 2431222

email : aravalihospital@yahoo.com



गुणवत्ता पूर्ण चिकित्सा सेवाओं के लिये
भारत सरकार की
क्वालिटी काउंसिल ऑफ इण्डिया (QCI-NABH)
द्वारा प्रमाणित

Name Mr. NIRBHAY VERMA	Visit Date & Time 05/06/2024 09:37:21	PATIENT ID 11242054
Age 37 Yrs Sex Male	Sample Accepted : 05/06/2024 13:46:50	Ref. By
	Test Authenticated at : 05/06/2024 18:16:02	



CLINICAL PATHOLOGY

Test Name	Value	Status	Unit	Biological Ref Interval
URINE EXAMINATION				
<u>PHYSICAL EXAMINATION</u>				
QUANTITY	20			
COLOUR	PALE YELLOW			
SPECIFIC GRAVITY	QNS			
APPEARANCE	CLEAR			
DEPOSITS	NIL			
PH	ACIDIC			
<u>CHEMICAL EXAMINATION</u>				
ALBUMIN	NIL			
SUGAR	NIL			
<u>MICROSCOPY EXAMINATION</u>				
EPITHELIAL CELLS	4-5		/HPF	
PUS CELLS	1-2		/HPF	
RBC'S	NIL		/HPF	
CASTS	ABSENT			
CRYSTALS	ABSENT			
BACTERIA	NIL			
YEAST CELLS	NIL			
TRICHOMONAS VAGINALIS	NIL			
SPERMATOZOA	NIL			
OTHERS	NIL			



DR. NARENDRA MOGRA End of Report ***

RMC NO5394

DR. HUSSAIN ALI RANGWALA

Helpline : 9352 108 108

www.aravalihospital.in



Aravali Hospital

332, Ambamata Scheme, Udaipur - 313 004

T: 91 294 2430222, 2431222

email : aravalihospital@yahoo.com



गुणवत्ता पूर्ण चिकित्सा सेवाओं के लिये
भारत सरकार की
क्वालिटी काउंसिल ऑफ इण्डिया (QCI-NABH)
द्वारा प्रमाणित

Ref No.	Date : 05-06-2024		
Patient's Name :	Mr. NIRBHAY SINGH	Age 37 Yrs.	Sex: M
Ref. By :	DR.		

X-RAY EXAMINATION REPORT

Part X-Rayed : CHEST PA View

Contrast Medium Used : None

Report :

- ❖ The lungs on either side show equal translucency and show normal vasculature.
- ❖ No focal lung parenchymal or interstitial lesion is seen.
- ❖ No evidence of any infiltration is seen.
- ❖ The hilar shadows are normal in size, shape and position.
- ❖ The pleural cavities are clear.
- ❖ The domes of the diaphragm are smooth.
- ❖ The cardiac size is normal.

Impression:

❖ **NO CARDIO PULMINARY ABNORMALITY IS SEEN.**

RADIOLOGIST

Note: This report is not valid for medico legal purpose.
Every report needs to be correlated and interpreted clinically.



Helpline : 9352 108 108

www.aravalihospital.in

NIRBHAY VERMA 37YR

Male


6/5/2024 9:35:05 AM

- Rate 87 . Age not entered, assumed to be 50 years old for purpose of ECG interpretation
- PR 140 . Sinus rhythm.....
- QRSD 85 . ST elev, probable normal early repol pattern.....normal P axis, V-rate 50- 99
- QT 360 . Baseline wander in lead(s) VI, V2.....ST elevation, age<55
- QTC 433

--AXIS--

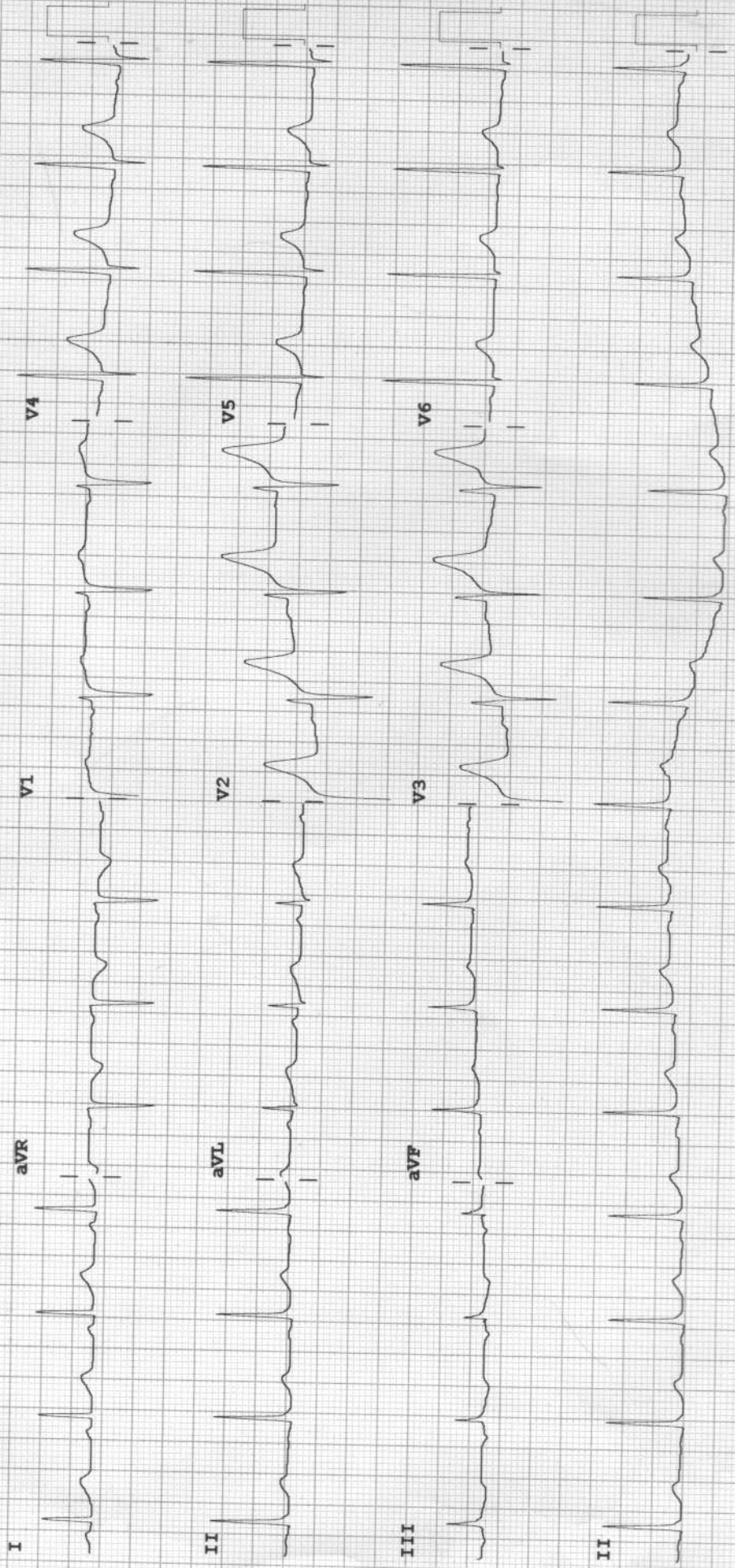
P 13
 QRS 43
 T 13

12 Lead; Standard Placement

TWNL 

- NORMAL ECG -

Unconfirmed Diagnosis



Device:

Speed: 25 mm/sec

Limb: 10 mm/mV

Chest: 10.0 mm/mV

F 60~ 0.15-100 Hz

100B CL

P?

CM

R

MR. NIRBHAY VERMA 37YRS MEDIWHEEL M CHEST PA 05-Jun
ARAVALI HOSPITAL, 332 AMBAMATA SCHEME, UDAIPUR