

MER- MEDICAL EXAMINATION REPORT

Date of Examination	15/11/2024		
NAME	Ajendra Shukla		
AGE	40 yrs	Gender:	male
HEIGHT(cm)	165 cm	WEIGHT(kg):	72 kg BMI: 26.4
B.P.	120/90 mmHg		
ECG	Report attached		
X Ray	Report attached		
Vision Checkup:	Left Eye		Right Eye
	Distance Vision:	6/6	6/6
	Near Vision:	6/6	6/6
	Color Vision:	Normal	
ENT / Audiometry Checkup	NA		
Present Ailments	No		
Details of Past ailments (If Any)	No		
Comments / Advice : She /He is Physically Fit	He is Physically fit		
No Any medical history			

Dr. Jai B. Raisinghani
M.D., Card.
Clinical Cardiologist
Reg. No. 29981 (MCI)

Signature with Stamp of Medical Examiner



Ajendra Kumar Shukla




Dr. Jal B. Raisinghani

M.D. D. Card.
Clinical Cardiologist
Reg. No. 10081 (MCI)

Patient Name : Ajendra Shukla	Patient ID : AHCN-34012112401001
Age/Sex : 40 Years /Male	Register Date : 13 Nov, 2024
Ref. By : Apollo Health - Arcolferni - Mediwheel	Reported Date : 13 Nov, 2024

Investigation	Observed Value	Biological Reference Interval	Unit
CBC with ESR			
Hemoglobin (Hb)	13.5	13 - 17	g/dL
Hemoglobin %	79.41	0 - 100	
Total RBC Count	4.25	4.5 - 5.5	mill/cumm
Mean Corpuscular Volume (MCV)	7.56	78.2 - 97.50	fL
Mean Corpuscular Hemoglobin (MCH)	31.76	27 - 33	pg/cell
Mean Corpuscular Hemoglobin Concentration (MCHC)	1550.00	33 - 36	g/dL
Hematocrit Value (Hct)	35.6	40 - 50	%
Red cell Distribution Width (RDW)	15.1	11.5 - 14	%
Total WBC Count	6071	4000 - 11000	cumm
Neutrophils	52	40 - 70	%
Lymphocytes	29	20 - 40	%
Eosinophils	04	1 - 4	%
Monocytes	05	1 - 6	%
Basophils	00	0 - 1	%
Platelet Count	199000	150000 - 450000	/cumm
Erythrocyte Sedimentation Rate (ESR)	15	0 - 22	mm/hr
Serum Creatinine			
Serum Creatinine	0.89	0.60 - 1.40	mg/dL
BUN / Creatinine Ratio			
BUN / Creatinine Ratio	11.6		

****END OF REPORT****



Dr. S N Tripathi
 M.D. (Path)
 Reg No. 2000/04/1994

The above result relate only to the specimens received and tested in laboratory and should be always correlate with clinical findings and other laboratory markers.

Patient Name : Ajendra Shukla	Patient ID : AHCN-34012112401001
Age/Sex : 40 Years /Male	Register Date : 13 Nov, 2024
Ref. By : Apollo Health - Arcofemi - Mediwheel	Reported Date : 13 Nov, 2024

Investigation	Observed Value	Biological Reference Interval	Unit
---------------	----------------	-------------------------------	------

BLOOD GROUP, ABO & RH TYPING

Blood Group, ABO & RH Typing

ABO Group	B
RH Factor	Positive

The test to determine your blood group is called ABO typing. Your blood sample is mixed with antibodies against type A and B blood. Then, the sample is checked to see whether or not the blood cells stick together. If blood cells stick together, it means the blood reacted with one of the antibodies.

Rhesus (Rh) factor is an inherited protein found on the surface of red blood cells. If your blood has the protein, you're Rh positive. If your blood lacks the protein, you're Rh negative.

Indirect, Direct & Total Bilirubin

Indirect, Direct & Total Bilirubin

Indirect Bilirubin	0.66	0.2 - 0.8	mg/dL
Direct Bilirubin	0.15	0 - 0.3	mg/dL
Total Bilirubin	0.81	0 - 2.0	mg/dL

Fasting Glucose And Post Prandial Glucose

Fasting Blood Glucose	90.05	70 - 110	mg/dL
Fasting Urine Glucose	Absent		
Fasting Urine ketone	Absent		
Post Prandial Blood Glucose	117.4	70 - 140	mg/dL
Post Prandial Urine Glucose	Absent		
Post Prandial Urine ketone	Absent		

SGPT (ALT)

SGPT (ALT)	23.9	00 - 40	U/L
Interpretation			



Dr. S N Tripathi
 M.D. (Path)
 Reg No. 2000/04/1994

The above result relate only to the specimens received and tested in laboratory and should be always correlate with clinical findings and other laboratory markers.



Patient Name : Ajendra Shukla	Patient ID : AHCN-34012112401001
Age/Sex : 40 Years /Male	Register Date : 13 Nov, 2024
Ref. By : Apollo Health - Arcofemi - Mediwheel	Reported Date : 13 Nov, 2024

Urine Examination Routine

Urine Examination Routine

Investigation	Observed Value	Biological Reference Interval	Unit
Quantity	40		ml
Appearance clear	Pale yellow		
Colour	Clear		
PH	6.0	5.0 - 8.0	
Specific Gravity	1.020	1.005 - 1.030	
Proteins	Absent		
Glucose	Absent		
Ketones	Absent		
Bilirubin	Absent		
Urobilinogen	Absent		
Leucocyte Esterase	Absent		
Nitrite	Absent		
Occult Blood	Absent		
R.B.C.	Absent		
Pus Cells	2-4	0 - 5	WBC / hpf
Epithelial Cells	2-2	0 - 2	hpf
Casts	Absent	0 - 0	hpf
Crystals	Absent		
Amorphous Material	Absent		
Bacteria	Absent		

*****END OF REPORT*****

Dr. S N Tripathi
M.D. (Path)
Reg No. 2000/04/1994

The above result relate only to the specimens received and tested in laboratory and should be always correlate with clinical findings and other laboratory markers.

23 Alpanka Shukla
40 Yrs / M / Smoker
Ht/Wt : 165 Cms / 72 Kgs

KNA HEALTH CARE

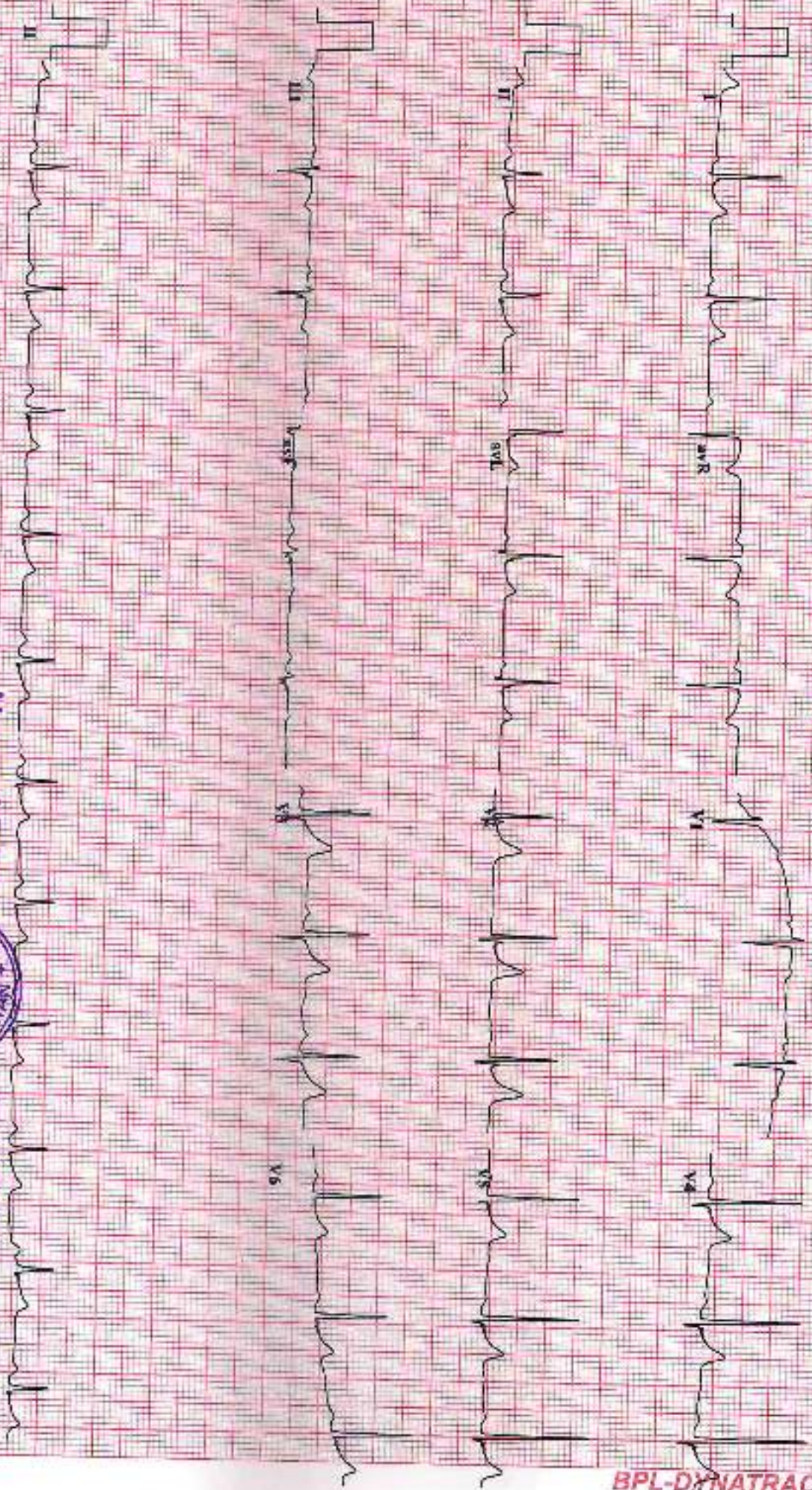Therana School Ground Floor, Malangand Road, Kalyan (C)

Date/Time : 13-11-24 - 09:58
Ref. By :
Ref (ambly) :

Speed : 25 mm/Sec
Gain : 10 mm/mV
Filter/Notch : 0.1-35Hz / R50

Heart Rate : 66
P Interval : 110 msec
PR Interval : 157 msec

QRS Interval : 85 msec P axis : +88°
QT Interval : 355 msec QRS axis : +30°
QTc Interval : 372 msec I axis : +120°



Within Normal Limits

Normal ECG



Dr. Jay B. Raisinghani

MD, DNB
General Cardiology
Reg. No. 29581 (MCO)

DR Jay Raisinghani
MD Cardiologist



SHREE GANESH DIAGNOSTIC CENTER

Let's do good...

SONOGRAPHY | COLOR DOPPLER | DIGITAL X-RAY | PATHOLOGY

Dr. Abhishek Singh

MBBS, DMRE, FMF (Mumbai)

Consultant Radiologist & Sonologist

Previous post in

1) Krishna Sagar (Chennai)

2) Premier Sagar (Kerala)

3) Bhakta Atomic Research Centre (Chembur, Mumbai)

4) Loknarya Tilak Hospital (Sion, Mumbai)

5) Mahabaleshwar Hospital (Daha)

Name of Patient :AJENDRA SHUKLA	Age/Sex: 40Years/MALE
	Date: 13/11/2024

RADIOGRAPH OF CHEST PA VIEW

Both the lung fields are clear.

The Broncho vascular markings are appears normal.

The hilar shadows are appears normal.

Both Cardio phrenic and Costophrenic angles are clear.

The Cardiac silhouette is within normal limits.

Aortic shadow is normal.

Both domes of diaphragms are normal.

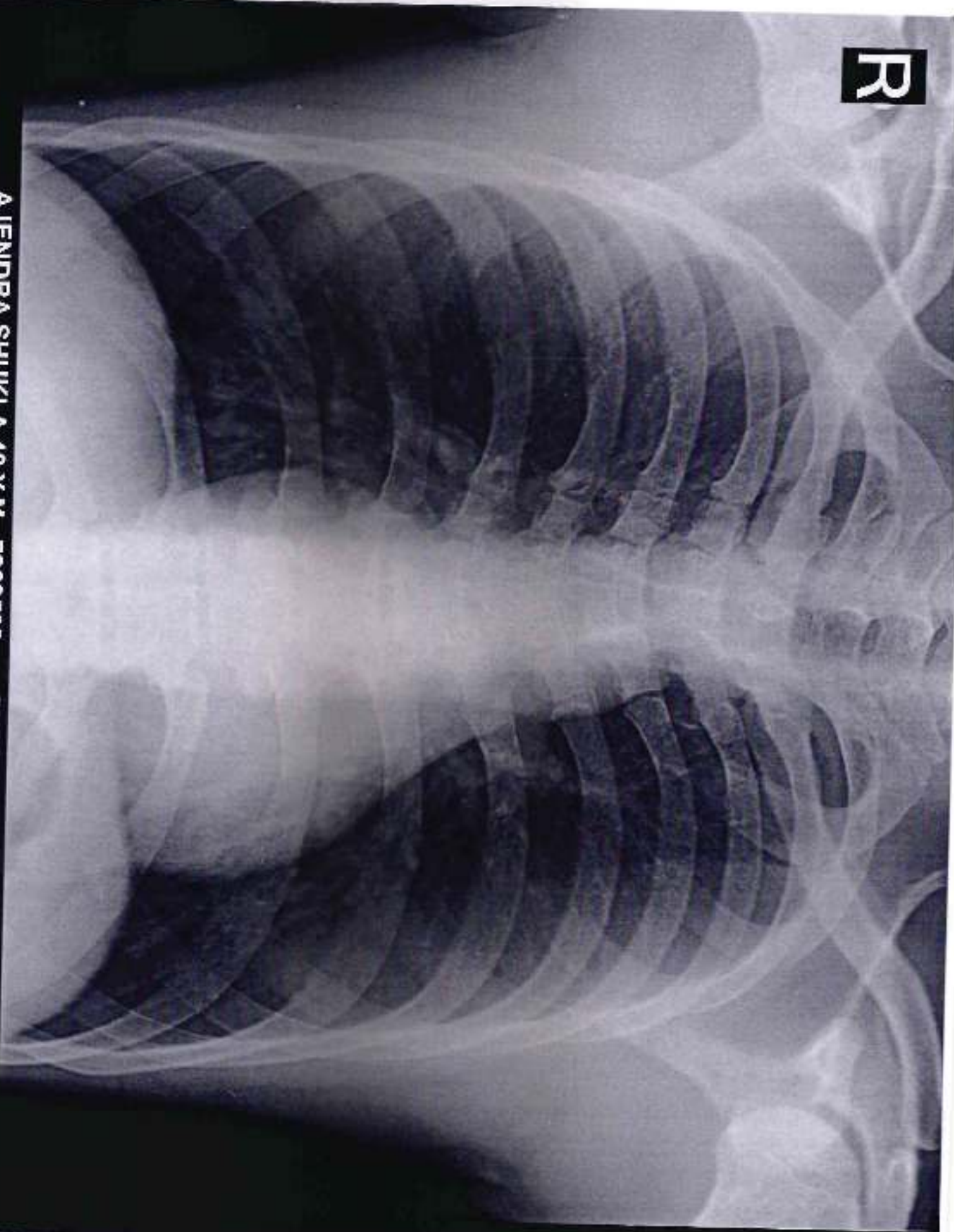
The visualized bony thorax is normal.

CONCLUSION : No Active Pulmonary Parenchymal Lesion is seen.

Abhishek

**DR ABHISHEK SINGH,
MBBS DMRE FMF
CONSULTANT RADIOLOGIST**

R



AJENDRA SHUKLA 40 Y M 7968508 CHEST,FRN P->A 13 11 24

SHREE GANESH DIAGNOSTIC CLINIC