

MR. DURGA PRASAD SHARMA

BOB

32 YEARS /MALE

01-4-2024

Height: 178 Cms

Weight: 66 Kg

BP: - 120/84 mmhg

Pulse: - 77/- Regular

BMI: - 20.8 kg/m²

EYE: - NORMAL

The Medical Examiner should record the findings under one of the following categories:-

FIT

UNFIT on account of



Dr. D.S. Chhabra

DR. D.S. CHHABRA

MBBS. MD.

MR. DURGA PRASAD SHARMA
BANK OF BARODA

32 Years /M
01-04-2024

HEAMOGRAM

Test Name	Results	Normal Range
Haemoglobin (HB)	14.8	13 - 18 gm%
R.B.C. Count	5.67	4.5 - 5.5 milli./cu.mm
PCV	47.7	40 - 50 %
MCV	84.13	80 - 95 fl
MCH	26.10	27 - 32 pg
MCHC	31.03	31.5 - 34.5 %
TOTAL WBC COUNT	5,900	4,000 to 11,000 /cu.mm
DIFFERENTIAL WBC COUNT	.	
Neutrophils	60	
Lymphocytes		40 - 75 %
	35	20 - 40 %
Monocytes	03	02 - 08 %
Eosinophils	02	01 - 05 %
Basophils	00	00 - 01 %
PLATELET COUNT	2.69	1.5 - 4 Laes/cu.mm.
E.S.R	13	M- 0-10 at the end of 1 hr. F- 0-20 at the end of 1 hr

DR. POOJA PRAPANNA
M.D.

DR. POOJA PRAPANNA
M.D.

Note :- All pathological tests have technical and biological limitations. Please correlate clinically as well as with other investigative findings.
A review should be requested in case of any disparity. This report is not valid for medicolegal purpose.

MR. DURGA PRASAD SHARMA

32 Years /M

BANK OF BARODA

01-04-2024

Test Name	Results	Normal Range
-----------	---------	--------------

HAEMATOLOGY PROFILE

BLOOD GROUP	: -
"ABO " GROUP	"B"
Rh (D) Factor	Positive

(Cross matching & recheck of Blood Group is mandatory before any transfusion)

SEROLOGY PROFILE

HBsAg	Non Reactive
-------	--------------

* Test done by screening methods.
Requires confirmation at referral centre.

BIOCHEMISTRY

FASTING BLOOD SUGAR	71.0	70 - 110 mg/dl
P.P. BLOOD SUGAR	85.0	upto 140 mg/dl
BUN	21.0	5 - 21 Mg/dl
CREATININE	1.27	0.6 - 1.4 mg\dl
URIC ACID	6.23	3.5 - 7 mg\dl
CALCIUM	8.67	8.5 - 10.5 mg\dl

DR. POOJA PRAPANNA
MDDR. POOJA PRAPANNA
M.D.

Note - All pathological tests have technical and biological limitations. Please correlate clinically as well as with other investigative findings.
A review should be requested in case of any disparity. This report is not valid for medicolegal purpose.

MR. DURGA PRASAD SHARMA

32 Years /M

BANK OF BARODA

01-04-2024

BIOCHEMISTRY

Test Name	Results	Normal Range
SERUM BILIRUBIN	:-	
TOTAL BILIRUBIN	0.83	0 - 1 mg/dl
DIRECT BILIRUBIN	0.15	<0.25 mg/dl
INDIRECT BILIRUBIN	0.68	< 1.0 mg/dl
S.G.O.T	22.0	0 - 45 IU/L
S.G.P.T	20.0	0 - 45 IU/L
ALKALINE PHOSPHATE	86.0	Adult - 42 - 128 IU/L Child - 150 - 630 IU/L
TOTAL PROTEIN	6.78	6.0 to 8.0 g/dl
ALBUMIN	4.12	3.2 to 5.0 g/dl
GLOBULIN	2.66	1.9 to 3.5
A:G RATIO	1.55	1.2 TO 2.3
GAMA GT	24.0	5 - 43 Iu/l

Dr. POOJA PRAPANNA
MDDR. POOJA PRAPANNA
M.D.

Note :- All pathological tests have technical and biological limitations. Please correlate clinically as well as with other investigative findings.
A review should be requested in case of any disparity. This report is not valid for medicolegal purpose.

MR. DURGA PRASAD SHARMA**32 Years /M****BANK OF BARODA****01-04-2024****LIPID PROFILE**

Test Name	Results	Normal Range
TOTAL LIPIDS	574	400 - 700 mg/dl
CHOLESTROL	200.0	<200 mg/dl- Desirable 200 - 239 mg/dl - Borderline High >240 Mg/dl High
HDL CHOLESTROL	39.0	35- 60 mg/dl
TRIGLYCERIDE	124.0	<150 mg/dl Normal 150 - 199 mg/dl Borderline High 200 - 499 mg/dl High
LDL CHOLESTROL	136.2	<100 mg/dl Optimal 100- 129 mg/dl Borderline high 160 - 189 mg/dl High
VLDL CHOLESTROL	24.8	<40 mg/dl
RISK RATIO	5.13	3 - 6

Dr. POOJA PRAPANNA
MD
DR. POOJA PRAPANNA
M.D.

MR. DURGA PRASAD SHARMA
BANK OF BARODA

32 Years /M
01-04-2024

HBA1C

Test Name	Results	Normal Range
HBA1C	5.40	Normal 4-6 % Good Control 6-7 % Fair Control 7-8 % Unsatisfactory Control 8-10 % Poor Control Above 10 %

Dr. POOJA PRAPANNA
MD
DR. POOJA PRAPANNA
M.D.

Note :- All pathological tests have technical and biological limitations. Please correlate clinically as well as with other investigative findings.
A review should be requested in case of any disparity. This report is not valid for medicolegal purpose.

MR. DURGA PRASAD SHARMA
BANK OF BARODA32 Years /M
01-04-2024**URINE EXAMINATION**

Test Name	Results	Normal Range
PHYSICAL EXAMINATION		
Quantity	30 ml	
Colour	Pale Yellow	
Appearance	Clear	
Deposits	Absent	
Specific Gravity	1.015	
Reaction	Acidic	
CHEMICAL EXAMINATION		
Albumin	Nil	
Sugar	Nil	
Ketones	Absent	
Bile Pigments	Negative	
Bile Salt	Negative	
Hematuria		
	Negative	
MICROSCOPIC EXAMINATION		
Pus Cells	1- 2 /hpf	
Red Blood Cells	Nil/hpf	
Epithelial Cell	1 - 2 /hpf	
Crystals	Nil	
Casts	Absent	

Dr. POOJA PRAPANNA
MDDR. POOJA PRAPANNA
M.D.

4D SONOGRAPHY • COLOR DOPPLER • ECHO • PATHOLOGY • DIGITAL X-RAY & OPG • TMT • ECG • HOLTER

MR. DURGA PRASAD SHARMA

32 Yrs./M

BOB

01st April, 2024

X-RAY CHEST PA VIEW

Bony cage is normal.

Trachea is central. C.P. angles are clear.

Cardiac contour and cardiothoracic ratio are normal.

Lung fields are clear.

DR.D.S.CHHABRA.

M.D.

MR. DURGA PRASAD SHARMA

32 Yrs./M.

BOB

01st April, 2024

ABDOMINAL SONOGRAPHY

Liver is of normal size, shape, has smooth margins & regular contours & the parenchyma is normal in echostructure. No focal lesion.

Gall bladder is of normal size, shape, has thin walls & the contents are clear fluid. No evidence of any calculus. Biliary tree is undilated.

Pancreas is normal, no focal / diffuse pathology. Spleen is normal. The portal and splenic veins are normal in calibre.

Both Kidneys are normal in size [measure about 11 cms. in length], shape and echostructure. No evidence of any calculus in both. The collecting system and ureter on both side are undilated.

Urinary bladder is normal in size, shape & has thin walls.

Prostate is of normal size (around 17 gms.) & is normal in echostructure.

There is no ascitis. No obvious abdominal lymphadenopathy. No sub / supra diaphragmatic pathology on either side.

IMPRESSION :

Normal study.

**DR.D.S.CHHABRA.**

M.D.



LABORATORY REPORT



Name : Mr DURGA PRASAD SHARMA	Sex/Age : Male / 32 Years	Case ID : 40401600046
Ref. By :	Dis. At :	Pt. ID :
Bill. Loc. : UNIQUE DIAGNOSTIC CENTRE INDORE		Pt. Loc. :
Reg Date and Time : 01-Apr-2024 11:04	Sample Type : Serum	Mobile No. :
Sample Date and Time : 01-Apr-2024 11:04	Sample Coll. By : non	Ref Id1 :
Report Date and Time : 01-Apr-2024 12:19	Acc. Remarks : -	Ref Id2 :

TEST	RESULTS	UNIT	BIOLOGICAL REF RANGE	REMARKS
Thyroid Function Test				
Triiodothyronine (T3) CMIA	132.42	ng/dL	58 - 159	
Thyroxine (T4) CMIA	8.94	µg/dL	4.6 - 10.5	
TSH CMIA	2.04	µIU/mL	0.4 - 4.2	

INTERPRETATIONS

- Circulating TSH measurement has been used for screening for euthyroidism, screening and diagnosis for hyperthyroidism & hypothyroidism. Suppressed TSH (<0.01 µIU/mL) suggests a diagnosis of hyperthyroidism and elevated concentration (>7 µIU/mL) suggest hypothyroidism. TSH levels may be affected by acute illness and several medications including dopamine and glucocorticoids. Decreased (low or undetectable) in Graves disease. Increased in TSH secreting pituitary adenoma (secondary hyperthyroidism), PRTN and in hypothalamic disease thyrotropin (tertiary hyperthyroidism). Elevated in hypothyroidism (along with decreased T4) except for pituitary & hypothalamic disease.
- Mild to modest elevations in patient with normal T3 & T4 levels indicates impaired thyroid hormone reserves & incipient hypothyroidism (subclinical hypothyroidism).
- Mild to modest decrease with normal T3 & T4 indicates subclinical hyperthyroidism.
- Degree of TSH suppression does not reflect the severity of hyperthyroidism, therefore, measurement of free thyroid hormone levels is required in patient with a suppressed TSH level.

CAUTIONS

Sick, hospitalized patients may have falsely low or transiently elevated thyroid stimulating hormone. Some patients who have been exposed to animal antigens, either in the environment or as part of treatment or imaging procedure, may have circulating antianimal antibodies present. These antibodies may interfere with the assay reagents to produce unreliable results.

TSH ref range in pregnancy

First trimester
Second trimester
Third trimester

Reference range (microIU/ml)

0.24 - 2.00
0.43-2.2
0.8-2.5

Note:(LL-VeryLow,L-Low,H-High,HH-VeryHigh ,A-Abnormal)

Dr Astha Dawani
Consultant Pathologist.

Dr. A Mishra
M.D. Microbiology

Dr. Soma Yadav
M.D. (Pathology)

Printed On : 01-Apr-2024 12:29

DR. PRIYANK JAIN

M.D.,D.M.

CONSULTANT CARDIOLOGIST

UNIQUE DIAGNOSTIC CENTRE

45-B, Jaora Compound,
Opp. M.Y.Hospital, M.Y.H. Road,
INDORE - 452 001. (M. P.).
Phone : 2704118. 4082228

ECHOCARDIOGRAPHY REPORT

NAME : MR. DURGA PRASAD SHARMA Age : 32 Yrs./ M
REFERRED BY : BOB Date : 01st April, 2024

ECHOCARDIOGRAPHIC OPINION

INTERPRETATION :-

- ** No RWMA.
- ** Good biventricular function. LVEF : 60 %.
- ** Normal cardiac valves, healthy pericardium.
- ** Grade I diastolic dysfunction.



Dr. PRIYANK JAIN
MBBS, MD, DM.
Reg. no. 19547

DR. PRIYANK JAIN. M.D.,D.M.

TWO DIMENSIONAL ECHOCARDIOGRAPHY

M Mode examination revealed normal movement of both mitral leaflets during diastole.

No SAM or mitral valve prolapse is seen.

Mitral valve opening is normal. No evidence of mitral valve prolapse is seen.

Tricuspid valve is normal, pulmonary valve is normal, aortic root is normal in size, dimensions of left atrium and left ventricle are normal.

Aortic cusps are not thickened and enclosure line is central.

Aortic valve has three cusps and its opening is not restricted.

2 - D imaging in PLAX, SAX and apical views revealed a normal sized left ventricle.

Movement of septum, anterior, posterior, inferior and lateral walls is normal. Global LVEF is 60 %.

Right atrium and right ventricle are normal in size.

Tricuspid valve leaflets move normally.

Pulmonary valve is normal.

Interatrial and interventricular septa are intact.

No intracardiac mass or thrombus is seen.

No pericardial pathology is observed.

MEASUREMENTS :

[C] DIMENSIONS	OBSERVED VALUES	Normal Values (For Adults)
1. Aortic Root diameter	: 3.3 cms.	2.0-3.7 cm < 2.2 cm / M ²
2. Aortic Valve Opening	: 1.7 cms.	1.5-2.6 cm
3. Right Ventricular Dimension	: --	
4. Left Atrial Dimension	: 3.4 cms.	1.9-4.0 cm < 2.2 cm / M ²
5. Left Ventricular ED Dimension	: 4.1 cms.	3.7-5.6 cm < 3.2 cm / M ²
6. Left Ventricular ES Dimension	: 2.5 cms.	2.2-4.0 cm
7. Inter Ventricular ED Septal thickness	: 1.5 cms.	0.6-1.2 cm
8. Left Ventricular ED PW thickness	: 1.4 cms.	0.5-1.0 cm
9. IVS / LVPW	: 01	< 1.3

[E] INDICES OF LEFT VENTRICULAR FUNCTION		
1. Mitral E - Septal Separation	: 0.5	< 0.9- cm
2. Left Ventricular Ejection Fraction	: 60 %	60 - 80 %

DOPPLER

Peak Flow Velocity (M/Sec.)		Peak Gradient (mmHg.)	Regurgitation
MV	Normal	--	Normal
TV	Normal	--	Normal
AV	Normal	--	Normal
PV	Normal	--	Normal

PASP : Normal

Handwritten signature

B बैंक ऑफ़ बड़ोदा
Bank of Baroda

नाम. दुर्गा प्रसाद शर्मा
Name **DURGA PRASAD SHARMA**

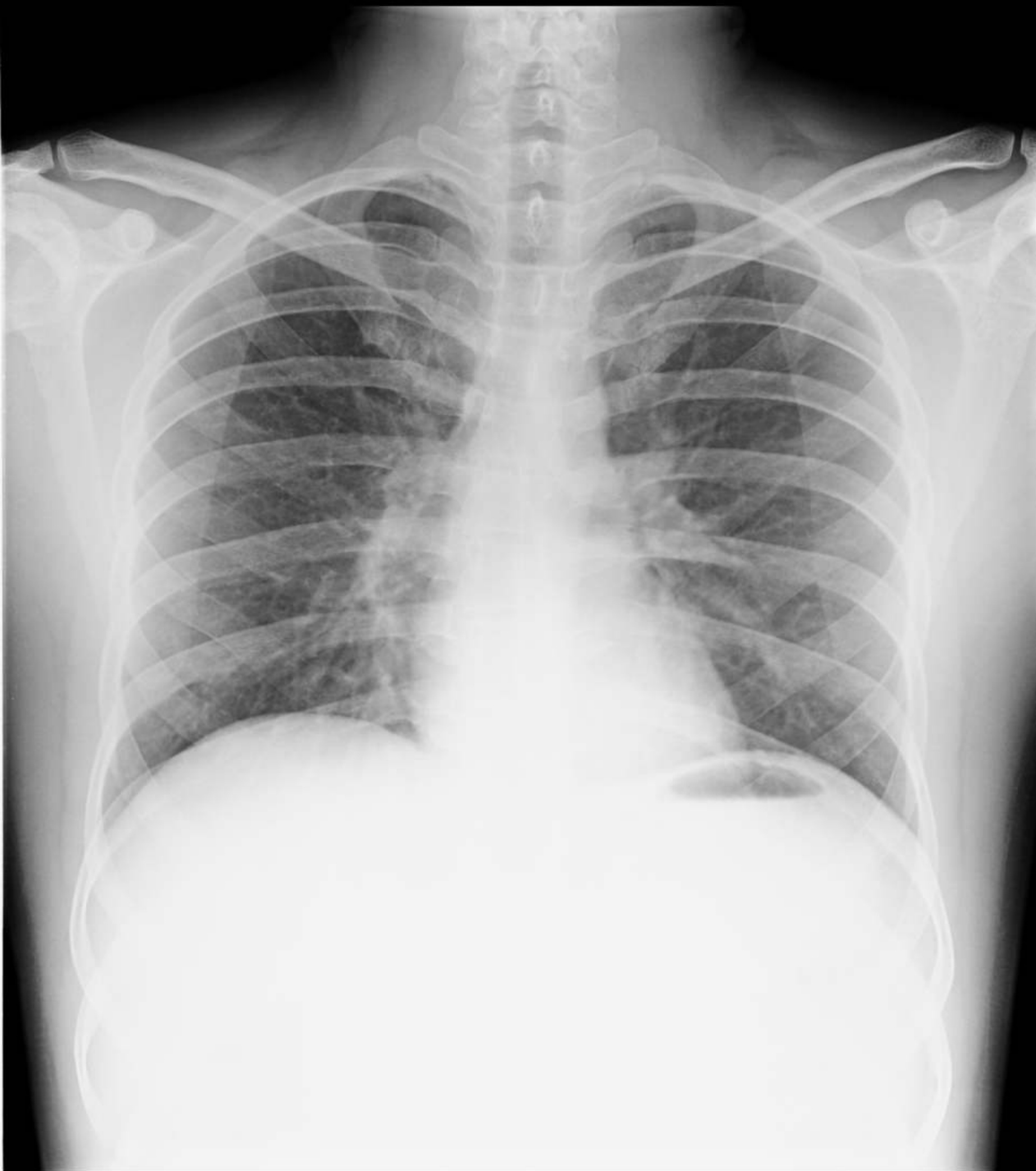कर्मचारी इडेंट नं. 179357
E.C. No.

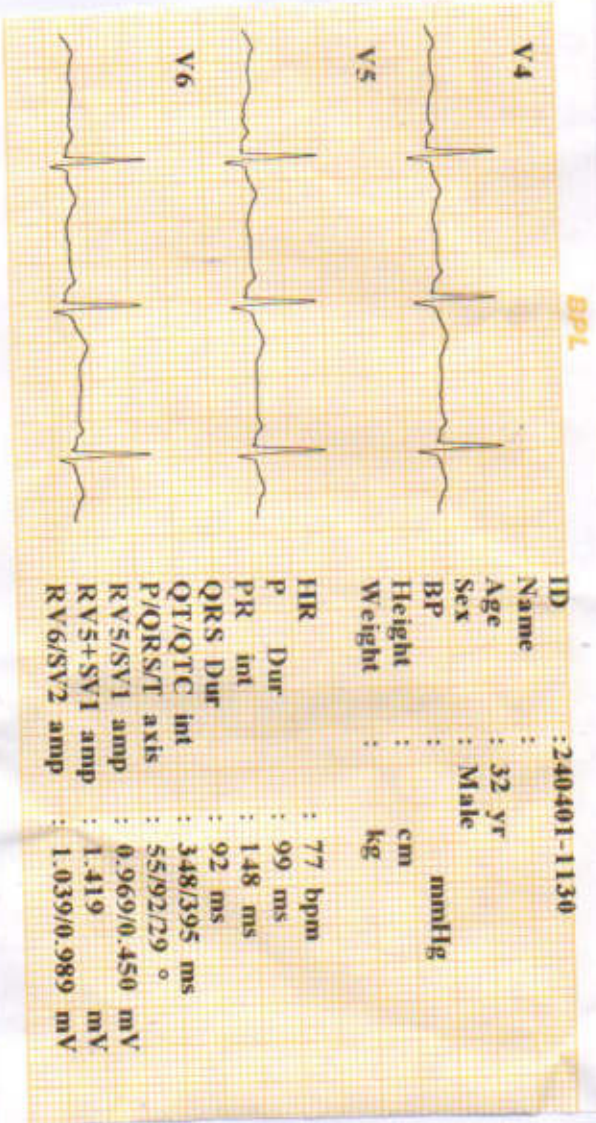
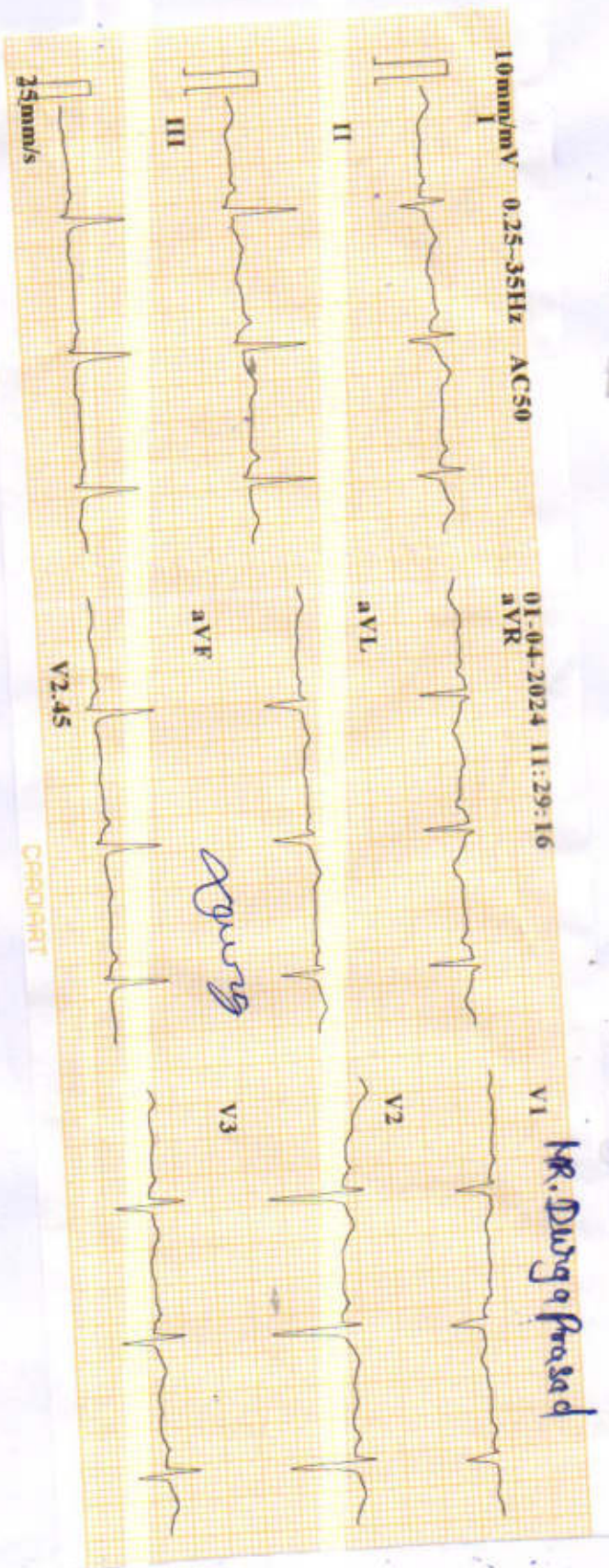Handwritten signature
आधिकारी प्राधिकारी
Issuing Authority

Handwritten signature
धारक के हस्ताक्षर
Signature of Holder



Dr. D. S. Chhabra
M.B.B.S., M.D.
Reg. No. 5087





DR. PRIYANK JAIN
MBBS, MD, DM
Reg. No. 19547

Handwritten signature and initials in blue ink.

UNIQUE DIAGNOSTIC CENTRE INDORE

01 Apr 2024
Name : MR. DURGA PRASAD SHARMA

Ref.by : BANK OF BARODA
Done by : DR. PRIYANK JAIN M.D.,DM.

