

DR. NETRAVALKAR'S ASHWINI PATHOLOGY LABORATORY

(For all investigations in Histopathology, Cytopathology, Haematology, Clinical Pathology, Microbiology & Hormonal Chemistry)

Consultant Pathologist **Dr. Prasad Netravalkar** MBBS, MD (Path) BOM

(HOME COLLECTION FACILITY AVAILABLE)

Panaji : 1st, Floor, Rizvi Sadan, Above Saroj Emporium, Near Inox Theatre, Opp. Municipal Market, Panaji.
Ph.: 2229142, 8407912840, 8390242524

E-mail : ashwinilabpanaji@gmail.com, drprasadnetravalkar@gmail.com

Mapusa : F8, Ramchandra Chambers, 1st Floor, Mapusa Clinic Road, Mapusa - Bardez, Goa. Ph : 2252320

Pt.No. : 11 240624

Pt.Name : Mr. Sawant Manohar Shantaram

Age : 56 Yrs. Sex : M

Ref. By : -

Date : 24-06-2024

Normal Range

COMPLETE HEMOGRAM

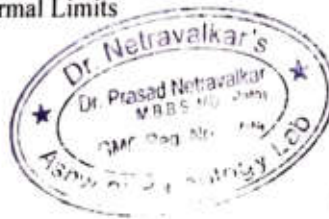
Haemoglobin	: 14.6	g/dl	13.5 - 18 g/dl
W.B.C Count	: 7900	cells/ cu-mm	4000 - 11000 cells/ cu-mm
R.B.C Count	: 5.10	millions / cu-mm	4.5 - 6.5 millions / cu-mm
MCV	: 80.8	fl	80 - 96 fl
MCH	: 28.7	Pg	27 - 33 Pg
MCHC	: 35.5	%	32 - 37 %
PCV	: 41.2	%	40 - 54 %
Platelet Count	: 3.04	lakhs /cu mm	1.5 - 4.5 lakhs /cu mm
E.S.R (Westergren)	: 10	mm/hr	0 - 20 mm/hr

DIFFERENTIAL COUNT

Stab Cells	: 04	%	1-5 %
Neutrophils	: 46	%	40 - 60 %
Lymphocytes	: 41	%	20 - 45 %
Eosinophils	: 04	%	1 - 6 %
Monocytes	: 05	%	0 - 10 %
Basophils	: 00	%	0 - 1 %
Abnormal Cells	: Nil		

SMEAR EXAMINATION

RBC Morphology	: Normocytic , Normochromic
W.B.C Morphology	: Within Normal Limits
Platelets on Smear	: Adequate
Parasites	: Absent



Pathologist

Dr. Prasad Netravalkar
MBBS, MD (Bom)
GMC Reg. No. 1294

We Care

All Diagnostic facilities under one roof in Panaji centre - Lab, ultrasound, X ray, ECG, TMT, ECHO

DR. NETRAVALKAR'S ASHWINI PATHOLOGY LABORATORY

(For all investigations in Histopathology, Cytopathology, Haematology, Clinical Pathology, Microbiology & Hormonal Chemistry)

Consultant Pathologist **Dr. Prasad Netravalkar** MBBS, MD (Path) BOM

(HOME COLLECTION FACILITY AVAILABLE)

Panaji : 1st. Floor, Rizvi Sadan, Above Saroj Emporium, Near Inox Theatre, Opp. Municipal Market, Panaji.
Ph.: 2229142, 8407912840, 8390242524

E-mail : ashwinilabpanaji@gmail.com, drprasadnetravalkar@gmail.com

Mapusa : FS, Ramchandra Chambers, 1st Floor, Mapusa Clinic Road, Mapusa - Bardez, Goa. Ph 2252320

Pt.No. : 11 240624

Pt.Name : Mr. Sawant Manohar Shantaram

Age : 56 Yrs. Sex : M

Ref. By : -

Date : 24-06-2024

		<u>Normal Range</u>
Fasting Blood Sugar	: 123.0 mg/dl	70 - 110 mg/dl
2 Hrs. Blood Sugar	: 218.0 mg/dl	110 - 140 mg/dl

GLYCOSYLATED HAEMOGLOBIN IN BLOOD (HPLC METHOD)

HbA1C : 6.50 %

Mean Blood Glucose : 140 mg %

INTERPRETATION:

HbA1c %

NORMAL

Below 6.5 %

GOOD DIABETIC CONTROL

6.5 % - 7.5 %

FAIR CONTROL

7.5 % - 8.0 %

UNSATISFACTORY CONTROL

8.0 % - 10.0 %

POOR CONTROL

Above 10.0 %



Pathologist

Dr. Prasad Netravalkar

MBBS, MD (Bom)
GMC Reg. No. 1294

We Care

All Diagnostic facilities under one roof in Panaji centre - Lab, ultrasound, X ray, ECG, TMT, ECHO

DR. NETRAVALKAR'S ASHWINI PATHOLOGY LABORATORY

(For all investigations in Histopathology, Cytopathology, Haematology, Clinical Pathology, Microbiology & Hormonal Chemistry)

Consultant Pathologist **Dr. Prasad Netravalkar** MBBS, MD (Path) BOM

(HOME COLLECTION FACILITY AVAILABLE)

Panaji : 1st, Floor, Rizvi Sadan, Above Saroj Emporium, Near Inox Theatre, Opp. Municipal Market, Panaji.
Ph.: 2229142, 8407912840, 8390242524

E-mail : ashwinilabpanaji@gmail.com, drprasadnetravalkar@gmail.com

Mapusa : FS, Ramchandra Chambers, 1st Floor, Mapusa Clinic Road, Mapusa - Bardez, Goa. Ph : 2252320

Pt.No. : 11 240624

Pt.Name : Mr. Sawant Manohar Shantaram

Age : 56 Yrs. Sex : M

Ref. By : -

Date : 24-06-2024

Normal Range

LIPID PROFILE

Total Cholesterol	: 171.0 mg/dl	130 - 220 mg/dl
S. Triglycerides	: 113.0 mg/dl	35 - 170 mg/dl
HDL Cholesterol	: 39.0 mg/dl	> 35 mg/dl
LDL Cholesterol	: 109 mg/dl	< 130 mg/dl
VLDL Cholesterol	: 23 mg/dl	Upto 35 mg/dl
TC/HDL Ratio	: 4.4	< 4.5
LDLC/HDL Ratio	: 2.8	2.5 - 3.5



24/6/24
Pathologist

Dr. Prasad Netravalkar
MBBS, MD (Bom)
GMC Reg. No. 1294

We Care

All Diagnostic facilities under one roof in Panaji centre - Lab, ultrasound, X ray, ECG, TMT, ECHO

**DR. NETRAVALKAR'S
ASHWINI PATHOLOGY LABORATORY**

(For all investigations in Histopathology, Cytopathology, Haematology, Clinical Pathology, Microbiology & Hormonal Chemistry)
Consultant Pathologist **Dr. Prasad Netravalkar** MBBS, MD (Path) BOM

(HOME COLLECTION FACILITY AVAILABLE)

Panaji : 1st, Floor, Rizvi Sadan, Above Saroj Emporium, Near Inox Theatre, Opp. Municipal Market, Panaji.
Ph.: 2229142, 8407912840, 8390242524

E-mail : ashwinilabpanaji@gmail.com, drprasadnetravalkar@gmail.com

Mapusa : FS, Ramechandra Chambers, 1st Floor, Mapusa Clinic Road, Mapusa - Bardez, Goa. Ph.: 2252320

Pt.No. : 11 240624

Pt.Name : Mr. Sawant Manohar Shantaram

Age : 56 Yrs. Sex : M

Ref. By : -

Date : 24-06-2024

Normal Range

LIVER FUNCTION TEST

S. Bilirubin (Total)	: 0.49	mg/dl	0 - 1 mg/dl
S. Bilirubin (Direct)	: 0.20	mg/dl	0 - 0.25 mg/dl
S. Bilirubin (Indirect)	: 0.29	mg/dl	0 - 0.75 mg/dl
S.G.O.T	: 16.0	U/L	0 - 42 U/L
S.G.P.T	: 18.0	U/L	0 - 42 U/L
S. Alkaline Phosphatase	: 89.0	IU/L	15 - 112 IU/L
GGTP	: 21.0	U/L	11-43 U/L
Total Proteins	: 7.10	g/dl	6.0 - 10.0 g/dl
S. Albumin	: 4.01	gm%	3.2 - 5.5 gm%
S. Globulin	: 3.1	g/dl	2.3 - 3.5 g/dl
A/G Ratio	: 1.3 : 1		



Dr. Prasad Netravalkar
MBBS, MD (Bom)
GMC Reg. No. 1294

We Care

All Diagnostic facilities under one roof in Panaji centre - Lab, ultrasound, X ray, ECG, TMT, ECHO

DR. NETRAVALKAR'S ASHWINI PATHOLOGY LABORATORY

(For all investigations in Histopathology, Cytopathology, Haematology, Clinical Pathology, Microbiology & Hormonal Chemistry)
Consultant Pathologist **Dr. Prasad Netravalkar** MBBS, MD (Path) BOM

(HOME COLLECTION FACILITY AVAILABLE)

Panaji : 1st. Floor, Rizvi Sadan, Above Saroj Emporium, Near Inox Theatre, Opp. Municipal Market, Panaji.
Ph.: 2229142, 8407912840, 8390242524

E-mail : ashwinilabpanaji@gmail.com, drprasadnetravalkar@gmail.com

Mapusa : F8, Ramchandra Chambers, 1st Floor, Mapusa Clinic Road, Mapusa - Bardez, Goa. Ph : 2252320

Pt.No. : 11 240624

Pt.Name : Mr. Sawant Manohar Shantaram

Age : 56 Yrs. Sex : M

Ref. By : -

Date : 24-06-2024

Normal Range

KIDNEY FUNCTION TESTS

Blood Urea	: 29.0 mg/dl	15 - 40 mg/dl
S. Creatinine	: 1.02 mg/dl	0.7 - 1.4 mg/dl
S. Uric Acid.	: 6.10 mg/dl	2.5-7.5 mg/dl
S. Sodium	: 139.7 mEq/L	135 - 155 mEq/L
S. Potassium	: 4.01 mEq/L	3.5 - 5.5 mEq/L
S. Chlorides	: 100.8 mEq/L	99 - 108 mEq/L



Pathologist

Dr. Prasad Netravalkar
MBBS, MD (Bom)
GMC Reg. No. 1294

We Care

All Diagnostic facilities under one roof in Panaji centre - Lab, ultrasound, X ray, ECG, TMT, ECHO

**DR. NETRAVALKAR'S
ASHWINI PATHOLOGY LABORATORY**

(For all investigations in Histopathology, Cytopathology, Haematology, Clinical Pathology, Microbiology & Hormonal Chemistry)

Consultant Pathologist **Dr. Prasad Netravalkar** MBBS MD (Path) BDM

(HOME COLLECTION FACILITY AVAILABLE)

Panaji : 1st. Floor, Rizvi Sadan, Above Saroj Emporium, Near Inox Theatre, Opp. Municipal Market, Panaji.
Ph.: 2229142, 8407912840, 8390242524

E-mail : ashwinilabpanaji@gmail.com, drprasadnetravalkar@gmail.com

Mapusa : FS, Ramchandra Chambers, 1st Floor, Mapusa Clinic Road, Mapusa - Bardez, Goa. Ph. 2252320

Pt.No. : 11 240624

Pt.Name : Mr. Sawant Manohar Shantaram

Age : 56 Yrs. Sex : M

Ref. By : -

Date : 24-06-2024

BIOCHEMISTRY REPORTS

Fasting Urine Glucose : Absent

2 Hrs. Urine Glucose : Absent



[Signature]
Pathologist

Dr. Prasad Netravalkar

MBBS, MD (Bom)
GMC Reg. No. 1294

We Care

All Diagnostic facilities under one roof in Panaji centre - Lab, ultrasound, X ray, ECG, TMT, ECHO

DR. NETRAVALKAR'S
ASHWINI PATHOLOGY LABORATORY

Investigations in Histopathology, Cytopathology, Haematology, Clinical Pathology, Microbiology & Hormonal Chemistry
Consultant Pathologist **Dr. Prasad Netravalkar** MBBS, MD (Path) BOM
(HOME COLLECTION FACILITY AVAILABLE)

Panaji : 1st. Floor, Rizvi Sadan, Above Saroj Emporium, Near Inox Theatre, Opp. Municipal Market, Panaji.
Ph.: 2229142, 8407912840, 8390242524
E-mail : ashwinilabpanaji@gmail.com, drprasadnetravalkar@gmail.com
Mapusa : ES, Ramchandra Chambers, 1st Floor, Mapusa Clinic Road, Mapusa - Bardez, Goa. Ph. : 2252420

Pt.No. : 11 240624
Pt.Name : Mr. Sawant Manohar Shantaram Age : 56 Yrs. Sex : M
Ref. By : - Date : 24-06-2024

EXAMINATION OF URINE

PHYSICAL EXAMINATION

Quantity : 20 ml
Colour : Pale Yellow
Appearance : Clear
pH : 6.5
Specific Gravity : 1.010

CHEMICAL EXAMINATION

Proteins : Absent
Glucose : Absent
Ketone Bodies : Absent
Bile Salts : Absent
Bile Pigments : Absent
Occult Blood : Negative
Urobilinogen : Normal

MICROSCOPIC EXAMINATION [As per hpf]

Epithelial Cells : Occasional /hpf
Pus Cells : Occasional /hpf
Red Blood Cells : Absent
Casts : Absent
Crystals : Absent



Pathologist

Dr. Prasad Netravalkar
MBBS, MD (Bom)
GMC Reg. No. 1294

We Care

All Diagnostic facilities under one roof in Panaji centre - Lab, ultrasound, X ray, ECG, TMT, ECHO

DR. NETRAVALKAR'S ASHWINI PATHOLOGY LABORATORY

Special Investigations in Histopathology, Cytopathology, Haematology, Clinical Pathology, Microbiology & Hormonal Chemistry)
Consultant Pathologist **Dr. Prasad Netravalkar** MBBS, MD (Path) BOM
(HOME COLLECTION FACILITY AVAILABLE)

Panaji : 1st. Floor, Rizvi Sadan, Above Saroj Emporium, Near Inox Theatre, Opp. Municipal Market, Panaji.
Ph.: 2229142, 8407912840, 8390242524
E-mail : ashwinilabpanaji@gmail.com, drprasadnetravalkar@gmail.com
Mapusa : FS, Ramchandra Chambers, 1st Floor, Mapusa Clinic Road, Mapusa - Bardez, Goa. Ph. 2252320

Patient Name : MR. SAWANT MANOHAR SHANTARAM
Age / Gender : 56 / Male
Patient ID : 33215
Source : DIRECT

Referral : SELF
Reporting Time : Jun 22, 2024, 02:24 p.m.
Sample ID :  241740014

Test Description	Value(s)	Reference Range	Unit
PSA (Prostate Specific Antigen)-Total	1.86	0 - 4	ng/ml.

PSA- Prostate Specific Antigen*

INTERPRETATION :

Prostate-specific antigen (PSA) is a glycoprotein that is produced by the prostate gland, the lining of the urethra, and the bulbourethral gland. PSA exists in serum mainly in two forms, complexed to alpha-1-anti-chymotrypsin (PSA-ACT complex) and unbound (free PSA). Increases in prostatic glandular size and tissue damage caused by benign prostatic hypertrophy, prostatitis, or prostate cancer may increase circulating PSA levels. Transient increase in PSA can also be seen following per rectal digital or sonological examinations.

Note: Patients on Biotin supplement may have interference in some immunoassays. With individuals taking high dose Biotin (more than 5 mg per day) supplements, at least 8-hour wait time before blood draw is recommended.

END OF REPORT



(Handwritten Signature)

Pathologist

Dr. Prasad Netravalkar
MBBS, MD (Bom)
GMC Reg. No. 1294

We Care

All Diagnostic facilities under one roof in Panaji centre - Lab, ultrasound, X ray, ECG, TMT, ECHO

DR. NETRAVALKAR'S ASHWINI PATHOLOGY LABORATORY

Investigations in Histopathology, Cytopathology, Haematology, Clinical Pathology, Microbiology & Hormonal Chemistry)
Consultant Pathologist **Dr. Prasad Netravalkar** MBBS, MD (Path) BOM

(HOME COLLECTION FACILITY AVAILABLE)

Panaji : 1st, Floor, Rizvi Sadan, Above Saroj Emporium, Near Inox Theatre, Opp. Municipal Market, Panaji.
Ph.: 2229142, 8407912840, 8390242524

E-mail : ashwinilabpanaji@gmail.com, drprasadnetravalkar@gmail.com

Mapusa : FS, Ramchandra Chambers, 1st Floor, Mapusa Clinic Road, Mapusa - Bardez, Goa Ph : 2252320

Patient Name : MR. SAWANT MANOHAR SHANTARAM

Age / Gender : 56 / Male

Patient ID : 33215

Source : DIRECT

Referral : SELF

Reporting Time : Jun 22, 2024, 02:23 p.m.

Sample ID :



241740014

Test Description	Value(s)	Reference Range	Unit
------------------	----------	-----------------	------

Vitamin B12, Cynacobalamin

Vitamin B12-Cyanocobalamin Method Serum, ECLIA	470.3	187 - 883	pg/mL
---	-------	-----------	-------

Interpretation:

- Vit B12 levels are decreased in megaloblastic anemia, partial/total gastrectomy, pernicious anemia, peripheral neuropathies, chronic alcoholism, senile dementia, and treated epilepsy.
- An associated increase in homocysteine levels is an independent risk marker for cardiovascular disease and deep vein thrombosis.
- HoloTranscobalamin II levels are a more accurate marker of active VitB12 component.

Note: Patients on Biotin supplement may have interference in some immunoassays. With individuals taking high dose Biotin (more

than 5 mg per day) supplements, at least 8-hour wait time before blood draw is recommended.

Ref: Arch Pathol Lab Med—Vol 141, November 2017

END OF REPORT



Pathologist

Dr. Prasad Netravalkar
MBBS, MD (Bom)
GMC Reg. No. 1294

We Care

All Diagnostic facilities under one roof in Panaji centre - Lab, ultrasound, X ray, ECG, TMT, ECHO

DR. NETRAVALKAR'S ASHWINI PATHOLOGY LABORATORY

Investigations in Histopathology, Cytopathology, Haematology, Clinical Pathology, Microbiology & Hormonal Chemistry.
Consultant Pathologist **Dr. Prasad Netravalkar** MBBS, MD (Path) BOM
(HOME COLLECTION FACILITY AVAILABLE)

Panaji : 1st, Floor, Rizvi Sadan, Above Saroj Emporium, Near Inox Theatre, Opp. Municipal Market, Panaji.
Ph.: 2229142, 8407912840, 8390242524
E-mail : ashwinilabpanaji@gmail.com, drprasadnetravalkar@gmail.com
Mapusa : FS, Ramchandra Chambers, 1st Floor, Mapusa Clinic Road, Mapusa - Bardez, Goa. Ph - 2252320

Patient Name : MR. SAWANT MANOHAR SHANTARAM

Referral : SELF

Age / Gender : 56 / Male

Reporting Time : Jun 22, 2024, 02:24 p.m

Patient ID : 33215

Sample ID :



Source : DIRECT

Test Description	Value(s)	Reference Range	Unit
------------------	----------	-----------------	------

Vitamin D3 Total

Vitamin D3 Total **29.07** 30.0 - 100.0 ng/ml

Method - ECL

Interpretations

1. Cholecalciferol (Vitamin D3) is synthesized in the skin from 7 dehydrocholesterol in response to sunlight, some part also comes from Diet and supplements. Ergocalciferol (Vitamin D2) comes essentially from diet and supplements
2. Both Cholecalciferol and Ergocalciferol are converted in the liver to 25 OH Vitamin D. 25 OH Vitamin D is further hydroxylated in the kidneys to produce 1, 25 Dihydroxy Vitamin D.
3. The measurement of 1,25 Dihydroxy Vitamin D is indicated in several disorders affecting calcium metabolism such as sarcoidosis, renal failure, hyper or hypo -parathyroidism, rickets, tumour associated hypercalcemia, vitamin resistant dysfunction and treatment with anti-convulsive medication.

END OF REPORT



Pathologist

Dr. Prasad Netravalkar
MBBS, MD (Bom)
GMC Reg. No. 1294

We Care

All Diagnostic facilities under one roof in Panaji centre - Lab, ultrasound, X ray, ECG, TMT, ECHO

DR. NETRAVALKAR'S ASHWINI PATHOLOGY LABORATORY

Investigations in Histopathology, Cytopathology, Haematology, Clinical Pathology, Microbiology & Hormonal Chemistry

Consultant Pathologist: **Dr. Prasad Netravalkar** MBBS, MD (Path) BOM

(HOME COLLECTION FACILITY AVAILABLE)

Panaji : 1st. Floor, Rizvi Sadan, Above Saroj Emporium, Near Inox Theatre, Opp. Municipal Market, Panaji.
Ph.: 2229142, 8407912840, 8390242524

E-mail : ashwinilabpanaji@gmail.com, drprasadnetravalkar@gmail.com

Mapusa : FS, Ramchandra Chambers, 1st Floor, Mapusa Clinic Road, Mapusa - Bardez, Goa Ph : 2252320

Patient Name : MR. SAWANT MANOHAR SHANTARAM

Age / Gender : 56 / Male

Patient ID : 33215

Source : DIRECT

Referral : SELF

Reporting Time : Jun 22, 2024, 02:24 p.m.

Sample ID :



241740014

Test Description	Value(s)	Reference Range	Unit
Thyroid Profile			
T3 (Total) Method : Serum ECL	1.96	1.30 - 3.10	nmol/l
T4 (Total)* Method : Serum ECL	129.4	66.0 - 181.0	nmol/l
TSH(Ultrasensitive)* Method : Serum ECL	4.66	0.270 - 4.20	uIU/ml

END OF REPORT



Pathologist

Dr. Prasad Netravalkar
MBBS, MD (Bom)
GMC Reg. No. 1294

We Care

All Diagnostic facilities under one roof in Panaji centre - Lab, ultrasound, X ray, ECG, TMT, ECHO

ASHWINI PATHOLOGY LABORATORY



Offer all investigations in Histopathology, Cytopathology, Haematology, Clinical Pathology, Microbiology & Hormonal Chemistry)
Consultant Pathologist - **Dr. Prasad Netravalkar** MBBS MD (Path) BOM
(HOME COLLECTION FACILITY AVAILABLE)

Panaji : 1st, Floor, Rizvi Sadan, Above Saroj Emporium, Near Inox Theatre, Opp. Municipal Market, Panaji.
Ph.: 2229142, 8407912840, 8390242524
E-mail : ashwinilabpanaji@gmail.com, drprasadnetravalkar@gmail.com

Mapusa : F8, Ramchandra Chambers, 1st Floor, Mapusa Clinic Road, Mapusa - Bardez, Goa. Ph : 2252320

Pt.No. : 11 240624
Pt.Name : Mr. Sawant Manohar Shantaram
Ref. By : -
Age : 56 Yrs. Sex : M
Date : 24-06-2024

Blood Group : 'A' Rh Positive



Pathologist

Dr. Prasad Netravalkar
MBBS, MD (Bom)
GMC Reg. No 1294

We Care

All Diagnostic facilities under one roof in Panaji centre - Lab, ultrasound, X ray, ECG, TMT, ECHO

CERTIFICATE OF MEDICAL FITNESS

This is to certify that I have conducted the clinical examination

of Sawant Manohar on 24/6/24

After reviewing the medical history and on clinical examination it has been found that he/she is

	Tick
<ul style="list-style-type: none">• Medically Fit	<input checked="" type="checkbox"/>
<ul style="list-style-type: none">• Fit with restrictions/recommendations <p>Though following restrictions have been revealed, in my opinion, these are not impediments to the job.</p> <p>1.....</p> <p>2.....</p> <p>3.....</p> <p>However the employee should follow the advice/medication that has been communicated to him/her.</p> <p>Review after _____</p>	<input type="checkbox"/>
<ul style="list-style-type: none">• Currently Unfit. <p>Review after _____ recommended</p>	<input type="checkbox"/>
<ul style="list-style-type: none">• Unfit	<input type="checkbox"/>

Dr. [Signature]
Medical Officer
The Apollo Clinic, (Location)

This certificate is not meant for medico-legal purposes.





MER- MEDICAL EXAMINATION REPORT

Date of Examination	24/6/24.	
NAME	Saurant Manohar	
AGE	56	Gender male
HEIGHT(cm)	176	WEIGHT (kg) 76
BP	180/114 mmHg	
ECG	— Normal —	
X Ray	— Normal —	
Vision Checkup	Color Vision : Normal	
	Far Vision Ratio : 6/6	
	Near Vision Ratio : 6/6	
Present Ailments	— No —	
Details of Past ailments (If Any)	— No —	
Comments / Advice : She / He is Physically Fit	Healthy	

Signature with Stamp of Medical Examiner

भारत सरकार
GOVERNMENT OF INDIA

मनोहर शंता राम सावंत
Manohar Shantaram Sawant
जन्म वर्ष / Year of Birth : 1969
पुरुष / Male



9359 2751 2326

आधार — सामान्य माणसाचा अधिकार

Handwritten signature



Principal N



Dr. Netravalkar's
Pathology Lab

GPS Map Camera



Panaji, Goa, India
B 165, New Municipal Market, Panaji, Goa 403001, India
Lat 15.498466°
Long 73.822388°
22/06/24 09:25 AM GMT +05:30

Handwritten signature

201,202,203, Rizvi Sadan, 2nd Floor, Near Municipal Market, Next to Vaidya Hospital, Panaji - Goa
Tel.: 0832 2238122 | Email: drashanetravalkar@gmail.com

Cardiology Report

Page 1/2

ASHWINI LABORATORY

Date of Exam 22.06.2024

Patient / Exam Information

Patient ID VS8802280-24-06-22-2
Name **APARAJITHA SAWANT 56**
DOB, Age
Sex **Other**
Height
Weight
BSA
HR

Perf. Phys Ref Phys Sonographer
Comment Indication

M-Mode Measurements	Value	m1	m2	m3	m4	m5	m6	Meth
AVILA								
Ao Root Diam.	3.26 cm	3.26						avg.
LA Diam	3.08 cm	3.08						avg.
Left Ventricle								
IVSd	1.21 cm	1.21						avg.
LVDd	4.41 cm	4.41						avg.
LVPWd	1.03 cm	1.03						avg.
IVSs	0.54 cm	0.54						avg.
LVDs	2.72 cm	2.72						avg.
LVPWs	1.27 cm	1.27						avg.
EDV (Teich)	88.159 ml	88.159						
EDV (Cubed)	85.766 ml	85.766						
ESV (Teich)	27.513 ml	27.513						
ESV (Cubed)	20.124 ml	20.124						
SV (Teich)	60.646 ml	60.646						
SV (Cube)	65.642 ml	65.642						
EF (Teich)	68.79 %	68.79						
EF (Cube)	76.54 %	76.54						
Fract. Short.	38.32 %	38.32						
LV Mass	203.05 g	203.05						

2D Generic	Value	m1	m2	m3	m4	m5	m6	Meth
Dist.								
D	1.17 cm	1.17						avg.

1 / 2
22.06.2024 4:06:48 PM

Netravalkar's Echocardiography Centre

Dr. Ashadevi Netravalkar
MBBS., MD, AFIH
Consultant Radiologist & Sonologist

201,202,203, Rizvi Sadan, 2nd Floor, Near Municipal Market, Next to Vaidya Hospital, Panaji - Goa.
Tel.: 0832 2238122 | Email : drashanetravalkar@gmail.com

Name

MANOHAR SAWANT 56

Patient ID

VS8802280-24-06-22-2

Comment

NON-DILATED LEFT VENTRICLE WITH MILD BASAL SEPTUM HYPERTROPHY AND PRESERVED EJECTION FRACTION. NO REGIONAL WALL MOTION ABNORMALITIES. VALVES ARE GROSSLY NORMAL. AORTIC ROOT IS NORMAL. PERICARDIUM IS NORMAL.

Ashadevi

Date

22.06.2024

Perf. Physician:

Sonographer:

2 / 2
22.06.2024 4:06:48 PM

201,202,203, Rizvi Sadan, 2nd Floor, Near Municipal Market, Next to Vaidya Hospital, Panaji - Goa
Tel.: 0832 2238122 | Email : drashanetravalkar@gmail.com

NAME: MR.MANOHAR SAWANT
AGE: 56/YRS
REF BY: DR.SELF

DATE: 22/06/2024
SEX: M

ULTRASONOGRAPHY OF ABDOMEN AND PELVIS

LIVER – It shows mild increased echotexture and normal size. No focal lesions are seen.

Intrahepatic biliary and portal radicals appear normal. Length of liver is 12.2cm.PV -9mm.

PANCREAS— It shows normal echotexture and size. No focal lesions are seen.

GALL BLADDER---It is moderately distended. No calculus is seen. Pericholecystic space is normal.CBD is normal.

SPLEEN----- It shows normal echotexture and size. Length of spleen is 9.5cm.

BOTH KIDNEYS Both kidneys show normal echotexture and size. Corticomedullary differentiation is seen well . Perirenal space is normal.

Right kidney--measures 10.6cm x4.7cms .

Mild hydronephrosis . No calculus is seen.

Left kidney—measures 9.1cm x 4.1cms .

No calculus or hydronephrosis is seen.

Urinary Bladder is well distended .No calculus or mass is seen .Wall thickness is 3mm.

Both VUJs are normal.

PVR is 20ml .

Prostate measures 4.4cms x4.4cmsx 3.4cms Weight is 35gms.

No calcification or mass is seen.

No free fluid is seen in pelvis.

Impression : MILD RIGHT HYDRONEPHROSIS .
PROSTAOMEGALY.

With regards,



DR.ASHADEVI NETRAVALKAR,MD
RADIOLOGIST

DR. ASHADEVI NETRAVALKAR
MBBS, MD, AFH

Consultant Radiologist
2nd Floor, Rizvi Sadan Panaji
Tel: 0832-2238122 / 9522125224

201,202,203, Rizvi Sadan, 2nd Floor, Near Municipal Market, Next to Vaidya Hospital, Panaji - Goa
Tel.: 0832 2238122 | Email : drashanetravalkar@gmail.com

NAME: MR.MANOHAR SAWANT
AGE: 56/YRS
REF BY: DR.SELF

DATE: 22/06/2024
SEX: M

X-RAY CHEST--- PA VIEW

Prominent bronchovascular markings are seen. Otherwise lung fields are clear.

Both costophrenic angles are clear.

Cardiac size is normal.

Both domes of diaphragm are normal.

Rib cage is normal.

IMPRESSION : Normal study.

With regards,



DR.ASHADEVI NETRAVALKAR, MD
RADIOLOGIST

DR. ASHADEVI NETRAVALKAR, MD
Consultant Radiologist & Sonologist
201,202,203, Rizvi Sadan, 2nd Floor,
Near Municipal Market, Next to Vaidya Hospital,
Panaji - Goa

Dr. Netravalkar's Imaging Centre

Dr. Ashadevi Netravalkar

MBBS., MD, AFIH

Consultant Radiologist & Sonologist

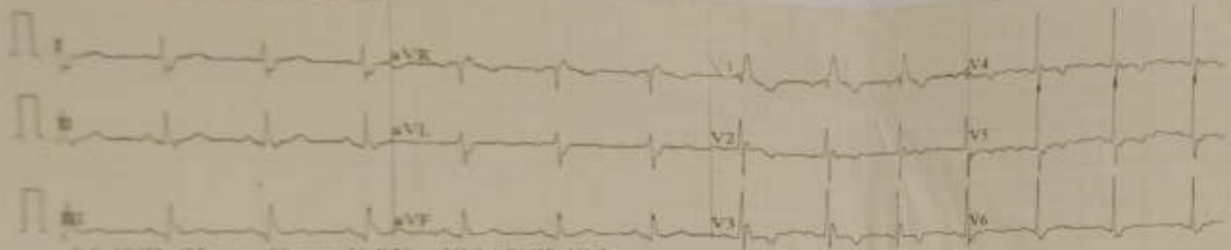
Name : MANOHAR SAWANT
Age : 56 M/F M Date : 22.06.24
Investigation : ECG
Ref. by Dr. : _____

201,202,203, Rizvi Sadan, 2nd Floor, Near Municipal Market,
Next to Vaidya Hospital, Panaji - Goa.

Tel.: 0832 2238122 | Email : drashanetravalkar@gmail.com

Timing : 8.00 am to 1.00 pm | 4.00 pm to 7.00 pm

ID: 405 22-06-2024 23:41:18



0.5-100Hz 25mm/s 10mm/mV ♥79 V10 SEMIP V17



ID: 405

Male mmHg

37 years

cm kg

[Signature]

HR	79	bpm
P	112	ms
PR	156	ms
QRS	87	ms
QT/QTc	380/447	ms
PR/ST	77/93.49	ms
QT/ST	101/103	ms

ECG shows sinus rhythm
with normal intervals
Advised to consult
Cardiologist

[Signature]
24/6/24

DR. SIGN.